

Role of Dynamic Magnetic Resonance Imaging in Assessment of Female Pelvic Floor Dysfunction

Aliaa S Sheha, MSc*, Ola M Nouh, MD*, Inas M Azab, MD*,
Mohamed A Nassef*, MD*, Ahmed M Ibrahim, MD**.

* Departments of Radiodiagnosis and ** Obstetrics and Gynecology, Faculty of Medicine,
Ain Shams University.

Abstract

Introduction: Pelvic floor weakening is a major health problem in older women, with an 11.1% lifetime risk of women over 50 years old to undergo surgery for pelvic organ prolapse and urinary incontinence. Clinical examination is the main method of diagnosis, yet imaging is essential especially in patients with multicompartiment defects. Pelvic Magnetic Resonance (MR) Imaging is expected to play a role in the preoperative planning for complex cases due to its high soft tissue resolution, which will help perform site-specific repair and so avoid recurrence.

Aim of the work: The aim of this work is to evaluate the role of Magnetic Resonance Imaging as a non invasive method in the assessment of female pelvic floor dysfunction.

Methods: The studied group included 40 female patients complaining of pelvic organ prolapse and / or stress urinary incontinence or fecal incontinence. All patients were subjected to full history taking, clinical examination and Dynamic Magnetic resonance Imaging using 1.5 Tesla Philips MR Scanner.

Results: Good concordance was found between Dynamic MRI and clinical examination in all three compartments. The concordance was 82.5% in the anterior compartment, 80% in the posterior compartment, 85% in enteroceles and 65.0% in the middle compartment.

Conclusion: Dynamic MRI is a promising method that can be used as an imaging tool in the preoperative planning of pelvic organ prolapse.

INTRODUCTION

Weakening of the female pelvic floor is a prevalent and debilitating disorder. It results in abnormal descent of the urinary bladder, the uterovaginal vault, and the rectum, resulting in urinary incontinence, fecal incontinence, and pelvic organ prolapse⁽¹⁾. Eleven percent of women undergo surgery for pelvic organ prolapse and/or urinary incontinence during life time, and 30% of them undergo repeat surgery⁽²⁾.

Given the paucity of understanding of pelvic floor dysfunction pathophysiology and the high rate of recurrence and repeat surgery, imaging, like dynamic magnetic resonance (MR) plays a major role in its clinical management, especially for the preoperative assessment of patients with multi-compartment defects and failed surgical repairs⁽³⁾.

Pelvic MR imaging using the combination of motion-insensitive T2-weighted single-shot fast spin echo and high soft tissue resolution standard T2-weighted fast spin echo techniques has helped to identify soft tissue abnormalities that directly correlate with

the clinical and intraoperative findings related to pelvic floor prolapse. Pelvic MR imaging should also help to document and advance knowledge of surgical repair methodology⁽⁴⁾.

THE AIM OF THE WORK

The aim of the work is to highlight the role of MRI as a non invasive method in the assessment of pelvic floor dysfunction in females.

METHODS

This study was conducted over a period of 2 years and included 40 female patients, complaining of stress urinary incontinence, fecal incontinence or pelvic organ prolapse. Patients of interest were recruited from the obstetrics and gynecology department in Ain Shams University Maternity Hospital. We excluded patients with bad general condition, those who had a contraindication for MRI, and patients with detrusor instability.

After taking oral consent from all patients to undergo dynamic MRI of the pelvic floor, these patients were subjected to full clinical history, physical examination with

grading pelvic organ prolapse by the Baden-Walker Half Way Grading System as follows:

- Grade 0: No Prolapse
- Grade 1: Halfway to the hymen
- Grade 2: To hymen
- Grade 3: Halfway past hymen
- Grade 4: Maximum descent ⁽⁵⁾.

Urodynamic studies were done to exclude detrusor instability.

Patients were prepared by enemas the night before the MRI, fasting for 6 hours prior to the study and abstaining from micturition 1 hour before. Opacification of the rectum and vagina were done by sonographic gel and saline.

Dynamic MRI was done using 1.5 tesla superconductive G.E signa LX MRI scanner in Ain Shams University Hospital (ASUH). Sagittal, axial and coronal turbo spin echo sequences were done, followed by dynamic sequences in the sagittal plane using single shot fast spin echo sequences (SSFSE), during maximum straining.

• **Imaging Parameters:**

Sagittal T2W: TR 3000, TE 100, slice thickness 4 mm, gap 1.5mm, Field of view (FOV) 220.

Axial T2W: TR 3500, TE 80, slice thickness 2mm, gap 1mm, FOV 225.

Axial T1W: TR 420, TE 10, slice thickness 2mm, gap 1mm, FOV 255.

Coronal T2W: TR 3500, TE 80, slice thickness 2mm, gap 1mm, FOV 220.

Dynamic SSFSE: TR 3000, TE 160, FOV 290, number of dynamic scans 60, time 3minutes.

Image interpretation was done by a single radiologist, starting by drawing the pubococcygeal line (PCL), from the inferior border of symphysis pubis to the last coccygeal joint. Organ descent was assessed in the three compartments in relation to the PCL. Static images of the pelvis were assessed for muscle or ligament tears, fascial defects and any other associated findings.

The results of MRI were compared with the clinical examination of patients regarding the presence or absence of pelvic organ prolapse and its grading.

RESULTS

This study included 40 female patients. The mean age of included women was 44.88±11.81 years (range 20 - 65 years). The Median parity was 4. Of the included 40 women, 26 (65%) were premenopausal, while 14, (35%) were postmenopausal. (Figure 1).

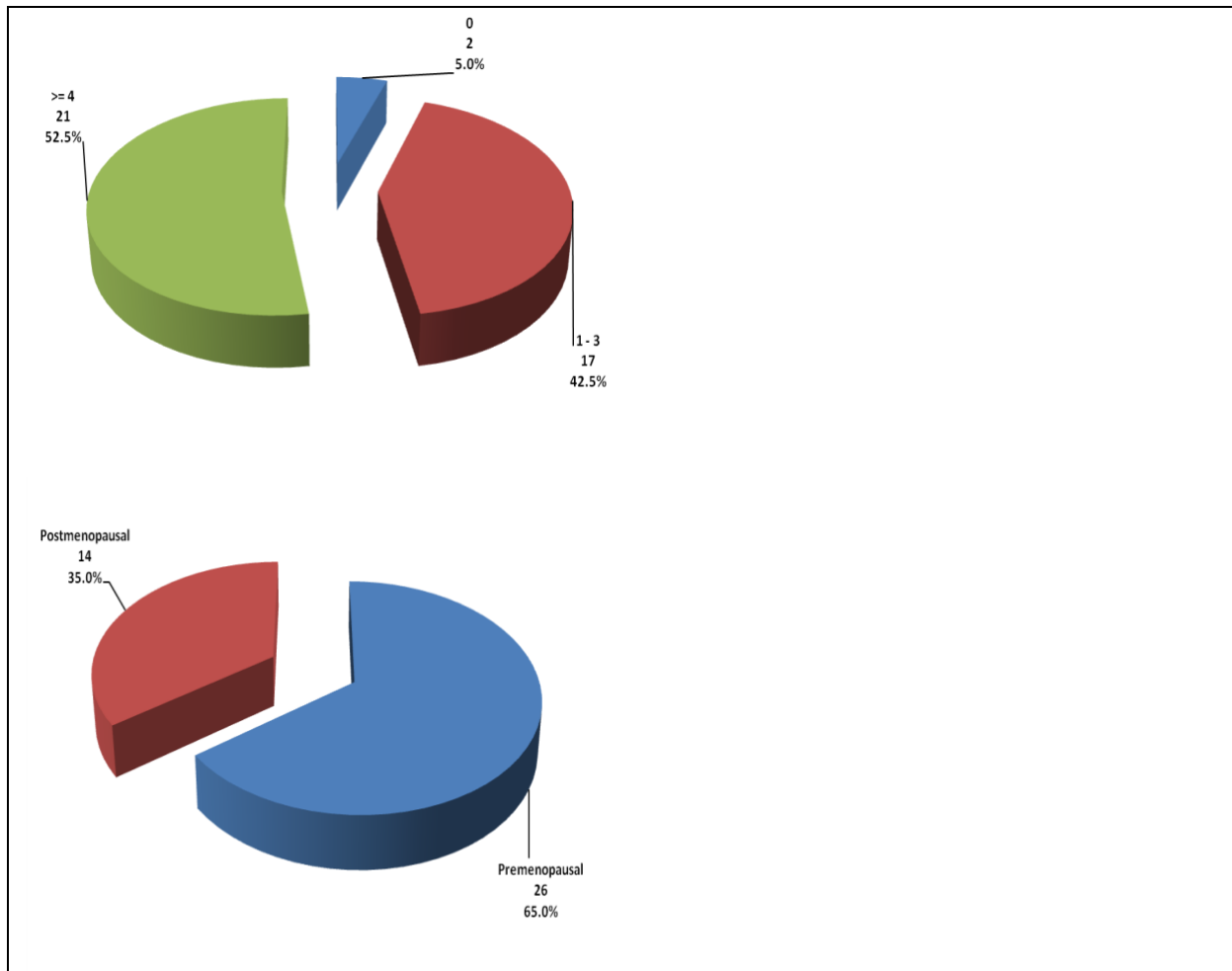


Figure (1): 1Pie-Chart showing Parity and Menopausal State in Included Women.

Of the included 40 women, 2 (5%) were nulliparae, 37 (92.5%) delivered vaginally, and 1 (2.5%) delivered by Cesarean section. Of the included 38 parous women, 23 (60.5%) had hospital delivery while 15 (39.5%) had home delivery. Prolonged labor was reported in 18 (55%) women, episiotomy in 29 (47.5%) women, perineal or vaginal tear in 19 (47.5%) women, large-birth-weight infant in 18 (45%) women, and operative vaginal delivery in 11 (27.5%) women. (Figure 1 and 2).

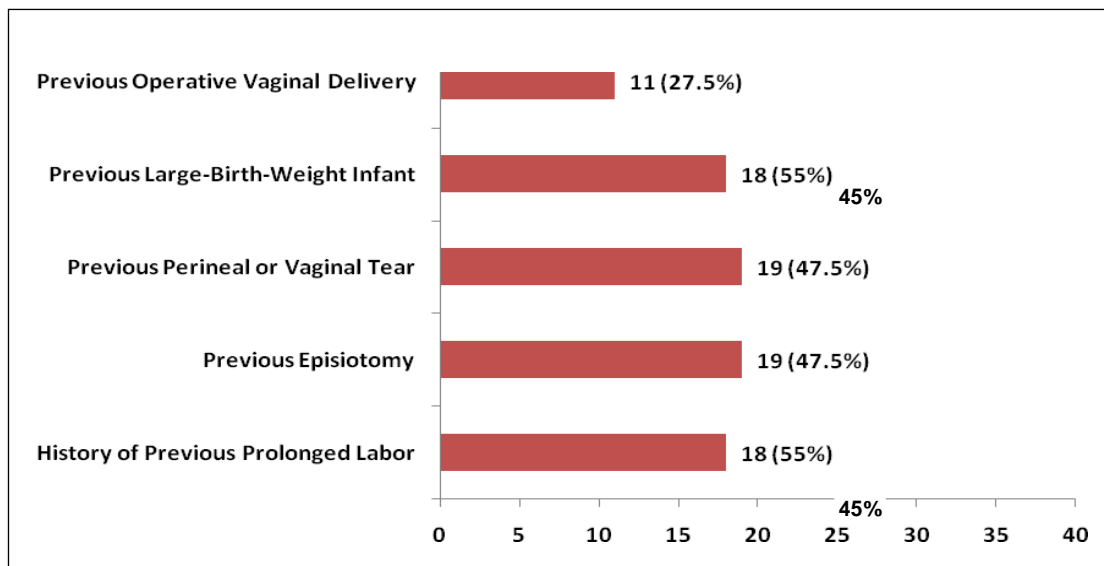


Figure (2): Bar-Chart showing Previous Delivery Events in Included Women.

Of the included 40 women, 6 (15%) had isolated genital prolapse, 15 (37.5%) had isolated SUI, 11 (27.5%) had combined prolapse and SUI, 2 (5%) had combined prolapse and anal incontinence, 1 (2.5%) had combined SUI and anal incontinence, while 5 (12.5%) had combined prolapse, SUI and anal incontinence. (Figure 3).

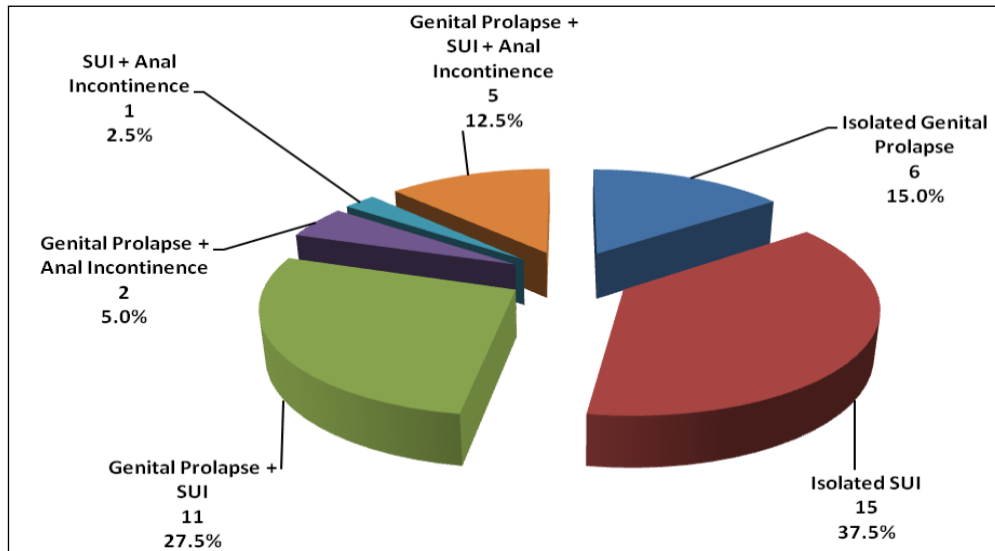


Figure (3): Pie-Chart showing Pelvic Floor Dysfunction in Included Women.

Of the included 40 women, 32 (80%) had cystocele by physical examination [20 (50%) were grade-1 by the Baden Walker Half Way Grading System, while 12 (30%) were grade-2]; 27 (67.5%) had rectocele [12 (30%) were grade-1, 14 (35%) were grade-2, 1 (2.5%) was grade-3]; 4 (10%) had uterine descent [1 (2.5%) was grade-1, 2(5%) were grade-2, 1 (2.5%) was grade-3]; and 1 (2.5%) had enterocele by physical examination.(Figure 4).

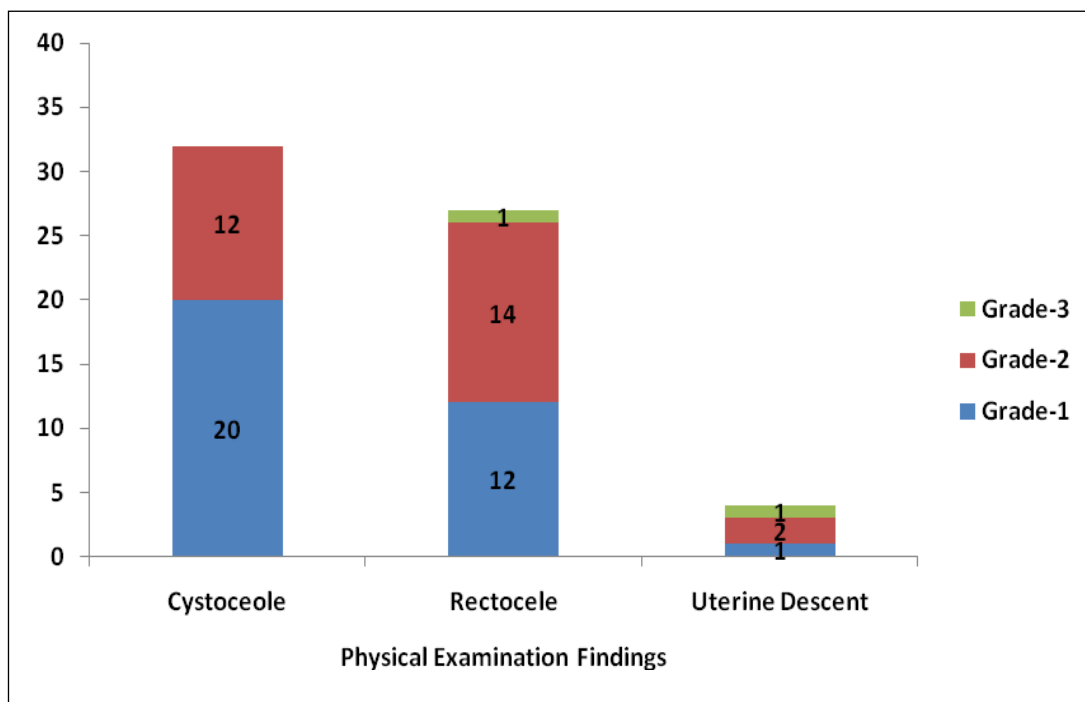


Figure (4): Bar-Chart showing Physical Examination Findings regarding Anterior, Posterior and Middle Compartments in Included Women.

Regarding the MRI findings, cystocele was detected in 33 (82.5%) women [18 (45%) were grade-1, 11 (27.5%) were grade-2, 4 (10%) were grade-3], rectocele in 29 (72.5%) women [7 (17.5%) were grade-1, 17 (42.5%) were grade-2, 5 (12.5%) were grade-3]; enterocele in 7 (17.5%) women.(Figure 5).

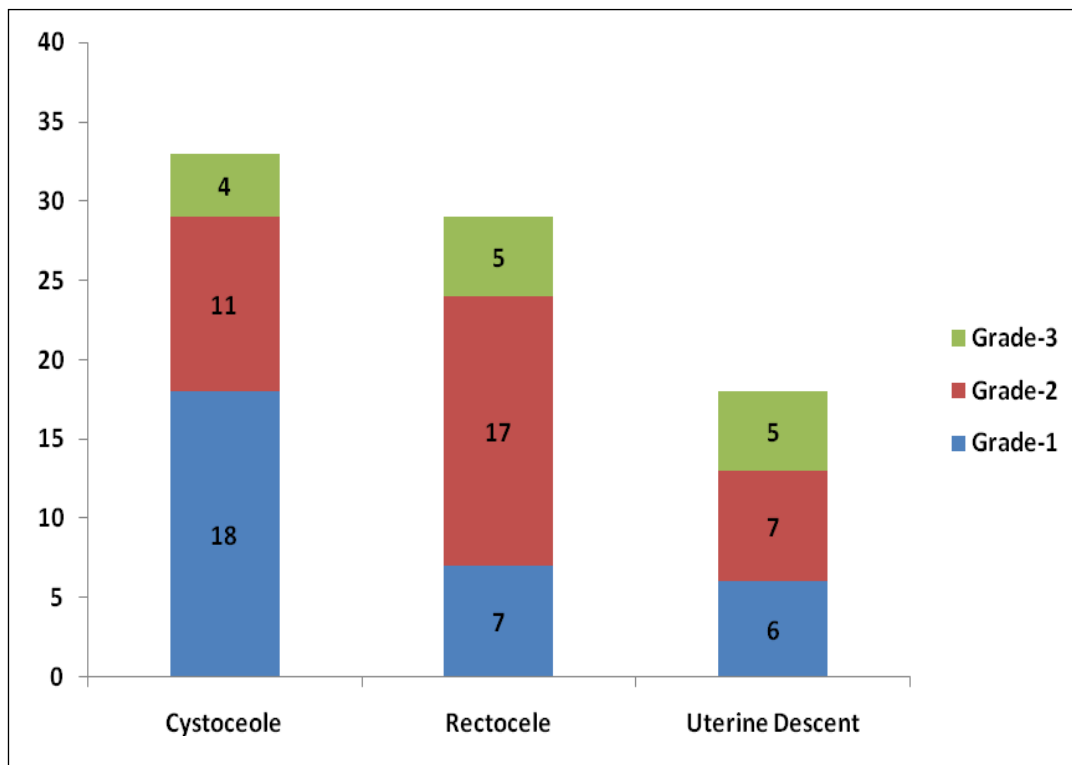


Figure (5): Bar-Chart showing MRI Findings regarding Anterior, Middle and Posterior Compartments in Included Women.

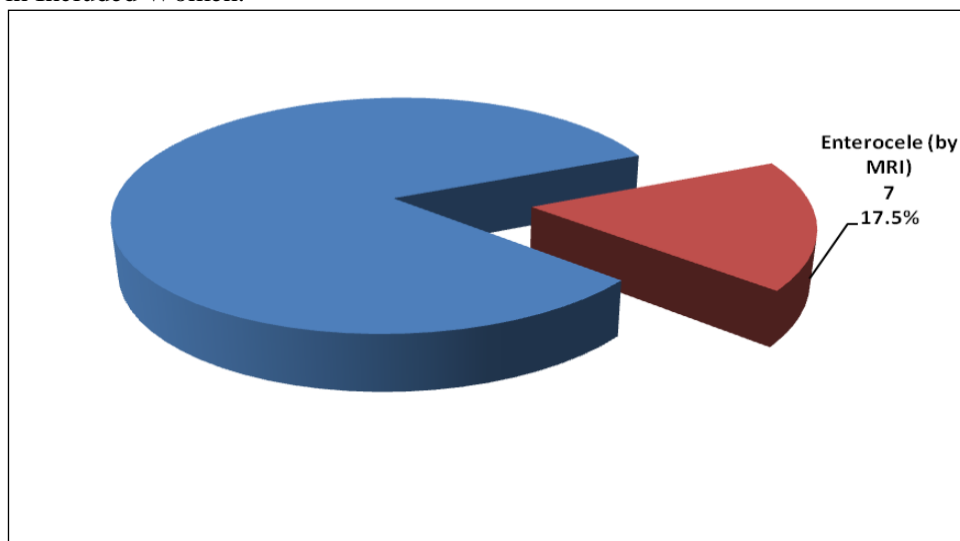


Figure (6): Pie-Chart showing MRI Findings regarding Enterocele in Included Women.

There was a significant agreement between MRI and physical examination findings regarding presence or absence of cystocele [$\kappa=0.462$, $p=0.007$] (Table-1). Of the included 40 women, 33 (82.5%) had similar findings (whether positive or negative for cystocele), while in 4 (10%) women MRI detected cystocele that was missed by physical examination, and in 3 (7.5%) MRI missed cystocele that was diagnosed by physical examination.

Table (1): Agreement between Physical Examination and MRI Findings Regarding Anterior Compartment in Included Women

MRI Findings of the Anterior Compartment	Physical Examination of Anterior Compartment		Percentage of Agreement	κ	P
	Cystocele	Normal			
Cystocele	29 (72.5%)	4 (10%)	82.5%	0.426	0.007 S
Normal	3 (7.5%)	4 (10%)			

Data presented as number (percentage)
 κ Kappa coefficient of agreement

MRI magnetic resonance imaging
 S significant

There was a significant agreement between MRI and physical examination findings regarding presence or absence of rectocele [$\kappa=0.525$, $p=0.001$] (Table-2). Of the included 40 women, 32 (80%) had similar findings (whether positive or negative for rectocele), while in 5 (12.5%) women MRI detected rectocele that was missed by physical examination, and in 3 (7.5%) MRI missed rectocele that was diagnosed by physical examination.

Table (2): Agreement between Physical Examination and MRI Findings Regarding Posterior Compartment in Included Women.

MRI Findings of the Posterior Compartment	Physical Examination of Posterior Compartment		Percentage of Agreement	κ	P
	Rectocele	Normal			
Rectocele	24 (60%)	5 (12.5%)	80%	0.525	0.001 S
Normal	3 (7.5%)	8 (20%)			

Data presented as number (percentage)

MRI magnetic resonance imaging

κ Kappa coefficient of agreement

S significant

There was a non-significant agreement between MRI and physical examination findings regarding presence or absence of uterine descent [$\kappa=0.139$, $p=0.120$] (table-3). Of the included 40 women, 26 (65%) had similar findings (whether positive or negative for uterine descent), while in 14 (35%) women MRI detected uterine descent that was missed by physical examination (Table-3).

Table (3): Agreement between Physical Examination of Middle Compartment Defect and MRI Findings of uterine prolapse in Included Women.

MRI Findings of the Middle Compartment	Physical Examination of Middle Compartment		Percentage of Agreement	κ	P
	Uterine Descent	Normal			
Uterine Descent	4 (10%)	14 (35%)	65%	0.139	0.120 NS
Normal	0 (0%)	22 (55%)			

Data presented as number (percentage)

MRI magnetic resonance imaging

κ Kappa coefficient of agreement

NS non significant

There was a significant agreement between MRI and physical examination findings regarding presence or absence of enterocele [$\kappa=0.216$, $p=0.028$] (Table-4). Of the included 40 women, 34 (85%) had similar findings (whether positive or negative for enterocele), while in 6 (15%) women MRI detected enterocele that was missed by physical examination.

Table (4): Agreement between Physical Examination and MRI Findings Regarding Enterocele in Included Women

MRI Findings of the Enterocele	Physical Examination of Enterocele		Percentage of Agreement	κ	P
	Present	Absent			
Present	1 (2.5%)	6 (15%)	85%	0.216	0.028 S
Absent	0 (0%)	33 (82.5%)			

Data presented as number (percentage)

MRI magnetic resonance imaging

κ Kappa coefficient of agreement

S significant

DISCUSSION

Pelvic floor dysfunction and prolapse affect 50 % of women past middle age. Failure to recognize the complex set of pelvic floor defects in individuals leads to most post-surgical failures ⁽⁶⁾.

Since the introduction of fast imaging sequences, magnetic resonance (MR) imaging has become a promising diagnostic tool in the assessment of the pelvic floor dysfunction. Many protocols concerning the MR imaging procedure and interpretation on pelvic organ prolapse (POP) have been introduced ⁽⁷⁾.

Of the included 40 women in our study, 9 (22.5%) underwent previous surgery for genital prolapse or stress urinary incontinence. This indicates that repeat surgeries among the sample were 22.5%. According to Broekhuis *et al.*, 30% of patients undergoing surgery for pelvic organ prolapse and / or urinary incontinence undergo repeat surgery ⁽²⁾.

The clinical staging of pelvic organ prolapse was done using the Baden Walker Half way grading system as opposed to pelvic organ prolapse quantification system (POP-Q) system used by Fauconnier *et al.*, Cortes *et al.*, Lienemann *et al.*, Hodroff *et al.*, Kaufman *et al.*, Singh *et al* and Tunn *et al.* The Modified Baden-Walker system was used by Gousse *et al.* and Goodrich *et al.* ⁽²⁾. The lack of experience with the POP-Q system led us to use the more widespread Half-way grading system in this study.

All patients included in this study were prepared by bladder, vaginal and rectal opacification which was also done in the

studies conducted by Cortes *et al.*, Hodroff *et al* and Tunn *et al.* ^{(8) (9) (10)}. No opacification was done by Agildere *et al.*, Fauconnier *et al.*, Goodrich *et al.*, and Gousse *et al.* In our opinion, vaginal and rectal Opacification provides better soft tissue contrast, to improve the accuracy of dynamic MR imaging ^{(11) (12) (5) (13)}.

In this study, dynamic MR imaging was performed in the supine position due to non-availability of open-magnet unit MRI which could assess patients in the sitting position. According to Bertschinger *et al.*, in a study comparing closed-magnet unit -versus open-magnet unit dynamic MR Imaging, the presence and grading of prolapse was concordant in the majority of patients. Therefore, our findings can be applied to open-magnet unit dynamic MR Imaging.

In this study, we selected the pubococcygeal line (PCL) as the reference line for the assessment of pelvic organ prolapse, because it was the most commonly used reference line on dynamic MR imaging ⁽²⁾.

Broekhuis *et al* also stated that it was the most reliable to use as it is drawn between two fixed bony points. The PCL was also used by Hodroff *et al.*, Agildere *et al.*, Lienemann *et al.*, Kaufman *et al* and Tunn *et al.* ⁽²⁾. According to Lienemann *et al.*, the PCL was defined as a horizontal line drawn from the inferior rim of pubic bone & the last visible coccygeal joint, which was the same definition applied in our study⁽¹⁴⁾.

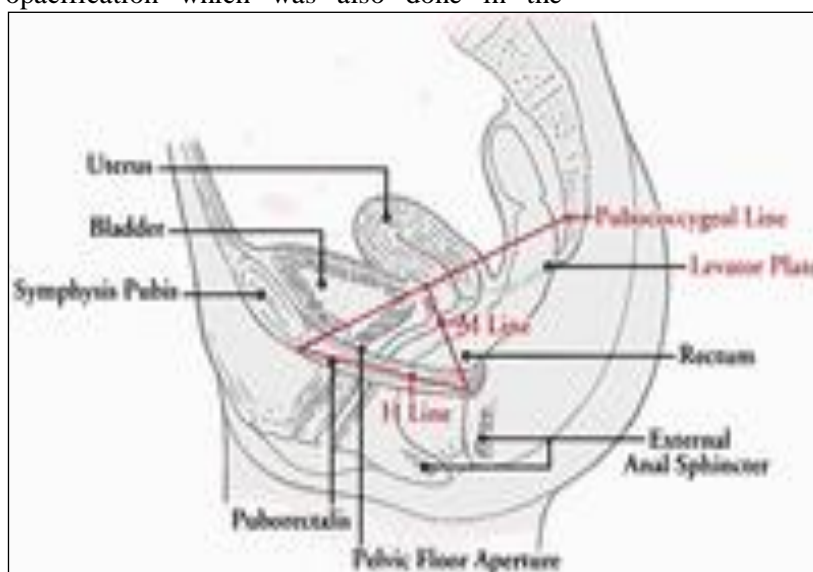

Figure (7): Drawing of the sagittal midline view of the female pelvis shows bony landmarks and the puborectal muscle, also called the levator sling. The pubococcygeal, H, and M lines and the levator plate are delineated in red ⁽¹⁵⁾.

As to the concordance of dynamic MR imaging findings with physical examination, we found that in the anterior compartment there was good agreement between MR Imaging findings and physical examination regarding the presence or absence of cystocele, with 33 (82.5%) of the patients having similar findings in both. As regards the middle compartment there was non significant agreement between MR Imaging findings and physical examination regarding the presence or absence of uterine descent, with 26 patients (65%) having similar findings. In the posterior compartment, there was good agreement regarding the presence or absence of rectocele in both MR Imaging and physical examination, with 32 (80%) of the patients having similar findings. In enterocele, there was good agreement between MR Imaging and physical examination with 34 (85%) of pts having similar findings yet in 6 (15%) of women MR Imaging detected enteroceles that were missed by physical examination.

According to Gupta et al., they found poor correlation between MRI and clinical examination in all three compartments. However in their study they used the HMO classification for pelvic organ prolapse on MR Imaging, grading the prolapse with reference to the hiatal "H" line. On comparing MRI findings with intraoperative examination, they found good agreement for enteroceles. Therefore they concluded that MRI would result into better enterocele detection & so better surgical outcome, as it has been reported in the literature that only half of enteroceles were detected by physical examination ⁽⁶⁾.

Gousse et al. Lienemann et al. and Hodroff et al. have concluded that pelvic organ prolapse was accurately staged on dynamic MR Imaging compared to physical examination in the anterior and middle compartment, but not for rectoceles (posterior compartment). Lienemann. et al. described the PCL as a useful reference line for descent in the anterior compartment only ⁽²⁾.

The results of this study were in agreement with Gousse- et al. and Lienemann et al. only in the anterior and middle compartments, while they disagreed in posterior compartment. This could be

attributed to the difference in the clinical staging used in our study (the Half-way grading system) as opposed to the Modified Baden Walker system used by Gousse et al. and the POP-Q system used by Lienemann et al. Both authors used the pubococcygeal line as the reference line in MRI. Gupta et al. found that MR Imaging correlated poorly with clinical examination in all the three compartments, which was also not matching the results of this study which found disagreement only in the middle compartment.

This could be due to the use of a different MRI staging system which was the HMO grading system. They also used the POP-Q system for clinical grading of prolapse. Therefore, the diversity of the clinical systems as well as the MRI reference lines used could be responsible for the different results.

The main weakness in this study was the lack of correlation with a 'gold standard' which is the intra operative examination which was included in the study done by Gupta et al. This did not allow the assessment of the sensitivity and diagnostic accuracy of MRI.

Also the straining efforts of the patients could be suboptimal in some cases due to lack of direct communication between the radiologist and the patient. This was partly solved by coaching the patients on Valsalva maneuver prior to the examination and noting for the indentation caused by the small bowel loops on the urinary bladder dome, as well as the inward movement of the anterior abdominal wall muscles. If this could not be seen, the dynamic sequences were repeated till maximum straining efforts were obtained.

In summary, our study revealed that the overall correlation between dynamic MR Imaging staging of pelvic organ prolapse and physical examination was generally good in this study, yet with non significant agreement in the middle compartment.

However, the diversity of reference lines used in MRI as well as the different clinical staging systems are possibly responsible for the diversity of results in this aspect in the current literature.

Case (1): 45 year old patient, Para 5+2 complaining of stress urinary incontinence and painful perineal swelling. Past history of classical repair.

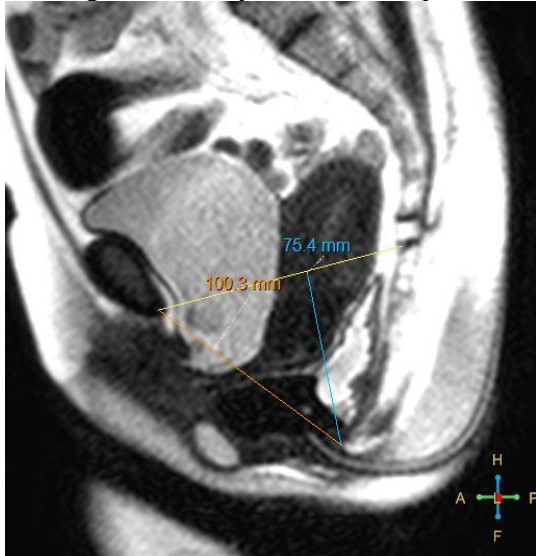


Figure (8): Midsagittal Dynamic image showing H (hiatal) line 10 cm and M (Muscular pelvic floor descent) line 7.5 cm, denoting grade III hiatal enlargement and grade III muscular pelvic floor descent.

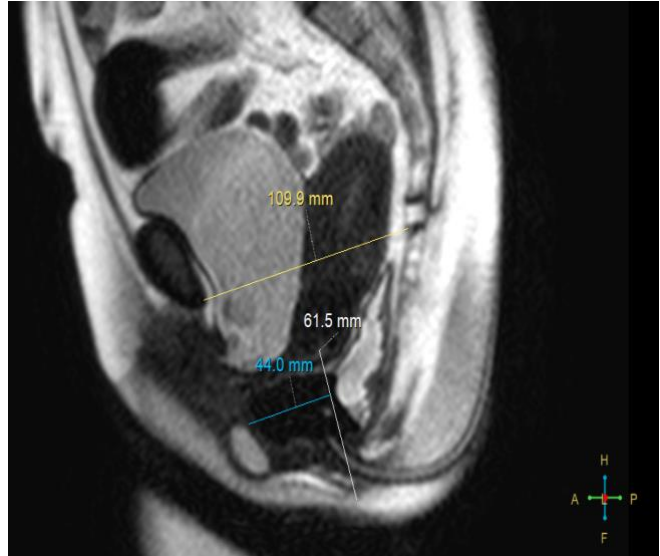


Figure (9): Midsagittal Dynamic image showing moderate anterior rectocele, mild cystocele and mild uterine prolapse. Note Bartholin gland cyst.

Case (2): 36 year old patient, Para 3 complaining of fecal incontinence and a sensation of rectal swelling.

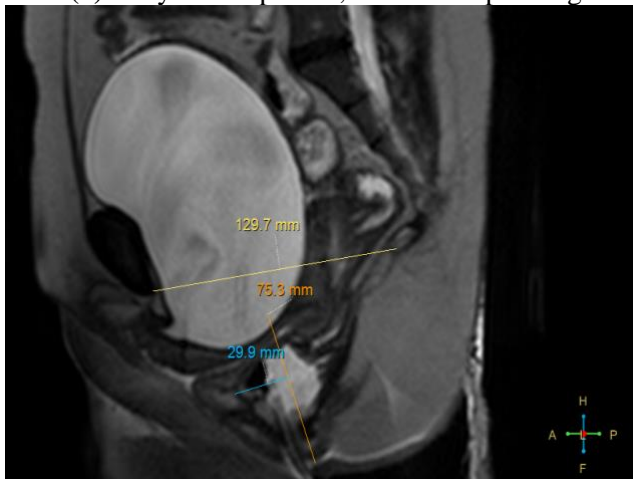


Figure (10): Midsagittal Dynamic image showing mild Cystocele, urethral hypermobility with rotation to the horizontal plane. Mild anterior rectocele with intrarectal intussusception.

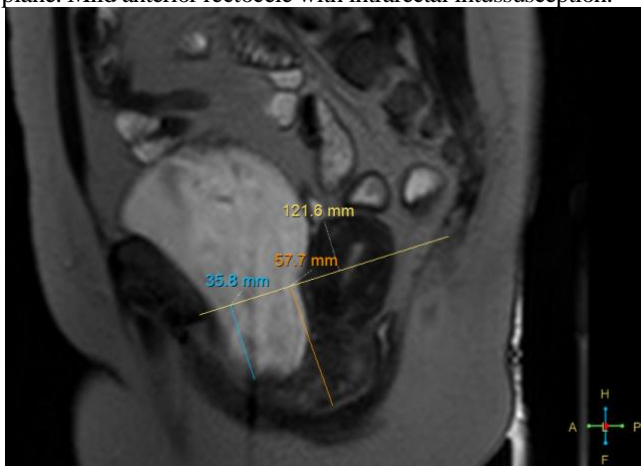


Figure (11): Parasagittal image showing moderate 5.7 cm uterine prolapse, with more evident moderate 3.5 cm cystocele.

CONCLUSION

Further research is needed on the different reference lines, as well as comparison of the results of dynamic MRI with the gold standard which is the intraoperative examination. This would allow the assessment of the diagnostic accuracy of dynamic MRI in pelvic organ prolapse. It is also advisable that the clinicians use a standard scoring system for pelvic organ prolapse like the POP - Q system to standardize the clinical assessment of these patients. Moreover, future studies are needed to correlate the static and dynamic MRI findings to better define the cause of the patients defects and consequently perform site specific repair in future surgeries to avoid recurrence of symptoms.

REFERENCES

1. Law YM and Fielding JR. MRI of Pelvic Floor Dysfunction: Review. *AJR*. 2008; 191:45-53
2. Broekhuis SR, Futterer JJ, Barentsz JO, Vierhout ME, Kluivers KB. A systematic review of clinical studies on dynamic magnetic resonance imaging of pelvic organ prolapse: the use of reference lines and anatomical landmarks. *Int Urogynecol J Pelvic Floor Dysfunct*.2009; 20(6):721-729
3. Boyadzhyan L, MD Steven S. Raman, MD Shlomo Raz, MD. Role of Static and Dynamic MR Imaging in Surgical Pelvic Floor Dysfunction. *Radiographics*.2008; 28:949-967.
4. Martin DR, Salman K, Wilmot CC, Galloway NT. MR imaging evaluation of the pelvic floor for the assessment of vaginal prolapse and urinary incontinence. *Magn Reson Imaging Clin N Am*. 2006; 14(4):523-35
5. Goodrich MA, Webb MJ, King BF, Bampton AE, Campeau NG, Riederer SJ. Magnetic resonance imaging of pelvic floor relaxation: dynamic analysis and evaluation of patients before and after surgical repair. *Obstet Gynecol* 1993; 82:883-891
6. Gupta S, Sharma J.B, Hari S, Kumar S, Roy K.K, Singh N. Study of dynamic magnetic resonance imaging in diagnosis of pelvic organ prolapse. *Arch Gynecol Obstet* 2012; 286:953-958
7. Mariëlle ME, Lakeman, Zijta FM, Peringa J, Nederveen AJ, Stoker J, Roovers JPWR. Dynamic magnetic resonance imaging to quantify pelvic organ prolapse: reliability of assessment and correlation with clinical findings and pelvic floor symptoms. *Int Urogynecol J* 2012; 23:1547-1554
8. Cortes E, Reid WM, Singh K, Berger L. Clinical examination and dynamic magnetic resonance imaging in vaginal vault prolapse. *Obstet Gynecol* 2004; 103:41-46
9. Hodroff MA, Stolpen AH, Denson MA, Bolinger L, Kreder KJ. Dynamic magnetic resonance imaging of the female pelvis: the relationship with the pelvic organ prolapse quantification staging system. *J Urol* 2002; 167:1353-1355
10. Tunn R, DeLancey JO, Quint EE. Visibility of pelvic organ support system structures in magnetic resonance images without an endovaginal coil. *Am J Obstet Gynecol* 2001; 184:1156-1163.
11. Agildere AM, Tarhan NC, Ergeneli MH, Yologlu Z, Kurt A, Akgun S, Kayahan EM. MR rectography evaluation of rectoceles with oral gadopentetate dimeglumine and polyethylene glycol solution. *Abdom Imaging* 2003; 28:28-35
12. Fauconnier A, Zareski E, Abichedid J, Bader G, Falissard B, Fritel X. Dynamic magnetic resonance imaging for grading pelvic organ prolapse according to the International Continence Society classification: which line should be used? *Neurourol Urodyn* 2008; 27(3):191-197
13. Gousse AE, Barbaric ZL, Safir MH, Madjar S, Marumoto AK, Raz S. Dynamic half Fourier acquisition, single shot turbo spin-echo magnetic resonance imaging for evaluating the female pelvis. *J Urol* 2000; 164:1606-1613
14. Lienemann A, Sprenger D, Janssen U, Grosch E, Pellengahr C, Anthuber C. Assessment of pelvic organ descent by use of functional cine-MRI: which reference line should be used? *Neurourol Urodyn* 2004; 23:33-37
15. Fielding J. Practical MR imaging of female pelvic floor weakness. *Radiographics* 2002; 22(2):295-304.