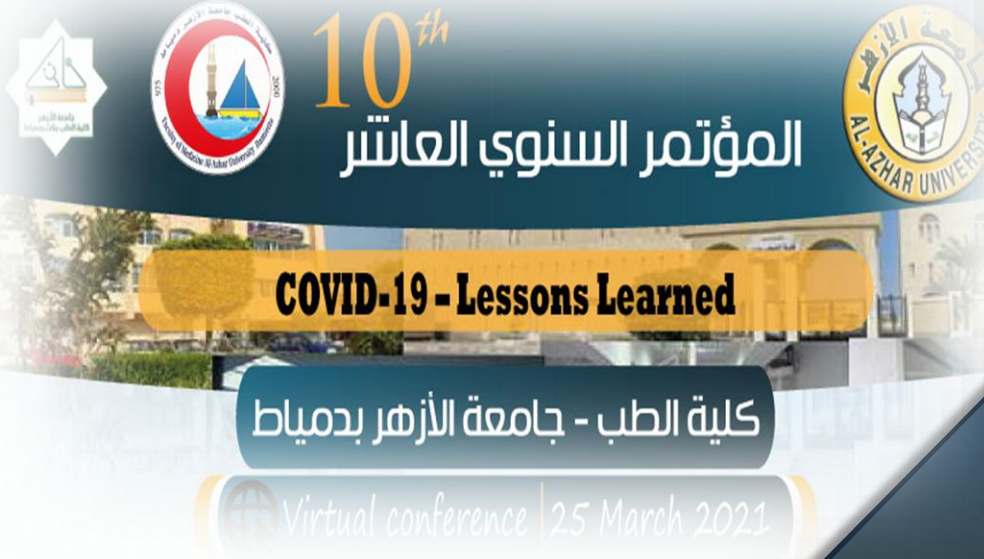

# IJMA



## INTERNATIONAL JOURNAL OF MEDICAL ARTS

*Volume 3, Issue 2 [Spring (April-June) 2021]*



<http://ijma.journals.ekb.eg/>

Print ISSN: 2636-4174

Online ISSN: 2682-3780

## About IJMA [last updated March, 1<sup>st</sup>, 2021]

- ✓ International Journal of Medical Arts is the Official Journal of the Damietta Faculty of Medicine, Al-Azhar University, Egypt
- ✓ It is an International, Open Access, Double-blind, Peer-reviewed Journal
- ✓ Published four times a year
- ✓ The First Issue was published in July 2019
- ✓ Published under the following license: Creative Commons Attribution-ShareAlike 4.0 International Public License (CC BY-SA 4.0). It had updated from the Creative Commons license [CC BY] in volume 2, Issue 4, October 2020 About IJMA
- ✓ The Egyptian Knowledge Bank hosts the web site of IJMA
- ✓ The Egyptian Knowledge Bank supports IJMA
- ✓ IJMA follows the regulations of the International Committee of Medical Journal Editors
- ✓ IJMA is indexed in the "Directory of Open Access Journals" [Indexed on 15 January 2021].
- ✓ IJMA is a member of the International Society of Managing and Technical Editors
- ✓ Listed in "Index Copernicus", "Publons", "Academic resource index [ResearchBib]", "Electronics journal library", "Eurasian Scientific Journal Index", and "Citefactor"
- ✓ IJMA introduced to the search engine [BASE] through DOAJ

Click image to reach the page



Egyptian Knowledge Bank

DOAJ



INDEX COPERNICUS  
INTERNATIONAL



ESJI Eurasian Scientific Journal Index  
www.ESJIndex.org





Available online at Journal Website  
<https://ijma.journals.ekb.eg/>  
Main subject [Plastic Surgery]\*



## Original article

# Early Versus Late Alveolar Cleft Repair Using Cancellous Iliac Bone Grafts in A developing Country

Ahmed Abd Alfatah Abd Algalil Makharita<sup>[1]</sup>; Ahmed Salama Sayouh<sup>[2]</sup>; Mahmoud Ahmed Amin<sup>[3]</sup>

Department of Plastic Surgery, Nasser Institute Hospital, Ministry of Health, Egypt<sup>[1]</sup>

Department of Surgery, Damietta Faculty of Medicine, Al-Azhar University, Egypt<sup>[2]</sup>

Department of Plastic Surgery, Damietta Faculty of Medicine, Al-Azhar University, Egypt<sup>[2]</sup>

**Corresponding author:** Ahmed Abd Alfatah Abd Algalil Makharita.

Email: [makharitaplastic@domazhermedicine.edu.eg](mailto:makharitaplastic@domazhermedicine.edu.eg)

Submission date: October 25, 2020; Revision date: January 17, 2021; Acceptance date: January 18, 2021

DOI: [10.21608/ijma.2021.53013.1216](https://doi.org/10.21608/ijma.2021.53013.1216)



## ABSTRACT

**Background:** Orofacial clefts are common congenital malformations, with alveolar cleft as the most common [75%] of all anomalies. Many treatment modalities are available. However, our clinical experience with bone graft modality is not well addressed.

**The aim of the work:** To evaluate the effectiveness of early [2 to 12 years; before complete eruption of the cleft canine] versus late [> 12 years; after complete eruption of the cleft canine] cancellous anterior iliac bone grafting for alveolar cleft reconstruction.

**Patients and Methods:** Twenty-three patients with alveolar clefts who were admitted for alveolar cleft reconstruction surgery were included. They were categorized into early and late secondary grafting groups. All patients inquired about their history. Submitted to full clinical examination, laboratory and radiological examinations. The imaging studies include two-dimensional orthopantomogram for all patients, while 3-D fascial computed tomography and cone-beam computed tomography were done for selected patients. Both intraoperative and postoperative data were collected, any complications were registered and patients followed up regularly up to 6 months.

**Results:** Both groups were comparable as regarding patient characteristics except younger age in early group, and there was a statistically significant difference between early and late groups regarding cleft side and cleft permanent canine full eruption. Males represented 69.9%. The cleft was on the left side in 56.4%. Seven patients [30.4%] had maternal risk factor [five in early and two in late group]. Blood loss was less than 80 ml in all patients in both groups. All oronasal fistulas were sealed off successfully in all patients [100%] and all had normal healthy gingival contour with vital teeth adjacent to the cleft. All showed evidence of good bone filling in the alveolar defect after 6 months postoperatively. Only one patient developed hypertrophic scars at each group.

**Conclusion:** Alveolar cleft reconstruction is preferred to perform autologous cancellous bone grafting harvested from the iliac crest bone to repair the cleft with excellent outcome on short-term follow-up.

**Keywords:** Chronic Rhinosinusitis; Salivary; Nasal; Pepsin; Gastroesophageal Reflux Disease.

This is an open-access article registered under the Creative Commons, ShareAlike 4.0 International license [CC BY-SA 4.0] [<https://creativecommons.org/licenses/by-sa/4.0/legalcode>].

**Citation:** Makharita AAA, Ibrahim AA, Sayouh AS, Amin MA. Early Versus Late Alveolar Cleft Repair Using Cancellous Iliac Bone Grafts in A developing country. IJMA 2021; 3[2]: 1412-1422. [DOI: [10.21608/ijma.2021.53013.1216](https://doi.org/10.21608/ijma.2021.53013.1216)].

\* Main subject and any subcategories have been classified according to the research topic.

## INTRODUCTION

Orofacial clefts are considered the most prevalent congenital anomalies in the craniofacial region as well as the second most common congenital anomaly following clubfoot [1].

Among these, orofacial cleft disorders; the most frequent defects are cleft lip and palate, while alveolar cleft represents 75% of all cleft lip and palate anomalies [2]. The worldwide reported prevalence of alveolar cleft in Europe is 1/700 live birth, with demographic ethnic variability from 1/300 in Asians to 1/2500 among African descendants. It is also more prevalent in males than females and more frequent on the left side more than the right side [3]. In fact, alveolar cleft is considered one of the most effective congenital causes of alveolar bone deficiencies that also can be caused by trauma, periodontal inflammation, abscesses, iatrogenic surgical excision of benign lesions, malignant tumors and advanced age-related atrophic changes [4].

In most of the clefts of the primary palate, the alveolar part of the cleft is located between the lateral incisor, if present, and the canine with probable 35% to 60% chance of congenital absence of the cleft lateral incisor [5]. For instance, etiology of alveolar cleft is Multifactorial. It may be due to genetic factors, environmental factors or teratogens, which may induce incomplete fusion of both the maxillary and the intermaxillary prominences, producing cleft alveolus craniofacial anomaly [6].

In a historical perspective, the multidisciplinary treatment of alveolar cleft has changed over the past century. In 1901, von Eiselsberg first reported reconstruction trials. Later on, Skoog in 1965 developed the primary gingivoperiosteoplasty, which had a positive impact by that time. However, in 1972 boyne and sands emphasized the importance of secondary bone grafting followed by many authors who modified these autogenic techniques until Nique et al. actually pioneered allogenic alveolar bone grafting in 1987 [7].

Besides the psychological and social burden on alveolar cleft patients, these patients commonly complain of oronasal fistulae with regurgitation of food and drink particles into the nasal cavity. Secondary alveolar bone grafting enhances the closure of these

oronasal fistulae, increasing oral hygiene and supporting the nasal alar base [8].

The definitive timing of alveolar cleft repair is controversial as it can be applied primarily during infancy, or secondarily later on [9]. However, the alveolar cleft is usually treated between 7 and 11 years of age and is often connected to the development of the maxillary canine root [10]. Bone grafting materials are variable including autografts, isografts, allografts, alloplastic grafts, xenografts along with bone graft substitute. The most commonly used bone grafting material is autogenic cortical, cancellous or cortico-cancellous bone grafts [11]. Iliac crest is the most common donor source for alveolar cleft autogenous grafting because it is easy to harvest, provides a large amount of cancellous bone and more advantageous than other sources of autologous bone grafts like the cranium, mandible, ribs and tibia [12].

## THE AIM OF THE WORK

The aim of the current work was to evaluate the effectiveness of early versus late cancellous anterior iliac bone grafting for alveolar cleft reconstruction in patients with cleft alveolus anomaly as regard to postoperative outcomes and complications.

## PATIENTS AND METHODS

The study included 28 patients [a convenient sample] with alveolar clefts who were admitted to Plastic and Reconstructive Surgery Department; Al-Azhar University Hospital [New Damietta], Damietta Health Insurance and Damietta Military Hospital for alveolar cleft reconstruction surgery using cancellous bone grafts from the anterior iliac crest during the period between July 2018 and August 2019. Five patients were excluded. Thus, the final cases were 23 patients. The excluded patients were 4 patients under 2 years, and one patient with untreated cleft lip and palate

The inclusion criteria: patients older than two years, uni- or bi-lateral treated cleft lip, associated treated cleft palate, and complicated cleft alveolus [oro-nasal fistula]. On the other side, the exclusion criteria included associated high-risk comorbidities, the presence of other craniofacial abnormalities, patients < two years of age, edentulous patients, and associated untreated cleft lip or palate.

Ethical considerations: the study protocol was



approved by the institutional review board [for its ethical and research design aspects] of the Damietta Faculty of Medicine [Al-Azhar University]. In addition, all patients and/or their legal guardians were informed about the study and provided informed consent to share in the study, which completed according to ethical codes.

Eligible patients were categorized into two groups according to the timing of the surgery in relation to dental and chronological ages as the following: The early secondary grafting group: from 2 to 12 years [before complete eruption of the cleft canine], and Late secondary grafting group: more than 12 years [after complete eruption of the cleft canine].

On admission, all patients inquired about their detailed history [patient's demographic data, maternal history with emphasis on risk factors related to pregnancy, chronic medical diseases, affected side, associated cleft lip or palate and their repair and food particle or fluid regurgitation into nasal floor]. Subsequently, full clinical examination [general and local] was performed. The local examination confirmed the affected side, the presence of oronasal fistula, any dentation abnormalities, gingival contour, facial growth malformations, alar base deformities and donor site condition. Then, imaging studies were done and included two-dimensional orthopantomogram [panoramic X-ray] for all patients, while 3-D fascial computed tomography and cone-beam computed tomography were confined for selected patients. Finally, a preoperative lab workup had been performed and included complete blood count [CBC], fasting blood sugar [FBS], liver function tests [ALT, AST and bilirubin], renal function tests [serum urea and creatinine] and coagulation profile [PT, aPTT and INR].

**Surgical technique:** All patients were treated by secondary cancellous bone grafting taken from the iliac crest. Orthodontics had been taken off before surgery, and in bilateral cases, each single side was treated separately. General anesthesia was the rule for all patients, with endotracheal armored tube and oral packing. All patients received prophylactic antibiotic [cefotaxime] according to calculated doses for their

body weight. The patient operated while he/she in a supine position with a folded bath towel underneath the donor hip [Figures 1 and 2]. The patient donor site was painted with povidone-iodine before anything and draped, then the face was painted with povidone-iodine. The oral cavity was prepared with diluted povidone-iodine. Towels and drapes were used to expose only the surgical area. Gingival margin incisions were done on the cleft side, and wide mucoperiosteal flap including at least one tooth distal and mesial to the cleft was made, exposing the bony cleft. The lingual aspect mucoperosteum was reflected to simultaneously close the often slit-like opening present. In this manner, the maximal lingual soft tissue is preserved for closure [Figure 3]. Once the buccal and lingual flaps have been raised, access was readily obtained to the nasal mucosa of the pyramidal cleft, which was then undermined and turned inward for a tension-free repair of the oronasal fistula [Figure 4]. The alveolar defect was measured to assess how much of cancellous bone was needed [Figure 5] with refreshment of the bony edges [figure 6]. The rotational flap from the buccal cheek was then elevated to cover the labial defect [Figure 7]. Then, all the surgical set was changed to take the cancellous bone graft from the donor hip. Incision of 4 to 8 cm was made through the skin and subcutaneous layers depending on how much bone was needed. The incision was made one inch below the crest to lessen postoperative pain and limping, and to avoid the incidence of hypertrophic and keloid scar formation [Figure 8]. The cartilaginous or bony cap of the iliac crest was reflected superiorly based on the external oblique muscle to maintain its blood supply [Figure 9]. Cancellous bone grafts were harvested with curette and osteotomies then are preserved in blood-soaked gauze [Figures 10,11]. After repositioning the cartilaginous cap with [0 vicryl] sutures with good hemostasis, the wound was closed in layers after placement of vacuum assisted closed suction drains [Figure 12]. The cancellous bone grafts were packed in between the refreshed alveolar segments to reconstruct the alveolar cleft [Figure 13]. Finally, a watertight closure was achieved using 4/0 vicryl sutures [Figure 14].

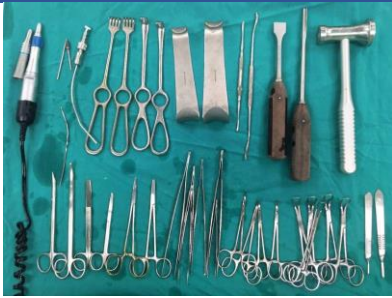

Figure [1]: Surgical set used in the procedure showed from the upper left clock wisely: Round burr set, frazier suction tube, cheek retractors, periosteal elevators, osteotome, gauche, mallet, scalpels, backhaus towel clips, Hemostats, pickups, needle holders and scissors

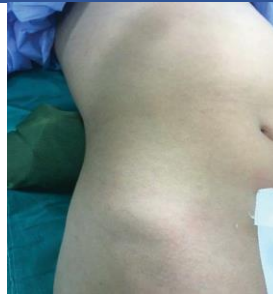

Figure [2]: Showing intraoperative folded bath towel underneath the donor hip

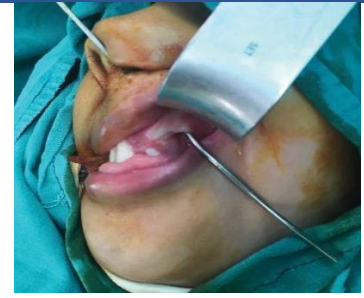

Figure [3]: Showing propped oronasal fistula

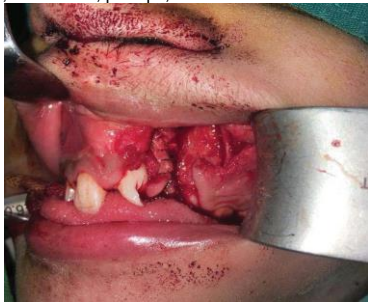

Figure [4]: Intraoperative repair of the lingual surface of the oronasal fistula

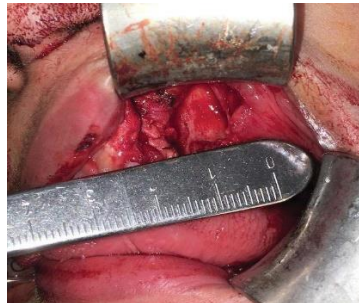

Figure [5]: Measuring the alveolar bony defect

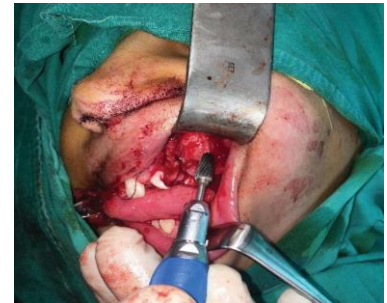

Figure [6]: Intraoperative refreshment of alveolar defect bony edges

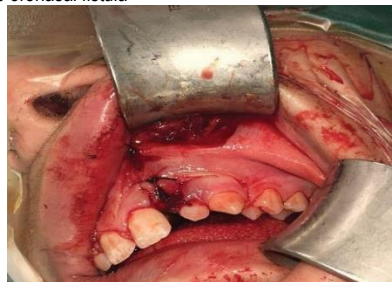

Figure [7]: Elevating rotational flap from the buccal cheek

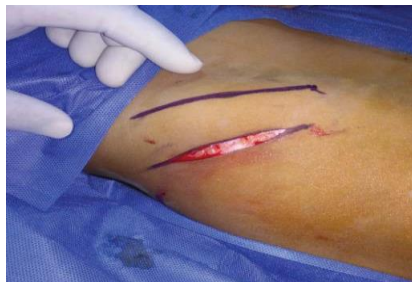

Figure [8]: Marking of donor anterior iliac crest incision

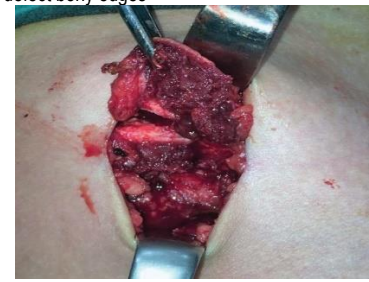

Figure [9]: Preserving the iliac crest cartilaginous cap

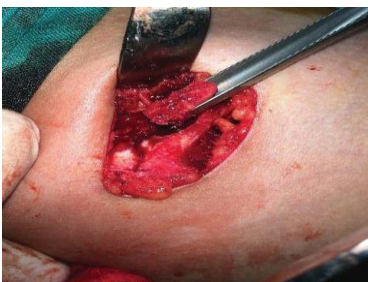

Figure [10]: Collecting cancellous bone grafts

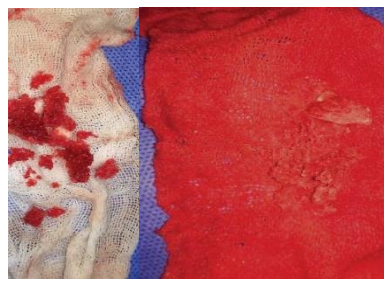


Figure [11]: Showing cancellous bone grafts in a blood soaked gauze

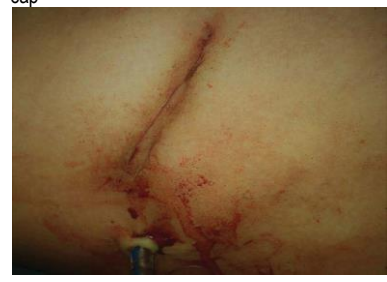

Figure [12]: layered closure of donor site skin

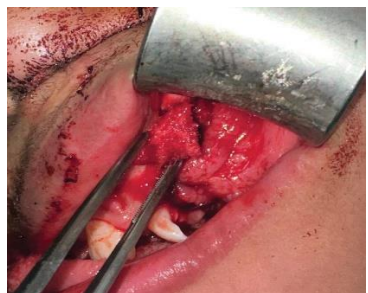


Figure [13]: Cancellous bone grafts packed inlay into the alveolar defect

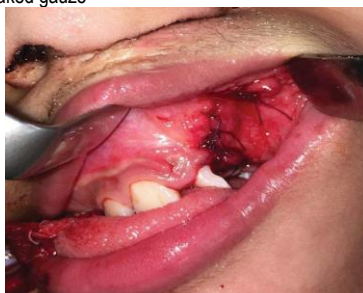

Figure [14]: Closure of labial surface of the oronasal fistula



Postoperative care: Vital signs were recorded routinely. All patients had injectable antibiotics [cefotaxime] and [metronidazole] for 5 days. Postoperative recovery was reported for all patients, and they have been instructed to get the early ambulation.

Oral hygiene was maintained by gentle saline and betadine irrigation. Over the next weeks to months, grafted bone integration into the patient's own bone tissue was observed.

The normal permanent teeth eruption through the graft in the early group was observed too. Frequently, after all the permanent teeth have come out, patients needed braces to straighten them.

Patients were admitted for 48 hours postoperative, and then discharged with subsequent regular visits [weekly in first postoperative months, then every two weeks in the second month, then monthly till 6-12 months] for follow-up.

All were assessed on the clinical and radiological basis.

The clinical assessment included assessment of the oronasal fistulas, continuity of the dental arch, the depressed alar base, and questioning the patient about any sign of regurgitation of food particles or liquids. In addition, all patients were checked up for gingival contour, and for the teeth adjacent to the cleft.

The complications' assessment included recipient site complications such as infection, flap necrosis, residual oro-nasal communication, extrusion of graft material, and dehiscence of flap margins; the donor site complications such as sensory disturbance in the antero-lateral thigh, chronic pain, hematoma, wound infection or abnormal posture.

The radiological assessment: Postoperative Panorama X-rays were arranged to all patients after 6 months to evaluate the outcome of the procedure, assessment of the periodontal pocket changes in the structural pattern of the bone graft with time, and eruption status of the lateral incisor or canine adjacent to the cleft.

Statistical Analysis: The collected data were coded, processed and analyzed using the SPSS [Statistical Package for Social Sciences] version 19 for Windows® [IBM®SPSS® Inc, Chicago, IL, USA]. Qualitative data

were presented as number and percentage. Comparison between groups was done using Chi-Square test. Quantitative data were tested for normality by Kolmogorov-Smirnov test. Normally distributed data were presented as mean  $\pm$  SD. Student t-test was used to compare between the two groups.  $P < 0.05$  was considered statistically significant.

## RESULTS

In this study, 28 patients were identified with alveolar cleft, five of them were excluded amounting to 23 patients who met the inclusion criteria.

The excluded patients were 4 patients under 2 years, and 1 patient with untreated cleft lip and palate. Their age ranged between 4 and 18 years, and male patients represented 69.9% compared to 30.4% for females. The cleft was on the right among 6 patients [26.1%], on the left [13 patients, 56.4%] and bilateral among 4 patients [17.4%].

Permanent lateral incision eruption was reported in 11 patients [47.8%]. All patients in late group had cleft permanent canine full eruptions, compared to none in the early group. Seven patients [30.4%] had maternal risk factor [five in the early and two in the late group]. Only one patient [4.3%] was known to be diabetic [come from the early group]. Preoperative orthodontics were discovered in two patients [8.7] [Both were in the late group].

Patients in the early group were significantly younger [ $7.46 \pm 1.90$  years] vs  $14.60 \pm 1.47$  in late group], and there was a statistically significant difference between the early and late groups regarding cleft side and cleft permanent canine full eruption [Table 1].

The operative time in the first [early] group ranged between 90 and 148 minutes and the mean was [ $108.08 \pm 17.45$  minutes] and in late group, it ranged between 94 and 150 minutes [Mean  $117.20 \pm 18.52$  minutes] with no significant difference between the two groups. In addition, there was no significant difference between both groups regarding the duration of hospital stay [ $2.38 \pm 0.65$  and  $2.30 \pm 0.67$  days in the early and late groups respectively].

Blood loss was less than 80 ml in all patients in both groups and no intraoperative mortality had been reported.

All oronasal fistulas were sealed off successfully in both groups [100%] supporting the continuity of the dental arch, lifting depressed alar base with no regurgitation of food particles or liquids. All patients had normal healthy gingival contour with vital teeth adjacent to the cleft. Wound healed satisfactorily in all patients. The time of complete healing ranged from 10 to 14 days.

All panoramic X-rays in both the early and late groups showed evidence of good bone filling in the alveolar defect after 6 months postoperatively, which predict later eruption of the canine in the alveolar repaired defect in the [first] early group.

Only one patient developed a hypertrophic scar at the donor site in the first [early] group [7.7%] and another only one patient had a hypertrophic scar in the [late] group [10%], which improved with the time. No infection or hematoma was reported [Table 2].

Although, three patients in the early group [23.1%] and two patients in the late group [20%] walked with a limb with delayed ambulation for 3 days, other 18 patients of the two groups [78.3%] early ambulated 6 hours postoperatively with almost no pain. This shows no significance of the two groups as regard early or delayed postoperative ambulation [Table 2].

Table [1]: Preoperative data and patient characteristics

Variables		The early group [n=13]	The late group [n=10]	Test	P
Age [year]		7.46 ± 1.90	14.60 ± 1.47	9.827	<0.001*
Sex[n, %]	Male	8[61.5%]	8[80.0%]	0.91	0.34
	Female	5[38.5%]	2[20.0%]		
Cleft side [n, %]	Right	2[15.4%]	4[40.0%]	10.688	0.005*
	Left	11[84.6%]	2[20.0%]		
	Bilateral	0[0.0%]	4[40.0%]		
Cleft permanent lateral incision eruption	No	9[69.2%]	3[30.0%]	3.48	0.062
	Yes	4[30.8%]	7[70.0%]		
Cleft permanent canine full eruption	No	13[100.0%]	0[0.0%]	23.0	<0.001*
	Yes	0[0.0%]	10[100.0%]		
Maternal risk factor		5[38.5%]	2[20.0%]	0.91	0.34
Associated medical disease [DM]		1[7.7%]	0[0.0%]	0.80	0.37
Preoperative orthodontics		0[0.0%]	2[20.0%]	2.84	0.09

Table [2]: Intra-and post-operative data of the studied patients

Variables		The early group [n=13]	The late group [n=10]	Test	P
Operative time [minute]		108.08 ±17.45	117.20±8.52	1.211	0.239
Hospital stay [days]		2.38 ± 0.65	2.30 ± 0.67	0.304	0.764
IOP blood loss	<80 ml	13[100.0%]	10[100.0%]	-	-
	>80ml	0[0.0%]	0[0.0%]		
Mortality	Yes	0[0.0%]	0[0.0%]	-	-
	No	13[100.0%]	10[100.0%]		
Six months PO oronasal fistula	Open	0[0.0%]	0[0.0%]	-	-
	Closed	13[100.0%]	10[100.0%]		
Six months PO Panorma	Bad filling	0[0.0%]	0[0.0%]	-	-
	Good filling	13[100.0%]	10[100.0%]		
PO complications	Scarring	1[7.7%]	1[10.0%]	0.38	0.84
	Infection	0[0.0%]	0[0.0%]		
	Hematoma	0[0.0%]	0[0.0%]		
PO ambulation	Early	10[76.9%]	8[80.0%]	0.31	0.85
	Delayed	3[23.1%]	2[20.0%]		

Here we presented full data of a sample case: she is a female patient, 8.5 years old, was admitted in

Damietta Military Hospital. She had left unilateral cleft alveolus with persistent left oronasal fistula.



Radiological investigations revealed a left alveolar cleft between the left permanent central incisor and left lateral incisor with un-erupted left canine. The patient was prepared for early left alveolar cleft repair using right cancellous iliac bone grafts. Postoperatively, there

was a complete closure of the left oronasal fistula. Panorama X-ray showed good bone filling in the alveolar defect after six months with predicted undistorted canine eruption [Figures 15-21].

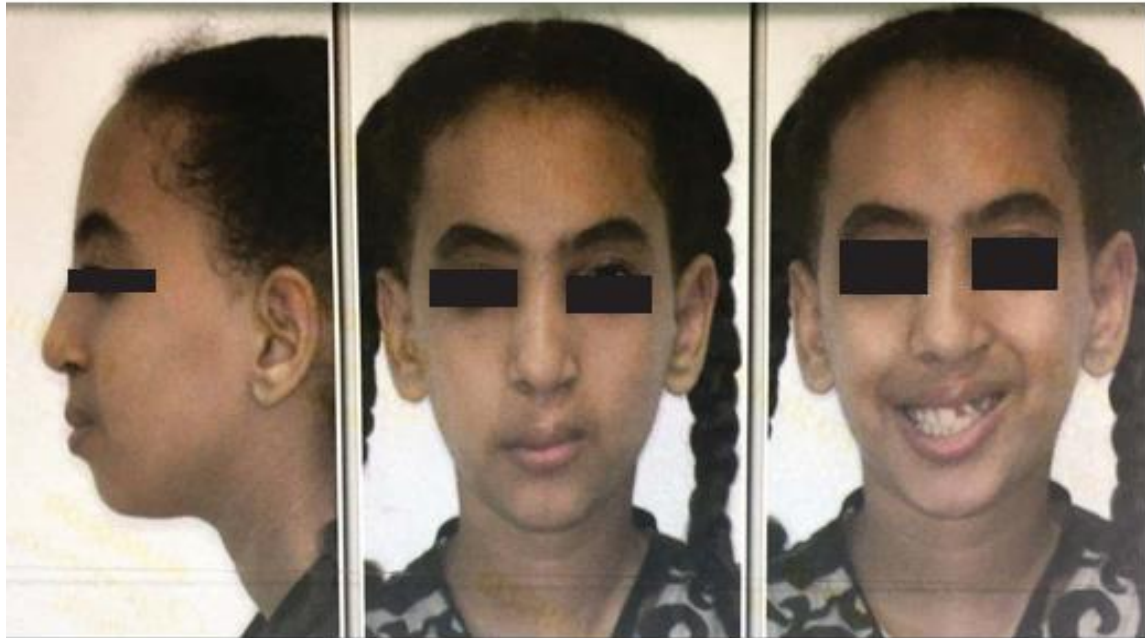

Figure [15]: 8.5 years old female with left unilateral alveolar cleft

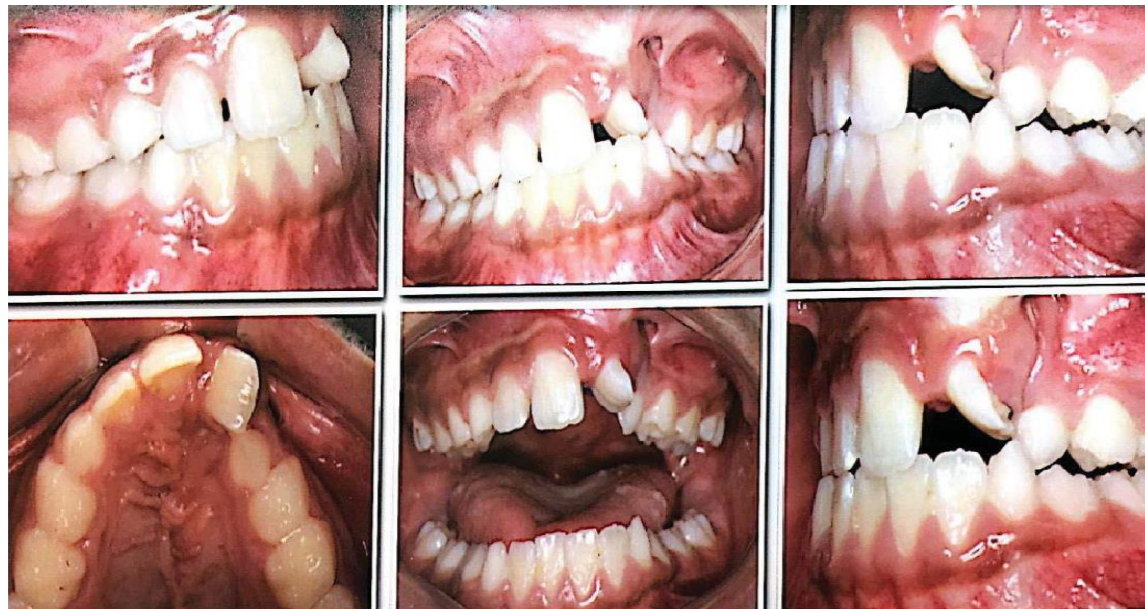


Figure [16]: Preoperative occlusal views showing left unilateral cleft alveolus with oral opening of the oronasal fistula



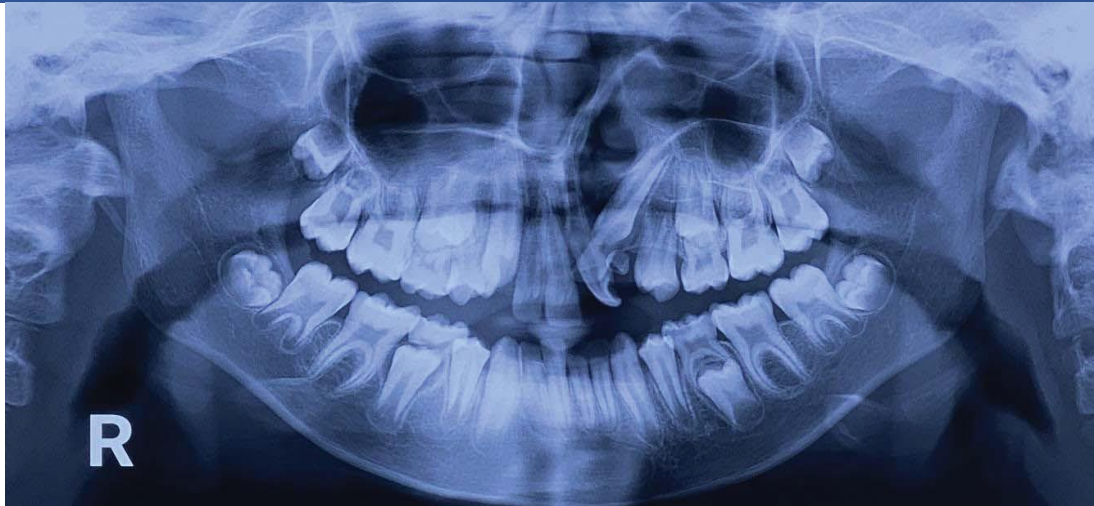

Figure [17] Preoperative panorama X-ray showing alveolar cleft at the left side

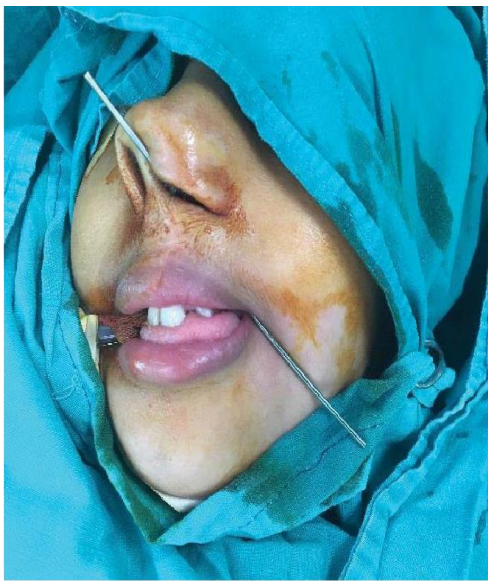

Figure [18] Intraoperative probing of the alveolar cleft confirming the oronasal fistula

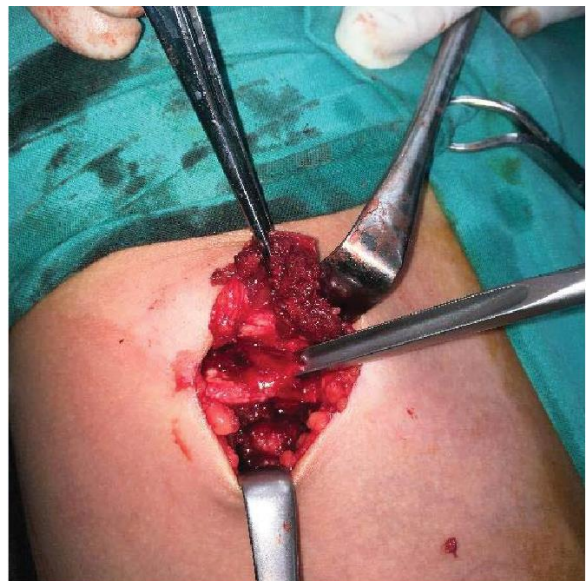

Figure [19] Harvesting cancellous bone grafts from the anterior iliac crest

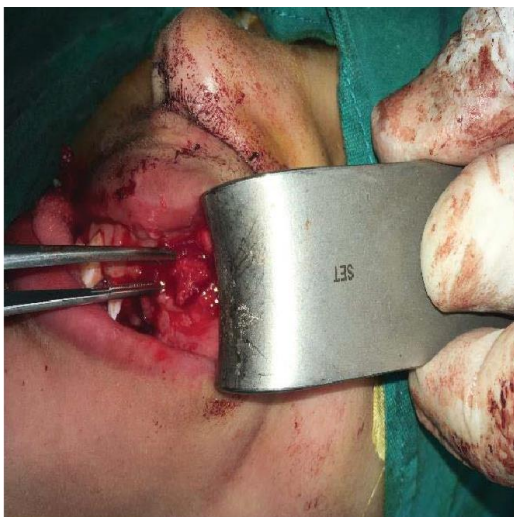

Figure [20] Inlay packing of cancellous bone grafts between the refreshed alveolar cleft bones

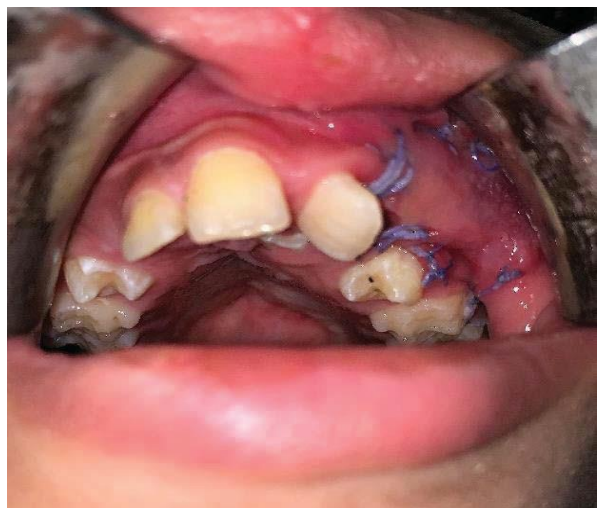

Figure [21]: Complete closure of the oronasal fistula with good gingival contour, three weeks postoperatively

## DISCUSSION

The results of the current study revealed that, either early or late alveolar reconstruction using the anterior iliac crest cancellous bone grafts is associated with excellent outcome. No significant difference was reported between groups regarding their gender, and gender had no effect on the overall outcome. These results are in line with Saruhan and Ertas [13]. In addition, the cleft side did not affect the outcome, although there was a significant difference between the early and late groups. This is in accordance with Choi et al. [14] who did not find that, alveolar cleft side did not affect the postoperative outcome.

Our results also agree with the study of Simões Holz et al. [15] who reported that incidence of canine impaction on the alveolar cleft side was 24% with an increased incidence of lateral incisor absence at the cleft side.

Adam et al. [16] and Correa et al. [17] identified risk factors [e.g., maternal metabolic disorders, prenatal teratogens, phenytoin and valproic acid in early pregnancy] as major causes of orofacial clefts. One case of diabetes mellitus was reported in the current work. Herkrath et al. [18] also reported maternal age above 40 to be an orofacial cleft aetiological risk factor. They reported seven patients with maternal risk factors [30.4%], of these, four patients were with diabetic mother, two patients had their maternal age above 40 and one patient with antiepileptic [phenytoin] drugs administered prenatally.

The study by Brudnicki et al. [19] had a little variability than the current study regarding operative time. They reported a mean surgical duration of alveolar bone grafting of  $83 \pm 21.7$  minutes [Compared to  $108.08 \pm 17.45$  minutes in the early and  $108.08 \pm 17.45$  minutes in the late group]. They considered two-team approach. But their study comes in agreement with the current one as regard to hospital stay. They reported that the mean length of postoperative hospitalization was 2.9 days [here the duration was  $2.38 \pm 0.65$  in the early and  $2.30 \pm 0.67$  in the late group] with discharge on the second or third day in non-complicated cases and on day 8 in complicated cases.

The eventual oronasal fistulae were all completely closed successfully in both groups [100%] with normal healthy gingival contour and no regurgitation of food particles or liquids during the follow-up period. In

addition, there was a radiological evidence of good bone filling in the alveolar defect after six months postoperatively, which anticipates a better later eruption of the canine in the alveolar repaired defect in the early group and provides a room for post-surgical orthodontics and implants. These results are proposed to be attributable to the accumulated experiences of the main performing supervisor surgeons in alveolar cleft reconstruction using cancellous autogenous iliac bone grafts, the pre-surgical management which are strict to the inclusion criteria and aseptic surgical conditions. The results are conventional in agreement with Lorenzoni et al. [20] who used Bergland and Chelsea scales in their study for the assessment of their successful alveolar bone grafts and advocated alveolar bone grafting even in advanced ages.

In terms of postoperative complications, no patients reported immediate or delayed postoperative infection in both groups. We propose that the absence of postoperative infection in this study is based on the absence of coincident comorbidity such as diabetes except for only one patient in the early group. Moreover, careful antibiotic prophylaxis, aseptic intraoperative conditions, cooperative infection control team and good preoperative management are suggested to be also reasons for this result. This situation is in agreement with Du Y et al. [21].

Postoperative scarring at the donor site was encountered in only one patient in each group. This could be attributed to the lowered incision at donor site during the surgery that avoids shearing with clothes later on. Besides, 3 patients in the early and two patients in the second group walked with a limb with mild postoperative donor site pain and delayed ambulation for 3 days. Brudnicki et al. [19] reported that, complications such as pelvic contour alteration was reported in [40.1%], unsatisfactory scar [23%] and gait disturbances and delayed ambulation [92.5%] of the patients. This is greatly different from the current work and may be explained by different inclusion criteria.

Meticulous dissection and good hemostasis at both donor and recipient sites with almost less than 80 ml intraoperative blood loss in all cases, reduced the risk of accompanied morbidity like hematoma and pelvic fractures and therefore, there was no need for blood transfusion for any case performed. In addition, no mortality has been reported in the current study. Nocini et al. [22] reported a higher incidence of postoperative



hematoma formation and increased incidence of pelvic fractures. Actually, they expressed a literature review of previous studies. Taking into account, the dramatic advances in the field of surgery and surgical instruments could explain this contradiction.

Brudnicki et al. [19] reported scanty amounts of cancellous bone grafts to be harvested in large wide or bilateral defects specially in older patients, while in this study the average defect sizes were not large and all harvested cancellous bone grafts were enough to close the defect with good bone filling at follow-up panorama x-rays. We noticed that the defect size was much smaller in the early group with less harvested grafts. In addition, we performed all bilateral alveolar cleft cases in a two-staged approach, with at least 3 to 4 months between each stage.

Janssen et al. [23], Nagashima et al. [24] reported improved outcomes with new alloplastic modalities and tissue-engineered scaffolds and techniques rather than traditional autologous bone sources with fewer comorbidities. Unfortunately, lack of funding and high cost prevented us from further study on these new materials and techniques.

This study did not reveal a statistically significant difference as regard the development of postoperative complications between the early and late treatment groups.

This confirms the optimal benefit of the same surgical procedure used in both groups. However, the core of the study depended on dental age together with chronological age of the patients as regard the cleft permanent canine eruption status. Hence, this study recommends early secondary than primary alveolar grafting.

The study is in a quite agreement to Seifeldin [9] as they support early secondary grafting specially in mixed dentation age rather than primary grafting and late secondary grafting.

It is also in partial agreement to Siegenthaler et al. [25] who reported that secondary bone grafting is more beneficial than primary grafting, yet they concluded that early secondary grafting performed at the age of 2-4 years preserved the dental arch relationships more than performing it at around 10 year. However, and on the opposite side, Salyer [26], reported that, secondary grafting in mixed dentation

age results in canine malposition and impaction and subsequently extending the time of post-operative orthodontics.

In conclusion, from the above results regarding the alveolar cleft reconstruction, it is preferred to perform autologous cancellous bone grafting harvested from the iliac crest bone to repair the cleft. Furthermore, the ideal timing is early, especially in mixed dentation stage before complete canine eruption into or adjacent to the alveolar cleft to preserve the maxillary arch in a reasonable growth pattern.

#### Financial and Non-financial Relationships and Activities of Interest

None

#### REFERENCES

1. Mahran H, Alanezi M, Ali KS, Alshehri AA. Complications after Use of Iliac Bone Graft for Post Cleft Alveolar Bone Defect. *Am J Oral Maxillofacial Surg* 2018; 5[1]: 22-28.
2. Mossaad A, Badry TE, Abdelrahman M, Abdelazim A, Ghanem W, Hassan S, Adly N, Shawkat W. Alveolar Cleft Reconstruction Using Different Grafting Techniques. *Open Access Maced J Med Sci*. 2019; 7 [8]: 1369-1373. [DOI: 10.3889/ oamjms.2019.236].
3. Grollemund B, Guedeney A, Vazquez MP, Picard A, Soupre V, Pellerin P, Simon E, Velten M, Dissaux C, Kauffmann I, Bruant-Rodier C, Danion-Grilliat A. Relational development in children with cleft lip and palate: influence of the waiting period prior to the first surgical intervention and parental psychological perceptions of the abnormality. *BMC Pediatr*. 2012 Jun 8; 12:65. [DOI: 10.1186/1471-2431-12-65].
4. Kumar P, Vinitha B, Fathima G. Bone grafts in dentistry. *J Pharm Bioallied Sci*. 2013 Jun;5 [Suppl 1]:S125-7. [DOI: 10.4103/0975-7406.113312].
5. Stasiak M, Wojtaszek-Słomińska A, Racka-Pilszak B. Current methods for secondary alveolar bone grafting assessment in cleft lip and palate patients - A systematic review. *J Craniomaxillofac Surg*. 2019;47[4]:578-585. [DOI: 10.1016/ j.jcms.2019.01.013].
6. Frisdal A, Trainor PA. Development and evolution of the pharyngeal apparatus. *Wiley Interdiscip Rev Dev Biol*. 2014 Nov-Dec;3[6]:403-18. [DOI: 10.1002/wdev.147].
7. Kyung H, Kang N. Management of Alveolar Cleft. *Arch Craniofac Surg*. 2015; 16[2]; 49-52. [DOI: 10.7181/acfs.2015.16.2.49].



8. Rychlik D, Wójcicki P. Bone graft healing in alveolar osteoplasty in patients with unilateral lip, alveolar process, and palate clefts. *J Craniofac Surg.* 2012 Jan; 23 [1]:118-23. [DOI: 10.1097/SCS.0b013e318240faa0]
9. Seifeldin SA. Is alveolar cleft reconstruction still controversial? [Review of literature]. *Saudi Dent J.* 2016 Jan; 28 [1]:3-11. [DOI: 10.1016/j.sdentj.2015.01.006].
10. Vuletic M, Knežević P, Jokić D, Rebić J, Žabarović D, Macan D. Alveolar Bone Grafting in Cleft Patients from Bone Defect to Dental Implants. *Acta Stomatol Croat.* 2014 Dec; 48[4]:250-7. [DOI: 10.15644/asc47/4/2].
11. Radia S, Cash AC, Moar K. An Unusual Case of an Odontogenic Keratocyst Associated with an Ungrafted Alveolar Cleft: A Case Report and Review of the Literature. *Cleft Palate Craniofac J.* 2019;56[1]:110-115. [DOI: 10.1177/1055665618770053].
12. Kang NH. Current Methods for the Treatment of Alveolar Cleft. *Arch Plast Surg.* 2017 May; 44 [3]: 188-193. [DOI: 10.5999/aps.2017.44.3.188].
13. Saruhan N, Ertas U. Evaluating of Platelet-Rich Fibrin in the Treatment of Alveolar Cleft with Iliac Bone Graft by Means of Volumetric Analysis. *J Craniofac Surg.* 2018 Mar; 29 [2]:322-326. [DOI: 10.1097/SCS.0000000000004125].
14. Choi HS, Choi HG, Kim SH, Park HJ, Shin DH, Jo DI, Kim CK, Uhm KI. Influence of the Alveolar Cleft Type on Preoperative Estimation Using 3D CT Assessment for Alveolar Cleft. *Arch Plast Surg.* 2012;39[5]:477-82. [DOI: 10.5999/aps.2012.39.5.477].
15. Simões Holz I, Martinelli Carvalho R, Lauris JR, Lindauer SJ, Gamba Garib D. Permanent canine eruption into the alveolar cleft region after secondary alveolar bone grafting: Are there prediction factors for impaction? *Am J Orthod Dentofacial Orthop.* 2018; 154 [5]: 657-663. [DOI: 10.1016/j.ajodo.2018.01.016].
16. Adam MP, Polifka JE, Friedman JM. Evolving knowledge of the teratogenicity of medications in human pregnancy. *Am J Med Genet C Semin Med Genet.* 2011 Aug 15; 157C [3]:175-82. [DOI: 10.1002/ajmg.c.30313].
17. Correa A, Gilboa SM, Besser LM, Botto LD, Moore CA, Hobbs CA, Cleves MA, Riehle-Colarusso TJ, Waller DK, Reece EA. Diabetes mellitus and birth defects. *Am J Obstet Gynecol.* 2008;199[3]:237.e1-9. [DOI: 10.1016/j.ajog.2008.06.028].
18. Herkrath AP, Herkrath FJ, Rebelo MA, Vettore MV. Parental age as a risk factor for non-syndromic oral clefts: a meta-analysis. *J Dent.* 2012;40[1]:3-14. [DOI: 10.1016/j.jdent.2011.10.002].
19. Brudnicki A, Rachwalski M, Wiepszowski Ł, Sawicka E. Secondary alveolar bone grafting in cleft lip and palate: A comparative analysis of donor site morbidity in different age groups. *J Craniomaxillofac Surg.* 2019;47 [1]:165-169. [DOI: 10.1016/j.jcms.2018.11.006].
20. Lorenzoni DC, Janson G, Bastos JC, Carvalho RM, Bastos JC Jr, de Cássia Moura Carvalho Lauris R, Henriques JF, Ozawa TO. Evaluation of secondary alveolar bone grafting outcomes performed after canine eruption in complete unilateral cleft lip and palate. *Clin Oral Investig.* 2017 Jan;21[1]:267-273. [DOI: 10.1007/s00784-016-1786-3].
21. Du Y, Zhou W, Pan Y, Tang Y, Wan L, Jiang H. Block iliac bone grafting enhances osseous healing of alveolar reconstruction in older cleft patients: A radiological and histological evaluation. *Med Oral Patol Oral Cir Bucal.* 2018 Mar 1; 23 [2]:e216-e224. [DOI: 10.4317/medoral.21991].
22. Nocini PF, Bedogni A, Valsecchi S, Trevisiol L, Ferrari F, Fior A, Saia G. Fractures of the iliac crest following anterior and posterior bone graft harvesting. Review of the literature and case presentation. *Minerva Stomatol.* 2003 Oct;52[10]:441-8, 448-52. [PMID: 14765029].
23. Janssen NG, de Ruiter AP, van Hout WMMT, van Miegem V, Gawlitta D, Groot FB, Meijer GJ, Rosenberg AJWP, Koole R. Microstructured  $\beta$ -Tricalcium Phosphate Putty Versus Autologous Bone for Repair of Alveolar Clefts in a Goat Model. *Cleft Palate Craniofac J.* 2017;54[6]:699-706. [DOI: 10.1597/15-314].
24. Nagashima H, Sakamoto Y, Ogata H, Miyamoto J, Yazawa M, Kishi K. Evaluation of bone volume after secondary bone grafting in unilateral alveolar cleft using computer-aided engineering. *Cleft Palate Craniofac J.* 2014;51[6]:665-8. [DOI: 10.1597/13-045].
25. Siegenthaler M, Bettelini L, Brudnicki A, Rachwalski M, Fudalej PS. Early versus late alveolar bone grafting in unilateral cleft lip and palate: Dental arch relationships in pre-adolescent patients. *J Craniomaxillofac Surg.* 2018 Dec; 46 [12]: 2052-2057. [DOI: 10.1016/j.jcms.2018.09.031].
26. Salyer KE. Primary reconstruction of alveolar clefts using recombinant human bone morphogenetic protein-2: clinical and radiographic outcomes. *J Craniofac Surg.* 2009 Sep;20 Suppl 2:1765. [DOI: 10.1097/SCS.0b013e3181b5d0af].

# International Journal

<https://ijma.journals.ekb.eg/>

Print ISSN: 2636-4174

Online ISSN: 2682-3780

# of Medical Arts