

RESEARCH ARTICLE

Troponin in Severe Pulmonary Stenosis, is it Important to Measure?

Mohammad Eltahlawi, Mohammad Morsy, Mohammad Elawady, Ahmed Eldamanhory.

Cardiology Department, Faculty of Medicine, Zagazig University, 44519, Zagazig, Egypt.

Article History: Received: 30/11/2020 Received in revised form: 20/03/2021 Accepted: 29/03/2021

Abstract

Osteoarthritis (OA) is considered the prevalent arthritis in human and some animals, causing Pulmonary valve stenosis is a congenital disease in most of cases. The treatment of choice is balloon valvuloplasty (BPV) in human. Information is needed regarding analytical characteristics of cardiac troponin assays used in preclinical studies which usually are applied on animal models based on cumulative knowledge of several studies in the last two decades we aim to assess the relationship between troponin biomarker and the severity of pulmonary valve stenosis. Thirty-six patients with severe valvular pulmonary stenosis (PS) were recruited. Comparable control healthy group were involved. Serum troponin I was measured for all the sample populations. Echocardiographic evaluation of pulmonary valve and right ventricular (RV) function were done. Results: The estimated level of cardiac troponin in thirty-six patients with severe valvular PS was recruited, there was significant correlation between peak Systolic pressure gradient (SPG) and troponin in PS ($r = 0.768$). There was a significant correlation between troponin level and the parameters of RV diastolic dysfunction ($p < 0.001$) ($r = 0.81$). Troponin was significantly decreased 2 weeks after BPV ($p < 0.01$). Conclusion: serum cardiac troponin is elevated in valvular PS and correlates with its severity and associates with RV dysfunction. RV function improved after BPV associated with decrease in the troponin level in human. Troponin could be used as a biomarker for PS severity and the associated RV diastolic dysfunction in human. The human will benefit from relief of pulmonary stenosis by balloon valvuloplasty as in our study and other studies which made on animals with pulmonary stenosis.

Keywords: Pulmonary stenosis; Troponin; Tissue Doppler; Balloon valvuloplasty; Re-stenosis

Introduction

The commonest etiology of pulmonic stenosis (PS) is congenital. Rarely rheumatic fever affects pulmonary valve (PV) [1]. Insulated pulmonary valve stenosis is predominantly around 10% of all congenital heart disease. Typically, the valves are partly fused and the three cusps are thin and spreading, which render the valve into a deep conical or dome-shaped form with a small central opening. In cases with extreme valve PS, hypertrophy of the right ventricle (RV) can lead to an infundibular narrowing leading to the right ventricular outflow tract (RVOT) obstruction pressure gradient could be measured simultaneously by continuous wave Doppler echocardiography. Patients present with severe PS with any symptom at the

beginning of disease progression. That is because of possible development of dangerous complications and disability of the life later that could occur if appropriate treatment is not done in time [2].

Balloon pulmonary valvuloplasty (BPV) is the safest cure for extreme PS valve. This causes relaxation of the congestion of the right ventricular outflow (RVOT) [3].

Relieving of the RVOT obstruction can be undertaken surgically or percutaneously where the obstruction involves the pulmonary valve. These procedures could be measured by echocardiography by calculating the pressure gradient over the RVOT before and after the operation. RV dysfunction due to pressure overload is associated with elevated cardiac

mark. Troponin is one of the cardiac markers that has been shown to increase RV dysfunction in certain cases, such as pulmonary embolism (PE). Right ventricular dilation and rapid rise in pulmonary arterial resistance is thought to induce troponin release in acute PE. Troponin-T-positive patients were more likely to have certain heart problems, such as right ventricular dysfunction [4].

The purpose of this analysis is to establish the relationship between troponin and the severity of PS and the associated RV diastolic dysfunction and to be as a comparative reference for animal suffering from same condition.

Cardiac troponin I is a specific biomarker of myocardial injury and severe pulmonic stenosis as mentioned previously in dogs, cats and laboratory animals measurement of serum cTnI can be used to aid in diagnosing cardiac diseases in rhesus macaques. However, cTnI measurement does not replace echocardiographic evaluation to diagnose cardiac diseases in rhesus macaques due to the poor sensitivity of the assay and the weak correlation to with more established echocardiographic markers for cardiac disease [5-9].

Material and Methods

The research was undertaken at the Department of Cardiology, Zagazig University Hospitals. We included cases with severe valvular PS during the period between March and December 2018.

Inclusion criteria

Patients suffering severe valvular PS are amenable for balloon pulmonary valvuloplasty. The diagnosis depends on 2D echocardiography according to guidelines as follows.

- patients with a domed pulmonary valve with no symptoms & SPG>60mmHg or MSPG>40mmHg (less than moderate pulmonary regurg (PR)).
- patients with a domed pulmonary valve with symptoms & SPG>50mmHg or

MSPG> 30 mmHg (less than moderate PR) [10,11].

Exclusion criteria:

We excluded the patients with:

- 1- RVOT obstruction in presence of complex congenital heart disease e.g. Fallot tetralogy (F4).
- 2- Moderate and severe PR.
- 3- Sub valvular and supra valvular PS.
- 4 Other causes of troponin increase:
 - Chronic or acute renal dysfunction;
 - Extreme congestive heart failure, acute and chronic.
 - Hypertensive crisis;
 - Tachyarrhythmias or bradyarrhythmias.
 - Coronary embolism, severe pulmonary hypertension
 - Inflammatory conditions such as myocarditis.
 - Acute brain conditions, including cerebral infarction or sub-arachnoid hemorrhage.
 - Aortic dissection, aortic valve disease or hypertrophic cardiomyopathy;
 - Coronary contusion during aplatation, speed, cardioversion, or biopsy of the heart.

Ethical issue:

Chronic or acute renal diseased case has given written informed consent. The report has been approved by the Medical Science and Ethics Committee (IRB) of Zagazig University.

Data gathered included:

Data were collected for all patients once moderate and severe valvular pulmonary stenosis was proved. The following data were collected:

1. **Demographic characteristics and risk factors:** age, gender, and family history of congenital heart diseases.
2. **Full history taking involving:**

- Risk factors: age, sex, any other congenital or valvular heart disease.
- Onset, course, duration of the presenting complain (cyanosis, exertional dyspnea, fatigue, low cardiac output symptoms, chest pain, syncope ..etc)
- Family history of any congenital heart diseases

3. Physical examination:

* General examination including:

- Pulse and blood pressure.
- Chronic or acute renal function of the neck veins.
- Edema in the lower limbs.
- Checking of the abdomen and chest.
- *Cardial exam .Including:
- Inspection, palpation and auscultation;

4. **Laboratory investigations including** serum troponin level before balloon valvuloplasty then two weeks later.

5. **Twelve lead electrocardiography** with special emphasis on the QRS duration which represents the time for ventricular depolarization. It was recorded in each patient immediately after hospital admission. Echocardiograph (ECG) was done on admission at a paper speed of 25mm/s and amplification of 10mm/mv.

6. **Echocardiography:** A standard transthoracic echocardiogram (TTE) was performed using commercially available systems. Images were obtained using a 2.5 MHz transducer. Cardiac chambers and pulmonary artery are assessed. The pulmonary valve systems have been tested in detail using the normal left lateral decubitus location. The pulmonary valve has been structurally tested in the picture of the parasternal short axis. The peak systolic pressure gradients above the pulmonary valve were then obtained using continuous-wave (CW) Doppler.

-We considered the following in compliance with the 2018 AHA/ACC guideline.

The valve area of a stable adult is 2.0 cm²/m² of body surface area.

Mild valve PS is characterised as a valve area greater than 1 cm² and a transvalvular pressure Peak gradient <36 mm Hg (peak velocity <3 m/s) •Fairly extreme PS occurs when the valve area is 0.5-1.0 cm², with a transvalvular pressure Peak gradient of 36–64 mm Hg (peak velocity 3–4 m/s) •Extreme PS is classified as the valve area < 0.5 cm² and the transvalve pressure Peak gradient 64 mm Hg (peak velocity > 4 m/s).

The pulmonary valve annulus was assessed.

- **Color & continuous-wave Doppler** across pulmonary valve to assess amount of pulmonary regurg.

- **RV function evaluation:** the following parameters were used:

•Chronic or acute renal dEa• NMildvalv RVFAC was classified as (RV end diastolic area – RV end systolic area)/end diastolic area × 100. Correct ventricular field in the diastole and systole was obtained by tracing the RV endocardium in both phases from the ring along the free wall to the apex and then down to the annulus along the interventricular septum in the apical 4 chamber view.

Tricuspid cancelar plane systolic excursion (TAPSE):

In apical 4-chamber vision, the M-mode cursor was positioned at the la by tricuspid annulus at lateral RV free wall in such a way that the annulus moved along M-mode cursor.

For RV function assessment the following done:

a) Myocardial performance index (MPI) by pulsed-wave tissue Doppler imaging.

b) Pulsed wave tissue Doppler imaging:

Chronic or acute repulsed diffusion tensor imaging (DTI) images were acquired by positioning the cursor on the RV free wall at the tricuspid annulus level. The sample volume of 3.5 mm will be used. Gains have been configured and low wall philtre settings

and the Doppler speed range of -20 to $+20$ cm/s and the sweep speed of 50 mm/s have been chosen. As a Doppler-based procedure, correct synchronisation (<20 degrees) with the ultrasound beam is considered necessary.

The main positive velocity (S') was reported with the movement of the annulus to the apex during systole. Chronic or acute repulsed DTI two large negative waves were reported, one in the early diastole (E') and one in the late diastole (A'). S' length was calculated as ejection time (ET), the time between the end of S' and the beginning of E' as isovolume relaxation time (IRT), the time between the end of A' and the beginning of S' as isovolume contraction time (ICT). Correct ventricular MPI has been estimated as $(IRT + ICT)/ET$.

c) Diastolic RV dysfunction:

Trans-tricuspid E/A ratio, E/E ratio, E deceleration rate time were taken for grading RV diastolic dysfunction. Impaired relaxation was defined as E/A ratio <0.8 , pseudo normalization as E/A ratio 0.8 to 2.1 with E/E' ratio >6 and restrictive filling as E/A ratio >2.1 with deceleration time <120 ms.

7- Catheterization and balloon valvuloplasty:

Pulmonary balloon technique (PBV) with target balloon: annulus diameter ratio (BAR) around 1.2:1.4. The data reported included: age at catheterization, initial RV pressure, the ratio of right ventricular pressure to systemic arterial or ventricular pressure, the diameter of the largest balloon used for valve expansion at full inflation, and the PV annulus diameter measured during systole and BAR was determined to be the ratio of these two diameters. Goal for the BAR for patients undergoing PBV, 1.2:1.4, depends on experimental studies in which a BAR of 1.5 or higher had a more risk of damage to the RVOT. Immediately after balloon valvuloplasty there is a decline in the peak-to-peak gradient through the PV & a decline in RVSP.[12].\

Results

Thirty-six patients with severe valvular PS with mean age 3.24 ± 1.7 years were studied. The cases were 16 females and 20 males. No big complications of this approach have been encountered in our collection. In most cases, the right ventricular pressure decreased enough after the surgery to avoid further therapy. There is no scientific indication that pulmonary regurgitation is caused by surgery in any of the patients.

Table (1): The clinical and investigational data of patients with valvular pulmonary stenosis

Criteria	- Total = 36
- Age (years)	-
- Mean \pm SD	- 3.24 ± 1.7
- Range	- 1-6
- Sex	-
- Male	20 (55.6%)
- Female	- 16 (44.4%)
- Echo	-
- Maximum PG	- 88.7 ± 10.3
- RV	-
- E/e'	- 8.3 ± 1.12
- Lab	-
- Troponin	- 12.5 ± 3.4

SD: standard error, PG: pressure gradient, RV: right ventricular

Table (2): Comparison between patient's data before and after balloon valvuloplasty

Criteria	- Before valvuloplasty	balloon	- After 2 weeks	- P-value
- E/e'	- 8.3 ± 1.12		- 3.34 ± 0.55	- < 0.001 - (HS)
- Troponin	- 12.5 ± 3.4		- 0.21 ± 0.11	- < 0.001 - (HS)

HS: highly significant

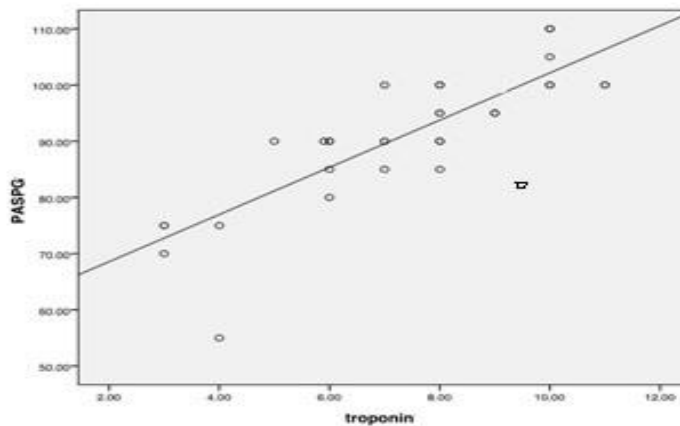


Figure 1. The relation between Systolic pressure gradient (SPG) and treponin level. There was a significant correlation between SPG and treponin level

Troponin was elevated in all the cases. Mean troponin level was 12.5 ± 3.4 ngm/ mL.

There was a significant correlation between peak SPG and troponin before BPV ($P < 0.001$) ($r = 0.768$) (Figure 1).

There was a significant correlation between troponin level and the parameters of RV diastolic dysfunction (E/e') ($P < 0.001$) ($r = 0.81$).

The BPV were successful in all patients with adequate (more than 50%) decrease in peak SPG.

There was a significant drop in troponin values 2 weeks post-BPV ($P < 0.001$).

In addition, the associated RV function was significantly improved 2 weeks after BPV regarding maximum SPG and E/e' ($P < 0.001$) for each (Table 2).

Discussion

This is the first study, to the best of our knowledge, evaluating the relationship between PS and the troponin and the impact of

BPV on this biomarker level. In the current study, severe PS causes rise in troponin values that decreased significantly after BPV. Besides, the level of troponin-biomarker correlated significantly to the degree of PS severity as well as to the grade of RV diastolic dysfunction.

PS exerts a significant pressure overload on RV that may cause that may cause a rise in right ventricular pressure. This elevation is accompanied by multiple changes in the RV muscle and geometry, including changes in the morphology, movement of the interventricular septum, as well as changes in the shape of the RV cavity, and an increase in the RV muscle mass[13].

RV dysfunction due to pressure overload is associated with elevated cardiac markers. Troponin is one of cardiac markers which was found to be increased in some settings of RV dysfunction in some cases like pulmonary embolism (PE). Right ventricular dilation and strain from sudden increase in pulmonary

arterial resistance is believed to be the cause of troponin release in acute (PE) so, RV strain can lead to subsequent troponin release [14]. Our hypothesis is that RV pressure overload due to severe PS might result in relative RV ischemia due to vascular compression. This ischemia results in-turn into micro-necrosis with troponin release. Congenital heart diseases that cause hypertrophy of ventricular wall and increased its pressure could affect myocardial blood flow [15,16]. This overload is usually associated with RV dysfunction as occurs in pulmonary embolism with acute rise in pulmonary arterial pressure [17].

In our study, the serum troponin level decreased significantly upon relief of RV strain after BPV. These results proved that the myonecrosis caused by RV strain disappears after BPV evidenced by reduction of the level troponin which has high sensitivity and specificity to myocardial injury [18].

The current study revealed that RV dysfunction occurred with PS and significantly improved after BPV. The first to publish that percutaneous balloon pulmonary valvuloplasty (PBPV) was found to be the treatment of choice in cases of significant valvular PS. This technique was widely adopted and it showed good long-term outcomes regarding successful relief of RVOT obstruction since in our study, No big complications of echocardiography were encountered before valvuloplasty of the balloon, then two weeks after. Echocardiographic evidence in patients with pulmonary stenosis showed that the right ventricular activity in patients with pulmonary stenosis had substantially compromised tricuspid annular plane systolic excursion (TAPSE) and E/e both of these parameters changed significantly after valvuloplasty but there was no substantial difference before and after valvuloplasty. [19].

In agreement of our results, another study conducted on PS patients found that RV reverse remodeling occurred after BPV with significant improvement of E/E' of the TV lateral annulus[20]. No big complications of the echo. A research based primarily on elevated pressure and/or volume load resulting

in myocardial injury. Any recently developed and sensitive methods for the assessment of cardiac troponins have been indicated to be helpful in determining myocardial damage in children with congenital heart disease [21].

It was clear that in fact, the right ventricle, being smaller and more compact, is forced to avoid post load pain caused by increased pulmonary flow. No big problems of the echo stated in the Law of Laplace, both of these modifications result in an improvement in the thickness of the right ventricular wall at the same time. In previous research, both ventricular hypertrophy and ventricular wall stress due to left to right shunts have been reported to interrupt myocardial perfusion. In addition, elevated intra-wall pressure due to stress often disrupts the coronary perfusion analysis, which focuses primarily on increased blood pressure [22].

No major complications or major trials were undertaken in childhood patients, classified into two groups: those with pressure loads, such as aortic coarctation or aortic and pulmonary valve stenosis, and those with volume loads, such as ASD (atrial septal defect) or PDA (patent ductus arteriosus) [23, 24].

No major complications or major trials showed that CTEPH (chronic thrombo embolic pulmonary hypertension) has affected both the right and left ventricles of the heart. Improved lung perfusion and reduction of right ventricular pressure overload are the direct effects of pulmonary thrombo endarterectomy (PTE), the elimination of pressure overload which in turn results in a profound reduction of right ventricular size and a recovery of systolic function. Our results revealed that the removal of pressure overload on right ventricle from pulmonary stenosis will improve right ventricular functions [25].

With or without major problems the patient analysis exposed measurements of tricuspid annular motion from the apical point of view as a tool for estimating RV function. There are however, few studies on the study of tricuspid annular motion in RV disease. RV base

descent is both sensitive and unique to the diagnosis of patients with hemodynamically severe RV dysfunction and the most potent indicator of adverse reactions in patients with myocarditis.[26-27].

The studies have been stated that the use of tricuspid annular motion for RV function is the logical consequence of recent findings on tricuspid annular motion. A systolic velocity, also greater than that of mitral annulus, has been seen for tricuspid annulus in healthy subjects, suggesting that longitudinal shortening plays an important role in right ventricular activity and that patients with pulmonary stenosis have dramatically altered status with TDI [28]. It was cleared that right ventricular ejection fraction mainly constant in patients on follow up after PBPV (percutaneous balloon pulmonary valvuloplasty) [29].

Our study results are comparable with the previous findings of experimental studies made on animals as a study of cardiac troponin and C reactive protein (CRP) which increased in dogs with severe pulmonary stenosis and balloon vavoplasty has been done [6,9] Meanwhile Cardiac troponins are quantitative markers of heart injury which measured in dogs and cats and which correlate with prognosis, irrespective of clinical presentation of the case either acute heart disease, chronic heart disease, reversible heart injury or irreversible Based on preclinical studies on different animal species, Individual assay characterization by animal species is needed to prevent misinterpretation of myocardial injury-based cardiac troponin findings[5-9]

Conclusion

Troponin is elevated in valvular PS and correlates with its severity and associates with RV dysfunction. RV function improved after BPV associated with decrease in the troponin level. Troponin could be used as a biomarker for PS severity and the associated RV diastolic dysfunction in human. The animal and human will benefit from relief of pulmonary stenosis by balloon vavoplasty as in our study and

other studies which made on animals with pulmonary stenosis.

Conflict of Interest: There is no conflict of interest concerning this study.

References

- [1] Margey, R. and Inglessis-Azuaje, I. (2012): Percutaneous Therapies in the treatment of valvular pulmonary stenosis. *Interventional Cardiology Clinics* 1(1): 101-119.
- [2] Silversides, C., Beaudesne, L., Bradley, T., Connelly, M., Niwa, K., Mulder, B., Webb, G., Colman, J. and Therrien, J. (2010): Canadian Cardiovascular Society 2009 Consensus Conference on the management of adults with congenital heart disease: Outflow tract obstruction, coarctation of the aorta, tetralogy of Fallot, Ebstein anomaly and Marfan's syndrome. *Can J Cardiol* 26(3): e80–e97.
- [3] Stout, K.K. Daniels, C.J., Aboulhosn, J., Bozkurt, B., Broberg, C.S., Colman, J.M., Crumb, S.R., Dearani, J.A., Fuller, S., Gurvitz, M., Khairy, P., Landzberg, M.J., Saidi, A., Valente, A.M. and Van Hare, G.F. (2019): AHA/ACC guideline for the management of adults with congenital heart disease: Executive summary. A report of the American College of Cardiology / American Heart Association Task Force on Clinical Practice Guidelines. *Circulation* 139: e637-e697.
- [4] Candice, K. Silversides, L. and Timothy, B.(2010): Canadian Cardiovascular Society 2009 Consensus Conference on the management of adults with congenital heart disease: Outflow tract obstruction, coarctation of the aorta, tetralogy of Fallot, Ebstein anomaly and Marfan's syndrome. *Can J Cardiol.* 26(3): e80–e97.
- [5] Langhom, R. and Willesen, J.L. (2016): Cardiac Troponins in Dogs and Cats *Journal of Veterinary Internal Medicine* 30 (1): 36-50.
- [6] Ueda, Yu ; Yee, JoAnn L ; Williams, Amber , Roberts, Jeffrey A , Christe, Kari

- L ,Stern, Joshua A (2020) :Identifying Cardiac Diseases using Cardiac Biomarkers in Rhesus Macaques (*Macaca mulatta*), : Comparative Medicine, 70(5): 348-357
- [7] Apple FS, Murakami MM, Ler R, Berridge B, Bounous D, Brewster D , Dunn B, Hausner E, Herman E, Holt G, Lamb M, MacGregor J, Nicklaus R, Pettit S, Reagan B, Roome N, Schultze E, Short B, Stoll R, Stonebrook M, Taggert P, Thudium D, Topper M, Walker D, Wallace K and York M (2008): Analytical characteristics of commercial cardiac troponin I and T immunoassays, in serum from rats, dogs, and monkeys with induced acute myocardial injury. *Clin Chem*; 54:1982–1989
- [8] Ljungvall I, Hoglund K, Tidholm ,AI Olsen H, Borgarelli M, Venge P, and Häggström J (2010): Cardiac troponin I is associated with severity of myxomatous mitral valve disease, age, and C-reactive protein in dogs. *J Vet Intern Med*;24:153–159.
- [9] Winter RL, Saunders AB, Gordon SG, Gordon SG, Miller MW, Sykes K T, Suchodolski J S and Steiner J M.(2014) :Analytical validation and clinical evaluation of a commercially available high-sensitivity immunoassay for the measurement of troponin I in humans for use in dogs. *J Vet Cardiol* 16:81–89.
- [10] Harrild, D.M., Powell, A.J., Tran, T.X., Geva, T., Lock, J.E., Rhodes J & McElhinney DB. (2010): Long-Term Pulmonary Regurgitation Following Balloon Valvuloplasty for Pulmonary Stenosis: Risk Factors and Relationship to Exercise Capacity and Ventricular Volume and Function. *Journal of the American College of Cardiology* 55(10): 1041–1047.
- [11] Baumgartner, H., Hung, J., Bermejo, J., Chambers, J.B., Evangelista, A., Griffin, B.P. and Quiñones, M. Echocardiographic assessment of valve stenosis (2008): EAE/ASE recommendations for clinical practice. *European Heart Journal-Cardiovascular Imaging*.
- [12] Gielen, H., Daniels, O. and van Lier, H. (1999): Natural history of congenital pulmonary valvar stenosis: an echo and Doppler cardiographic study. *Cardiol Young* 9: 129-35.
- [13] Alyan, O., Ozdemir, O., Kacmaz, F., Topaloglu, S., Ozbakir, C., Gozu, A., et al. (2008): Sympathetic overactivity in patients with pulmonary stenosis and improvement after percutaneous balloon valvuloplasty. *Ann Noninvasive Electrocardiol* 13: 257-65.
- [14] Douketis, J.D., Crowther, M.A., Stanton, E.B., et al.(2002): Elevated cardiac troponin levels in patients with subacute pulmonary embolism. *Arch Intern Med* 162: 79-81.
- [15] Petersen, S.E., Jerosch-Herold, M., Hudsmith, L.E. et al.(2007): Evidence for microvascular dysfunction in hypertrophic cardiomyopathy: new insights from multiparametric magnetic resonance imaging. *Circulation* 115: 2418–2425.
- [16] Kubo, T., Kitaoka, H., Okawa, M. et al. (2010): Serum cardiac troponin I is related to increased left ventricular wall thickness, left ventricular dysfunction, and male gender in hypertrophic cardiomyopathy. *ClinCardiol* 33: E1–E7.
- [17] Douketis, J.D., Crowther, M.A., Stanton, E.B., et al.(2002): Elevated cardiac troponin levels in patients with subacute pulmonary embolism. *Arch Intern Med* 162: 79-81.
- [18] Garg, P., Morris, P., Fazlanie, A.L., Vijayan, S., Dancso, B., Dastidar, A.G., Plein S, Mueller, C., Haaf, P.(2017) Cardiac biomarkers of acute coronary syndrome: from history to high-sensitivity cardiac troponin. *Intern Emerg Med* 12: 147–155.
- [19] Kan, J.S., White.R.I., Mitchell, S.E. and Gardner, T.J. (1982): Percutaneous balloon valvuloplasty: a new method for

- treating congenital pulmonary-valve stenosis. *N Engl J Med*; 307(9):540-2
- [20] Mansour, A., Elfiky, A.A., Mohamed, A.S. and Ezzeldin, D.A. (2020): Mechanism of the right ventricular reverse remodeling after balloon pulmonary valvuloplasty in patients with congenital pulmonary stenosis: A three-dimensional echocardiographic study. *Ann Pediatr Card* 13: 123-9.
- [21] Torbicki, A., Kurzyna, M., Kuca, P., Fijałkowska, A., Sikora, J., Florczyk, M. (2003): Detectable serum cardiac troponin T as a marker of poor prognosis among patients with chronic precapillary pulmonary hypertension. *Circulation* 108: 844–848.
- [22] Galderisi, M. (2007): Epicardial coronary vessels and coronary microcirculation in pressure overload hypertrophy: a complex interaction. *Am J Hypertens* 20: 285–286
- [23] Eerola, A., Jokinen, E.O., Savukoski, T.I. (2013): Cardiac troponin I in congenital heart defects with pressure or volume overload. *Scand Cardiovasc J* 47: 154–159.
- [24] Kayali, S., Ertugrul, I., Yoldas, T., Kaya, O., Ozgur, S., Orun, U.A. and Karademir, S. (2018): Sensitive cardiac troponins: Could they be new biomarkers in pediatric pulmonary hypertension due to congenital heart disease? *Pediatric Cardiology* 39: 718-725.
- [25] Menzel, T., Wagner, S., Kramm, T., Mohr-Kahaly, S., Mayer, E., Braeuninger, S. and Meyer, J. (2000): Pathophysiology of impaired right and left ventricular function in chronic embolic pulmonary hypertension changes after pulmonary thromboendarterectomy. *Chest Journal* 118(4): 897-903.
- [26] Lindström, L., Wilkenshoff, U.M., Larsson, H., (2001): Echocardiographic assessment of arrhythmogenic right ventricular cardiomyopathy. *Heart* 86(1): 31-8.
- [27] Hoffmann, R., Hanrath, P. (2001): Tricuspid annular velocity measurement. Simple and accurate solution for a delicate problem? *Eur Heart J* 22(4): 280–282.
- [28] Li S, Yu H, Wong, S.J. and Cheung, Y. (2014): Right and left ventricular mechanics and interaction late after balloon valvoplasty for pulmonary stenosis. *European Heart Journal – Cardiovascular Imaging* 15(9): 1020-1028.
- [29] Ashley, B. and Brooke, E., et al. (2009): Cardiac troponin I and C-reactive protein concentrations in dogs with severe pulmonic stenosis before and after balloon valvuloplasty. *Journal of Veterinary Cardiology* 11(1): 9-16.

الملخص العربي

التروبونين في الضيق الشديد بالصمام الرئوي هل من المهم قياسه؟

محمد الطحلاوي, محمد مرسى, محمد العوادى و أحمد الدمنهورى

قسم أمراض القلب- كلية الطب- جامعة الزقازيق 44519, الزقازيق- مصر

يعتبر ضيق الصمام الرئوي من أكثر عيوب القلب الخلقية. وقد أصبح توسيع الصمام الرئوي بالبالون هو العلاج الأمثل للمرضى الذين يعانون من ضيق شديد بالصمام الرئوي وفي جميع الفئات العمرية.

دراسة العلاقة بين مستوى التروبونين و الضيق الخلقى الشديد في الصمام الرئوي هناك حاجة إلى معلومات بخصوص الخصائص التحليلية لمقاييسات التروبونين القلبية المستخدمة في الدراسات قبل السريرية والتي يتم تطبيقها عادةً على نماذج حيوانية بناءً على المعرفة الشاملة للعديد من الدراسات في اخر عقدين.

نهدف لدراسة الحالية إلى تقييم العلاقة بين المرقم الحيوي لتروبونين وشدة تضيق الصمام الرئوي بحيث تضمنت المرضى المصابين بضيق شديد بالصمام الرئوي د. (PS) وشاركت المجموعة السليمة الضابطة الاصحاء. وقد تم عمل قياس نسبة التروبونين للمرضى و الأشعة التليفزيونية على القلب وتقييم درجة تضيق الصمام الرئوي وتقييم وظائف البطين الايمن كما تم عمل توسيع الصمام الرئوي بتقنية البالون الواحد عن طريق القسطرة لكل المرضى.

وقد شملت الدراسة 36 مريض مصابون بضيق شديد بالصمام الرئوي. اوضحت الدراسة وجود ارتباط ذات دلالة احصائية قوية بين ارتفاع معدل التروبونين و الضيق الشديد بالصمام الرئوي الذى انخفض بطريقه ملحوظه بعد اسبوعين من توسيع الصمام الرئوي بالبالون كما اوضحت الدراسة وجود ارتباط كبير بين ارتفاع معدل التروبونين ودلالات اعتلال الوظائف الانبساطيه للبطين الايمن.

اوضحت الدراسة زيادة مستوى التروبونين في المرضى الذين عانوا من ضيق شديد بالصمام الرئوي و الذي تناسب ايجابيا مع مقدار فرق الضغط خلال الصمام الرئوي مع وجود اعتلال بوظائف البطين الايمن لذلك يجب استخدام التروبونين كمؤشر للضيق الشديد بالصمام الرئوي مع اعتلال الوظائف الانبساطيه للبطين الايمن في البشر. الحيوانات والبشر سوف يستفيدون من علاج ضيق الصمام الرئوي بتقنية البالون كما في دراستنا ودراسات اخري تم عملها علي حيوانات مصابة بضيق في الصمام الرئوي.