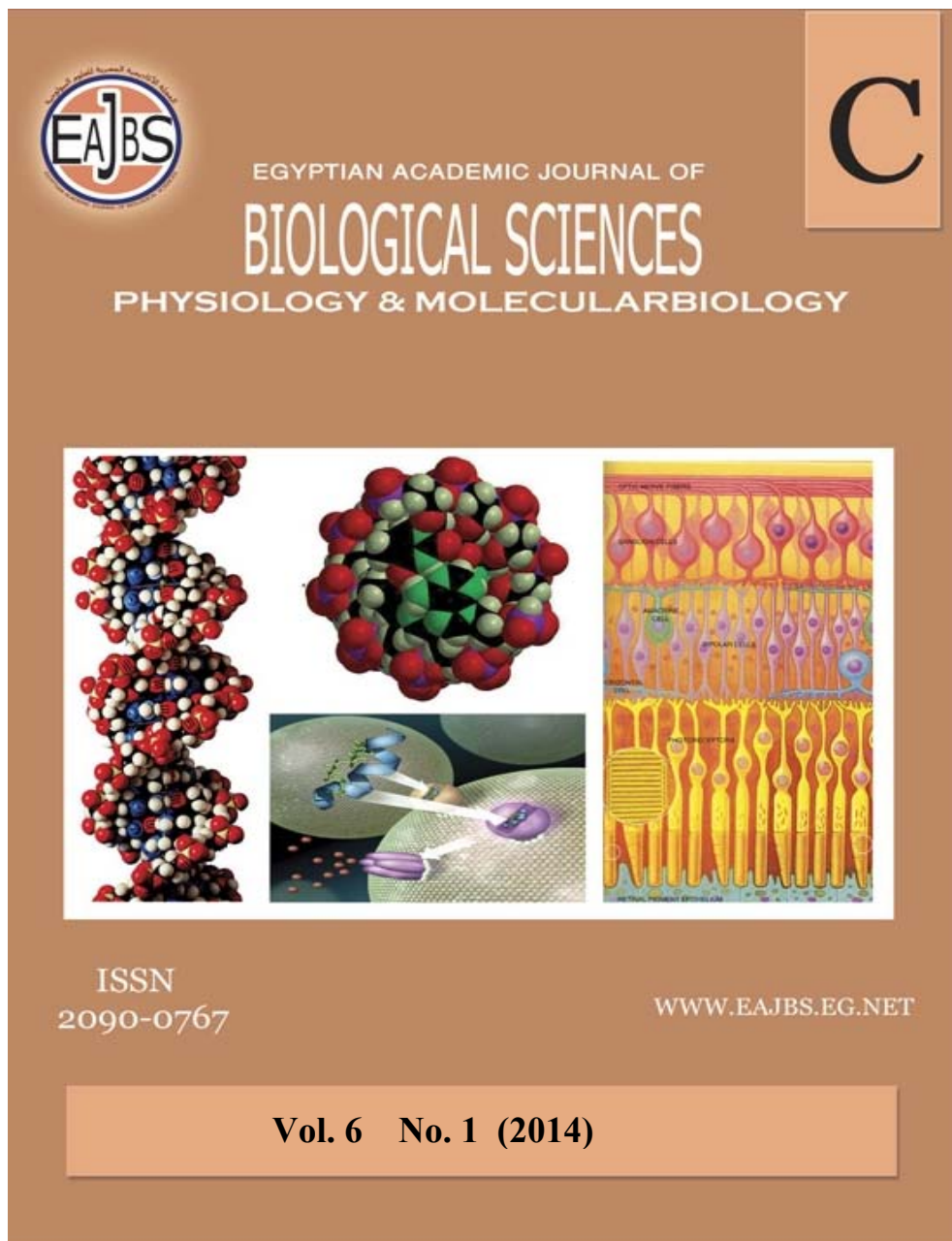


**Provided for non-commercial research and education use.  
Not for reproduction, distribution or commercial use.**



Egyptian Academic Journal of Biological Sciences is the official English language journal of the Egyptian Society for Biological Sciences, Department of Entomology, Faculty of Sciences Ain Shams University.

Physiology & molecular biology journal is one of the series issued twice by the Egyptian Academic Journal of Biological Sciences, and is devoted to publication of original papers that elucidate important biological, chemical, or physical mechanisms of broad physiological significance.

[www.eajbs.eg.net](http://www.eajbs.eg.net)



**The curative effect of Bee Venom and Propolis on oxidative stress induced by  $\gamma$ -irradiation on blood and tissues of rats**

**Abd-Elraheim A. Elshater<sup>1</sup>; Mouchira M. Mohi Eldin<sup>2</sup>; Muhammad M. A. Salman<sup>3</sup> and Naglaa R. A. Kasem<sup>4</sup>**

<sup>1,3,4</sup>Zoo Department, Faculty of Science; <sup>2</sup>Pathology and Clinical Pathology Department, Faculty of Vet. Med., South Valley University, Qena, 83523

**ARTICLE INFO**

**Article History**

Received: 3/2/2014

Accepted: 30/3/2014

Available online:

**Keywords:**

Bee Venom

Propolis

Oxidative stress

$\gamma$ -irradiation

Rats

**ABSTRACT**

The biological effects of ionizing radiation result in the formation of free radicals which are the main cause of cellular damage. This study was aimed to detect the curative effect of some antioxidants drugs (Bee venom and Propolis) on the hematological, biochemical and histological parameters after exposed to  $\gamma$ -irradiation on the rats. Five groups of adult male albino rats were established (n= 11). The first group (Gp. 1) was served as normal group. Gp. 2 was exposed the whole body of rats to a single shot dose of gamma radiation (5Gy) and served as control group. Gp. 3 was injected intraperitoneal (i.p.) daily with Bee venom at dose (5ml/kg body weight). Gp. 4 was given orally Propolis daily at dose 300 mg/kg body weight (B.wt). Gp. 5 was administered of (5ml/kg body weight) of Bee venom injected i.p. plus orally 300 mg/kg (B.wt) of Propolis, daily. All groups were treated after 8 hours exposure, for 40 day. Whole blood, serum and biopsy from liver and kidneys were collected for hematological, biochemical and histopathological examinations, respectively. In the irradiated group (gp. 2), hematotoxicity was determined by a significant decrease in red blood cells (RBCs), white blood cells (WBCs), blood Platelets (PLTs), haemoglobin (Hb) and PCV value, as well as there are an elevation in serum ALT, AST, ALP, LDH, creatinine and urea, associated with reduction in albumin and uric acid. Hepatotoxicity was recorded in a highly significant increase malondialdehyde (MDA) with marked reduction in glutathione (GSH) levels, superoxide dismutase (SOD) and catalase (CAT) activities. In addition to, degenerative and necrotic changes showed in liver and kidneys. It could be concluded that Bee venom and Propolis, clarified a modulatory role against the cellular damage produced by free radicals induced by ionizing radiation.

**INTRODUCTION**

Human on earth exposed to radiation either natural background radiation or some of the population has the occasional medical or dental X- ray (Stevenson, 2001). Ionizing radiations caused damage of the cells directly by ionization of DNA and other cellular targets and indirectly through Reactive Oxygen Species (ROS), which cause disruption of membrane lipids leading to subsequent formation of peroxide radicals (Rajapakse *et al.*, 2007). Oxidative stress is not only a consequence of chronic liver injury but it contributes to fibrogenesis and it appears as a key player in the pathogenesis of hepatic diseases (Coussens and Werb, 2002).

The cell membrane permeability is disturbed following irradiation as exhibited by changes in tissue ionic contents of Na and K (Nabila and Azza, 2005). Natural antioxidants play a recent source of protection against  $\gamma$ -radiation (Gerber *et al.*, 2002). Diet-derived antioxidants have been reported to decrease free radical attack on biomolecules and diminishing cumulative oxidative damage (Saada and Azab, 2001). The medicinal use of honey bee products (apitherapy) used since ancient times. It was producing a greatest number of biological effects used in experimental pharmacology (Mohd *et al.*, 2011).

Recent studies reported that Bee venom possesses antimutagenic, (Varanda *et al.*, 1999) proinflammatory, (Sumikura *et al.*, 2003) anti-inflammatory, (Nam *et al.*, 2003) antinociceptive, (Kim *et al.*, 2003) and anticancer effects (Orsolich *et al.*, 2003). Bee venom is demonstrated to have a radio-protective effect against basal and oxidative DNA damage in Wistar rat lymphocytes (Gajski and Garaj-Vrhovac, 2009). Propolis is often referred to as "bee glue." It is a mixture of resin, essential oils and waxes, and also contains amino acids, minerals, ethanol, vitamin A, B complex, E, and flavonoids which responsible for the biological and antioxidant activity and this is a principally based on their radical scavenging effect (Kumazawa *et al.*, 2010).

The aim of this work was to highlight on the curative effect of some antioxidants (Bee venom and Propolis) on the hematological, biochemical and histological parameters after exposed to  $\gamma$ -irradiation on the rats.

## MATERIALS AND METHODS

### Animals:

This experiment was carried out on fifty male albino rats at aged of 4-5 months, and weighted about (250-280 g).

The animals were obtained from the animal house, Faculty of Medicine, Assuit University, Egypt. The animals were housed in the animal house of the Faculty of Science, South Valley University, Qena, Egypt. The rats were divided into five groups housed in controlled suitable plastic cages with separate bottom and kept at room temperature and fed on balanced stable commercial diet for drinking tap water was provided ad libitum.

### Radiation Facility:

Animals were placed in a specially designed well-ventilated acrylic container and the whole body of the animals were exposed to 5 Gy as a single shot dose, given at a dose rate of 0.84 Gy/min from the biological irradiator gamma cell-40, cesium-137 source (Atomic Energy Agency, Canada Limitd, AECL), belonging to National Center for Radiation Research and Technology (NCRRT), Cairo (Rehab and Ibrahim, 2012).

### Bee venom:

Lypholized Apis Mellifera purified Bee venom (VACSERA, Egypt, 1mg/vial) was used. It was injected intraperitoneal at dose 5ml/kg according to (Nahed and Amany, (2010).

### Propolis:

Propolis was purchased from Agricultural Research Centre (ARE). Extraction of PEE was carried out according to the method of Boeru and Derevici, (1978).

### Experimental design:

The animals were randomly assigned into 5 groups (10 rats for each group). The first ten rats were separated for group1, which were injected i.p. with 0.9% isotonic saline solution at a dose (10 ml/kg b.wt) and used as normal group. All remaining animals were irradiated with one shot dose (5 Gy/ rat) and divided into four groups (gps. 2, 3, 4 & 5). Group 2, irradiated rats were injected intraperitoneal (i.p.) with 0.9% isotonic saline solution at a dose (10

ml/kg b.wt) and used as control group. Group 3, irradiated animals were injected intraperitoneal (i.p.) with Bee venom (5ml/kg b.wt) daily. Group 4, irradiated animals were orally administered with Propolis ethyl extract (300 mg/kg body weight) daily. Group 5, irradiated animals were daily injected intraperitoneal (i.p.) with Bee venom (5ml/kg b.wt), following with oral administration of Propolis ethyl extract (300 mg/kg b.wt) daily. Gps 3, 4 & 5 were treated with drugs after exposed to irradiation with 8 hours, daily and the experiment were continuous for 40 days. All animals were sacrificed at the end of the experiment.

#### **Blood collection:**

The blood were collected from all animals and divided into two portions, one portion was taken in EDTA containing tubes and used for hematological examination. The other portion of blood was left in clean tubes at room temperature to clot, after an hour, then serum was separated by centrifugation for 30 minutes at 3000 rpm. The sera were collected in labeled epindorff's tubes and stored at - 20 °C until used for biochemical analysis. A part of right lobe of liver was dissected and washed with physiological saline solution, dried, weighed and homogenized in phosphate buffer (pH7.4) and kept frozen until used for biochemical assays.

#### **Hematological analysis:**

The hematological evaluation consisted of erythrocytes (RBCs), white blood cells (WBCs), platelets (PLT) counts and Hb content, determination by Automated Hematology Analyzer (Diff3) Mek-6410/Mek-6420.

#### **Biochemical analysis:**

ALT and AST were determined by colorimetric method which described by Reitman and Frankel (1957). ALP was measured according to the method of (Belfield and Goldberg, 1971). Albumin was determined by the colorimetric method which described by Dumas *et*

*al.* (1971). LDH was measured according to the colorimetric method which described by Friedman and young, (1997). Creatinine was determined by colorimetric method which described by Bartles *et al.* (1972). Urea was determined by Fawcett and Scott (1960). Uric acid was determined by enzymatic colorimetric method which described by Barham and Trinder (1972).

In the liver homogenate, reduced glutathione (GSH) was determined by colorimetric method described by Beutler *et al.* (1963), CAT was determined by colorimetric method described by Aebi (1984), SOD was determined by colorimetric method described by Nishikimi *et al.* (1972) and determination of MDA was carried out according to the method of Ohkawa *et al.* (1979).

#### **Histopathological examination:**

Specimens from liver and kidneys of all treated and control rats were collected and fixed in 10% neutral buffered formalin solution and embedded in paraffin wax. Sections of about 5  $\mu$ m thickness were prepared and stained with haematoxylin and eosin for examination.

#### **Statistical analysis:**

The results are expressed as mean  $\pm$  S.E. The means comparisons were made by using one-way analysis of variance (ANOVA) using Graph Pad Prism 03n software. Statistical significance was set at  $p < 0.05$ .

## **RESULTS**

#### **Hematological indices:**

Exposure of rats to  $\gamma$ -radiation resulted in a highly significant decrease in RBCs count, WBCs count, platelets count, Hb concentration and PCV value at ( $p < 0.01$ ) when compared with the normal animals. These results were recorded in Table (1). Daily treatment with Bee venom, there were a significant increase ( $p < 0.05$ ) in RBCs count, WBCs count, platelets count, Hb concentration and PCV value when compared with control animals (gp 2) but it was not

reach to normal animals (gp 1). Propolis and Propolis plus Bee venom treatment for 40 days shows highly increase at ( $p < 0.01$ ) in RBCs count, WBCs count, platelets count, Hb concentration and PCV value when compared with control animals, but a significant improvements were recorded almost near to normal values when compared with normal animals.

Table 1: Effect Bee venom, Propolis and Propolis plus Bee venom for 40 days of treatment after a single whole body dose of gamma radiation on hematological parameters (RBCs, WBCs, Platelets count, Hb concentration and PCV value) in males of Albino rats.

Groups	RBCs count ( $\times 10^6 / \text{mm}^3$ )	WBCs count ( $\times 10^3 \text{ mm}^3$ )	Hb concn. (g/dL)	Platelets count ( $\times 10^3 \text{ mm}^3$ )	CV (%)
	Mean $\pm$ S.D.	Mean $\pm$ S.D.	Mean $\pm$ S.D.	Mean $\pm$ S.D.	Mean $\pm$ S.D.
Normal	7.22 $\pm$ 0.33	8.04 $\pm$ 0.54	12.93 $\pm$ 0.63	509.0 $\pm$ 32.17	37.88 $\pm$ 1.64
Control	4.08 <sup>-a</sup> $\pm$ 0.28	5.38 <sup>-a</sup> $\pm$ 0.56	8.64 <sup>-a</sup> $\pm$ 0.62	277.3 <sup>-a</sup> $\pm$ 30.85	23.28 <sup>-a</sup> $\pm$ 1.21
Bee venom	5.17 <sup>-a +b</sup> $\pm$ 0.45	6.53 <sup>-a +b</sup> $\pm$ 0.67	10.39 <sup>-a +b</sup> $\pm$ 0.59	388.5 <sup>-a +b</sup> $\pm$ 25.69	29.91 <sup>-a +b</sup> $\pm$ 1.89
Propolis	6.11 <sup>-a +b</sup> $\pm$ 0.41	7.63 <sup>-a +b</sup> $\pm$ 0.55	11.15 <sup>-a +b</sup> $\pm$ 0.73	473.9 <sup>-a +b</sup> $\pm$ 45.94	31.30 <sup>-a +b</sup> $\pm$ 1.58
Propolis + Bee venom	5.95 <sup>-a +b</sup> $\pm$ 0.32	7.43 <sup>-a +b</sup> $\pm$ 0.75	10.99 <sup>-a +b</sup> $\pm$ 0.93	468.9 <sup>-a +b</sup> $\pm$ 42.26	31.30 <sup>-a +b</sup> $\pm$ 2.13

Results are expressed as mean  $\pm$  S.D. of 10 animals for each group.

-a = highly significant decreased compared with normal at  $p < 0.01$

+b = significantly increased compared with control at  $p < 0.05$ .

--a = highly significant decreased compared with normal at  $p < 0.01$ .

++b = highly significant increased compared with control at  $p < 0.01$ .

### Biochemical analysis

#### Liver function enzymes:

Results in Table (2) indicated that, exposed whole body to a single dose of gamma radiation, induced a highly significant increase at ( $p < 0.01$ ) in serum

ALT, AST, ALP and LDH activities as compared with the corresponding normal values. It induced also a highly significant decrease at ( $p < 0.01$ ) in serum Albumin level when compared with normal level.

Table 2: Effect of Bee venom, Propolis and Propolis plus Bee venom for 40 days of treatment after a single whole body dose of gamma radiation on serum levels of AST, ALT, ALP, Albumin and LDH in blood of males Albino rats.

Groups	ALT (Units/ml)	AST (Units/ml)	Albumin (g/dL)	ALP (IU/L)	(U/L)
	Mean $\pm$ S.D.	Mean $\pm$ S.D.	Mean $\pm$ S.D.	Mean $\pm$ S.D.	Mean $\pm$ S.D.
Normal	61.84 $\pm$ 1.14	76.66 $\pm$ 1.22	3.49 $\pm$ 0.23	42.04 $\pm$ 1.24	92.4 $\pm$ 2.02
Control	110.4 <sup>++a</sup> $\pm$ 2.26	124.2 <sup>++a</sup> $\pm$ 1.35	1.63 <sup>--a</sup> $\pm$ 0.32	109.2 <sup>++a</sup> $\pm$ 4.01	220.7 <sup>++a</sup> $\pm$ 7.31
Bee venom	91.94 <sup>++a -b</sup> $\pm$ 1.34	92.12 <sup>++a -b</sup> $\pm$ 1.52	2.05 <sup>--a +b</sup> $\pm$ 0.34	76.37 <sup>++a -b</sup> $\pm$ 1.67	179.7 <sup>++a -b</sup> $\pm$ 2.65
Propolis	73.81 <sup>++a --b</sup> $\pm$ 2.37	84.47 <sup>++a --b</sup> $\pm$ 1.43	2.97 <sup>-a +b</sup> $\pm$ 0.41	54.07 <sup>++a --b</sup> $\pm$ 1.96	119.8 <sup>++a --b</sup> $\pm$ 4.14
Propolis + Bee venom	74.70 <sup>++a --b</sup> $\pm$ 1.38	87.16 <sup>++a --b</sup> $\pm$ 1.91	2.96 <sup>-a +b</sup> $\pm$ 0.31	64.04 <sup>++a --b</sup> $\pm$ 1.98	121.9 <sup>++a --b</sup> $\pm$ 4.06

Results are expressed as mean  $\pm$  S.D. of 10 animals for each group.

+a = significantly increased compared with the normal at  $p < 0.05$ .

++a = highly significantly increased compared with the normal at  $p < 0.01$ .

-a = highly significant decreased compared with normal at  $p < 0.01$ .

--a = highly significant decreased compared with normal at  $p < 0.01$ .

+b = significantly increased compared with control at  $p < 0.05$ .

++b = highly significant increased compared with control at  $p < 0.01$ .

-b = significantly decreased compared with control at  $p < 0.05$ .

--b = highly significant decreased compared with control at  $p < 0.01$ .

After oral administration of Bee venom treatments for 40 days, there were a significant decrease at ( $p < 0.05$ ) in serum ALT, AST, ALP and LDH activities when compared with control animals and there was a significant increase at ( $p < 0.05$ ) in Albumin level as compared with control animals.

Propolis and Propolis plus Bee venom treatment for 40 days showed a highly significant decrease at ( $p < 0.01$ ) in serum ALT, AST, ALP and LDH activities comparing with control animals, this decrease was showed marked improvements nearly reachable to normal levels. While serum Albumin level highly significant increased comparing with control animals level as well as, this increase in Albumin level was nearly reachable to normal levels.

**Renal function enzymes:**

Urea and creatinine levels in serum of the irradiated groups showed a highly

significant increase at ( $p < 0.01$ ) when compared with the normal group. It also induce a highly significant decrease at ( $p < 0.01$ ) in serum of uric acid level comparing with normal level. Those findings recorded in Table (3). Treated groups of Bee venom and Propolis plus Bee venom showed a significant decreases at ( $p < 0.05$ ) in serum creatinine and urea levels while serum uric acid level shows a significant increase at ( $p < 0.05$ ) comparing to control animals. The result recorded a remarkable improvement, comparing with normal animals. Oral doses of Propolis treatment induced a highly significant decrease in serum creatinine and urea levels, while serum uric acid level showed a highly significant increase comparing with control level. These results were approached to the normal level.

Table 3: Effect of Bee venom, Propolis and Propolis plus Bee venom for 40 days of treatment after a single whole body dose of gamma radiation on serum levels of creatinine, urea and uric acid in blood of male Albino rats.

Groups	Creatinine (mg/dL)	Urea (mg/dL)	Uric acid (mg/dL)
	Mean $\pm$ S.D.	Mean $\pm$ S.D.	Mean $\pm$ S.D.
Normal	0.41 $\pm$ 0.04	19.55 $\pm$ 0.715	4.18 $\pm$ 0.43
Control	0.94 <sup>++a</sup> $\pm$ 0.03	65.13 <sup>++a</sup> $\pm$ 1.917	1.42 <sup>--a</sup> $\pm$ 0.38
Bee venom	0.71 <sup>++a-b</sup> $\pm$ 0.05	45.92 <sup>++a-b</sup> $\pm$ 3.258	1.76 <sup>--a+<sup>b</sup></sup> $\pm$ 0.43
Propolis	0.58 <sup>+a--b</sup> $\pm$ 0.05	25.50 <sup>+a--b</sup> $\pm$ 0.759	3.19 <sup>-a+<sup>++b</sup></sup> $\pm$ 0.33
Propolis + Bee venom	0.61 <sup>+a-b</sup> $\pm$ 0.03	28.87 <sup>+a-b</sup> $\pm$ 2.113	2.95 <sup>-a+<sup>b</sup></sup> $\pm$ 0.24

Results are expressed as mean  $\pm$  S.D. of 10 animals for each group

- +a = significantly increased compared with the normal at  $p < 0.05$ .
- ++a = highly significantly increased compared with the normal at  $p < 0.01$ .
- a = significant decreased compared with normal at  $p < 0.05$ .
- a = highly significant decreased compared with normal at  $p < 0.01$ .
- +b = significantly increased compared with control at  $p < 0.05$ .
- ++b = highly significant increased compared with control at  $p < 0.01$ .
- b = significantly decreased compared with control at  $p < 0.05$ .
- b = highly significant decreased compared with control at  $p < 0.01$ .

**Liver homogenate biochemical enzymes:**

**Lipid peroxidation and liver antioxidant enzyme activities:**

Exposure of rats to  $\gamma$ -radiation resulted in a highly significant increase at ( $p < 0.01$ ) in Malondialdehyde (MDA) level, with marked reduction in GSH, CAT and SOD activities when compared with

normal animals. These results were recorded in Table (4). Bee venom and Propolis plus Bee venom daily treatment doses induced a significant decrease at ( $p < 0.05$ ) in MDA, associated with significant increase in GSH, CAT and SOD of Bee venom treated, while Propolis plus Bee venom recorded a highly significant increase in GSH, CAT and SOD activities comparing with corresponding level of control animals.

These result showed a remarkable change comparing with normal animals. Oral doses of Propolis showed a highly significant decrease at ( $p < 0.01$ ) in Malondialdehyde (MDA) level, with marked a highly significant increase in GSH, CAT and SOD activities comparing with control levels but these results recorded a remarkable improvement comparing with normal animals.

Table 4: Effect of Bee venom, Propolis and Propolis plus Bee venom for 40 days of treatment after a single whole body dose of gamma radiation on Malondialdehyde (MDA), reduced glutathione (GSH), catalase (CAT) and superoxide dismutase (SOD) activities in liver tissue of male Albino rats.

Groups	MDA (n mol/g. tissue)	GSH (mmol/g. tissue)	CAT (U/g)	SOD (U/g. tissue)
	Mean $\pm$ S.D.	Mean $\pm$ S.D.	Mean $\pm$ S.D.	Mean $\pm$ S.D.
Normal	54.2 $\pm$ 1.53	1.79 $\pm$ 0.074	1.84 $\pm$ 0.078	264.5 $\pm$ 3.5
Control	109.9 <sup>+++</sup> $\pm$ 5.09	0.73 <sup>-a</sup> $\pm$ 0.059	0.84 <sup>---a</sup> $\pm$ 0.11	215.7 <sup>---a</sup> $\pm$ 7.6
Bee venom	82.5 <sup>+++ -b</sup> $\pm$ 4.11	1.13 <sup>---a +b</sup> $\pm$ 0.044	1.01 <sup>---a +b</sup> $\pm$ 0.048	232.3 <sup>---a +b</sup> $\pm$ 2.3
Propolis	60.2 <sup>++a ---b</sup> $\pm$ 1.68	1.52 <sup>-a +++</sup> $\pm$ 0.049	1.58 <sup>-a +++</sup> $\pm$ 0.096	255.1 <sup>-a +++</sup> $\pm$ 2.2
Propolis + Bee venom	62.6 <sup>++a -b</sup> $\pm$ 2.57	1.49 <sup>-a +++</sup> $\pm$ 0.041	1.54 <sup>-a +++</sup> $\pm$ 0.055	251.3 <sup>-a +++</sup> $\pm$ 1.5

Results are expressed as mean  $\pm$  S.D. of 10 animals for each group.

+a = significantly increased compared with the normal at  $p < 0.05$ .

+++ = highly significantly increased compared with the normal at  $p < 0.01$ .

-a = significant decreased compared with normal at  $p < 0.05$ .

---a = highly significant decreased compared with normal at  $p < 0.01$ .

+b = significantly increased compared with control at  $p < 0.05$ .

+++b = highly significant increased compared with control at  $p < 0.01$ .

-b = significantly decreased compared with control at  $p < 0.05$ .

---b = highly significant decreased compared with control at  $p < 0.01$ .

### Pathological findings:

The liver in group (1) displayed normal hepatic lobules with normal architecture in the hepatic cells (Fig. 1). Vacuolar and hydropic degenerations in the hepatic cells with focal areas of necrosis leaving hallow areas showed in most liver of the rats which are radiated in gp. 2 (Figs 2& 3). Focal areas of necrotic debris with some inflammatory cells and red blood cells appeared among the other degenerated cells in gp. 3 (Fig.4). Regenerative changes showed in some of the hepatic cells with congestion in blood sinusoids in the liver of the rats which received Propolis in gp. 4 (Fig. 5). Most of hepatic cells in the rats which

received Propolis plus Bee venom showed focal areas of inflammatory cells with regeneration in most of hepatic cells in gp 5. (Fig.6). The regenerated cells characterized with division in the nucleus inside the regenerated cells with few round cells.

Kidneys (cortex and medulla) of group (1) seen in the normal structure (Fig. 7). Edema inside the Bowman's space causing severe pressure atrophy in the glomeruli cells with accumulation in the proteinase substances with cells debris adhered to the visceral layers of Bowman's capsule, besides congestion in the glomerular capillaries noticed in the radiated rats in gp. 2 (Fig. 8). Necrosis

with severe destruction showed in the renal epithelial cells in the lumen of tubules resulting in renal casts in all convoluted and collecting tubules in cortex and medulla. Medulla in kidneys showed highly distention in the lumen of the collecting tubules induced fattening in the epithelial cells appeared as cystic shape, besides distinct leukocytic cells infiltration mainly macrophages and cell debris among tubules (Fig. 9). Most rats which were treated with Bee venom in (gp. 3) showed slight congestion in the glomerular and renal blood vessels, besides some regeneration detected in some of renal tubular cells (Fig. 10). Meanwhile, the rats which were treated with Propolis showed aggregation with the mononuclear cells among the destructed collecting tubules, besides renal casts (Fig. 11). Meanwhile, mixture of Propolis plus Bee venom in group (5) was manifested by regeneration in most of the epithelial lining of the renal tubules. Focal areas of inflammatory areas replaced the degenerated cells (Fig. 12).

### DISCUSSION

Radiation exposure creates free radicals causing oxidative stress where antioxidant activity declines and lipid peroxidation increases (Nordberg and Arner, 2001). Ionizing radiations induce significant elevation in the physiological and metabolic processes, as well as, disorders in blood biochemical parameters (El-Masry and Saad, 2005) and causing chain reaction of oxidation (Ammar, 2009).

The present study displayed that whole body gamma irradiation (5 Gy) resulting in a highly significant decrease in the number of RBCs, WBCs, PLTs, remarkable fall in Hb and highly significant drop in PCV value, which may be due to alteration in bone marrow as well as hemopoietic system of the animals. Similar observations were obtained by Osman and Hamza (2013).

The decrease in the values of hematological parameters may be assigned to direct damage caused by a lethal dose of radiation (Heda and Bhatia, 1986). The cellular elements of the blood are particularly sensitive to oxidative stress because their plasma membranes contain a high percentage of polyunsaturated fatty acids (PUFA) (Chew and Park, 2004). Therefore, the decrease in WBCs count might be the consequence of radiation-induced lipid peroxidation and damage of their cell membranes. The reduction in total leucocytes count (leucopenia) and decrement of RBC's may be attributed to mitotic inhibition of the bone marrow precursors and/or direct destruction of mature circulation cells (Hassan *et al.*, 1996 and Ramadan, 2007). The observed decline in the total leucocytic count was agreement with El-Deeb *et al.* (2006). The decrease in Hb content was due to changes in erythrocyte membrane emphasizes the formation of free radicals. The effect of free radicals on erythrocyte membrane may contribute to the eventual leak of hemoglobin out of the cells (Hussein *et al.*, 2007). A depression in the hematocrit value can be attributed to total cell depletion in peripheral blood aided by disturbances in steady state mechanisms in blood forming organs as well as an increase in plasma volume after irradiation Nunia and Goyal (2004).

Our study reported that the rats exposed to 5 Gy of  $\gamma$ -radiation, was a highly significant increase in the activities of the serum AST, ALT, ALP and LDH enzymes, while Albumin stated a highly significant decrease post irradiation. The status of these marker enzymes are sensitive indices of hepatocellular necrosis as cell damage results in the leakage of these enzymes into the systemic circulation (Sang *et al.*, 2010). These results are in accordance with other studies (Manal and Abd El Azime, 2013).



The increased levels of AST and ALT could be referred to the drastic dysfunction of the liver cells induced by radiation interaction with cellular membranes and also related to extensive breakdown of liver parenchyma (Kafafy, 2000). The increase in serum ALP reflects the pathological alteration in biliary flow and damage to the liver cell membrane (Nadia, 2013). LDH is released during tissue injury and increases in its reported value usually indicate cellular death and leakage of the enzyme from the cell (McFarland, 1994). In addition, the Albumin decrease could be related in part to hepatic dysfunction and decreased protein synthesis (Saleh, 2011). These phenomena might be, at least partially responsible for protein loss after irradiation.

Elevated creatinine and urea levels were observed in rats exposed to gamma radiation. These results came similar to previous investigations by Abou-Safi (1998). These increments could be considered as a reflection of deteriorating renal performance (Geraci *et al.*, 1990) due to the ammonia formed by deamination of amino acids in the liver which converted to urea (Ganong *et al.*, 1999) or to increased breakdown of nucleic acids (Osman and Hamza, 2013). Since irradiation may cause breaking of DNA molecules and destruction of their bases (the purines) which may be catabolized into uric acid (Ganong *et al.*, 1999). As creatinine is formed largely in muscles and occurs freely in blood plasma and urine, its increased levels in plasma serve as an index of renal function impairment (Frag, 1994).

The present study showed that a single whole body dose of gamma radiation 5 Gray produced marked oxidative impact as evidenced by a highly significant increase in the level of Malondialdehyde (MDA) in liver tissue homogenate as one of the main end products of lipid peroxidation in agreement with (Guney *et al.*, 2004),

associated with a highly significant decrease in the activity of Superoxide dismutase (SOD) in liver tissue, highly significant decrease in Catalase (CAT) of liver tissue while recorded a significant decrease in Glutathione reduced (GSH) were recorded in liver tissue of irradiated rats, these are in agreement with those recorded by Bhatia and Jain (2004). They recorded a significant depletion in the antioxidant system accompanied by enhancement of lipid peroxides after whole body gamma-irradiation. Under normal conditions the inherent defense system, including glutathione and the antioxidant enzymes, protects against oxidative damage. The Antioxidant enzymes, SOD, CAT and GSH compose a set of antioxidant defense against reactive oxygen species (Khan *et al.*, 2009).

Histopathology stated that exposure to irradiation causes injury to blood vessels provoking anoxia of tissues resulting in degeneration and necrosis Kumar *et al.* (2003).

Dietary antioxidants play an important role in mitigating the damaging effects of oxidative stress on cells. According to Son *et al.* (2007) Bee venom increases coronary and peripheral blood circulation, improves the microcirculation of blood in the tissues against blood coagulation fibrinolytic, also stimulates the building of erythrocytes and as a protective agent from radiation by improves regeneration of erythrocytes. The present study found that treatment with BV had significantly decreased the elevation of serum ALT, AST, ALP and LDH levels, indicating the hepato-protective effect of BV, which might be explained by the reduction of elevated hepatic nuclear factor kappaB (NF- $\kappa$ B) expression in liver (Samar *et al.*, 2013). This was further confirmed by histological examination of liver. These results are consistent with other studies that showed the potent hepato-protective effect of BV by inhibiting the secretion

of pro-inflammatory cytokines, and decreasing the elevated serum aminotransferase enzymes in different models of induced hepatic injury (Park *et al.*, 2010). The present study found that kidneys function including urea and creatinine decreased while uric acid increased following Bee venom treatment. Clark *et al.* (1999) and Hyunseong *et al.* (2013) they found that BV has protective effects on renal tubular injury (epithelial necrosis). The present results recorded that a significant decrease of MDA in liver tissue, associated with a significant increase SOD, CAT and GSH activities in liver tissue (Abdel-Rahman *et al.*, 2013). Stanley *et al.* (1984) found that Bee venom inhibits production of superoxide anion by human neutrophils. Rain (2009) and Hegazi (2012) stated that BV therapy is a potent antioxidant led to a decrease in the levels of reactive oxygen species (ROS), which may be associated with the observations of BV affecting glutathion, superoxide dismutase (SOD) and catalase.

On the other hand, group of rats administered Propolis showed a significant improvement of RBCs count, WBCs, Hb, Platelets and PCV %. Propolis induced extensive proliferation of hematopoietic cells in the spleen and bone marrow (Orsolich and Basic, 2005). Moreover, it improves the digestive utilization of iron and increases the regeneration efficiency of hemoglobin especially during recovery from an anemic syndrome (Haro *et al.*, 2000). In addition, the high content of flavonoids in Propolis improves and accelerates the generation of erythrocyte and hemoglobin (Dong *et al.*, 2005). The current results showed a pronounced decrease in the activities of serum AST, ALT, ALP and LDH and a pronounced increase in Albumin compared to irradiated group, indicating that Propolis tended to prevent the damage and suppressed the leakage of enzymes

through cellular membranes. This result is in accordance with Newairy and Abdou (2013), that was an indication of stabilization of plasma membrane as well as repairment of hepatic tissue damage that can be considered as an expression of the functional improvement of the hepatocytes (Nirala and Bhadauria, 2008). Highly significant reduction of serum urea and creatinine levels was noticed after administration of aqueous Propolis extract group compared to control group. These results may indicate that Propolis can attenuate renal damage by decreasing the concentrations of urea and creatinine as previously reported (Abo-salem *et al.*, 2009) This effect is probably due to the antioxidant protective effect of Propolis which could have accumulated in the cells of the proximal convoluted tubule of the kidney where Propolis was reported to be collected and secreted (Sun *et al.*, 2000). Caffeic acid phenethyl ester (CAPE), a biological active component of Propolis was found to improve renal function tests in rat (Oktem *et al.*, 2005). Also, treatment with Propolis caused reduction in thiobarbituric acid reactive substances (TBARS) level and increased the activities of SOD and CAT and the level of GSH in liver tissue. These data are in agreement with the results obtained by Jasprica *et al.* (2007) who reported that Propolis caused reduction in the malondialdehyd (MDA) level and increased the activities of the antioxidant enzymes (SOD and CAT). Furthermore, Sobocanec *et al.* (2006) reported that Propolis increased the activity of CAT. Therefore, the flavonoids of the Propolis can increase the activities of the antioxidant enzymes and reduce the levels of the ROS. Kanbur *et al.* (2009) found decreases in the plasma and the liver tissue malondialdehyde (MDA) levels and normalization in the antioxidant enzyme parameters (SOD, CAT and GSH) of animals that were administered Propolis may be considered

as a protective mechanism against free radical production and lipid peroxidation (Eman, 2012). Other studies demonstrated the mechanisms responsible for the antiradical and antioxidant activities of Propolis, in a trial conducted by Matsushige *et al.* (1995).

It could be concluded that exposure to gamma radiation, led to impairment of liver and kidney functions. Moreover, either Propolis, or Bee venom alone or combined as a antioxidant drug results in suppression to the adverse effect caused by gamma radiation, but Propolis causing a faster regeneration than Bee venom noticed in most of tissues of the gamma radiated exposed rats.

#### REFERENCES

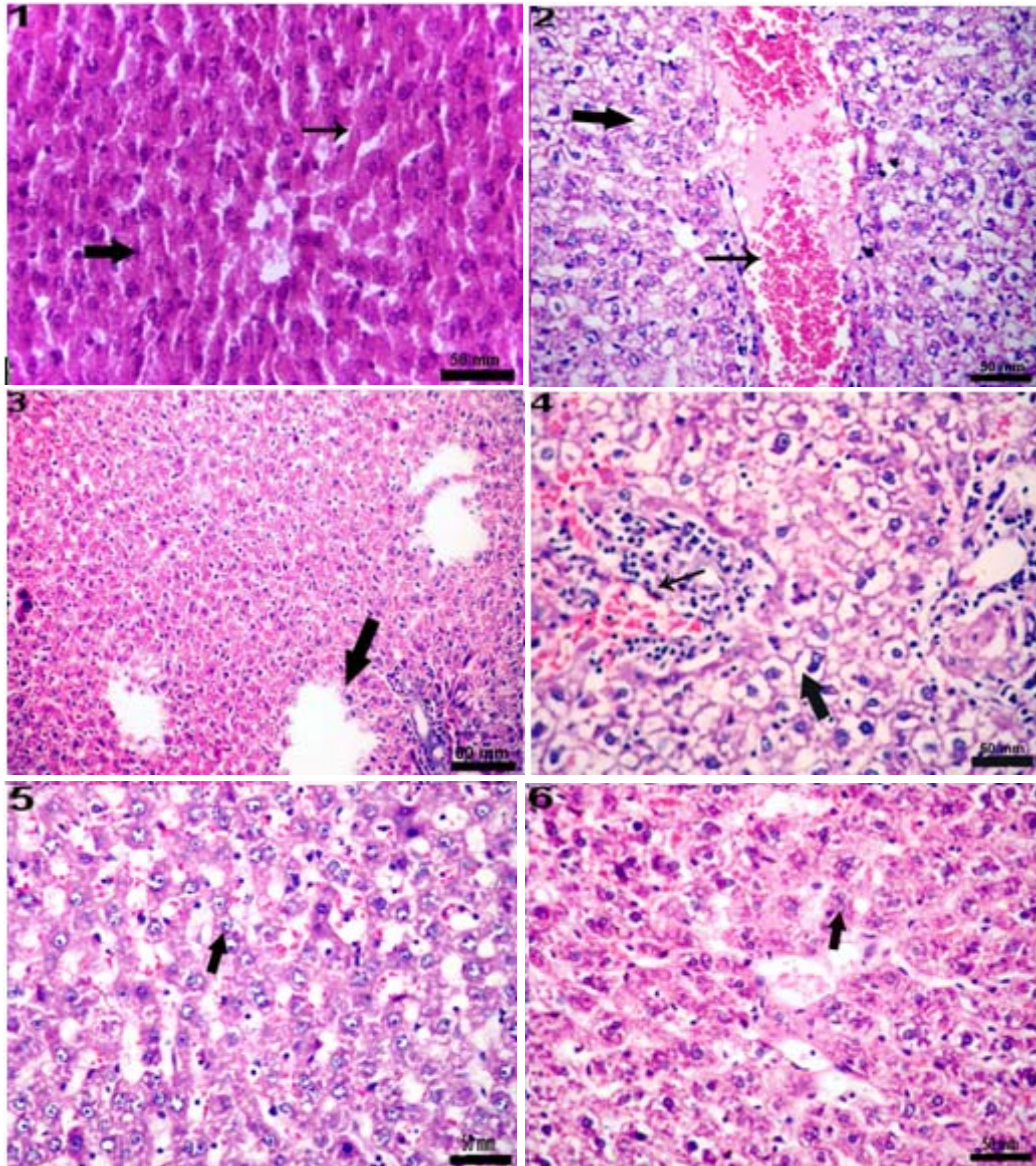
- Abdel-Rahman, M. 1; Elebiary, A. S.; Hafez, S. S.; Mohammed, H. E. and Abdel Moneim, A. E. (2013): Therapeutic activity of bee-stings therapy in rheumatoid arthritis causes inflammation and oxidative stress in female patients. *Int. J. Res. Ayurveda. Pharm.*, 4 (3): 316-321.
- Abo-Salem, O. S.; El-Edel, R. H.; Haeis, G. I.; Nermeen, El. D. and Ghonaime, M. M. (2009): Experimental diabetic nephropathy can be prevented by propolis: Effect on metabolic disturbances and renal oxidative parameters. *J. Pharm., Sci.*, 22 (2): 205-210.
- Abou-Safi, H., M. (1998): Physiological impairment of irradiation drugs estrus cycle in rats and role of combined treatment with vitamins A and B group. *Egypt. J. Med. Sci.*, 19 (1): 157.
- Aebi, H. (1984): Catalase. In: L. Packer(Ed), *Methods in Enzymology*. Academic. Pres., Orlando, 105: 121-126.
- Ammar, A. A. (2009): Evaluation of the protective role of wheat germ oil in irradiated rats. *Isotope and Rad. Res.*, 41: 911-920.
- Barham, D. and Trinder, P. (1972): An improved colour reagent for the determination of blood glucose by the oxidase system. *Analyst*, 97: 142-145.
- Bartels, H.; Bohmer, M. and Heirli, C. (1972): Estimation of creatinine clearance in patients with unstable renal function. *Clin. Chim. Acta.*, 37:173.
- Belfield, A. and Goldberg, D. M. (1971): Colorimetric determination of alkaline phosphatase activity. *Enzyme*, 12: 561-573.
- Beutler, E.; Duron, O. and Kelly, B. M. (1963): Improved method for the determination of blood glutathione. *J. Lab. Clin. Med.*, 61: 882-888.
- Bhatia, A. L. and Jain, M. (2004): *Spinacia oleracea* L. protects against gamma radiations, a study on glutathione and lipid peroxidation in mouse liver. *Phytomed.*, 11(7-8): 607-615.
- Boeru, V. and Derevici, A. (1978): Some chemical and physical data on Romanian propolis. *Apimondia "propolis*. Bucharest., pp.19-26.
- Chew, B. and Park, J. (2004): Carotenoid action on the immune response. *J. Nutr.*, 134: 257S-261S.
- Clark, C.; Gordon, R.; Harris, B. and Helvie, C. (1999): *Encyclopedia of Complementary Health Practice*. Springer., ISBN: 0-8262: 1237-4.
- Coussens, M. and Werb, Z. (2002): Inflammation and cancer. *Nat.*, 420: 860-867.
- Dong, L. W.; Wang, W. Y.; Yue, Y. T. and Li, M. (2005): Effects of flavones extracted from *Portulaca oleracea* on ability of hypoxia tolerance in mice and its mechanism. *Zhong. Xi. Yi. Jie. He. Xue. Bao.*, 3(6): 450-454.
- Doumas, B. T.; Watson, W. A. and Biggs, H. G. (1971): Albumin standards and the measurement of serum albumin with bromocresol green. *Clin. Chim. Acta.*, 31: 87-96.

- El-Deeb, A. E.; Abd El-Aleem, I. M. and Abd El-Rahman, A. A. (2006): The curative effect of some antioxidants on  $\gamma$ -irradiated rats. *J. Egypt. Soc. Toxicol.*, 35: 79-89.
- El-Masry, F. S. and Saad, T. M. (2005): Role of selenium and vitamin E in modification of radiation disorders in male albino rats: Isotope and *Rad. Res.*, 37 (5): 1261-1273.
- Eman, M. S. (2012): Antioxidant effect of aqueous extract of propolis on hepatotoxicity induced by octylphenol in male rats. *Acta. Toxicol. Argent.*, 20 (2): 68-81.
- Farag, M. H. (1994): Upgrading whole someness of soybeans through radiation deactivation of toxic lectin content. *Egypt. J. Rad. Sci. Applic.*, 7 (1): 99.
- Fawcett, J. K. and Scott, J. E. (1960): Enzymatic determination of urea. *J. Clin. Path.*, 13: 156-159.
- Friedman and young, (1997): Effects of disease on clinical laboratory tests, 3th ed. AACC Press.
- Gajski, G. and Garaj-Vrhovac, V. (2009): Radioprotective effects of honey bee venom (*Apis mellifera*) against 915-MHz microwave radiation-induced DNA damage in Wistar rat lymphocytes: in vitro study. *Int. J. Toxicol.*, 28(2): 88-98.
- Ganong, W. (1999): In 19<sup>th</sup> ed., Appleton & Lange, California, USA; Chap. 17.
- Geraci, J. P.; Jackson, K. L.; Mariano, M. S. and Michieli, B. M. (1990): Kidney and lung injury in irradiated rats protected from acute death by partial body shielding. *Rad. Res.*, 122(1): 95-100.
- Gerber, M.; Boutron-Ruault, M. C.; Herberg, S.; Riboli, E.; Scalbert, A. and et al. (2002): Food and cancer: state of the art about the protective effect of fruits and vegetables. *Bull Cancer*, 89: 293-312.
- Guney, Y.; Bukan, N.; Dizman, A. and Bildihan, A. (2004): Effects of two different doses of irradiation on antioxidant system in the liver of Guinea pigs. *Oncol.*, 26: 71-74.
- Haro, A.; Lopez-Aliaga, I.; Lisbona, F.; Barrionuevo, M.; Alferez, M. J. and Campos, M. S. (2000): Beneficial effect of pollen and/or propolis on the metabolism of iron, calcium, phosphorus and magnesium in rats with nutritional ferropenic anemia. *J. Agric. Food Chem.*, 48(11): 5715-5722.
- Hassan, S.; Abu-Gahadeer, A. and Osman, S. (1996): Vitamins B group and / or folic acid restoring the haematopoieic activity in irradiated rats. *Egypt. J. Rad. Sci. Applic.*, 9 (1): 67-78.
- Heda, G. L. and Bhatia, A. L. (1986): Haemocytometrical changes in Swiss albino mice after intrauterine low level HTO exposure. *Proc. Asian Reg. Conf. Med. Phys.*, pp. 390.
- Hegazi, A. G. (2012): Medical importance of bee products. *U. Ari Drg. Kasım Bee J.* 12 (4): 136-146.
- Hussien, E. M.; Darwish, M. M. and Ali, S. E. (2007): Prophylactic role of combined treatment with Coenzyme Q 10 and Vitamin E against radiation in male rats. *Egypt. J. Rad. Sci. Applic.*, 20 (1): 181-194.
- Hyunseong, K.; Gihyun, L.; Soojin, P.; Hwan-Suck, Ch.; Hyojung, L.; Jong-Yoon, K.; Sangsoo, N.; Sun Kwang, K. and Hyunsu, B. (2013): Bee Venom Mitigates Cisplatin-Induced Nephrotoxicity by Regulating CD4(+) CD25(+) Foxp3(+) Regulatory T Cells in Mice. *Evid Based Complement Alternat Med.*, 1-10.
- Jasprica, D.; Mornar, A.; Debelijak, Z.; Smolcic-Bubalo, A.; Medic- Saric, M.; Mayer, L.; Romc, Z.; Bucan, K.; Balog, T.; Sobocanec, S. and

- Sverko, V. (2007): *In vivo* study of propolis supplementation effects on antioxidative status and red blood cells. *J. Ethnopharmacol.*, 110: 548-554.
- Kafafy, Y. (2000): Protective effect of cytochrome and vitamin E on gamma irradiation injury in rats. *Egypt. J. Rad. Sci. Applic.*, 13 (2): 17-25.
- Kanbur, M.; Eraslan, G. and Silici, S. (2009): Antioxidant effect of propolis against exposure to propetamphos in rats. *Ecotoxicol. Environ. Saf.*, 72(3): 909-915.
- Khan, M. R.; Rizvi, W.; Khan, G. N.; Khan, R. A. and Shaheen, S. (2009): Carbon tetrachloride induced nephrotoxicity in rats: Protective role of *Digera muricata*. *Ethnopharmacol. J.*, 122 (1): 91-99.
- Kim, H. W.; Kwon, Y. B.; Ham, T. W.; Roh, D. H.; Yoon, S. Y.; Lee, H. J.; Han, H. J.; Yang, I. S.; Beitz, A. J. and Lee, J. H. (2003): Acupoint stimulation using bee venom attenuates formalin-induced pain behavior and spinal cord fos expression in rats. *J. Vet. Med. Sci.*, 65: 349-355.
- Kumar, V.; Cotran, R. S. and Robbins, S. L. (2003): Environmental Diseases. In Robbins Basic Pathology, 7<sup>th</sup> ed., Saunders. Philadelphia London Toronto., pp. 288.
- Kumazawa, S.; Ahn, M. R.; Fujimoto, T. and Kato, M. (2010): Radical-scavenging activity and phenolic constituents of propolis from different regions of Argentina. *Nat. Prod. Res.*, 24: 804-812.
- Manal, M. D. and Abd El Azime, A. Sh. (2013): Role of Cardamom (*Elettaria cardamomum*) in Ameliorating Radiation Induced Oxidative Stress in Rats. *Arab. J. of Nucl. Sci. and Appl.*, 46(1): 232-239.
- Matsushige, K. I.; Kusumoto, T.; Yamamoto, Y.; Kadota, S. and Namba, T. (1995): Quality evaluation of propolis. A comparative study on radical scavenging effects of propolis and *vespae nidus*. *J. Trad. Med.*, 12: 45-53.
- Mcfarland, M. B. (1994): Nursing implication of laboratory Testes. 3<sup>rd</sup> Edition Delmar Publishers Inc. (Albany, N.Y), pp. 190-205. ISBN: 10- 0827351356.
- Mohd Nuruddin, A. Onn Haji, H. and Kamaruddin, M. Y. (2011): Malaysian Bee Venom Abrogates Carrageenan Induced Inflammation in Rats. *J. of Api Product and Api Medical Sci.*, 3 (2): 75-80.
- Nabila, A. R. M. and Azza, A. M. (2005): Effect of Fractionated and Single Doses Gamma Irradiation on Certain Mammalian Organs. *Egypt. J. Hosp. Med.*, 19: 111- 122.
- Nadia, N. O. (2013): The role of antioxidant properties of Celery against lead acetate induced hepatotoxicity and oxidative stress in irradiated rats. *Arab. J. of Nucl. Sci. and Appl.*, 46(1): 339-346.
- Nahed, M. A. H. and Amany, M. H. (2010): Bee Venom-Lead Acetate Toxicity Interaction. *Austr. J. of Basic. and Appl. Sci.*, 4(8): 2206-2221. ISSN: 1991-8178.
- Nam, K. W.; Je, K. H.; Lee, J. H.; Han, H. J.; Lee, H. J.; Kang, S. K. and Mar, W. (2003): Inhibition of COX-2 activity and proinflammatory cytokines (TNF-alpha and IL-1beta) production by water-soluble sub-fractionated parts from bee (*Apis mellifera*) venom. *Arch Pharm. Res.*, 26: 383-388.
- Newairy, A. A. and Abdou, H. M. (2013): Effect of propolis consumption on hepatotoxicity and brain damage in male rats exposed to chlorpyrifos. *Afri. J. of Biotech.*, 12(33): 5232-5243.
- Nirala, S. and Bhadauria, M. (2008): Propolis reverses acetaminophen

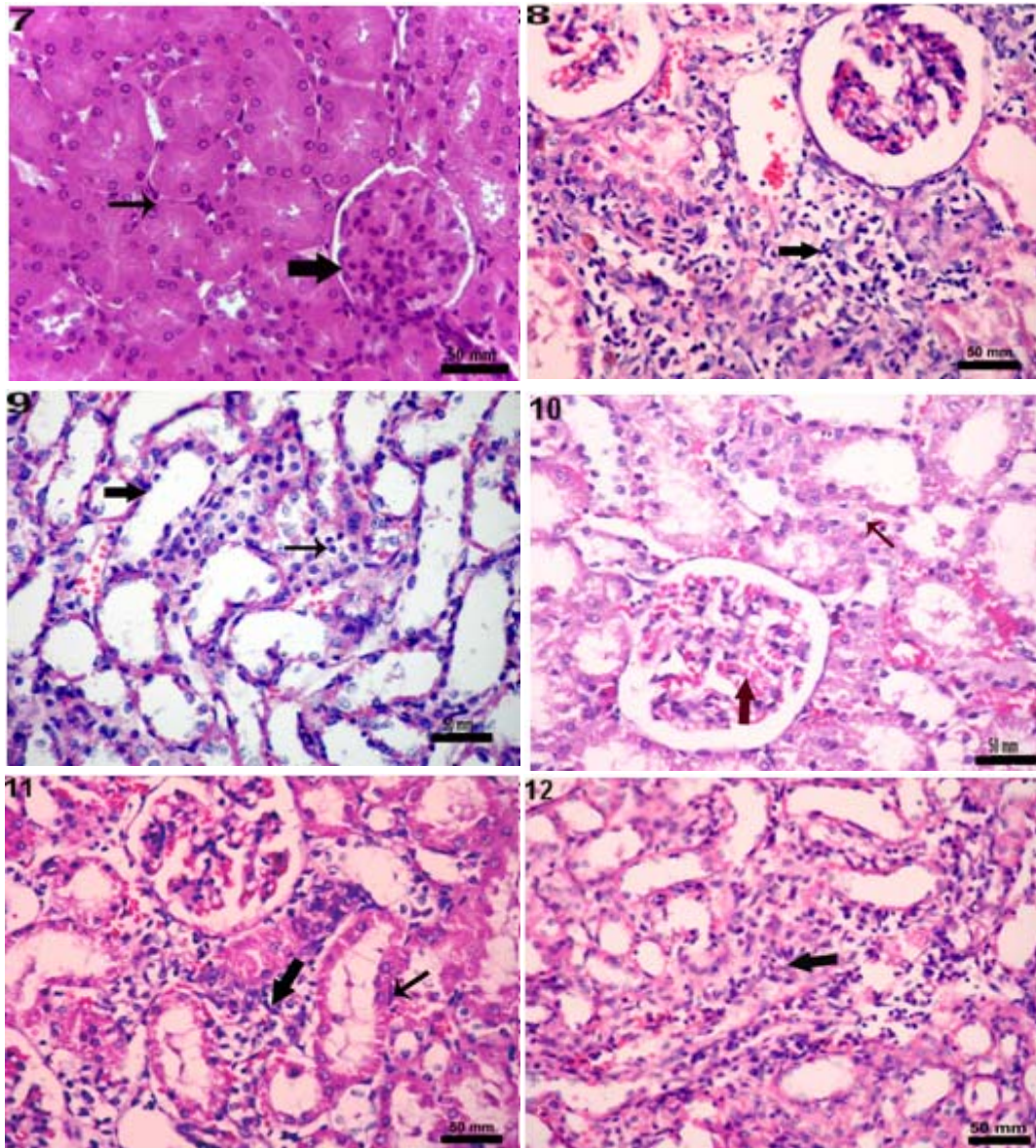
- induced acute hepatorenal alterations: A biochemical and histopathological approach". Arch. Pharm. Res., 31 (4): 451-461.
- Nishikimi, M.; Appaji, N. and Yagi, K. (1972): The occurrence of superoxide anion in the reaction of reduced phenazine methosulfate and molecular oxygen. Biochem. Biophys. Res. Commun., 46: 849-854.
- Nordberg, J. and Arner, E. (2001): Reactive oxygen species, antioxidants and mammalian thioredoxin system. Free Radic. Biol. Med., 31: 1287-1312.
- Nunia, V. and Goyal, P. K. (2004): Prevention of gamma radiation induced anaemia in mice by diltiazem. J. Radiat. Res., 45: 11-17.
- Ohkawa, H.; Ohishi, N. and Yagi, K. (1979): Assay for lipid peroxides. In: Animal tissue by thiobarbituric acid reaction. Anal. Biochem., 95: 351-8.
- Oktem, F.; Ozguner, F.; Sulak, O.; Olgar, S.; Akturk, O.; Yilmaz, H. and Altuntas, I. (2005): Lithium-induced renal toxicity in rats: protection by a novel antioxidant caffeic acid phenethyl ester. Mol. Cell. Biochem., 277(1-2): 109-115.
- Orsolic, N. and Basic, I. (2005): Antitumor, hematostimulative and radioprotective action of water-soluble derivative of propolis (WSDP). Biomed. Pharmacother., 59(10): 561-570.
- Orsolic, N.; Sver, L.; Verstovsek, S.; Terzic, S. and Basic, I. (2003): Inhibition of mammary carcinoma cell proliferation *in vitro* and tumor growth *in vivo* by bee venom. Toxicol., 41: 861-870.
- Osman, N. N. and Hamza, R. G. (2013): Protective Effect of *Carica papaya* Linn Against? Radiation-Induced Tissue Damage in Rats. Arab. J. of Nucl. Sci. and Appl., 46 (1): (305-312).
- Park, J. H.; Kim, K. H.; Kim, S. J.; Lee, W. R.; Lee, K. G. and Park, K. K. (2010): Bee Venom Protects Hepatocytes from Tumor Necrosis Factor-alpha and Actinomycin D. Archives of Pharm. Res., 33 (2): 215-223.
- Rain, D. (2009): Bee venom therapy for inflammatory conditions: historical and recent trends. Amer. Apither. soc. J., 16 (1): 1-11.
- Rajapakse, N.; Kim, M. M.; Mendis, E. and Kim, S. K. (2007): Inhibition of free radical mediated oxidation of cellular biomolecules by carboxylated chitoologosaccharides. Bioorg. Med. Chem., 15(2): 997-1003.
- Ramadan, F. L. (2007): Evaluation of the synergistic effect of danazol and radiation exposure on some biochemical functions in female albino rats. Egypt. J. of Hospit. Med., 27: 255-262.
- Rehab, M. and Ibrahim, M. (2012): Evaluation of the effect of Spirulina against Gamma irradiation induced oxidative stress and tissue injury in rats. Int. J. of Appl. Sci. and Engin. Res., 1, (2): 152-164.
- Reitman, S. and Frankel, S. (1957): Colorimetric method for estimation of GOT/AST and GPT/ALT transaminases. Am. J. Clin. Pathol., 28: 56-63.
- Saada, N. H. and Azab, K. S. (2001): Role of lycopene in recovery of radiation induced injury to mammalian cellular organelles. Pharmazie, 56: 239-241.
- Saleh, E. S. A. (2011): Hematological and Biochemical Studies on the Effect of Some Natural Antioxidants Pre-Injection in Irradiated Rats. Ph.D. Thesis, Dept. of Biochem. Fac. of Agric. Benha Univ.

- Samar, F. D.; Wesam, M. El.; Hossam, M. A. and Ebtehal, El. (2013): Targeting TNF-and NF-kB Activation by Bee Venom: Role in Suppressing Adjuvant Induced Arthritis and Methotrexate Hepatotoxicity in Rats. *Bee Venom Acupuncture and Methotrexate Interaction*, 8 (11): 1-13.
- Sang Hyun, P.; Kannampalli, P.; Mi Hee, Ch.; Kyong-Cheol, K. and Hae-Jun, P. (2010): Hesperidin and Curdlan treatment ameliorates  $\gamma$ -radiation induced cellular damage and oxidative stress in the liver of Sprague-Dawley rats, 1 (3):165-177.
- Sobocanec, S.; Sverko, V.; Balog, T.; Saric, A. A.; Rusak, G.; Likic, A. S.; Kusic, A. B.; Katalinic, A. V.; Radic, A. S. and Marotti, T. (2006): Oxidant/antioxidant properties of Croatian native propolis. *J. Agric. Food Chem.*, 54(21): 8018-8026.
- Son, D. J.; Lee, J. W.; Lee, Y. H.; Song, H. S.; Lee, C. K. and Hong, J. T. (2007): Therapeutic application of antiarthritis, pain-releasing, and anti-cancer effects of bee venom and its constituent compounds. *Pharmacol. & Therap.*, 115(2): 246-270.
- Stanley, D. S.; Jean-Louis, S.; Charles, M.; Francine, G. and Emil, S. (1984): Bee venom inhibits superoxide production by human neutrophils. *Inflammation*, 8 (4): 385-391.
- Stevenson, A. F. (2001): Low level radiation exposure. The radiobiologist's challenge in the next millennium. *Indian J. Exp. Biol.*, 40 (1): 12-24.
- Sumikura, H.; Andersen, O. K.; Drewes, A. M. and Arendt- Nielsen, L. A. (2003): Comparison of hyperalgesia and neurogenic inflammation induced by melittin and capsaicin in humans. *Neurosci. Lett.*, 337: 147-150.
- Sun, F.; Hayami, S.; Haruna, S.; Ogiri, Y.; Tanaka, K. and Yamada, Y. (2000): *In vivo* antioxidative activity of propolis evaluated by the interaction with vitamin C and E and the level of lipid hydroperoxides in rats. *J. of Agril. Food Chem.*, 48(5):1462-1465.
- Varanda, E. A.; Monti, R. and Tavares, D. C. (1999): Inhibitory effect of propolis and bee venom on the mutagenicity of some direct- and indirectacting mutagens. *Teratog. Carcinog. Mutagen.*, 19: 403-413.



Figs. 1- 6: Liver, (1) gp. 1 normal structure in the hepatic lobules in the rats gp. 1, (2) vacuolar and hydropic degenerations showed in most of the hepatic cells, with severe congestion (Thin arrow) in gp.2. HE. Bar= 50mm (3) corrosion in groups of hepatocytes, leaving hallow areas among destructed hepatocytes in gp.2, HE. Bar= 80mm (4) focal areas of necrotic debris with some inflammatory cells and red blood cells among the degenerated cells in gp. 3, (5) congestion in the blood sinusoids with regeneration were detected in some of the hepatic cells in gp. 4, (6) focal areas of inflammatory cells with regenerative changes of the some of the hepatocytes gp. 5. HE., All Bar= 50mm.





Figs. 7- 12: Kidneys, (7) normal structure in cortex and medulla in the rats in gp. 1, (8) edema inside the Bowman's space, causing atrophy in the glomeruli cells (Thick arrow), with proteinase substance near to visceral layers, besides congestion in the glomerular capillaries (Thin arrow) in gp. 2, (9) distention in the lumen of the collecting tubules formed cystic shape (Thick arrow), besides leukocytic cells infiltration among the tubules (Thin arrow) in gp. 2, (10) congestion in the glomerular and renal blood vessels, besides some regeneration in some of renal tubular cells were noticed in gp. 3, (11) aggregation with the mononuclear cells (Thick arrow) showed among the destroyed collecting tubules, besides renal casts (Thin arrow) in gp. 4, (12) focal areas of inflammatory areas replaced the degenerated cells in gp. 4. HE. All Bar= 50mm

## Arabic Summary

التأثير العلاجي لسم النحل و صمغ النحل على الإجهاد التأكسدي المستحدث بواسطة أشعة جاما على دم وأنسجة الفئران

عبد الرحيم على الشاطر<sup>1</sup> - مشيرة محمد محي الدين<sup>2</sup> - محمد محمود على سالماني<sup>3</sup>  
و نجلاء رشاد عطالله قاسم<sup>4</sup>  
1-3-4 قسم علم الحيوان - كلية العلوم - جامعة جنوب الوادي  
2- قسم الباثولوجيا والباثولوجيا الإكلينيكية - كلية الطب البيطري - جامعة جنوب الوادي

تؤدي الآثار البيولوجية للإشعاع المؤين إلى تكوين الشوارد الحرة والتي هي السبب الرئيسي في تلف الخلايا . و هذه الدراسة تهدف إلى دراسة الأثر العلاجي لبعض مضادات الأكسدة ( سم النحل و صمغ النحل) على الآثار الضارة الناجمة من أشعة جاما على المكونات الخلوية للدم والقياسات البيوكيميائية في مصل الدم والنسيج الكبدي والكلوى . وقد تم تصميم الدراسة على خمس مجموعات من ذكور الفئران البيضاء البالغة (10 فأر لكل مجموعة). وأعتبرت المجموعة الأولى كمجموعة طبيعية. تعرضت المجموعة الثانية من الفئران لجرعة واحدة من أشعة جاما بمعدل 5 جراى وسميت المجموعة الضابطة. أما المجموعة الثالثة حقنت في الغشاء البريتونى بسم النحل عند جرعة 5مللي/ كيلوجرام من جسم حيوان لمدة أربعين (40) يوما بعد ثمانى (8) ساعات من التعرض للإشعاع . والمجموعة الرابعة تم إعطاؤها مستخلص صمغ النحل من خلال الفم عند جرعة 300 مللي/ كيلوجرام من جسم حيوان لمدة أربعين (40) يوما بعد ثمانى (8) ساعات من التعرض للإشعاع. وبالنسبة للمجموعة الخامسة فقد تم حقنها في الغشاء البريتونى بسم النحل عند جرعة 5مللي/ كيلوجرام من جسم حيوان ، ثم بعد ذلك تم إعطاؤها مستخلص صمغ النحل عند جرعة 300مللي/ كيلوجرام من جسم حيوان لمدة أربعين (40) يوما بعد ثمانى (8) ساعات من التعرض للإشعاع.

تم علاج جميع المجموعات لمدة 40 يوما بعد الإشعاع . وتم جمع عينات الدم و عينات من اعضاء الكبد والكلى وذلك لإجراء الفحوصات البيوكيميائية و الهستوباثولوجية ، ومن النتائج يتضح لنا أن الحيوانات المعرضة للإشعاع تظهر بها انخفاض في عدد كرات الدم الحمراء ومحتوى الهيموجلوبين ، بالإضافة إلى انخفاض معنوي ملحوظ في عدد كرات الدم البيضاء ، الصفائح الدموية ، وحجم خلايا الدم الحمراء المتجمعة (PCV) ، وكذلك هناك ارتفاع في أنشطة كلا من ALT، AST، ALP، LDH الكرياتينين و اليوريا ، مع انخفاض في الألبومين وحمض اليوريك. وسجلت زيادة كبيرة في المألون داي ألدهيد (MDA) مع انخفاض ملحوظ في أنشطة كلا من الجلوتاثيون (GSH) ، والسوبر اوكسيد ديسميوتيز (SOD) و الكاتاليز (CAT). بالإضافة إلى ظهور استحالآت حويصلية ومائية ، تتركز في كلا من خلايا الكبد والكلى. ولقد انعكست كل هذه الآثار من خلال العلاج بسم النحل و صمغ النحل. ومن تلك النتائج نستطيع أن نستنتج أن كلا من سم النحل و صمغ النحل بما تحتويه من خصائص كمضادات للأكسدة وكناسات للشوارد الحرة تلعب دور تحسنى ضد تلف الخلايا الناتج من الشوارد الحرة المستحدثه بواسطة الإشعاع.