

## Toxic effects of mancozeb containing formulations and neemix pesticides on kidney function and ultrastructure of albino rats

**Mahmoud M. Salem**

Zoology department, Faculty of science, Al-Azhar University, Nasr city, Cairo, Egypt

### ABSTRACT

Chronic effects of mancozeb containing formulations (Anadol, Blanko, Deltathin, Tazolin) and Nemic pesticides on kidney function and ultrastructure of albino rats were studied. Thirty six male albino rats weighing 200-220 g were housed in the laboratory under natural condition and received normal commercial ration and water ad-lib then subdivided into six groups, six animals each: control, Anadol, Blanko, Deltathin, Nemic and Tazolin groups. Animals of each pesticide groups were received 25% of the LD<sub>50</sub> of the corresponding pesticide once weekly for eight weeks using stomach tube.

Results revealed significant decrease ( $p < 0.05$ ) in serum total protein and albumen of all treated groups compared to control group. The lowest value of total protein ( $6.91 \pm 0.51$  g / dl) and albumen ( $3.86 \pm 0.12$  g / dl) was recorded for Tazolin group. In the other hand serum urea and uric acid were significantly increased ( $P < 0.05$ ) in all treated groups compared to control group. Tazolin group comes on the top record ( $42.34 \pm 5.65$  mg / dl for urea and  $8.44 \pm 1.02$  mg / dl for uric acid).

A significantly elevated serum urea and uric acid concentrations accompanied with decreased total protein and albumen levels usually indicates impaired glomerular function.

Results of the kidney ultrastructure of the different treated groups shows marked alterations compared to control group. Renal glomerulus, shows, degenerated basal lamina, endothelial cells, podocytes and degraded podocyte pedicels. Proximal convoluted tubule with fragmented brush border, plasmalemma, large number of vacuoles, dense granulation, mitochondria and lysosomes are seen specially in Tazolin treated group. Distal convoluted tubule with, plasmalemma, large number of vacuoles, dense granulation, mitochondria and lysosomes and secreted granules was also seen in all treated groups. It is concluded that the contamination produced as the result of using mancozeb containing pesticide and Nemic pesticide for long time may have severe toxic effect on kidney function and ultrastructure.

**Keywords:** Mancozeb and neemix pesticides ,kidney , ultrastructure , albino rats

### INTRODUCTION

The use of pesticides in agriculture has increased over the last decade. Their widespread, often uncontrolled use causes thousands of people to be daily exposed to environmental agricultural chemicals, resulting in acute and chronic health effects. In his review about the metabolism of fungicides, Somerville (1986) reported that, of the three main groups of pesticides (insecticides,

fungicides and herbicides) fungicides have probably the longest history.

In more recent times a wide range of fungicides have become available, including compounds with not only protectant but systemic activity. At present there is a paucity of data on the potential adverse effects of exposure to low levels of mancozeb for prolonged periods.

Mancozeb must be considered a multi potent carcinogenic agent

(Belpoggi *et al.* 2002). Varnagy *et al.* (2001) observed tubulonephrosis in their study on the reproduction toxicity of lead acetate and 80% mancozeb containing fungicide formulation (Dithane M45) on rats.

Joint administration of lead acetate and a mancozeb-containing fungicide can cause maternal toxicity, embryotoxicity and characteristic tetragenic effects (Varnagy *et al.*, 2000). Shukla and Arora (2001) reported that mancozeb or its metabolites are capable of crossing the placental barrier and can exert DNA damage and tumor initiating consequences in the fetal cells that, after promotion with TPA, get converted into neoplastic cells.

The fungicide mancozeb induced apoptosis at concentration of 50 µg / ml (Lin and Garry, 2000). Also Debbbarh *et al.* (2002) reported that there are indications that mancozeb may increase sensitivity to genetic and environmental risk factors for cell death and apoptosis.

Mancozeb has produced significant enzymatic changes in the activities of aspartate aminotransferase (ASAT), alanine aminotransferase (ALAT), alkaline phosphatase (ALP), lactate dehydrogenase (LDH), and acetylcholinesterase (AChE) throughout period of study on male rats in a dose dependent manner (Kackar *et al.*, 1999). He suggested that the chronic exposure of mancozeb produces significant toxicological effects in rats.

The engagement of Mancozeb containing pesticides for long time and its oral intake specially was reported to gave synergetic effect, may participate in many dramatic effects as: hepatic carcinoma, malignant tumor of pancreas and thyroid, DNA damage, hemolymphoreticular neoplasias, and increase the sensitivity to genetic and environmental risk factors for cell death and apoptosis in the experimental animals (El Zawahry, 2004).

Neemix (active ingredient Azadirachtin) is botanical agricultural insecticide used on food crops in and around agricultural areas and greenhouses. It is reported to be used for kill/repels a variety of insect pests including whiteflies, leafminer, caterpillars, aphids, and diamondback moth.

Acute toxicity of a neem pesticide (Vepacide Tech) was studied in male wistar rats by Mahboob *et al.* (1998). He found that low levels exposure of Vepacide may have significant effect on the xenobiotic detoxification mechanism of different tissues of rat.

In his study about immuno-contraceptive activity guided fractionation and characterization of active constituents of Neem (*Azadirachta indica*) seed extracts, Garg *et al.* (1998) proposed an active fraction from neem seeds, responsible for long term and reversible blocking of fertility after a single intrauterine administration with high efficacy.

The acute toxicity of *Azadirachta indica* (neem oil) was documented in rats and rabbits by Gandhi *et al.* (1988) by the oral route. Dose-related pharmacotoxic symptoms were noted along with a number of biochemical and histopathological indices of toxicity. The 24-h LD<sub>50</sub> was established as 14 ml / kg in rats and 24 ml / kg in rabbits. Prior to death, animals of both species exhibited comparable pharmacotoxic symptoms in order and severity, with lungs and central nervous system as the target organs of toxicity.

In the other hand Raizada *et al.* (2001) suggested that Azadirachtin at the highest dose tested is well tolerated by rats of both sexes. The highest dose (oral administration of 1500 mg / kg / day for 90 days) did not produce any signs of toxicity, mortality, changes in tissue weight, pathology and serum and blood parameters. This dose can be used as a basal dose for the determination of the no

observed effect level of Azadirachtin to calculate its safety margin.

The possible effect of Mancozeb containing formulations and Neemix pesticides on kidney function and ultrastructure of albino rats is the aim of this study.

## MATERIALS AND METHODS

Thirty six male albino rats weighing 200-220 g housed in the laboratory under natural condition for a week to be acclimatized and received normal commercial ration and allowed water ad-lib. Animals divided into six groups: control, Anadol (Mancozeb 60%), Blanko (Mancozeb 60%), Deltathin (Mancozeb 80%), Nemic (Azidractin-A 51%) and Tazolin (Mancozeb 64% + Metalaxyl 8%) groups. The last five groups received orally (using gastric tube) 5ml water suspension contain 25% of LD<sub>50</sub> (5000 mg/kg B.W) from the corresponding pesticide weekly for eight weeks. At the end of the experimental period, animals of all groups were sacrificed and blood samples were taken. Serum samples were then obtained and used for biochemical analysis.

Serum total protein was determined by the method of Lowry *et al.*, (1951), albumin was measured using the method of Doumes *et al.*, (1971), urea was measured by the method of Chaney *et al.*, (1962), uric acid was determined by using the method of Kajeyoma (1971).

For electron microscopic studies, animals were anaesthetised with intramuscular injection of Ketamin HCL (50 mg/Kg). The abdominal cavity was opened; the kidney was exposed and sliced open. The cut surface was immediately flooded with fresh 2.5% glutaraldehyde fixative, then thin slices were removed and chopped into small pieces (less than mm<sup>3</sup>), fixed in 2.5 % glutaraldehyde in cacodylate buffer at 40°C for 4 h. They were then post fixed

in 1 % osmium tetroxide, dehydrated in a graded alcohol series and embedded in Durcupan Araldite. Ultra thin sections were stained with uranyl acetate and lead citrate and examined with Joel 100 B electron microscope.

Statistical analysis: Data expressed as the means  $\pm$ S.D; Variations among the different groups and the control group were assessed by Students t-test according to Snedecor and Cochran (1982).

## RESULTS AND DISCUSSION

### 1- Kidney function:

Results of the effect of chronic treatment with some pesticides Anadol (mancozeb 60%), Blanco (mancozeb 60%), Deltathin (mancozeb 80%), Nemic(Azidractin A 51%) and Tazolin (mancozeb 64% + Metalaxyl 8%) on serum Total protein g/dl, Albumin g/dl, Urea mg/dl and Uric acid mg/dl levels in albino rats are shown in Table 1 and Fig. 1. Results revealed significant decrease ( $p < 0.05$ ) in serum total protein of all treated groups compared to control group. The lowest value ( $6.91 \pm 0.51$  g / dl) was recorded for Tazolin group.

Serum albumin was also significantly decreased ( $P < 0.05$ ) in all treated groups compared to control group. Tazolin group also recorded the lowest value ( $3.86 \pm 0.12$  g / dl).

In the other hand serum urea and uric acid were significantly increased ( $P < 0.05$ ) in all treated groups compared to control group. Tazolin group comes on the top record ( $42.34 \pm 5.65$  mg / dl for urea and  $8.44 \pm 1.02$  mg / dl for uric acid).

Low serum total protein concentration may be due to hypoalbuminaemia. Dilutional hypoalbuminaemia as in the present experiment may be resulted from increased capillary membrane permeability (Mayne, 1994).

Table 1: Effect of chronic treatment with some pesticides on serum Total protein g/dl, Albumin g/dl, Urea mg/dl and Uric acid mg/dl levels in albino rats

Pesticide/parameter		control	Anadol	Blanko	Deltathin	Nemic	Tazolo in
Total protein g/dl	Mean	8.99	7.10*	7.18*	6.93*	7.09*	6.91*
	S.D	0.55	0.49	0.42	0.44	0.56	0.51
Albumin g/dl	Mean	5.07	4.21*	4.12*	4.01*	4.11*	3.86*
	S.D	0.23	0.09	0.31	0.18	0.1	0.12
Urea mg/dl	Mean	22.42	32.36*	39.06*	38.46*	36.1*	42.34*
	S.D	3.23	5.15	4.47	4.5	2.86	5.65
Uric acid mg/dl	Mean	4.14	7.72*	7.72*	7.78*	8.14*	8.44*
	S.D	0.65	0.86	0.36	0.83	0.44	1.02

S.D = Standard deviation

\* = Significant (P &lt; 0.05)

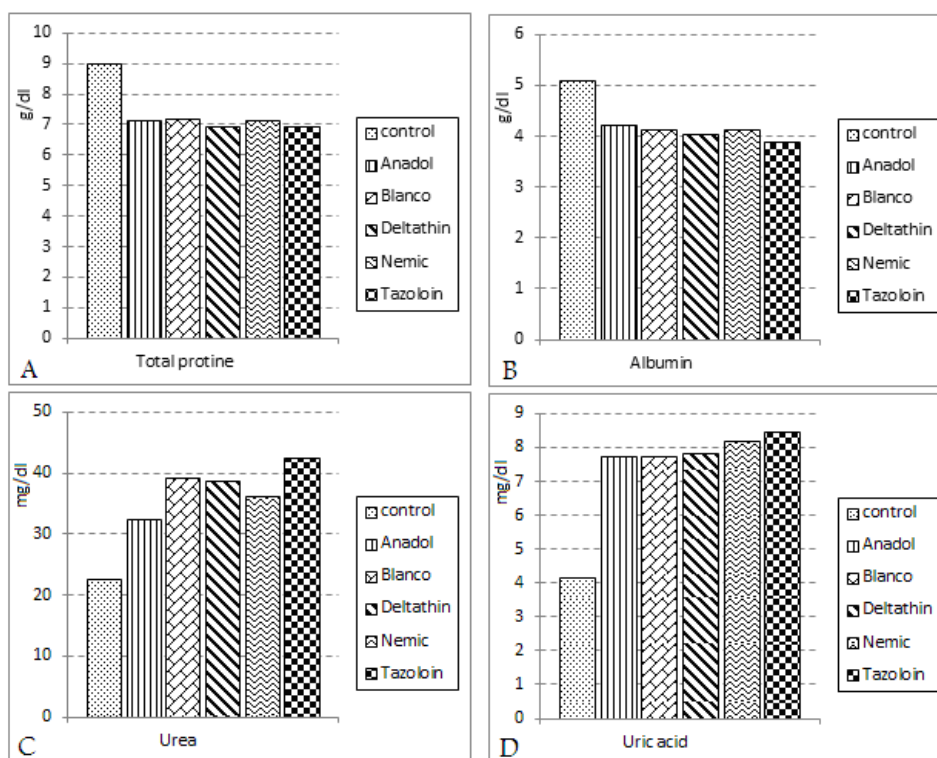


Fig. 1: Serum Total protein (A), Albumin (B), urea (C) and uric acid (D) concentrations in albino rats treated by some pesticides.

The nephritic syndrome is caused by increased glomerular basement membrane permeability, resulting in protein loss with consequent hypoalbuminaemia and oedema. The main effects are on plasma proteins.

Urea is derived in the liver from amino acids and therefore from protein, whether originating from the diet or tissues. The normal kidney can excrete large amount of urea. If the rate of production exceeds the rate of clearance plasma concentration rises. A

significantly elevated plasma urea concentration usually indicates impaired glomerular function. Uraemia only occurs in late stages of the disorder, when many glomeruli cease to function.

## 2- Electron microscopy observations:

### Glomerulus

Electron microscopic micrograph of normal control rat kidneys demonstrates that the basal lamina (BL) of glomerular capillaries (GC) represents one of the most important barriers in the organism body. It separates capillary endothelial cells (EC) from the podocytes (P) of renal glomeruli, assuming the function of a filter that segregates blood (SB) from the primitive urine (PU).

The endothelium of the glomerular capillary is interrupted by numerous pores. These are bridged by a thin membrane or diaphragm. The basal lamina comprises three layers, the lamina rara externa, lamina densa and the lamina rara interna. The lamina rara interna makes contact with endothelial cells and the lamina rara externa with podocyte pedicels (PP).

Plate 1A transmission electron micrographs revealed glomerulus of normal control rat kidney. Red blood corpuscles within glomerular capillary, endothelial cells, podocytes and podocyte pedicels.

In Anadol treated rat (plate 2, A) transmission electron micrographs revealed glomerulus, red blood corpuscles within glomerular capillary, endothelial cells, podocytes and degraded podocyte pedicels. In Blanko treated ones (plate 3, A) and in Deltathin treated rats (plate 3, C) glomerulus, red blood corpuscles within glomerular capillary, degenerated basal lamina, endothelial cells, podocytes and degraded podocyte pedicels are also seen.

Plate 4 A shows transmission electron micrographs revealed glomerulus of Nemic treated rat kidney, red blood corpuscles within glomerular capillary, endothelial cells, podocytes

and degraded podocyte pedicels. Plate 5 A revealed transmission electron micrographs of glomerulus of Tazolin treated rat kidney, red blood corpuscles within glomerular capillary, degenerated basal lamina, endothelial cells, podocytes and degraded podocyte pedicels.

In his study about the Morphometric analysis of podocyte foot process effacement in IgA nephropathy and its association with proteinuria Choi *et al.* (2010) demonstrates that proteinuria in IgA nephropathy is closely related to foot process effacement. Also Gagliardini *et al.* (2010) in his study about Imaging of the porous ultrastructure of the glomerular epithelial filtration slit stated that the morphologic analysis suggests that the filtration slit is a heteroporous structure instead of the previously proposed zipper-like structure. Selective changes in the ultrastructural organization of the pores may be responsible for the increased filtration of plasma proteins in glomerular disease.

### Proximal convoluted tubule

Normal (control) rat kidney (plate 1, B) transmission electron micrographs revealed proximal convoluted tubule with brush border, plasmalemma, mitochondria and lysosomes. In Anadol treated rats (plate 2, B) proximal convoluted tubule with brush border, plasmalemma, large number of vacuoles, mitochondria, some dense granules and lysosomes can be observed. In Nemic treated ones (plate 4, B) proximal convoluted tubule with brush border, plasmalemma, and large number of vacuoles, mitochondria and lysosomes are also seen. Tazolin treated rats (plate 5, B) shows proximal convoluted tubule with fragmented brush border, plasmalemma, and large number of vacuoles, dense granulation, mitochondria and lysosomes.

Microvilli of proximal tubule cells of the nephron constitute the so-called brush border (BB). They are longer than those of the striated border, but similar in

structural principle. The interior of the brush border microvilli contains actin like filaments. This indicates the ability of speeding up selective reabsorption from the tubular lumen by an active transport mechanism.

The plasma ultrafiltrate generated in the glomeruli is extensively modified and concentrated along the renal tubule. In the proximal tubules, some 70% of the filtered water, glucose, ions, vitamins, low molecular mass proteins, drugs, and other substances are reabsorbed to the blood or degraded in lysosomes. Proximal tubules have function related structural specializations: an apical brush border (BB) for absorption from the lumen and a basal membrane labyrinth for excretion in the extracellular space. These specializations are important for transcellular transport since they provide vast membrane surface for receptors, carriers, and transporters (Margit and Jurgen, 2005).

#### **Distal convoluted tubule**

Plate 1, C shows transmission electron micrographs of distal convoluted tubule of normal (control) rat kidney. It revealed that in distal convoluted tubules (DCT) three types of cells could be recognized easily the principal cell of the more proximal portions of the DCT are cuboidal with stubby apical microvilli and large mitochondria in the more distal region. The mitochondria become smaller and the cytoplasm bulges into the tubular lumen. The electron-dense cell can be identified in the distal part of the DCT with its prominent apical micro processes. In this region also, the mucin-secreting cells together with the electron-dense cells replace gradually the principal cells. In Anadol treated rats (plate 2, C), DCT cells with plasmalemma, large number of vacuoles, mitochondria and lysosomes. Some dense granules are seen also.

In Blanko treated ones (plate 3, B) and in Deltathin treated rats (plate 3, D) DCT cells with plasmalemma, large

number of vacuoles, mitochondria and lysosomes can be seen.

In Nemic treated rats (plate 4, C), DCT cells with plasmalemma, large number of vacuoles, mitochondria and lysosomes can be seen. Tazolin treated rats (plate 5, C) shows distal convoluted tubule with, plasmalemma, large number of vacuoles, dense granulation, mitochondria and lysosomes and secreted granules.

In cells of the proximal and distal nephron tubules, the reabsorbed material is passed on to capillaries via the basal labyrinth. At the same time, microvilli and basal labyrinth contribute to renal excretion, as various substances are eliminated into the secondary urine through the tubules. The substantial amounts of energy utilized in these processes are reflected by the presence of large mitochondria (M) within the renal cells.

In addition, each cell contains large lysosomes (Ly), peroxisomes and micropioncytotic vesicles. The latter are the morphologic expression of albumin reabsorption, since the molecules are able to pass through the glomerular basement lamina by virtue of their smaller size (Christensen and Birn, 2002).

The formation of basal labyrinth in cells of proximal and distal tubules of the nephron largely increases their surface of contact with the subepithelial space.

Deep plasmalemma (PL) infoldings subdivide the cell body into narrow compartments containing mitochondria (M), rough endoplasmic reticulum and lysosomes (Ly). Beneath the cell is a basal lamina (BL) of the epithelium, a capillary basal lamina and an endothelium.

Signes of tubulonephrosis on using mancozeb containing fungicide formulation (Dithan M45) on rats was also recorded by Varnagy *et al.* (2001).

In agreement with our findings Lin and Garry (2000) reported that the fungicide mancozeb induced apoptosis at

concentration of 50 microg /ml. Also Debbbarh *et al.* (2002) reported that there are indications that mancozeb may increase sensitivity to genetic and environmental risk factors for cell death and apoptosis. Gandhi *et al.* (1988) reported dose-related pharmacotoxic symptoms along with number of biochemical and histopathological indices of toxicity on using *Azadirachta indica* (neem oil) in rats and rabbits.

#### REFERENCES

- Belpoggi F, Soffritti M, Guarino M, Lambertini L, Cevolani D, Maltoni C. (2002). Results of long-term experimental studies on the carcinogenicity of ethylene-bis-dithiocarbamate (Mancozeb) in rats. *Ann N Y Acad Sci.* Dec., 982:123-36.
- Chaney, A. L.; Marbach, C. P. and Fawcett, J. K. (1962). A Colourimetric method for determination of blood urea., *J. Clin. Chem.*, 8: 130-135.
- Choi SY, Suh KS, Choi DE, Lim BJ. (2010). Morphometric analysis of podocyte foot process effacement in IgA nephropathy and its association with proteinuria. *Ultrastruct Pathol.*:34(4):195-8.
- Colosio C, Fustinoni S, Birindelli S, Bonomi I, De Paschale G, Mammone T, Tiramani M, Vercelli F, Visentin S, Maroni M. (2002). Ethylenethiourea in urine as an indicator of exposure to mancozeb in vineyard workers. *Toxicol Lett.* Aug 5;134(1-3):133-40.
- Christensen E, and Birn H. (2002). Megalin and cubilin: multi-functional endocytic receptors. *Nat. Rev. Molec. Cell Biol.* 3:258.
- Debbbarh I, Rambelomanana S, Penouil F, Castaigne F, Poisot D, Moore N. (2002). Human neurotoxicity of ethylene-bis-dithiocarbamates (EBCD). *Rev Neurol (Paris)* Dec; 158:1175-80.
- Doumas, B.; Watson, W. and Biggs, H. (1971). Alumin standards and the measurements of serum albumin with bromocreasol green. *Clin. Chem. Acta.*, 31: 87-90.
- El Zawahry EI. (2004). Assessment of the toxicity on chronic treatment with some pesticides on albino rats. *Bull. Egypt. Soc. Physiol. Sci.* 24 (1):251-264.
- Gagliardini E, Conti S, Benigni A, Remuzzi G, Remuzzi A. (2010). Imaging of the porous ultrastructure of the glomerular epithelial filtration slit. *J Am Soc Nephrol.* Dec: 21(12): 2081-9.
- Gandhi M, Lal R, Sankaranarayanan A, Banerjee CK, Sharma PL. (1988). Acute toxicity study of the oil from *Azadirachta indica* seed (neem oil). *J Ethnopharmacol.* May-Jun; 23(1):39-51.
- Garg S, Talwar GP, Upadhyay SN. (1998). Immunocontraceptive activity guided fractionation and characterization of active constituents of neem (*Azadirachta indica*) seed extracts. *J. Ethnopharmacol.* Apr., 60(3):235-46.
- Kackar R, Srivastava MK, Raizada RB (1999). Assessment of toxicological effects of mancozeb in male rats after chronic exposure. *Indian J Exp Biol Jun.*, 37 (6): 553-9.
- Kajeyoma, k. (1971). Enzymatic colorimetric method for the determination of uric acid., *J. Clin. Chem. Acta.*, 31: 421-428.
- Lin N, Garry VF. (2000). In vitro studies of cellular and molecular developmental toxicity of adjuvants, herbicides, and fungicides commonly used in Red River Valley, Minnesota. *J Toxicol Environ Health A.* Jul 28; 60(6):423-39.
- Lowry, O. H.; Rosebrouch, N. J.; Farr, A. L. and Randaall, b. J. (1951). Protein measurement with the folin phenol reagent., *Am. J. Cline. Pathol.*, 16: 40-44.

- Mahboob M, Siddiqui MK, Jamil K. (1998). The effect of subacute administration of a neem pesticide on rat metabolic enzymes. *J Environ Sci Health B*. Jul; 33(4):425-38.
- Margit P, and Jurgen R (2005). *Functional ultrastructure: An atlas of tissue biology and pathology*. Springer-Verlag / wien. Printed in Austria.
- Mayne, P. D. (1994). *Clinical chemistry in diagnosis and treatment*. 6<sup>th</sup> ed. Edward Arnold. London, Boston, Melbourne, Auckland. P. 189.
- Raizada RB, Srivastava MK, Kanshal RA, Singh RP. (2001). Azadirachtin, a neem biopesticide: subchronic toxicity assessment in rats. *Food Chem Toxicol*. May; 39 (5): 477-83.
- Shukla Y, Arora A. (2001). Transplacental carcinogenic potential of the carbamate fungicide mancozeb. *J Environ Pathol Toxicol Oncol*. 20(2):127-31.
- Snedecor G. W. and Cochran W.G. (1982): *Statistical methods* 7<sup>th</sup> Ed. Iowa, USA.
- Somerville L. (1986). The metabolism of fungicides. *Xenobiotica* oct-nov, 16 (10-11): 1017-30.
- Varnagy L, Budai P, Molnar E, Takacs I, Karpati A. (2000). Interaction of Dithane M-45 (mancozeb) and lead acetate during a teratogenicity test in rats. *Acta Vet Hung*, 48(1):113-24.
- Varnagy L, Budai P, Molnar E, Takacs I, Fejes S. (2001). One-generation reproduction toxicity study of mancozeb and lead acetate. *Meded Rijksuniv Gent Fak Landbouwkd Toegep Biol Wet*. 66(2b):873-8.



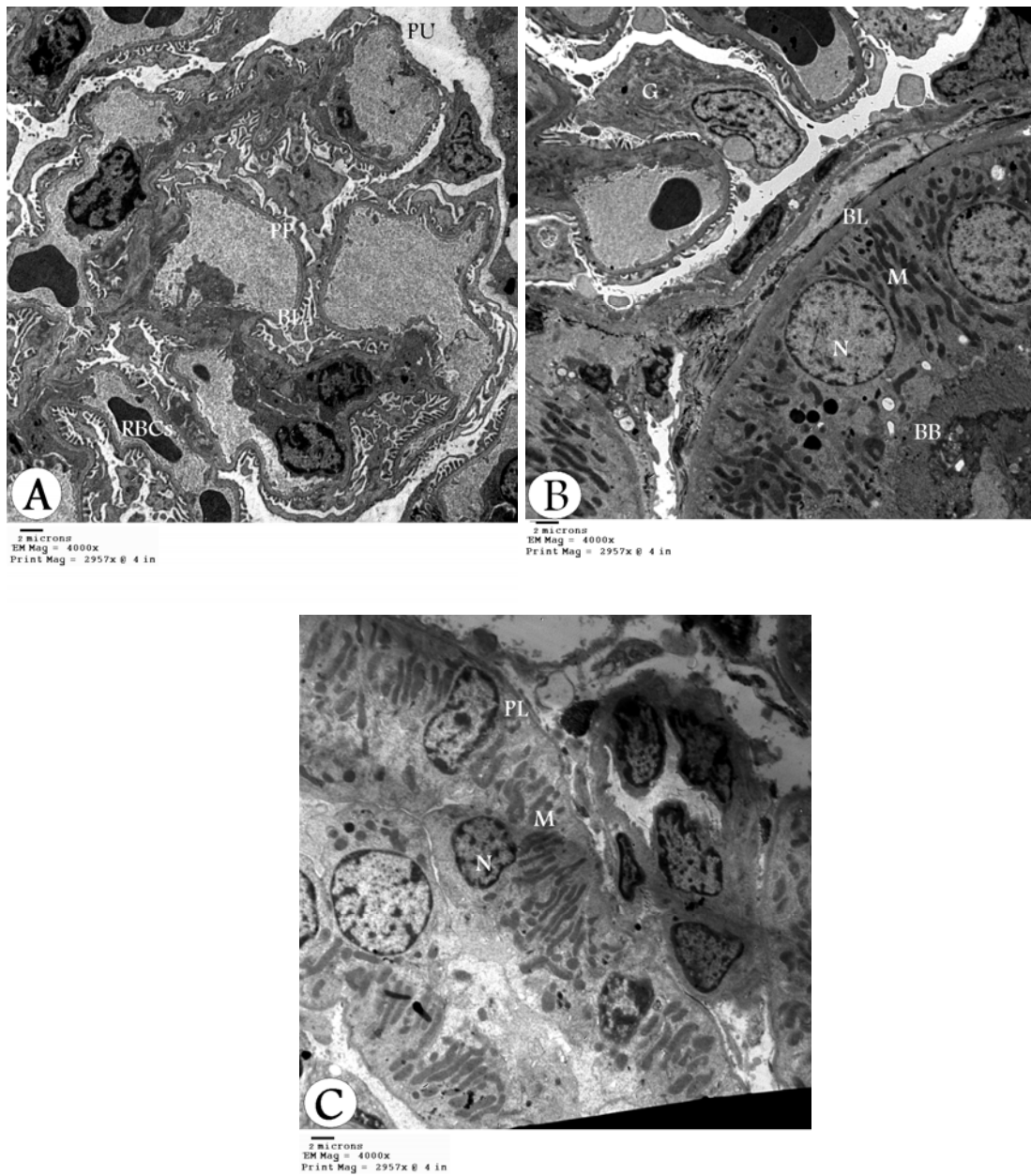


Plate 1: Transmission electron micrograph of normal Albino rat kidney showing glomerulus A, (magnification, 4000x), proximal convoluted tubule B, (magnification, 4000x) and distal convoluted tubule C (magnification, 4000x).

P = podocyte; PP = podocyte pedicels; PU = primitive urine; BL = basal lamina; G = glomerulus; PL = plasma lemma; N = nucleus; BB = brush border; M = mitochondria; RBCs = red blood corpuscles; and V = vacuoles.

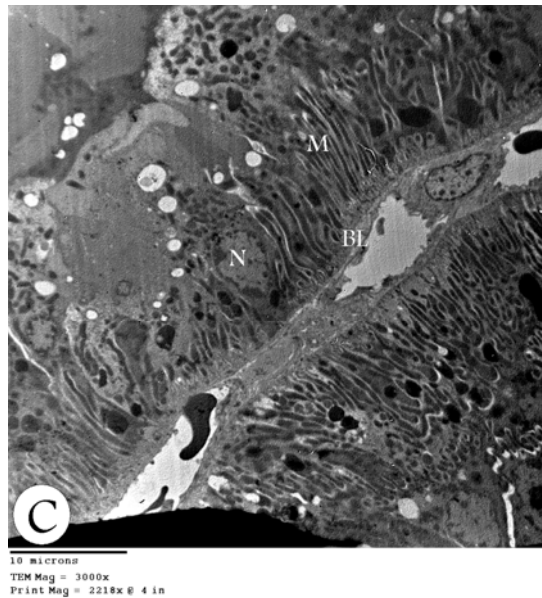
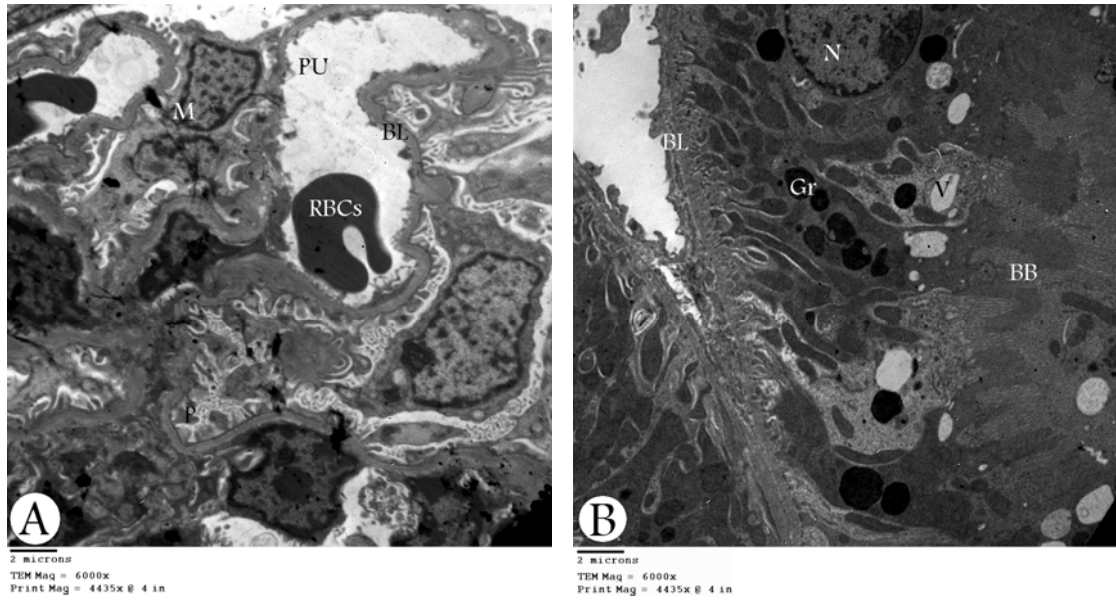


Plate 2: Transmission electron micrograph of Anadol treated rat kidney showing glomerulus A, (magnification, 6000x), proximal convoluted tubule B, (magnification, 6000x) and distal convoluted tubule C (magnification, 3000x).

P = podocyte; PP = podocyte pedicels; PU = primitive urine; BL = basal lamina; RBCs = red blood corpuscles; PL = plasma lemma; N = nucleus; BB = brush border; M = mitochondria; Gr = Granules and V = vacuoles.

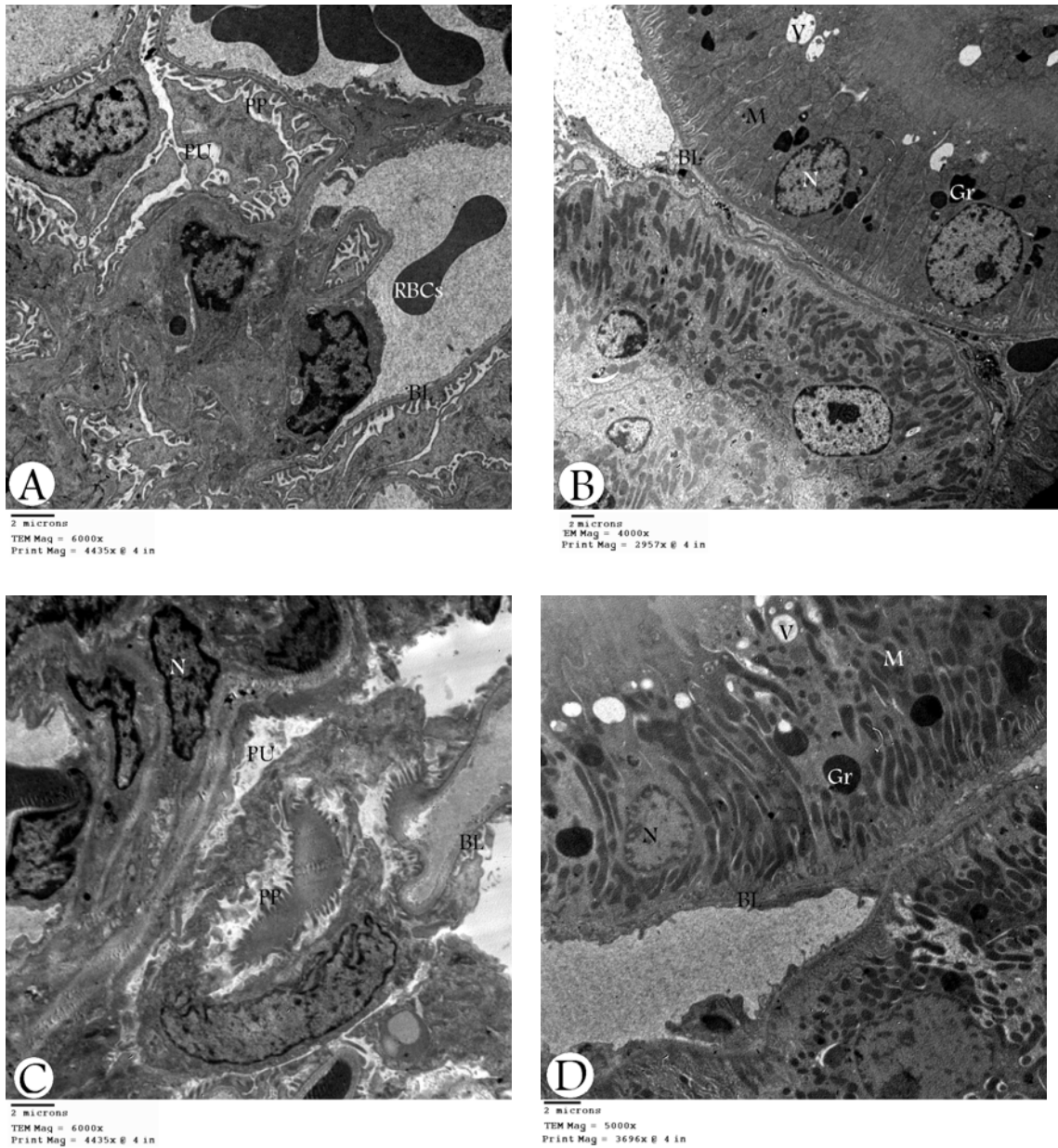


Plate 3: Transmission electron micrograph of Blanko treated rat kidney showing glomerulus A, (magnification, 6000x), distal convoluted tubule B, (magnification, 4000x) and Deltathin treated rat kidney showing glomerulus C, (magnification, 6000x), distal convoluted tubule D (magnification, 5000x).

P = podocyte; PP = podocyte pedicels; PU = primitive urine; BL = basal lamina; RBCs = red blood corpuscles; PL = plasma lemma; N = nucleus; BB = brush border; M = mitochondria; Gr = Granules and V = vacuoles.

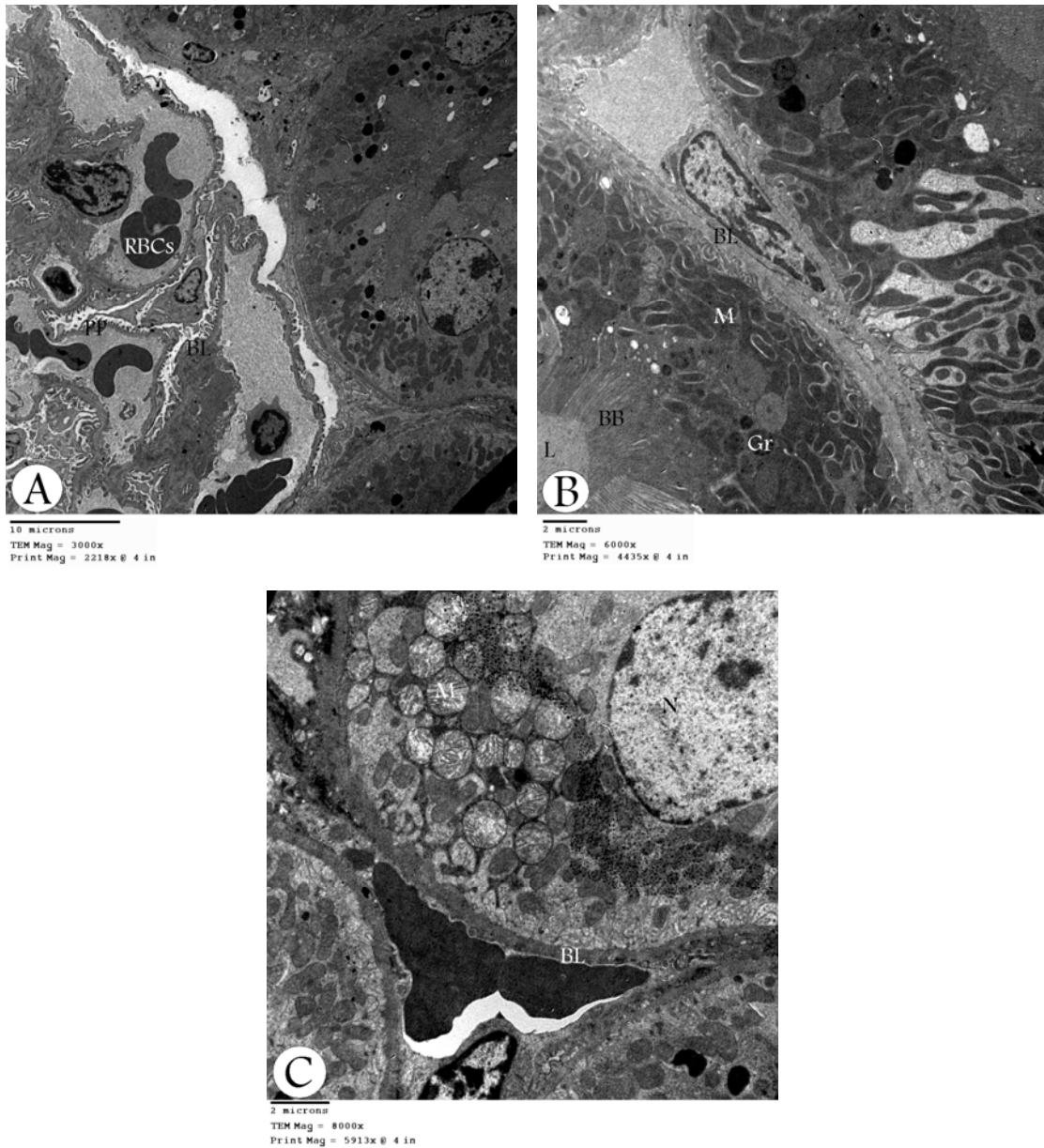


Plate 4: Transmission electron micrograph of Nemic treated rat kidney showing glomerulus A, (magnification, 3000x), proximal convoluted tubule B, (magnification, 6000x) and distal convoluted tubule C (magnification, 8000x).

P = podocyte; PP = podocyte pedicels; PU = primitive urine; BL = basal lamina; RBCs = red blood corpuscles; PL = plasma lemma; N = nucleus; BB = brush border; M = mitochondria; Gr = Granules and V = vacuoles.

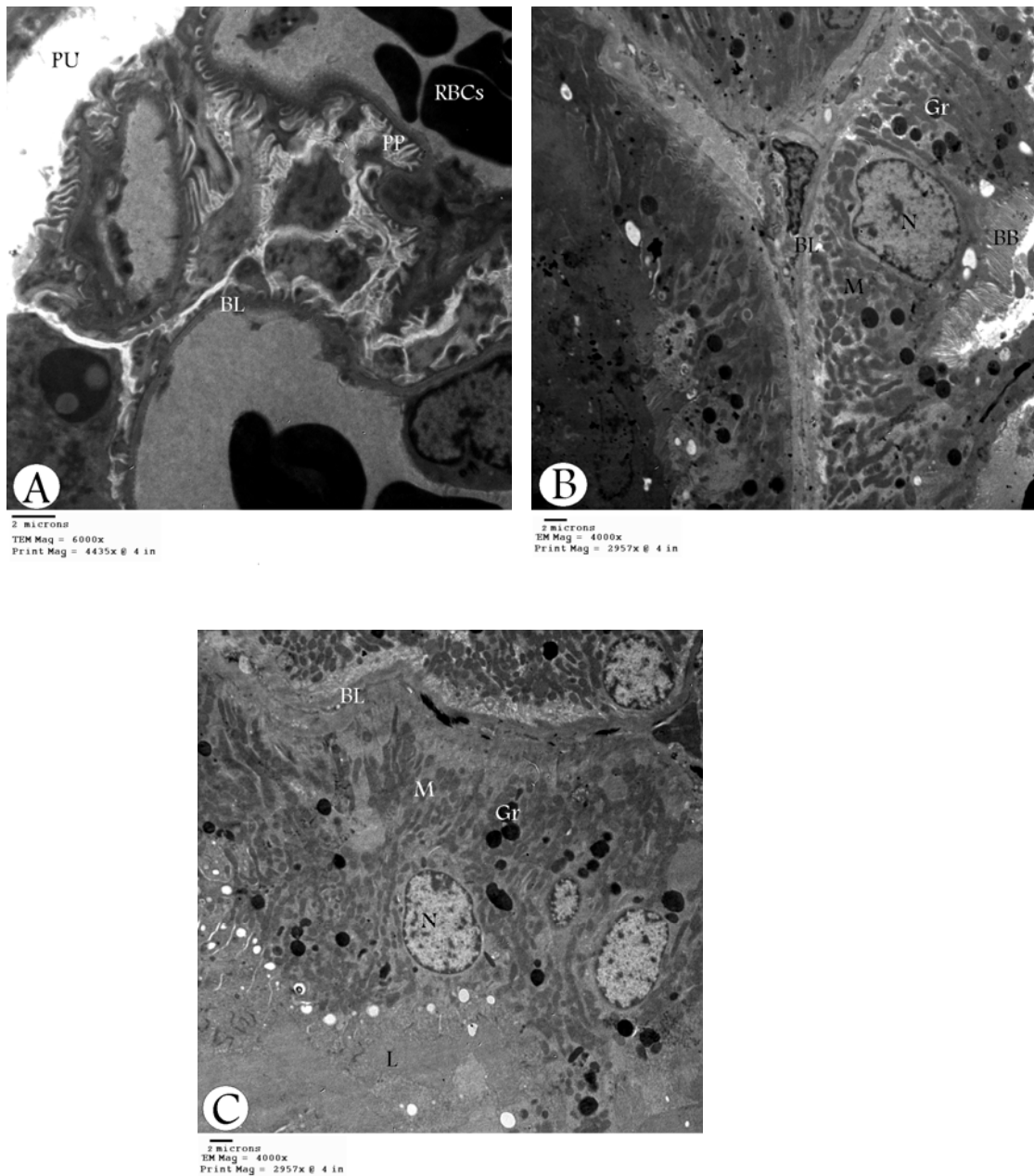


Plate 5: Transmission electron micrograph of Tazolin treated rat kidney showing glomerulus A, (magnification, 6000x), proximal convoluted tubule B, (magnification, 4000x) and distal convoluted tubule C (magnification, 4000x).

P = podocyte; PP = podocyte pedicels; PU = primitive urine; BL = basal lamina; RBCs = red blood corpuscles; PL = plasma lemma; N = nucleus; BB = brush border; M = mitochondria; Gr = Granules ; V = vacuoles and L = lumen.

## ARABIC SUMMARY

### التأثيرات السمية لبعض المبيدات المحتوية على المنكوزيب والنيمكس على الوظيفة و التركيب الدقيق لكلى الجرذان البيضاء

محمود محمد سالم

قسم علم الحيوان كلية العلوم جامعة الأزهر القاهرة

تمت دراسة التأثيرات المزمنة لبعض المبيدات المحتوية على المنكوزيب (انادول، بلانكو، دلتاين و تازولين) و مبيد النيمكس على الوظيفة و التركيب الدقيق لكلى الجرذان البيضاء. استخدم فى الدراسة ست و ثلاثون من الجرذان البيضاء يتراوح وزن الواحد منها ٢٠٠ - ٢٢٠ جرام و تم الاحتفاظ بها فى المعمل فى ظروف طبيعية مع توفير الغذاء و الماء و قد قسمت الى ست مجموعات ست حيوانات فى كل مجموعة : المجموعة الأولى ضابطة، الثانية أنادول، الثالثة بلانكو، الرابعة دلتاين ، الخامسة تازولين و السادسة نيمكس. تم تجريع حيوانات المجموعات من الثانية حتى السادسة ٢٥ % من نصف الجرعة المميتة لكل مبيد مرة واحدة أسبوعيا لمدة ثمانية أسابيع باستخدام أنبوبة معديّة. أظهرت النتائج انخفاضاً معنوياً فى مستوى البروتينات الكلية و الالبيومين فى مصل الدم لجميع المجموعات مقارنة بالمجموعة الضابطة. اقل القيم للبروتينات الكلية ( $0.51 \pm 6.91$  g/dl) و للالبيومين (3.86  $\pm 0.12$  g/dl) قد سجلت لمجموعة التازولين. و على الجانب الآخر ارتفع مستوى البوليأ و حمض البوليأ فى مصل الدم ارتفاعاً معنوياً فى جميع المجموعات بالمقارنة بالمجموعة الضابطة و سجلت أيضاً مجموعة مبيد التازولين أعلى المستويات ( $42.34 \pm 5.65$  mg/dl لليوريا و  $44 \pm 1.02$  mg/dl لحمض البوليأ). هذه النتائج مجمعة تظهر خلل واضح فى وظائف الكلى للمجموعات المعالجة بالمبيدات المختلفة. أوضحت دراسة التركيب الدقيق للكلى تبايناً واضحاً بين المجموعات المعاملة بالمبيدات المختلفة و المجموعة الضابطة: فيما يتعلق بالكبة ظهر تأكل واضح للغشاء القاعدى و تحطم لبعض خلايا بودوسيت كنتيجة لتأثير المبيدات المستخدمة. أما الأنابيب الملتفة القريبة فقد ظهر فيها تقطع فى الحافة شبيهة الفرشاة و كذلك تأكل للغشاء القاعدى مع وجود كثرة من الفجوات و الحبيبات الداكنة و الميتوكوندريا و الليسوسومات خصوصاً فى مجموعة مبيد التازولين. و فيما يتعلق بالأنابيب الملتفة البعيدة ظهر أيضاً تأكل فى الغشاء القاعدى مع العديد من الفجوات و الحبيبات الداكنة و الميتوكوندريا و الليسوسومات فى المجموعات المعالجة بالمبيدات المستخدمة. مما سبق يتضح ان استخدام المبيدات المحتوية على مادة المنكوزيب و كذلك مبيد النيمكس لفترات طويلة له تأثيرات ضارة و خطيرة على التركيب الدقيق و وظيفة الكلى.