

EARLY CHANGES IN SHOULDER BALANCE AFTER SELECTIVE ANTERIOR CORRECTION AND FUSION FOR LUMBAR SCOLIOSIS

Ahmed Abdelaal^{1,2(*)}, Kei Miyamoto^{2,3}, Tetsuya Shimokawa², Takahiro Masuda², Akira Hioki², Katsuji Shimizu², Haruhiko Akiyama²

¹Orthopedic Surgery dept., Faculty of Medicine, Sohag University, Sohag, Egypt

²Orthopedic Surgery dept., Graduate School of Medicine, Gifu University, Japan

³Spine Center, Gifu Municipal Hospital, Gifu, Japan

*E-mail: ahmedallam200@hotmail.com

Received 30/7/2020

Accepted 22/10/2020

Abstract

Some patients developed shoulder imbalance after selective anterior correction of lumbar scoliosis with spontaneous rebalances later on. We conducted this retrospective radiographic analysis study to study the effect of selective anterior correction of thoracolumbar and lumbar scoliosis on shoulder balance. Standing X-ray films of 15 patients with lumbar scoliosis operated by anterior correction at preoperative, 3, 6 & 12 months postoperative were used. Spine and shoulder balance parameters were measured. Correlations between changes in shoulder balance and spine parameters were evaluated. Shoulder height parameters showed early postoperative change from positive or neutral to negative shoulder balance, Lumbar and thoracic Cobb angles showed immediate postoperative improvement with a slight later increase contributing to shoulder rebalance mechanisms. Changes in T1 tilt was correlated to change in thoracic Cobb angle at 3 months post op. ($r= 0.515$ $p = .049$), CRCI was correlated to difference between changes in lumbar Cobb angle and changes in thoracic Cobb angle ($r= 0.56$ $p= 0.030$), close correlation between Correction change ratio and T1 tilt, FRA, CA and CPH was shown ($p=0.008, 0.016, 0.011$ & 0.012). Spontaneous Correction of shoulder balance after anterior correction of lumbar scoliosis is likely to occur during the first postoperative year. Flexibility of the thoracic curve was a major determinant in the shoulder re-balance, ratio between correction of lumbar curve and correction of thoracic curve may have a prognostic value in shoulder rebalance after anterior correction surgery. Clavicle angle has the best predictor for postoperative shoulder balance improvement.

Keyword: Lumbar scoliosis, Shoulder balance, Anterior correction

1. Introduction

Scoliosis surgery aims to obtain a well-balanced spine, maximum correction of the scoliotic curves, and maximum functionality of the vertebral column. Anterior thoracolumbar instrumentation and fusion is a widely used technique

for curve correction in idiopathic thoracolumbar scoliosis and other types of scoliosis. Previous studies have shown that anterior thoracolumbar instrumentation and fusion offers spontaneous correction of the compensatory curve [1].

Balance, after surgery, is obtained if the correction of the unfused curve echoes the correction of the fused thoracolumbar curve [2]. Huitema and colleagues [3] suggested that the improvement of the unfused thoracic curve occurs through a counter balancing mechanism of the surgical correction of the fused thoracolumbar curve. If this assumption is true, there should be a correlation between the correction of the unfused thoracic and fused thoracolumbar curves [2,3]. Thoracolumbar/lumbar scoliosis is a common type of adolescent idiopathic scoliosis (AIS) which is classified as Lenke type 5. Anterior spinal fusion (ASF) with single- or dual-rod constructions has been used for many years and has become a common method of correction over the past 20 years. Compared to posterior correction and spinal fusion (PSF), ASF has the great advantages, First; the anterior approach provides the best mechanical advantage [4,5], second; segmental fixation allows for greater manipulation and holding power than other systems [6], Third; the anterior correction of scoliosis involves the shortening, as opposed to the lengthening, of the spinal column. Thus, reduces the risks of an immediate traction injury to the spinal cord. Fourth; the anterior

technique should involve fewer segments in the correction of thoracolumbar and lumbar deformities. The preservation of additional motion segments reduces the risk of degenerative changes caudal to the fusion [7]. Finally, the risk of lumbar curve decompensation should also be reduced [8]. Patient satisfaction after surgery in AIS depends on many factors, such as surgical scars, improved back shape, reduced radiological Cobb angle and back pain [9,10], among those various factors, cosmeses of the back and shoulder are critically important to AIS patients and a big concern of the patients family [11-15]. There were several reports of psychological distress in adolescent females due to clinical deformity. Actually, we have observed clinically that some patients developed shoulder imbalance at an early stage or in the long-term due to the short fusion, and which was beyond the compensative ability of unfused levels. While some researchers had studied shoulder imbalance course after posterior correction of different types of scoliosis, no studies had investigated shoulder balance after selective anterior correction and fusion of lumbar scoliosis. In the present study, we studied the effect of selective anterior correction and fusion of thoracolumbar-lumbar and thoracolumbar- lumbar main thoracic curves on shoulder balance.

2. Material and Methods

2.1. Patients' criteria.

Fifteen cases, tab. (1) were included into this study. Patients with leg-length discrepancy, pelvis tilt or hip flexion deformity were excluded from the study. Average follow up (3 years 7 months), ranges from 16 months - 13 years, but only 1 year follow up radiographs were included in the study. The range, average Cobb angel of lumbar and thoracolumbar curve as well as shoulder

height parameters at different time points are shown in table 2. Flexibility indices of the curves ranged from 0.07 to 0.62, average is 0.29. All patients had anterior correction of Lumbar curves using anterior lumbar fusion system instruments (DePuy Synthes, Raynham, MA, United States) were used, Informed consents were obtained from the patients and their parents.

Table (1) Descriptive statistics of the cases.

No	Age	Sex	Diagnosis	Main curve	Fusion level	Preop. Lumbar Cobb	Preop Th. Cobb	Final Lumbar Cobb	Final Th. Cobb
1	14	F	AIS	T11-L4	T11-L3	45	32	1	12
2	16	F	AIS	T11-L4	T11-L4	67	80	22	24
3	14	F	Genetic Abnormality	T11-L4	T12-L4	48	11	9	3
4	15	F	Chiani Malformation	T11-L4	T11-L3	56	34	2	19
5	17	F	AIS	T11-L4	T11-L3	60	27	23	12
6	11	M	Reckling syndrome	T10-L3	T10-L3	69	25	43	34
7	14	F	Prader Willi syndrome	T10-L3	T10-L3	63	41	23	32
8	19	F	AIS	T11-L4	T11-L3	47	25	21	22
9	14	F	AIS	T10-L3	T10-L3	45	35	2	20
10	10	F	AIS	T10-L3	T10-L3	79	40	62	34
11	15	F	AIS	T11-L4	T11-L3	45	32	1	11
12	15	F	AIS	T6-L1	T7-T12	44	44	19	19
13	22	F	AIS	T11-L3	T11-L3	72	58	39	45
14	11	F	Prader Willi syndrome	T10-L3	T10-L3	74	54	22	33
15	15	F	AIS	T11-L4	T11-L3	39	18	7.5	10.9
Av. (SD)						57(+/-12)	37(+/-16)	20(+/-17)	22(+/-11)

2.2. Radiographic evaluation

All patients had standard anteroposterior radiograph of the whole spine. Five of the seven radiographic shoulder balance parameters adopted by Bago et al., and Kuklo et al [16,17] were used. These values were measured on each radiograph. T1 tilt, First rib angle (FRA), Clavicle angle (CA), Coracoid process height (CPH), and Clavicle-rib cage intersection (CRCI) [18,19].

T1 tilt: Is the angle between the horizontal line and the line through the upper endplate of T1, fig. (1-a).

FRA: The tilt of a tangential line that connects both the superior borders of first ribs, fig. (1-b).

CA: Is the angle between the horizontal line and the tangential line connecting the highest two points of each clavicle, fig. (1-c).

CPH: A horizontal line was traced in the superior edge of each coracoid process. The height difference between the right and left lines was recorded, fig. (1-d).

CRCI: The clavicle intersects the outer face of the rib cage to a variable height.

A horizontal line was traced through this point, the difference between the left and right lines was defined as CRCI, fig. (1-e).

Cobb angle: Lumbar Cobb angle well as thoracic Cobb angle were measured at preoperative, 3, 6, and 12 months post-operatively. Changes in each item were calculated with reference to preoperative values, as well as differences between changes of lumbar and thoracic Cobb angles at the same time points. Correction change ratio between lumbar and thoracic curve was calculated using the following formula:

$$\text{Correction Change ratio [18]} = (\text{Change in lumbar Cobb angle}) / (\text{Change in Th. Cobb angle}).$$

Correlation between scoliosis and shoulder height parameters: Correlation between changes in the scoliosis parameters (changes in lumbar Cobb, changes in thoracic Cobb, difference between changes, Correction Change ratio) and changes in shoulder balance parameters (T1 tilt, FRA, CA, CPH and CRCI) were calculated.

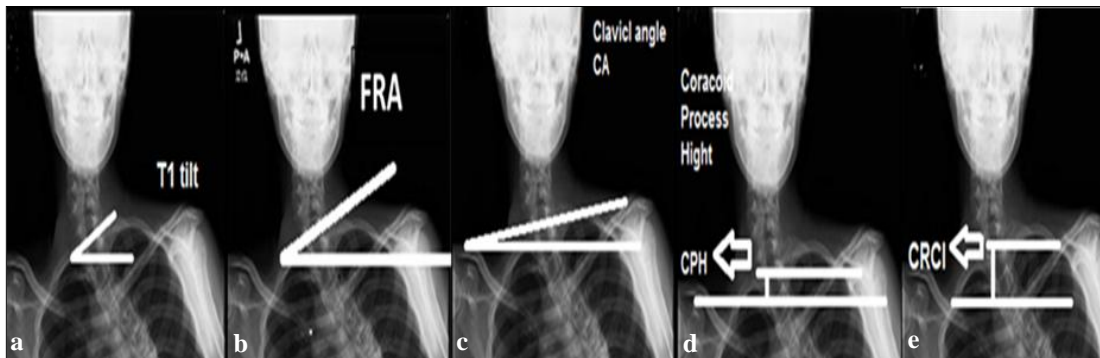


Figure (1) Shows **a.** *T1 tilt*; is the angle between the horizontal line and the line through the upper endplate of T1. Positive T1 tilt was defined as the angulation of the upper endplate of T1 to the horizontal line with the left proximal vertebral body up and right lower vertebral body down, **b.** *First rib angle (FRA)*; the angle between horizontal line and tangential line that connects both the superior borders of first ribs. Positive FRA indicates an inclination to the right of this reference line, **c.** *Clavicle angle (CA)*; is the angle between the horizontal line and the tangential line connecting the highest two points of each clavicle. Positive CA was defined right lower vertebral body down, as the left clavicle up and the right clavicle down, **d.** *Coracoid process height (CPH)*; a horizontal line was traced in the superior edge of each coracoid process. Positive CPH is defined as the higher side was the left, **e.** *Clavicle-rib cage intersection (CRCI)*; vertical height difference between points of intersection of clavicle and rib cage on both sides, with a positive value adopted when the higher side is left.

2.3. Statistical analysis

All parameters were measured twice; measurement agreement between first time and second time was estimated by a correlation analysis $r = 0.671$ (p value = 0.048). The statistical analysis was performed by SPSS 12.0 for windows. Statistical difference between readings at different time points was tested using

Wilcoxon signed rank test. Correlation analysis was made between changes in shoulder balance parameters and changes in scoliosis parameters. Statistical significance was set at $p < 0.05$. Study design was approved by the Ethical Committee of Gifu University Graduate School of Medicine.

3. Results

3.1. Shoulder height change after surgery

All shoulder parameters shows early postoperative change revealing the early change from positive or neutral shoulder balance with elevated left shoulder or leveled shoulders to negative shoulder balance or elevated right shoulder, or from a grade of imbalance to a more imbalanced grade. Pre and post-operative radiographic shoulder and spine measurements and changes as well as statistical difference between readings at different time points tested using Wilcoxon on signed

rank test are shown in tab. (2). At the final evaluation at one year post-operative, four cases had persistent shoulder imbalance, one with Prader Willi syndrome, one with unknown genetic abnormality, and two with AIS, their age at operation were 14, 14, 22 and 19 respectively. Correlations between changes in shoulder balance parameters and changes in scoliosis parameters at 3, 6 and 12 months follow up are shown in tab. (3).

3.2. Preoperative predictive values

Correlation between pre-operative shoulder height values and final shoulder balance was found to be significant CA: $r = 0.635$ (p value 0.011), T1 tilt: 0.596

(p value = 0.019), FRA: $r = 0.568$ (p value = 0.029), CRCI: $r = 0.551$ (p value = 0.033), CPH: $r = 0.529$ (p value = 0.043).

Table (2) Descriptive statistics of radiological shoulder height parameters and scoliosis parameters at different time points, Z factor produced by Wilcoxon signed rank test.

	Pre-op.	Post op. 3 months	Sig. Dif. Z (p value)	Post op. 6 months	Sig. Dif. Z(p value)	Post op. 12 months	Sig. Dif. Z (p value)
T1 tilt	0.1(+/-3.58)	-4.0(+/-6.77)	-2.135(.033) *	0.2(+/-6.62)	-1.70(.865)	-1.3(+/-5.08)	-.910(.363)
FRA	0(+/-4.33)	-3.6(+/-6.5)	-1.761(.078)	0.5(+/-7.68)	-3.98(.691)	-1.2(+/-4.52)	-.738(.46)
CA	0.1(+/-2.87)	-2.9(+/-4.12)	-2.166(.030) *	-0.1(+/-5.04)	-2.84(.776)	0.7(+/-3.79)	-.471(.638)
CPH	-1.8(+/-13)	-9.5(+/-17.88)	-1.25(.211)	0.7(+/-19.54)	-.625(.532)	2.6(+/-15.33)	-.570(.57)
CRCI	2.4(+/-10.18)	-7.4(+/-14.53)	-2.13(.033) *	-0.8(+/-13.24)	-.795(.427)	2.7(+/-11.17)	-.256(.798)
Lumbar Cobb	57.1(+/-12.72)	25.3(+/-23.61)	-3.351(.001) *	21.0(+/-17.53)	-3.408(.001) *	20.1(+/-17.14)	-3.408(.001) *
Thoracic Cobb	37.2(+/-6.59)	22.0(+/-12.37)	-2.897(.004) *	23.4(+/-11.54)	-3.067(.002) *	22.3(+/-11.2)	-3.068(.002) *

Table (3) Correlation between Shoulder parameters and Spine parameters at different time points.

	Parameter	Δ T1 tilt	Δ FRA	Δ CA	Δ CPH	Δ CRCI
At 3 months postoperative.	Δ Lumbar Cobb	-0.300(0.277)	-0.137(0.627)	0.151(0.591)	-0.20(0.944)	-0.229(0.411)
	Δ thoracic Cobb	0.515(0.049) *	0.384(0.158)	0.252(0.364)	0.266(0.337)	0.298(0.281)
	Δ lumbar- Δ thoracic Cobb	-0.478(0.071)	-0.306(0.267)	-0.64(0.820)	-0.170(0.545)	-0.308(0.264)
	Change Ratio	-.220(.431)	0.304(.271)	0.304(.271)	0.189(.499)	-0.013(.963)
At 6 months postoperative	Δ Lumbar Cobb	0.017(0.953)	0.114(0.687)	0.144(0.610)	-0.014(0.960)	-0.101(0.720)
	Δ thoracic Cobb	-0.121(0.667)	-0.244(0.382)	0.158(0.575)	-0.056(0.842)	-0.265(0.339)
	Δ lumbar- Δ thoracic Cobb	0.131(0.643)	0.323(0.240)	0.262(0.345)	0.044(0.876)	0.181(0.517)
	Change Ratio	-0.097(0.730)	-0.045(0.873)	-0.45(0.874)	0.079(0.781)	0.098(0.729)
At 12 months postoperative	Δ Lumbar Cobb	0.261(0.347)	0.265(0.340)	0.314(0.245)	0.161(0.565)	0.011(0.969)
	Δ thoracic Cobb	-0.160(0.955)	-0.419(0.503)	-0.088(0.756)	-0.036(0.900)	-0.508(0.053)
	Δ lumbar- Δ thoracic Cobb	0.230(0.410)	0.419(0.120)	0.350(0.201)	0.170(0.545)	0.560(0.030) *
	Change Ratio	0.658(0.008) *	0.608(0.016) *	0.635(0.011) *	0.630(0.012) *	0.333(0.226)

3.3. Case presentation.

Clinical course of 10 year old girl associated with AIS (Lenke 6 CN) is shown fig. (2-a). preoperative, leveled shoulders, fig. (2-b): 3 months postop, shoulder imbalance, fig. (2-c): one year follow up with restoration of shoulder balance). Clinical course of 22 year old

female associated with AIS (Lenke 6CN) is shown. Figure. (3-a): preoperative, leveled shoulders, fig. (3-b): at 3 months postop., shoulder imbalance, fig. (2-c): one year follow up, persistence of shoulder imbalance).

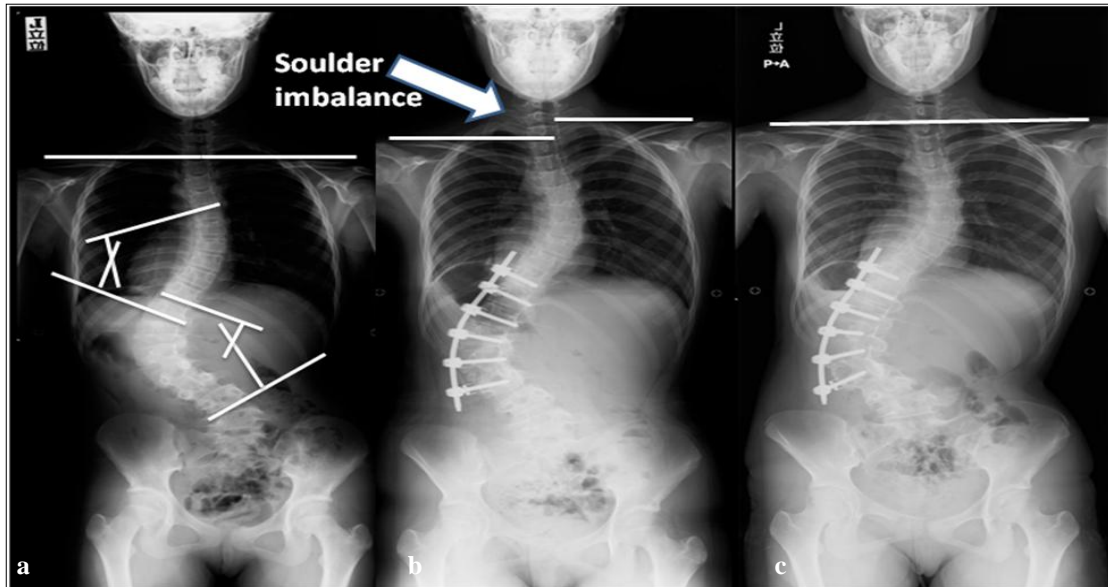


Figure (2) Shows 10 years female patient with Lenke 6CN AIS; **a.** pre-operative x-ray showing leveled both shoulders, T1 tilt= 0°, FRA= -2°,CA= 0°,CPH= 2 mm, CRCI= 3 mm, Lumbar Cobb angle =79°, Thoracic Cobb angle= 40°, **b.** post -operative (3 months) showing shoulder imbalance with elevated right shoulder, T1 tilt= -5°, FRA= -3°,CA= -5°,CPH= -21mm, CRCI= -10 mm, Lumbar Cobb angle =62°, Thoracic Cobb angle= 43°, **c.** post-operative (12months) shoulder rebalance with restoration of shoulder height equality,T1 tilt= 0°, FRA= 0°,CA= 0°,CPH= 3 mm, CRCI= 0 mm, Lumbar Cobb angle =62°, Thoracic Cobb angle= 34°.

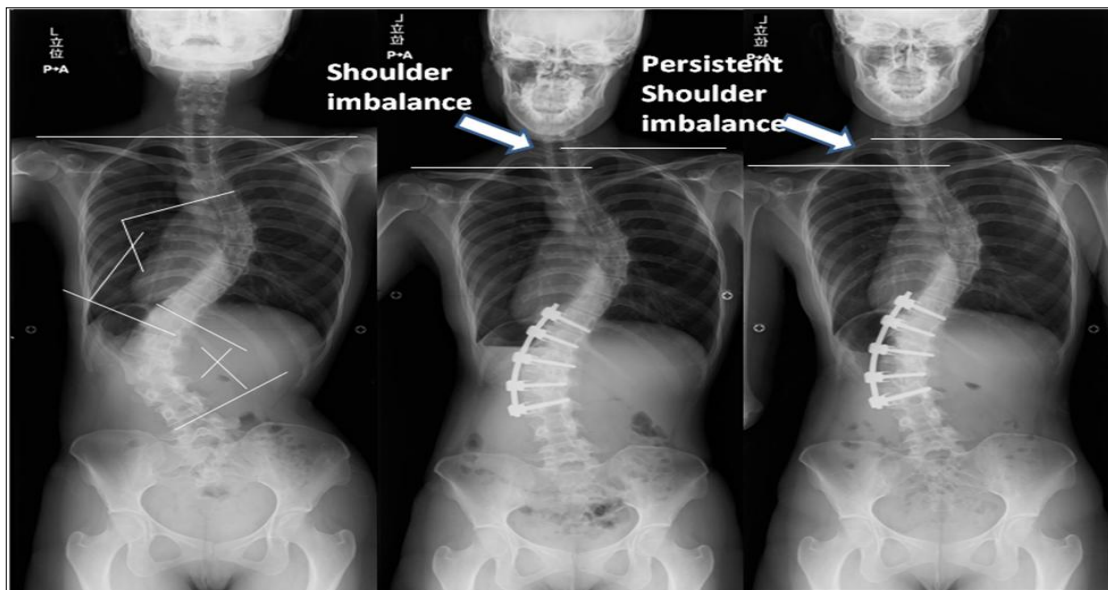


Figure (3) Shows 22 year's female patient with Lenke 6CN AIS; **a.** pre-operative leveled shoulders, T1 tilt= 4°, FRA= 3°,CA= -2°,CPH= -5 mm, CRCI= -4 mm, Lumbar Cobb angle =72°, Thoracic Cobb angle= 58°, **b.** post -operative (3 months) shoulder imbalance with elevated right shoulder, T1 tilt= -3°, FRA= -5°,CA= -4°,CPH= -18 mm, CRCI= -11 mm, Lumbar Cobb angle =37°, Thoracic Cobb angle= 48°, **c.** post-operative (12months) persistent shoulder imbalance with still elevated right shoulder.T1 tilt= -3°, FRA= -5°,CA= -6°,CPH= -22 mm, CRCI= -11 mm, Lumbar Cobb angle =40°, Thoracic Cobb angle= 45°

4. Discussion

Many reports had been published about spontaneous proximal thoracic PT curve correction after anterior correction

surgery [2,19,20], Timothy and colleagues had investigated the relationship between isolated fusion of the main thoracic MT

curve in Adolescent Idiopathic Scoliosis, and concluded that spontaneous PT curve correction consistently occurs after instrumented correction of MT curve after PSF and ASF [19], and additionally, this spontaneous correction is somewhat greater after ASF versus PSF of spontaneous correction of proximal thoracic curves regarding anterior correction [19]. Chong and colleagues had concluded a similar agreement with video assisted thoracoscopic surgery [20]. While Huitema and colleagues had investigated the predictability of spontaneous thoracic curve correction after anterior thoracolumbar correction and fusion in AIS [2,3]. The treatment of idiopathic scoliosis has improved considerably over the past several years due to advancements in spinal instrumentation and surgical procedures. While Jae-Young Hong and colleagues had stated, "final shoulder level could be aggravated regardless of the curvature types or fusion level", Kuklo et al [19] reported Spontaneous shoulder balance improvement after anterior and posterior spinal fusion of main thoracic curve in AIS, in addition to spontaneous proximal thoracic curve correction after ASF, Proximal thoracic PT curve exhibits greater spontaneous correction with ASF than in PSF. Thus, the instrumented ASF were historically preferred [21-23], offering the benefit of improved curve correction and derotation while preserving more motion segments compared to the posterior approach. This study is the first to report course of shoulder balance after selective anterior fusion of thoracolumbar scoliosis, all operation were done by single surgeon, independently analyzed by an

4.1. Correction change ratio

Significant correlations were found between correction change ratio and shoulder height parameters, i.e., T1 tilt, FRA, CA, CPH. This may explain the expected course of spontaneous shoulder height correction, which appears to show such significant correlations at one year follow up. As in early post-operative, shoulder

unbiased second surgeon with significant data acquisition in term of rigid radiographic analysis and statistical evaluation. We observed clinically that some patients developed shoulder imbalance at an early stage after ASF, due to the short fusion, however this imbalance is gradually correcting over time. In our research; the effect of ASF of thoracolumbar- lumbar and thoracolumbar-lumbar main thoracic curves on shoulder balance has been studied, Changes in T1 tilt at three months follow-up were found to be statistically significantly related to changes in thoracic Cobb angle, and a much less significant relation between T1 tilt changes and difference between changes of lumbar and thoracic Cobb angles. At six months follow up statistically significant correlation between shoulder height parameters and spine parameters couldn't be proved. At twelve months follow up statistically significant correlation between CRCI and difference of changes between lumbar and thoracic Cobb angles was proved, and negative correlation is found, though less significant, between CRCI changes and thoracic Cobb angle change at 12 months follow up. The change in strength of correlation between shoulder height parameters and spine parameter, and change of timing for different parameter to exhibit its correlation may reflect that the correction mechanisms don't act at the same time, including change in main thoracic curve change, change in proximal thoracic curve, and shoulder components which contribute with spinal elements to maintain the coronal balance to keep head and neck in balanced position.

balance is worsen, because selective correction and fusion of lumbar curve may cause shoulder imbalance or exaggerate the pre-existing imbalance, or, as the acute correction of lumbar curve may out-weigh the compensation capacity of the thoracic curve, leading to more lowering of left shoulder. Later on, the

thoracic curve shows his compensation process to keep the coronal balance, thus leading to gradual correction of the shoulder imbalance that had immediately occurred after surgery, this process was proved by testing the correlation coef-

4.2. Correction rate and Correction rate difference

Jae-Young Hong and colleagues [18] had concluded that the correction rate difference between middle and distal curve can affect final shoulder level in several types of scoliosis, while we

4.3. Preoperative predictive values

The most significant predictive preoperative values for final shoulder balance was CA This may partially consistent with what Kuklo and colleagues [19] stated;” The CA not T1 tilt provided the best preoperative radiographic prediction

4.4. Limitation of the study

There are some limitations in the present study. 1st; this is a retrospective study. However, it should be noted that all of the consecutive patients after the operation were followed successfully

ficient between the change in fused lumbar curve Cobb angle, and the change in unfused thoracic curve Cobb angle, which shows its maximal statistical significance at one year follow up, ($r = 0.611$ p value = 0.015).

couldn't prove statistically significant correlation between correction rate difference between the both curves and final shoulder level.

of postoperative shoulder balance”, though we had found significant correlation with other preoperative shoulder balance parameters, T1 tilt, FRA, CRCI and CPH.

with periodical x-ray examinations. 2nd; is the small number of patients who was included in this study. With a larger study group, the statistical results would be more evident.

5. Conclusion

Spontaneous Correction of shoulder balance after selective anterior fusion of lumbar scoliosis is likely to be the most probable after one year, however, some cases showed persistent shoulder imbalance at one year follow up. Those patients may necessitate a second stage posterior instrumentation. Stiffness of the thoracic curve was shown to affect post op. immediate shoulder imbalance. Reversely, the flexibility of the thoracic curve was shown to be a major determinant in the shoulder re-balance, ratio between correction of lumbar curve and correction of thoracic curve may have a prognostic value in shoulder rebalance after surgery. Clavicle angle has the best predictor for postoperative shoulder balance improvement, while other parameter has less strong predictability on postoperative shoulder balance.

References

- [1] Bridwell, K. (1994). Surgical treatment of adolescent idiopathic scoliosis: The basics and the controversies. *Spine*. 19: 1095-1100.
- [2] Jansen. R., van Rhijn, L., Duinkerke, E., et al. (2007). Predictability of the spontaneous lumbar curve correction after selective thoracic fusion in idiopathic scoliosis. *Eur Spine J*. 16: 1335-1342.
- [3] Huitema, G., Jansen, R., van Ooij, A., et al (2013). Predictability of spontaneous thoracic curve correction after anterior thoracolumbar correction and fusion in adolescent idiopathic scoliosis. A retrospective study on a consecutive series of 29 patients with a minimum follow-up of 2 years. *The Spine Journal*. 15 (5): 966-970
- [4] Dwyer, A., Newton, N., Sherwood, A. (1969). An anterior approach to scoliosis: A preliminary report. *Clin Orthop*. 62: 192-202.
- [5] Luk K., Leong, J., Reyes, L., et al (1989). The comparative results of treatment of idiopathic thoracolumbar

- and lumbar scoliosis using the Harrington, Dwyer, and Zielke instrumentations. *Spine*. 14: 275-280.
- [6] Hall, J. (1981). Dwyer instrumentation in anterior fusion of the spine. *J Bone Joint Surg*. 63: 188-190.
- [7] Ginsburgh, H., Goldstein, L., Robinson, S., et al (1979). Back pain in postoperative idiopathic scoliosis: Long-term follow-up study. *Spine*. 4: 518.
- [8] Turi, M., Johnston, C., Richards, B. (1993). Anterior correction of idiopathic scoliosis using TSRH instrumentation. *Spine*. 18: 417-422.
- [9] Xu-sheng, Q., Wei-wei, M, Wei-guo, L., et al (2009). Discrepancy between radiographic shoulder balance and cosmetic shoulder balance in adolescent idiopathic scoliosis patients with double thoracic curve. *Eur Spine J*. 18: 45-51.
- [10] Hahr, T., Merola, A., Zipnick, R., et al. (1995). Meta-analysis of surgical outcome in adolescent idiopathic scoliosis. A 35-year English literature review of 11,000 patients. *Spine*. 20: 1575-1584.
- [11] Asher, M., Min Lai, S., Burton, D. et al. (2003). The reliability and concurrent validity of scoliosis research society-22 patient questionnaire for idiopathic scoliosis. *Spine*. 28: 63-69.
- [12] Asher, Ma., Lai, S., Glattes, R., et al (2006). Refinement of the SRS-22 health related quality of life questionnaire function domain. *Spine*. 31: 593-597.
- [13] Hahr, T., Group, J., Shin, T., et al. (1999). Results of the scoliosis research society instrument for evaluation of surgical outcome in adolescent idiopathic scoliosis. A multicenter study of 244 patients. *Spine*. 24: 1435-1440.
- [14] Iwahara, T., Imai, M., Atsuta, Y. (1998). Quantification of cosmesis for patients affected by adolescent idiopathic scoliosis. *Eur Spine J*. 7: 12-15.
- [15] Theologis, T., Jefferson, R., Simpson, A., et al. (1993). Quantifying the cosmesis defect of adolescent idiopathic scoliosis. *Spine*. 18: 909-909.
- [16] Bago, J., Carrera, L., March, B., et al (1996). Four radiological measures to estimate shoulder balance in scoliosis. *J Pediatric Orthop*. B5: 31-34.
- [17] Kuklo, T., Lenke, L., Graham, E., et al. (2002). Correlation of radiographic, clinical, and patient assessment of shoulder balance following fusion versus nonfusion of the proximal thoracic curve in adolescent idiopathic scoliosis. *Spine*. 27: 2013-2020.
- [18] Jae-Young, H., Seung-Woo, S. Hitesh N., et al (2013), Analysis of factors that affect shoulder balance after correction surgery in scoliosis: A global analysis of all the curvature types. *Eur Spine J*. 22: 1273-1285.
- [19] Kuklo, T., Lenke, L., Won, D., et al. (2011). Spontaneous proximal thoracic curve correction after isolated fusion of the main thoracic curve in adolescent idiopathic scoliosis, *Spine*. 18, 1966-1975.
- [20] Chong-Suh, L., Sung-Soo, C., Seong-Kee, S., et al (2011). Changes of upper thoracic curve and shoulder balance in thoracic adolescent idiopathic scoliosis treated by anterior selective thoracic fusion using VATS. *J Spinal Disord Tech*. 24: 462-468.
- [21] Giehl, J., Volpel, J., Heinrich, E., et al. (1992). Correction of the sagittal plane in idiopathic scoliosis using the Zielke procedure (VDS). *Int Orthop*. 16: 213-218.
- [22] Kaneda, K., Fujiya, N., Satoh, S. (1986). Results with Zielke instrumentation for idiopathic thoracolumbar and lumbar scoliosis. *Clin Orthop Relat Res*. 205: 195-203.
- [23] Moe, J., Purcell, G., Bradford, D. (1983). Zielke instrumentation (VDS) for the correction of spinal curvature. Analysis of results in 66 patients. *Clin Orthop Relat Res*. 180: 133-53.