

Original article

## MODIFIED SURAL FLAP TO COVER DISTAL LOWER LIMB SOFT TISSUE DEFECTS

Mohamed Abdellah, Wael Salama<sup>(\*)</sup>, Ashraf Rashad, Hassan Noaman

Orthopedic Surgery dept., Faculty of Medicine, Sohag University, Sohag, Egypt

\*E-mail: [Waeladel582@gmail.com](mailto:Waeladel582@gmail.com)

Received 1/9/2020

Accepted 5/11/2020

### Abstract

The purpose of this study was to evaluate the outcomes of coverage of soft tissue defects of leg and foot by sural flap with preserving a lane of skin over the pedicle (cutaneous pedicle) with open passage between donor and recipient sites. A proscriptive study including thirty-six patients with distal lower limb soft tissue defects was carried out in the period between June 2018 and June 2019 at Sohag University Hospital. All these 36 patients underwent modified sural flap with preserved lane of skin over the pedicle with open passage for the pedicle between donor and recipient sites. Evaluation of viability of the flap, resistance against infection, healing of the flap, donor site healing and weight bearing, postoperative follow up to nine months. Group of patients including thirty-six patients with distal lower limb soft tissue defects underwent modified sural flap, the indication for flap cover was Motor car accident in 26 cases (72.2%) and exposed plate was in 6 cases (16.7%) crushing trauma was in 4 cases (11.1%). Infection were the common complications encountered Six cases (16.7%) three cases (8.35%) complicated by distal ischemia and One case (2.8%) was totally lost with increase in the flap viability with modified sural flap. Modified sural flap by preserving a lane of skin over the pedicle and open passage between donor and recipient site increase venous return of the flap and increase flap viability.

Keyword: Sural flap, Fasciocutaneous flap, Motor car accident, Distal third of leg, Dorsum of the foot

### 1. Introduction

The leg contains a thin subcutaneous layer and few muscles, thus, the tibia and tendons can easily become exposed due to trauma [1,2]. Soft tissue defects of lower 1/3 tibia and dorsum of foot presents a challenging problem to the surgeons particularly in developing countries where infrastructural facilities are yet to develop. The problem becomes worse because of the limited mobility and availability of the skin at the distal third of the leg region, unique weight bearing requirements and relatively poor circulation

of the skin [3]. Soft tissue defects over the distal third of lower limb are a common scenario faced by orthopaedic surgeons in their clinical practice. It may be the result of primary open trauma (Gustilo-Anderson Grade 3B), defect after radical debridement of open fractures (Gustilo Anderson 3A), cellulitis, defects created after contracture release, wound dehiscence after Tendon-Achilles repair, varicose ulcers and diabetic ulcers [4,5]. Over the past few decades, many lower limbs wound coverage techniques have been described.

Among the options for repairing wounds around the ankle and the foot, direct closure and skin grafting will not be applicable in many cases. Owing to the limitations in skin suitability, local rotation, advancement, and transpositional flaps are confined to smaller wounds [4,6]. A traditional cross-leg flap is a troubling and long, drawn out process for the patient, because it is a multistage procedure and requires an obligatory immobilization period that can further increase the risk of articular restriction. Muscle flaps for repair of ankle and foot wounds are of limited use, because they are not as reliable in those regions as in the middle or upper third of the leg [6,7]. Lateral and medial supramalleolar skin flaps can be used, but their dissections are somewhat difficult and their failure rates have been high. Also they present limitations relative to their dimensions [6,8,9]. Microsurgical flaps are a good alternative, but they are time consuming procedures and require sophisticated teams and equipment that are not always available [6,10,11]. One such wound coverage technique popularized by Masquelet is the use of neurocutaneous flaps based on distal neurocutaneous perforators or venocutaneous perforators [12,13]. Since then, reverse sural Fasciocutaneous

## 2. Materials and Methods

This prospective study was concluded on 36 cases of variable ages and sex (30 males and 6 females) which were presented to orthopaedic & traumatology department at Sohag university hospital in the period from June 2018 till June 2019., the study was done on patients suffering from soft tissue defects in the foot either dorsum or planter aspect, heel and leg with size from (5 to 15 cm<sup>2</sup>) with ages between 5 to 60 years (The median age of patients was 15 (7-28) years). The causes of the lesions are different and variable mostly, motor car accidents with a loss of large parts of soft tissue, crushing trauma, metal exposure, chronic ulcers. Motor car accident was the cause in 26 patients (72.2%), six patients (16.7%) with exposed plates

flaps have been described by Hasegawa, Rajacic and Nakajima, in which the arterial vascularization of the flap is provided by the vascular plexus around and inside the sural cutaneous nerve and by the arterial branches accompanying the short saphenous vein. [5] The sural flap acts as an axial flap and has 3 sources of nutrition: the vascular plexus of the deep fascia; the medial superficial sural artery, which follows the medial sural nerve; and the arteries that follow the minor saphenous vein. Venous return is ensured by the minor saphenous vein, which may be used as a distal pedicle to provide reverse flow. This vein must be preserved at least as high as the caliber perforator of the fibular artery, which is located 5-cm above the lateral malleolus and spreads with the medial superficial sural artery [2,14]. In the last decades, multiple modifications of the sural flap have been reported we have modified the surgical technique to include a skin extension along the course of the neuro-vascular pedicle. This skin extension would be expected to decrease the compression over the pedicle and offer better survival of the flap by enhancing the blood supply and drainage through the subdermal plexus [15,6].

and in four patients (11.1%) the cause was crushing trauma. The loss of soft tissue was associated with fractures in 20 patients (55.6%). we excluded patients with peripheral vascular disease, osteomyelitis, vascular injury or defects larger than 15 cm. All patients with acute soft tissue defects had appropriate emergency treatment with examination for other associated injuries. Local wash of the soft tissue defect with saline, intravenous antibiotics and tetanus toxoid were given then the limb was rested in posterior splint after dressing then plain X-ray was done to the limb to detect if there any fractures. We used modified sural flap with preservation of a lane of skin over the pedicle of the flap to cover the soft tissue defects in all patients with

open passage between donor and recipient sites for the pedicle. In patients with fractures all flaps were done after fracture fixation either internal or external fixation. The subjective evaluation included the assessment of flap viability (congestion,

### **2.1. Surgical technique**

All the procedures were performed with the patients positioned in the lateral or prone decubitus position under spinal anesthesia. A line is drawn from the mid-point between Achilles tendon and lateral malleolus at the level of lowest septocutaneous perforator to the mid-popliteal fossa, which represents the course of the superficial sural nerve and the lesser saphenous vein (LSV), fig. (1). After the landmarks have been identified and marked on the skin, the limb was exsanguinated, and the tourniquet was inflated to 350 mmHg. The flap is then outlined according to the size of the defect on the proximal third of the posterior calf according to the size of defect. The 3-cm-wide skin pedicle is outlined from base of flap along the central line down to the level of lowest septocutaneous perforator. Surgery begins with wound debridement. Next, the size of wounds is measured to assess the required size of the flap. At the proximal margin of skin flap, the LSV is identified first and ligated and the medial sural cutaneous nerve is also identified and ligated. Subfascial dissection proceeded immediately from both sides of skin flap toward the midline of the flap. Then the skin (down to the dermis) is incised at lower border of flap and along the 2 cm skin pedicle, fig. (2).

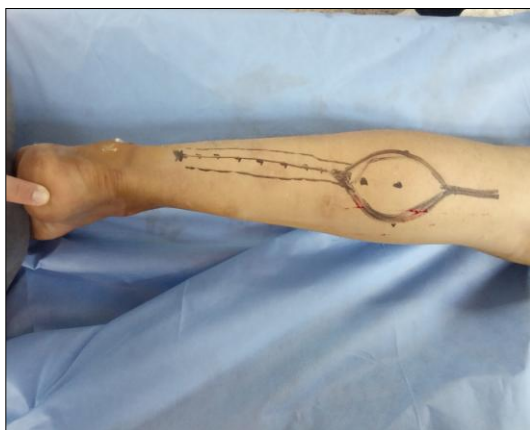

Figure (1) Shows prone decubitus & flap outlines

partial ischemia and total loss), resistance against infection, weight bearing, flap healing and donor site healing. Postoperative follow up was to average 6 months (3 to 9 months).

The skin flap with subdermal plexus is elevated carefully. The subfascial elevation proceeded from proximal to distal part under the flap and pedicle and stopped at a pivot point where there will be an anastomosis between the peroneal artery and the concomitant vessels around LSV and sural nerve. In our technique, a spoon-like skin flap is designed which contained the medial sural cutaneous nerve, LSV, and their accompanying vessels, fig. (3). Then the skin flap can be rotated 180 degrees either medially or laterally to resurface the defect. The blood supply to the flap was examined following deflation of the tourniquet. Perfusion was checked before flap rotation by waiting a few minutes and irrigating with lukewarm saline solution in order to promote microvascular circulation. No tunneling was done. An open passage was created for the flap and its cutaneous pedicle by incising the skin bridge between the donor and recipient area. The flap was then inset and sutured into the defect with non-absorbable suture, fig. (4). The donor area is then sutured or covered with a split skin graft according to flap size. The limb is immobilized with above knee slab in neutral ankle position with a non-compressive dressing, fig. (5).

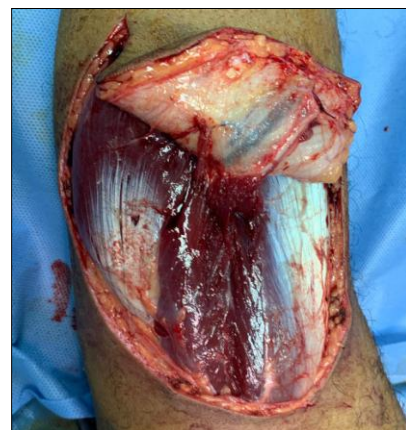

Figure (2) Shows LSV & sural nerve

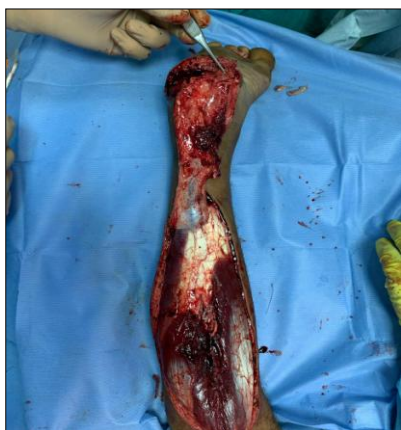

Figure (3) Shows subfascial dissection of the flap

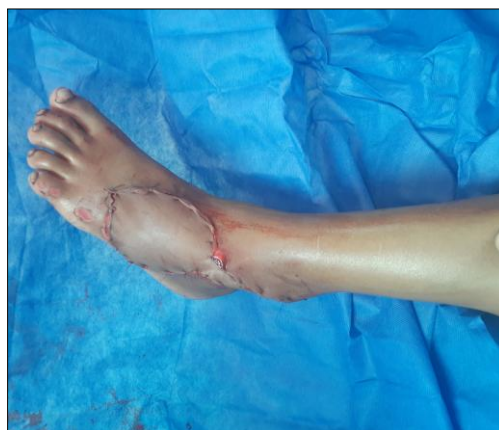

Figure (4) Shows flap suturing in recipient site

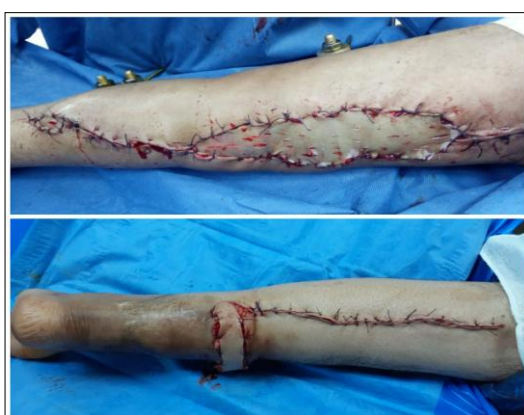

Figure (5) Shows direct closure or skin graft

## 2.2. Statistical analysis

The collected data was revised, coded, tabulated and introduced to a PC using Statistical package for Social Science (SPSS 25). Data was presented and

suitable analysis was done according to the type of data obtained for each parameter.

## 3. Results

Out of 36 patients operated for modified sural flaps, 30 were male and 6 were female. The average age of the patients was 19.3 years (5–60years). Road traffic accident was the cause of the lesion in 26 patients (72.2%) six patients (16.7%) with exposed plates and in four patients (11.1%) the cause was crushing trauma. sixteen cases (44.4%) has no fractures and twenty cases (55.6%) and according to site of fractures are differentiated to six cases (16.7%) have distal both bone leg fractures, four cases (11.1%) have mid-shaft both bone leg fractures, two cases (5.6%) have distal tibia fractures, two cases (5.6%) with distal shaft fibular fractures and six cases

(16.7%) with metatarsal fractures, tab. (1). twelve patients(33.3%) were presented with defects in dorsum of the foot , two patients (5.6%) with defect in dorsum of the ankle .four patients (11.1%) with defect in the middle third of the leg , two patients (5.6%) with defects in dorsum of the ankle and foot, six patients (16.7%) with defects over distal third leg, Two patients (5.6%) with defects over the medial malleolus, Two patients (5.6%) with defects over medial malleolus and medial aspect of the foot, Four patients (11.1%) with defects over the lateral aspect of the foot and two patients (5.6%) with defect over the heel. size of the defect range from 5-15 cm<sup>2</sup>. fourteen cases (38.9%) range from



5-9 cm<sup>2</sup>. eighteen cases (50%) range from 10-14 cm<sup>2</sup> and four cases (11.1%) with size defect 15 cm<sup>2</sup>, tab. (2) & fig. (6). Donor site was closed either primary or by partial thickness graft. twenty-eight cases (77.8%) done with primary closure and eight cases (22.2%) done with closure of donor site by partial thickness graft. Time of healing of the flap in relation to several factors like condition of soft tissue, presence or absence of infection and congestion. sixteen cases (47.1%) healed at two weeks, eight cases (23.5%) healed at three weeks and ten cases (29.4%) healed at one month. 100% of cases in our study have gained weight bearing either after healing of the flap or after healing of the fracture in presence of fractures, tab. (3). Most common complications related to sural flap are congestion, infection, distal ischemia and total loss. No cases have complicated by congestion as we preserve a lane of skin over the pedicle which enhance venous return through subdermal venous plexus and open passage between donor and recipient site which prevent compression over the pedicle. Six cases

(16.7%) developed infection which resolved by daily dressing and good antibiotic course. three cases (8.35%) complicated by distal ischemia two cases (5.6%) was superficial developed granulation tissue then secondary partial thickness graft and one case (2.8%) was associated to underlying sequestered bone treated by excision of the bone and ischemic part then primary closure of this defect and bone lengthening by Ilizarove. One case (2.8%) was totally lost this case has been covered by free muscle flaps and partial thickness graft, fig. (7). By analysis of statistics using student test and Fischer's test in two groups of distal ischemia and total loss there was no relation between presence or absence of fractures to distal ischemia or total loss as P- value is more than 0.05. No relation between site of the defect and distal ischemia or total loss as P- value is less than 0.05. There was positive relationship between size of the defect and total loss. Increase size of defect associated with increase in rates of total loss as P- value is less than 0.05, tabs. (4,5).

Table (1) Site and cause of fracture for study group

		N	%
Fractures	No	16	44.4%
	Yes	20	55.6%
Fractures	Distal BB leg fracture	6	16.7%
	BB leg fracture	4	11.1%
	Distal tibia fracture	2	5.6%
	Distal shaft fibula	2	5.6%
	Metatarsal fracture	6	16.7%
Causes	MCA	26	72.2%
	Exposed plate	6	16.7%
	Crushing trauma	4	11.1%

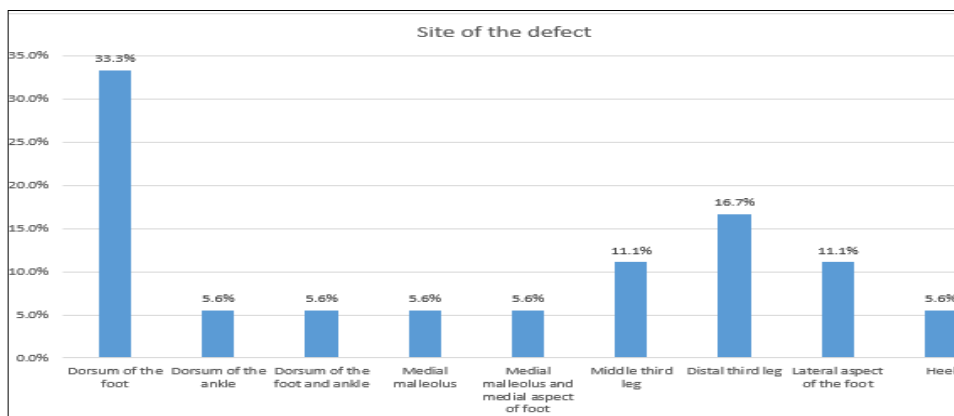


Figure (6) Shows the result of the study

Table (2) Site and size of the defect for study group

		Mean / N	SD / %	Median (IQR)
Site of the defect	Dorsum of the foot	12	33.3%	
	Dorsum of the ankle	2	5.6%	
	Dorsum of the foot and ankle	2	5.6%	
	Medial malleolus	2	5.6%	
	Medial malleolus and medial aspect of foot	2	5.6%	
	Middle third leg	4	11.1%	
	Distal third leg	6	16.7%	
	Lateral aspect of the foot	4	11.1%	
	Heel	2	5.6%	
Size of the defect (CM)		10.00	2.95	10 (7 - 12)
Size of the defect (CM)		5 - 9	14	38.9%
		10 - 14	18	50.0%
		=15	4	11.1%

Table (3) Time of healing for study group

		Mean / N	SD / %	Median (IQR)
Time of healing (Weeks)		1.94	0.74	2 (1 - 2)
Time of healing (Weeks)	Two weeks	16	47.1%	
	Three weeks	8	23.5%	
	One month	10	29.4%	

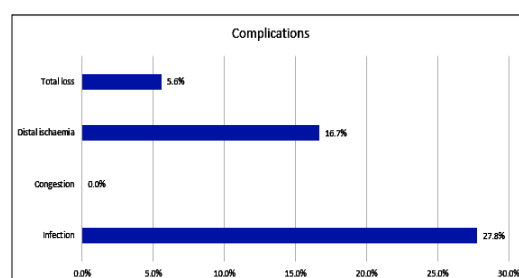


Figure (7) Shows the results of the study

Table (4) Site and size of the defect for study group

		Distal ischaemia		Fisher's Exact test of sig.	
		No	Yes	P-Value	Sig.
		N (%) Mean ± SD	N (%) Mean ± SD		
Fractures	No	14 (87.5%)	2 (12.5%)	0.672	NS
	Yes	16 (80%)	4 (20%)		
Site of the defect	Dorsum of the foot	8 (66.67%)	4 (33.33%)	0.415	NS
	Dorsum of the ankle	2 (100%)	0 (0%)		
	Dorsum of the foot and ankle	2 (100%)	0 (0%)		
	Medial malleolus	2 (100%)	0 (0%)		
	Medial malleolus and medial aspect of foot	2 (100%)	0 (0%)		
	Middle third leg	2 (50%)	2 (50%)		
	Distal third leg	6 (100%)	0 (0%)		
	Lateral aspect of the foot	4 (100%)	0 (0%)		
	Heel	2 (100%)	0 (0%)		
Size of the defect (CM)		9.73 ± 2.94	11.33 ± 2.88	0.23 <sup>(*)</sup>	NS
Size of the defect (CM)	5 - 9	12 (85.71%)	2 (14.29%)	0.217	NS
	10 - 14	16 (88.89%)	2 (11.11%)		
	=15	2 (50%)	2 (50%)		

(\*) Student t-test of significance.

Table (5) Site and size of the defect between 2 groups for study group

		Total loss		Fisher's Exact test of sig.	
		No	Yes	P-Value	Sig.
		N (%) Mean ± SD	N (%) Mean ± SD		
Fractures	No	16 (100%)	0 (0%)	0.492	NS
	Yes	18 (90%)	2 (10%)		
Site of the defect	Dorsum of the foot	12 (100%)	0 (0%)	0.341	NS
	Dorsum of the ankle	2 (100%)	0 (0%)		
	Dorsum of the foot and ankle	2 (100%)	0 (0%)		
	Medial malleolus	2 (100%)	0 (0%)		
	Medial malleolus and medial aspect of foot	2 (100%)	0 (0%)		
	Middle third leg	4 (100%)	0 (0%)		
	Distal third leg	4 (66.67%)	2 (33.33%)		
	Lateral aspect of the foot	4 (100%)	0 (0%)		
	Heel	2 (100%)	0 (0%)		
Size of the defect (CM)		9.71 ± 2.76	15 ± 0	0.011 <sup>(*)</sup>	S
Size of the defect (CM)	5 - 9	14 (100%)	0 (0%)	0.01	S
	10 - 14	18 (100%)	0 (0%)		
	=15	2 (50%)	2 (50%)		

(\*) Student t-test of significance.

## 4. Examples of Case Reports

### 4.1. Case (1)

20 years old male patient came to our ER with crushed foot. Primary repair of wounds and K. wires fixation to metatarsal fractures was done. Follow up after one week show gangrenous 4<sup>th</sup> and 5<sup>th</sup> toes with part of skin of the dorsum of the foot. We did debridement of the

gangrenous toes and skin and cover this soft tissue defect with modified sural flap which saved foot width and preserve normal gait. Stitches were removed after 3 weeks and the patient start weight bearing after healing of other metatarsal fractures, fig. (8).

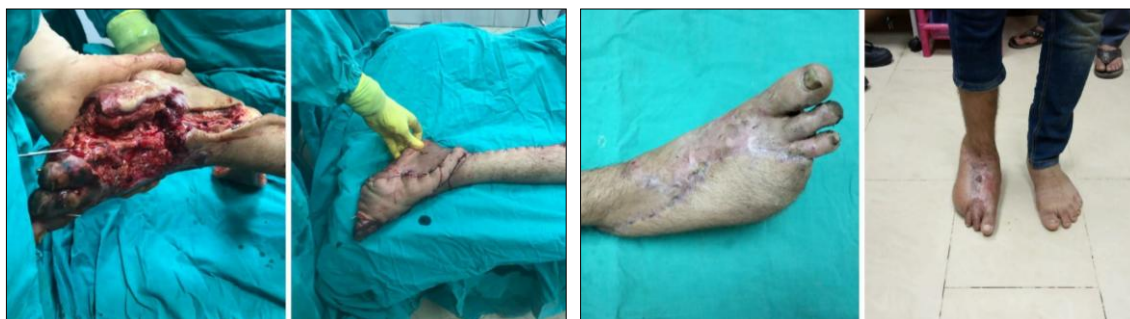


Figure (8) Shows case no, 1

### 4.2. Case (2)

35 years old male patient came to our outpatient clinic with gangrenous heel. Patient history was trauma to the

heel which was degloved and stitched outside. X-ray was done and the bone is free. In the operating theatre debridement

was done and coverage of the heel defect with modified sural flap. We removed stitches after 2 weeks and the patient

was allowed to start weight bearing after another 2 weeks, fig. (9).

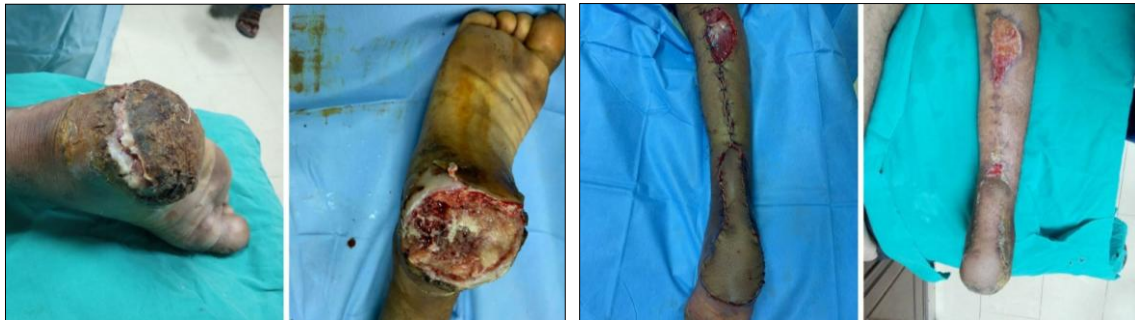

Figure (9) Shows case no, 2

#### 4.3. Case (3)

4 years old female child came to our ER after motor car accident with raw area on dorsum of the foot and ankle with exposed extensor tendons. The patient was clinically evaluated with no problems in head abdomen and chest.

she was hemodynamically stable X-ray was done and the bone was free. In the operating theatre the defect was covered by modified sural flap, we removed the stitches after 2 weeks with full weight bearing, fig. (10).

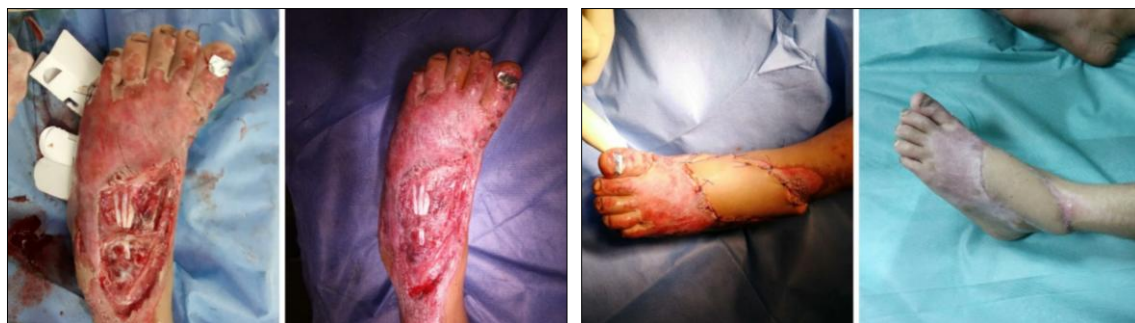

Figure (10) Shows case no, 3

#### 4.4. Case (4)

15 years old male patient came to our outpatient clinic with exposed tibia plate with raw area on medial side of tibia. Patient had fracture shaft tibia fixed by narrow DCP of four months duration. We did X-ray on the leg AP &

Lateral views showing full union of the fracture. In the operating theatre we removed the plate with good debridement of the defect and covered by modified sural flap. We removed the stitches after 2 weeks with full weight bearing, fig. (11).

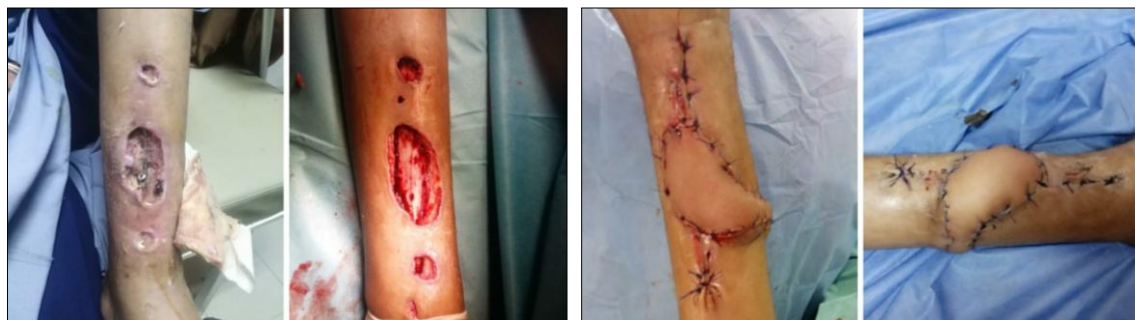

Figure (11) Shows case no, 4



## 5. Discussion

Lower limb has always been known for poor wound healing and soft reconstruction of the lower limb is challenging. The ideal reconstruction technique for both simple and complex defects of the lower limb should replace like to like tissues, minimize donor-site morbidity, preserve main vascular trunks, and reduce operating and hospitalization time. Perforator based flaps meet most of these requirements [17,18]. Reverse-flow sural flap has been proved a valuable tool in the reconstruction of these problematic defects. This flap receives a favorable judgment in the international literature and is recommended for many types of defects of the distal third of the lower leg and the ankle region [19]. In the classic description of the distally based sural flap, the pedicle is dissected from skin and passed through a tunnel between the pivot point and the defect area [20]. In our study the modification was preserving a lane of skin over the pedicle and create an open passage between donor site and the defect which decrease compression over the pedicle so decrease venous congestion and This skin extension would be expected to decrease the compression over the pedicle and offer better survival of the flap by enhancing the blood supply and drainage through the subdermal plexus. No one of cases in our study has developed venous congestion. Anoop C. Dhamangaonkar et al reported preserving a skin paddle demands using an open bridge technique without tunneling the skin between the donor area and the wound. This again prevents the chances of pedicle compression due to suturing the bridge over the pedicle as is done in the conventional sural Fasciocutaneous flap [5]. Anoop C. Dhamangaonkar et al reported that the disadvantage of maintaining the skin over the pedicle while lifting the flap is that it leaves a large donor area defect on the posterior calf that requires a split skin graft. Most of cases needed donor site grafting with 7

cases needed repeated donor site grafting [5]. The present study is not the first report of a skin extension modification. Yilmaz et al reported their clinical experience with 17 sural flaps. After they observed 2 cases of venous congestion and edema using the conventional method, they modified their procedure to leave a skin extension over the pedicle and to use it as a roof of the subcutaneous tunnel. They reported that this modification decreased the tunnel tension, making a larger flap possible [21]. Yavuz Kececi et al reported that opening a comfortable passage between the the pivot point of the flap and the defect area will prevent soft tissue edema making the tunnel narrower and compress the flap pedicle so venous congestion is less likely to occur if the pedicle does not pass through the tunnel [6]. Ayyappan and Chadha presented 5 cases with inclusion of the skin over the pedicle. They did not incise the skin for pedicle passage, instead laying the pedicle directly over the intact skin. They suggested that skin extension is useful modification, because it facilitates better manipulation of the flap and increases the margin of safety [22]. Kececi and Sir reported a case series with a few patients treated with skin extensions. In 6 of the 11 patients, the pedicle was exteriorized using the same method reported by Ayyappan and Chadha [18], with good clinical results. This “exteriorization technique,” which places the pedicle over the intact skin, has some advantages, such as a short operation time, prevention of Achilles tendon scarring, and easier repeat advancement when marginal necrosis occurs. However, drawbacks also exist, including the requirement for a secondary procedure, massive oozing, and wound care difficulty for 2 to 3 weeks [15]. Hyun Il Lee et al reported modification of sural flap by preserving a lane of skin over the flap pedicle which give these advantages (1) prevention of venous congestion induced by pedicle compression, (2) enhancement

of the vascular supply to the flap by a subdermal vascular network of the skin extension, and (3) easy handling of the flap and protection of the pedicle during the procedure [15]. The flap maintains the common disadvantages of Fasciocutaneous flaps: an unaesthetic scar in the donor area and hypoesthesia in the lateral region of the leg and foot. To improve the aesthetics of the scar in the donor area, we tried to limit the cutaneous portion of the flap to a width that allowed primary closure, extending the Fasciocutaneous portion according to the requirements of the wound and subsequently placing a skin graft over it [15]. In our series we made analytical

studies to determine if there are relations between flap viability and presence or absence fractures in the underlying bone. The result was that there are no relations between flap viability and presence or absence of fractures on the underlying bone. Our present study had: some points of strengths that operation was done by the same surgical team, the results were analyzed by independent investigator to avoid investigator bias and the clinical and functional outcome were determined based on standard scores while the points of weakness were the random and relatively small sample size.

## 6. Conclusion

*Venous congestion and distal edge necrosis are the most significant complications of sural flap. Our modification by preserving a lane of skin over the pedicle and open passage for the pedicle between donor and recipient sites decrease these complications by increase venous return of the flap and decrease compression over the pedicle*

## References

- [1] Ahmad, I., Akhtar, S., Rashidi, E., et al. (2013). Hemisoleus muscle flap in the reconstruction of exposed bones in the lower limb. *J. of Wound Care*. 22 (11): 635-642.
- [2] Vendramin, F. (2012). Retalho sural de fluxo reverso: 10 anos de experiência clínica e modificações. *Revista Brasileira de Cirurgia Plástica*. 27: 309-315.
- [3] Nelson, S., Watts, H., (2016). Working in Resource-challenged environments. In: Sabharwal, S. (ed.) *Pediatric Lower Limb Deformities: Principles and Techniques of Management*. Cham, Springer Int. Pub., Germany, 215-228.
- [4] Mendieta, M., Cabrera, R., Siu, A., et al. (2018). Perforator propeller flaps for the coverage of middle and distal leg soft-tissue defects. *Plast Reconstr Surg Glob Open*. 6 (5): e1759-.
- [5] Dhamangaonkar A., Patankar, H. (2014). Reverse sural fasciocutaneous flap with a cutaneous pedicle to cover distal lower limb soft tissue defects: experience of 109 clinical cases. *J Orthop Traumatol*. 15 (3): 225-229.
- [6] Kececi, Y., Sir, E. (2012). Increasing versatility of the distally based sural flap. *The Journal of Foot and Ankle Surgery*. 51 (5): 583-587.
- [7] Sugg, K., Schaub, T., Concannon, M., et al. (2015). The reverse superficial sural artery flap revisited for complex lower extremity and foot reconstruction. *Plast Reconstr Surg Glob Open*. 3 (9): e519.
- [8] Morgan, K., Brantigan, C., Field, C., et al. (2006). Reverse sural artery flap for the reconstruction of chronic lower extremity wounds in high-risk patients. *The Journal of Foot and Ankle Surgery*. 45 (6): 417-423.
- [9] Rios-Luna, A., Fahandezh-Saddi, H., Villanueva-Martínez, M., et al. (2008). Pearls and tips in coverage of the tibia after a high energy trauma. *Indian J Orthop*. 42 (4): 387-394.
- [10] Herter, F., Ninkovic, M., Ninkovic M. (2007). Rational flap selection and timing for coverage of complex upper extremity trauma. *Journal of Plastic, Reconstructive & Aesthetic Surgery*. 60 (7): 760-768.
- [11] Lu, L., Liu, A., Zhu, L., et al. (2013). Cross-leg flaps: Our preferred alter-

- native to free flaps in the treatment of complex traumatic lower extremity wounds. *Journal of the American College of Surgeons*. 217 (3): 461-71.
- [12] Ignatiadis, I., Tsiampa, V., Galanakos, S., et al. (2011). The reverse sural fasciocutaneous flap for the treatment of traumatic, infectious or diabetic foot and ankle wounds: A retrospective review of 16 patients. *Diabetic Foot & Ankle*. 2 (1): 5653.
- [13] Ciofu, R., Zamfirescu, D., Popescu, S. (2017). Reverse sural flap for ankle and heel soft tissues reconstruction. *J Med Life. Jan-Mar*. 10 (1): 94-98.
- [14] Iorio, M., Evans, K., Attinger, C. (2018). Soft tissue reconstructive options for the ulcerated or gangrenous diabetic foot. In: Veves, A., Giurini, J., Guzman, R. (eds). *The Diabetic Foot: Medical and Surgical Management*. Cham, Springer Int. Pub., Germany, 345-390.
- [15] Lee, H., Ha, S., Yu, S., et al. (2016). Reverse sural artery island flap with skin extension along the pedicle. *The Journal of Foot and Ankle Surgery*. 55 (3): 470-475.
- [16] Cui, Z., Zhang, X., Shou, J., et al. (2019). Repeated reverse sural fasciocutaneous flap is an effective surgical strategy for repairing long segmental soft tissue defects of the tibia. *Journal of International Medical Research*. 47 (10): 5003-5009.
- [17] Jordan, D., Malahias, M., Hindocha, S., et al. (2014). Flap decisions and options in soft tissue coverage of the lower limb. *Open Orthop J*. 8: 423-432.
- [18] Yasir, M., Wani, A., Zargar, H. (2017). Perforator flaps for reconstruction of lower limb defects. *World J Plast Surg*. 6 (1): 74-81
- [19] Korompilias, A., Gkiatas, I., Korompilia, M., et al. (2019). Reverse sural artery flap: A reliable alternative for foot and ankle soft tissue reconstruction. *European Journal of Orthopaedic Surgery & Traumatology*. 29 (2): 367-372.
- [20] Herlin, C., Sinna, R., Hamoui, M., et al. (2017). Canovas F, Captier G, Chaput B. Distal lower extremity coverage by distally based sural flaps: Methods to increase their vascular reliability. *Annales de Chirurgie Plastique Esthétique*. 62 (1): 45-54.
- [21] Yilmaz, M., Karatas, O., Barutcu, A. (1998). The distally based superficial sural artery island flap: Clinical experiences and modifications. *Plast Reconstr Surg*. 102 (7): 2358-2367.
- [22] Ayyappan, T., Chadha, A. (2002). Super sural neurofasciocutaneous flaps in acute traumatic heel reconstructions. *Plast Reconstr Surg*. 109 (7): 2307-2313.