

Effect Of Some Aflatoxins On A Lymphatic Organ (Spleen) Of Male Albino Rats (Histopathological Study)

Nahed Ahmed Omar

Department of Zoology, Faculty of Science, Damietta Branch, Mansoura University.

ABSTRACT

Background: The present study was planned to compare between two kinds of aflatoxins (AFB₂ and AF Mix) on spleen of male albino rats. Fifty young male albino rats ,each weighing 50g, were fed on diets containing aflatoxins at concentration of 1.0 ppm either of AFB₂ or AF mix. for 2, 4, 6 weeks followed by a withdrawal period of 2 weeks.

Material and Methods:- Rats were randomly divided into 3 groups: the 1st group of 10 rats was fed on the standard diet. The 2nd and the 3rd groups of 20 rats each were maintained on the standard diet plus either AFB₂ or AF mix. respectively. Ten animals from the latter 2 groups as withdrawal period. Pieces of spleen were subjected to histological procedures and the obtained sections (6 µm thick) were stained with the haematoxylin and eosin, also, mercuric bromophenol blue stain for total protein were used in this study.

Results:- Marked histopathological alterations were observed in the studied sections under the influence of AFB₂ and AF mix. It was found that AFB₂ induced more alterations. The most common changes were lymphocytic degeneration, fatty changes with numerous hemorrhagic areas. The two weeks withdrawal period showed a partial recovery of the developed changes.

Conclusion:- This study indicated that AFB₂ has a toxic effect on spleen than the equivalent level of AF mix. .Great caution must be followed to prevent the possible contamination of our food with such mycotoxins.

Key words:- Aflatoxins – Spleen – Histopathology.

INTRODUCTION

Aflatoxins are metabolites of *Aspergillus flavus* that grow on ground nuts and other food stuffs (Borker, 1966 ; Barnes, 1967), and were confirmed to be toxic (Newberne *et al.*, 1964).

There are two species of *Aspergillus* which are known to produce toxins. The isolated toxigenic *Aspergillus flavus* produces aflatoxin B₁ and B₂, whereas the isolated *A. parasiticus* generally produces aflatoxins B₁, B₂, G₁ and G₂. Aflatoxin B₁ was found to be a potent hepatotoxic and hepatocarcinogenic mycotoxin (Cole and Cox, 1981 ; Rastogi *et al.*, 2001) and caused severe histopathological alterations in liver (Rati *et al.*, 1991). At low level of aflatoxin B₁, the immune function and growth performance in pig were greatly inhibited (Chang and Pan, 1992) and induced liver tumors in rats (Angsubhakarn *et al.*, 1990).

The effects of long-term treatment of three dose levels of aflatoxin B₁ (AFB₁) on

lymphoid cells of weanling rats showed a marked reduction in the population and phagocytic capacity of macrophages due to AFB₁ administration (Raisuddin *et al.*, 1990). Aflatoxin B₁ was toxic to the systemic immune system in various animal species (Watzl *et al.*, 1999). Also, AFB₁ had an the immunosuppressive effect on macrophages after in vivo exposure (Moon *et al.*, 1999). Low level of it inhibited the immune function (Blaney and Williams, 1991 ; Chang and Pan, 1992).

In rabbits, the addition of aflatoxin B₁ to normal diet produced hyperglycaemia and decreased liver glycogen (Verma and Raval, 1992). This was similary met with in chickens (Abdelhamid *et al.*, 1995) and rats (Choi *et al.*, 1981 ; Rastogi *et al.*, 2001). In this respect, the elevation of blood glucose level and the decrease in glycogen in liver by aflatoxin was attributed to lowering insulin level and raising of cortisol (Abdelhamid and Dorra, 1990). Also, giving rats intraperitoneal

dose of 5 and 7 mg/kg of aflatoxin B₁ for 6-72 hrs and 5-10 days was found to decrease acid and neutral mucopolysaccharides in liver of rats (Dutu and Maltezeanu, 1976). Several investigations have shown the serious effects of aflatoxins on liver, lymphocytes, macrophages and lung.

In chicks, AFB₁ treatment decreased both humoral and cell-mediated immune response in growing chicks at dose level of 1mg/Kg diet (Sirajudeen *et al.*, 2011).

Toxic effects of human on T-lymphocyte (Dugyala and Sharma, 1996) and/or other lymphoid cells, the cytotoxic T-cells and natural killer cells (Methenitou *et al.*, 2001), which impair the function of direct or indirect killing of tumor cells, can have pronounced tumorigenesis effects. The inflammatory mechanisms are initiated when various organs have been damaged by toxic assault (Batey and Wang, 2002). AFB₁ effects on the immune system were dependent on dose and time (Hinton *et al.*, 2003). On the other hand, the reticular fibers in spleen cat, see small rings in the periphery of white pulp with toxin effect (Osuji *et al.*, 2005).

MATERIAL AND METHODS

50 male albino rats (*Rattus norvegicus*) weighing about 50g were obtained from the animal Station in Helwan, Cairo, Egypt. Animals were offered the standard diet (Meyer *et al.*, 1980) and water were daily provided *ad libitum*. For accommodation, rats were kept in the animal house for one week before experimentation. Then, the animals were randomly divided into 3 groups. The first group, of 10 rats, served as control and was given the standard diet only. The second group, of 20 animals was fed on the standard diet containing aflatoxin B₂ (AFB₂) (1.0 ppm AFB₂). 10 animals of this group were sacrificed after 6 weeks to examine the effect of AFB₂, the other 10 animals were left for 2 weeks feeding only on the standard diet to examine the effect of the withdrawal period. The 3rd group, of 20 animals was given on aflatoxin mixture (AF mix) (AFB₁, AFB₂, AFG₁ and AFG₂) mixed with the diet which contained 1.0 ppm of AF mix for each Kg of diet. From this group, 10 rats were sacrificed after 6 weeks to analyze the effect of AF mix, while the other 10 rats were left for extra 2 weeks as withdrawal period feeding only on the standard diet. AF mix contains AFB₁, AFB₂, AFG₁ and AFG₂ in a ratio 1: 1/2: 1/4 :

1/8 respectively. Pure AFB₂ and AF mix were obtained from Sigma Company, USA.

After 2, 4 and 6 weeks, pieces of spleens were taken, fixed in aqueous Bouin for 24 hrs and Carnoy's fluid, dehydrated, cleared and embedded in paraplast. Sections of 6µm in thickness were subjected to histopathological demonstration and stained with haematoxylin and eosin (Drury and Wallington, 1980). Also, we stained total proteins by mercuric bromophenol blue method (Mazia *et al.*, 1953).

RESULTS

The Histopathological Changes:-

In spleen of control untreated rat, the typical structure of spleen was microscopically evident. The red pulp, white pulp and eccentric artery (Fig. 1).

In rats fed on AFB₂ & AF mix for 2 weeks, the spleen showed degeneration and blood hemorrhage, pools of RBCs, numerous degenerated blood cells, megakaryocyte and bizarre arrangement of WBCs in the white pulp (Figs. 2&3).

In rats fed on AFB₂ & AF mix for 4 weeks, the spleen showed numerous necrotic area, highly congested blood sinuses, numerous areas which contained debris of ruptured degenerated cells, highly distorted white pulp, bizarre arrangement of T & B lymphocytes in it, thickened arterial wall with narrow lumen of it (Figs. 4&5).

In rats fed on AFB₂ & AF mix for 6 weeks, the spleen revealed numerous highly atrophied white pulp, haemosidrin granules, haemolysed RBCs with highly dilated and congested vein and some necrotic areas (Figs. 6a,b &7).

After 2 weeks withdrawal period showed somewhat normal appearance of the white pulp, but the red pulps were contained congested blood sinuses (Fig. 8) and somewhat normal appearance of the splenic tissue, but some degenerated areas were still detected (Fig. 9).

In the figures stained with mercuric bromophenol blue for total proteins, the splenic tissue of a control rat detected normal distribution of it with densely stained RBCs in the red pulp with less stained in white pulp (Fig. 10).

In rats fed on AFB₂ for 2, 4 & 6 weeks, the spleen showing highly dilated and congested trabecular vein which contained faintly stained with highly reduced total

protein in white and red pulps, poorly stained white pulp with negatively stained numerous degenerated areas, haemosidrin granules acquired black coloration and dilated wall of the congested trabecular vein contained haemolysed RBCs and numerous haemosidrin granules (Figs. 11a,b, 12a,b, & 13a,b,c,d.).

After 2 weeks withdrawal period in this treatment AFB₂, showed somewhat normal appearance of total protein was observed (Fig. 14).

In rats fed on AF mix for 2, 4, & 6 weeks, there were increased stain affinity in the

white pulp, dark coloration of haemosidrin granules and necrotic areas were poorly stained. Thickened, branched and elongated trabecula were moderately stained with a slight increased stain affinity in the red pulp (Fig. 15, 16, & 17).

After 2 weeks withdrawal period treatment with AF mix showed less stained white pulp, moderately stained thickened arterial wall with numerous faintly stained areas in the red pulp, but some congested blood sinuses were deeply stained (Fig. 18).

Explanations of Figures :-

1- Haematoxylin and eosin stains:-

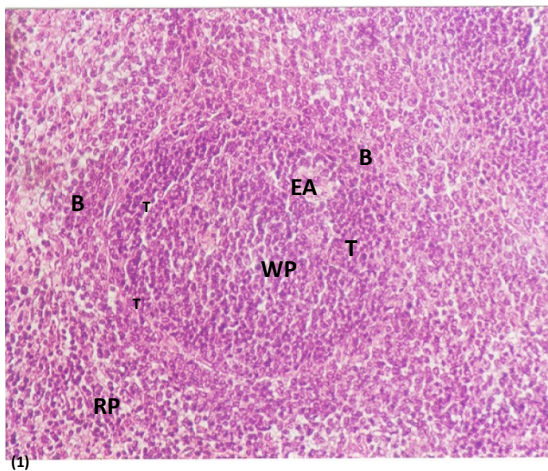


Fig. 1. Photomicrograph of spleen of the control rat, the typical structure of spleen was evident. T&B lymphocytes, the red pulp (RP) , white pulp (WP) and eccentric artery(EA). (H&E, 200X).

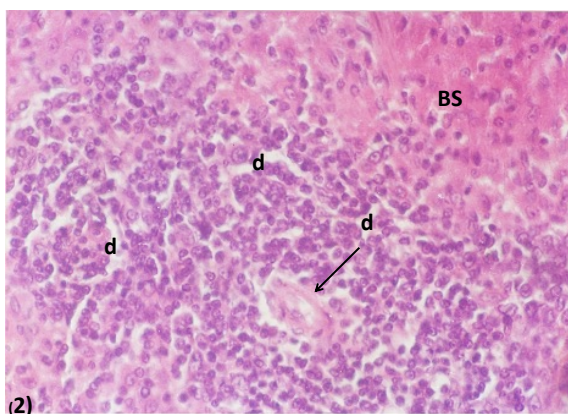


Fig. 2. Photomicrograph of spleen of a rat treated with AFB₂ for 2 weeks, the spleen tissue displayed degeneration (d), congested blood sinuses (BS) and highly dilated arterial wall (arrow) . (H&E, 400X).

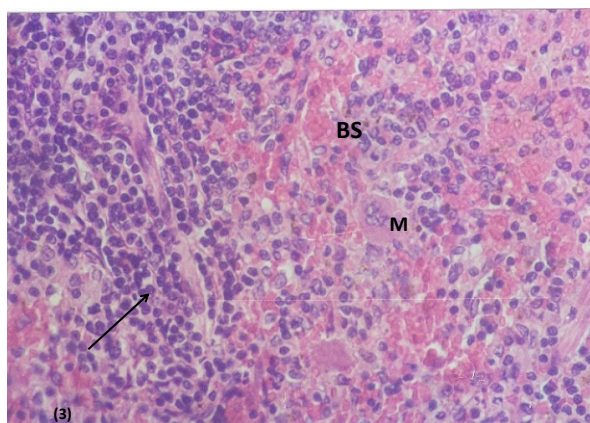


Fig. 3. Photomicrograph of spleen of a rat treated with AF mix. for 2 weeks, the spleen showing congested blood sinuses (BS), pools of RBCs, numerous degenerated blood cells, megakaryocyte (M) and bizarre arrangement of WBCs in the white pulp (arrow). (H&E, 400X).

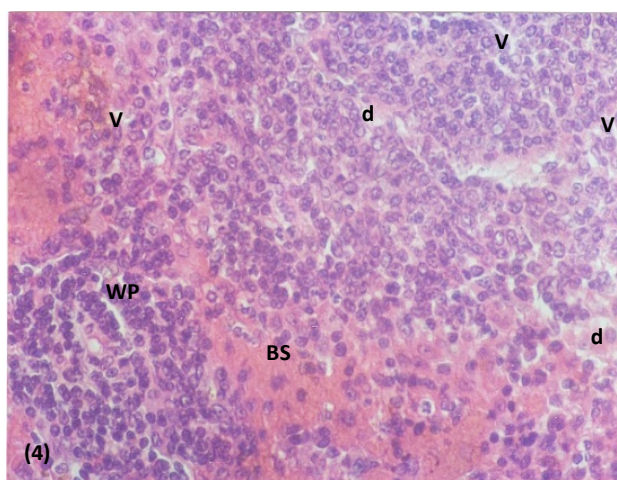


Fig. 4. Photomicrograph of spleen of a rat after 4 weeks treatment with AFB₂, the spleen showed numerous degenerated areas (d) highly congested blood sinuses (Bs), numerous vacuolated cells (V). (H&E, 400X).

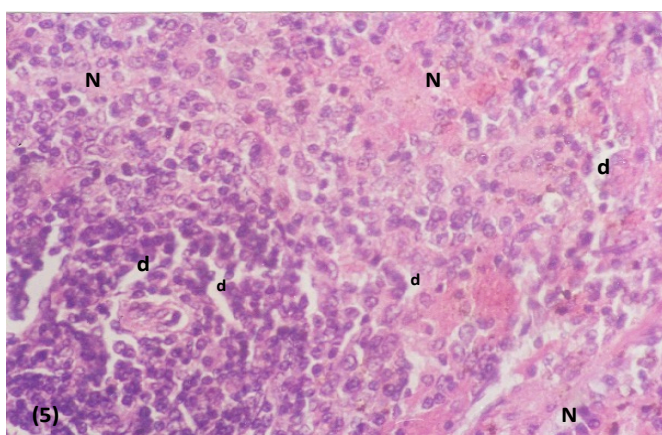
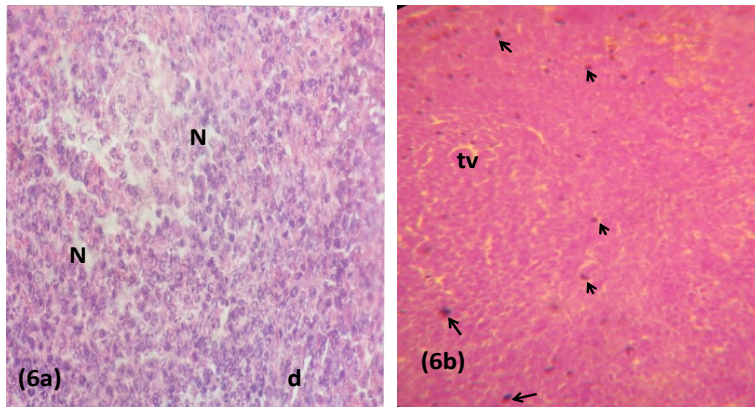


Fig. 5. Photomicrograph of spleen of a rat after 4 weeks treated with AF mix. Numerous degenerated areas which contained debris of ruptured degenerated cells, highly distorted white pulp, bizarre arrangement of T & B lymphocytes in the white pulp, thickened arterial wall with narrow lumen of it, numerous degenerated and necrotic areas. (H&E, 400X).



Figs. 6 a&b. Photomicrographs of spleen of a rat after 6 weeks, in rat treated with AFB₂, the spleen tissues showing numerous atrophied white pulps, haemosiderin granules (arrow), haemolysed RBCs with highly dilated and congested trabecular vein (tv) and some necrotic areas(N). (H&E, 400X).

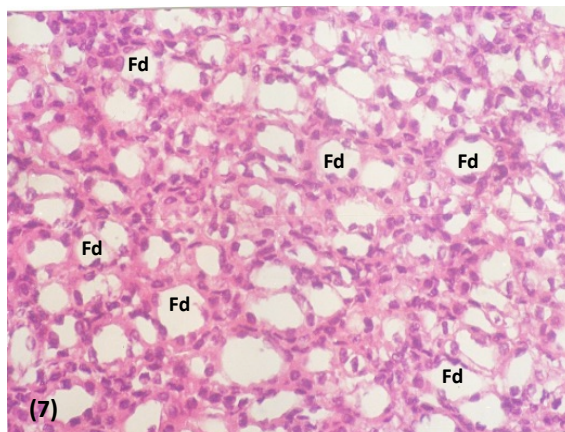
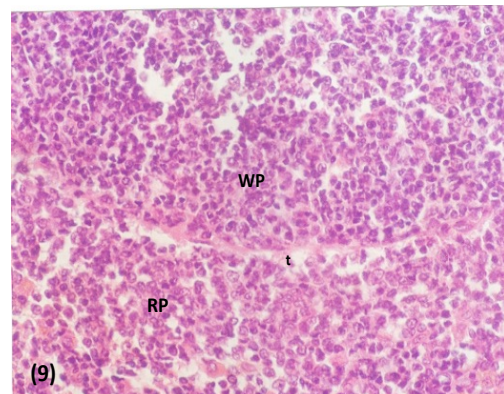
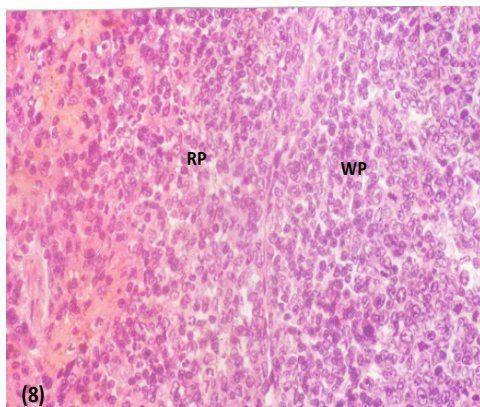


Fig. 7. Photomicrograph of spleen of a rat after 6 weeks treated with AF mix. spleen tissue showed fatty degeneration(Fd) in the lymphocytes of the white pulp with numerous(Fd). (H&E, 400X).



Figs. 8 & 9. Photomicrographs of spleen of a rat after 2 weeks as a withdrawal period from AFB₂ and AF mix. The spleen tissue showed some clear signs of spleen tissue repair. The red and white pulps appeared with more defined outlines, but some degenerated areas were still detected. (H&E, 400X).

2-The results of total protein with mercuric bromophenol blue stain:-

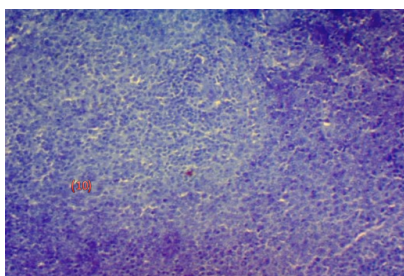
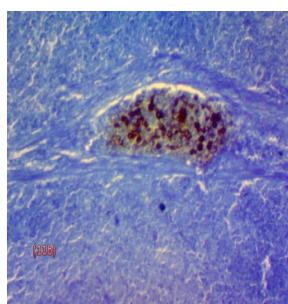
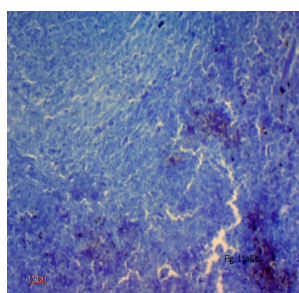
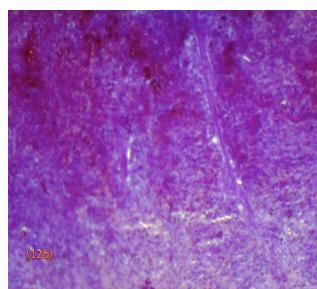
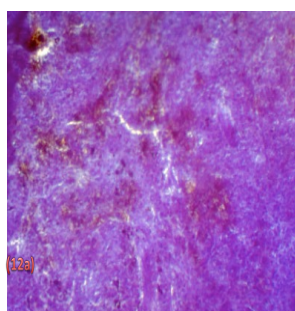


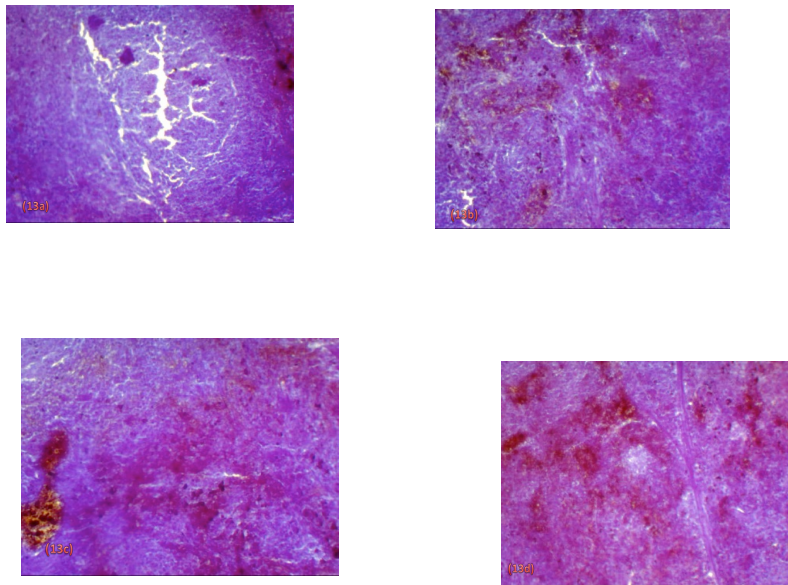
Fig. 10 . Photomicrograph of a spleen showing normal distribution of total protein in the splenic tissue of a control rat. Notice densely stained RBCs in the red pulp with less stained white pulp. (mercuric bromophenol blue, 100X).



Figs. 11a,b AFB₂ after 2 weeks, the photomicrographs showed highly dilated and congested trabecular vein which contained faintly stained, haemolysed protein of RBCs with highly reduced total protein in white and red pulps. The degenerated areas were negatively stained with less stained arterial wall. (mercuric bromophenol blue, 100X).



Figs. 12a,b AFB₂ after 4 weeks, the photomicrographs showed deeply stained pools of RBCs in the red pulps, numerous aggregated haemosiderin granules, necrotic and degenerated areas which poorly or negatively stained, highly elongated trabecula was negatively stained. (mercuric bromophenol blue, 100X).



Figs. 13a,b,c & d. AFB₂ after 4 weeks, the photomicrographs showed poorly stained white pulp with negatively stained numerous degenerated areas in it, congested blood sinuses in the red pulp appeared deeply stained, haemosidrin granules acquired black coloration, degeneration and branched trabeculae were moderately stained, highly atrophied white pulps were poorly stained, dilated wall of the congested trabecular vein contained haemolysed RBCs and congested haemosidrin granules. (mercuric bromophenol blue, 100X).

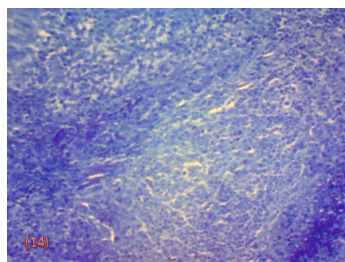


Fig. 14. AFB₂ after 2 weeks of withdrawal period, the photomicrograph showing somewhat normal appearance of the white and red pulps. (mercuric bromophenol blue, 100X).

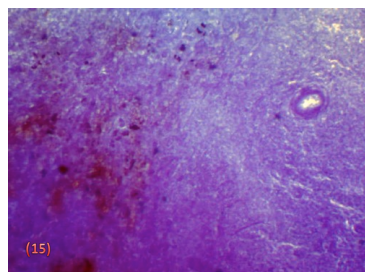


Fig. 15. AF mix after 2 weeks, the photomicrograph showing thickened arterial wall of the white pulp and congested blood sinuses acquired increased stain affinity, numerous aggregations of haemosidrin granules showed dark coloration, necrotic areas were poorly stained. (mercuric bromophenol blue, 100X).

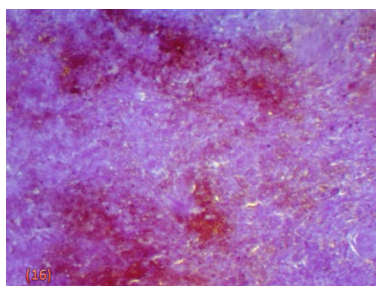


Fig. 16. AF mix after 4 weeks, the photomicrograph showing numerous aggregation of dark haemosiderin with deeply stained congested blood sinuses. (mercuric bromophenol blue, 100X).

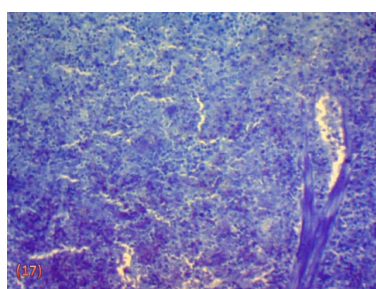


Fig. 17. AF mix after 6 weeks, the photomicrograph showed that thickened branched and elongated trabecula was moderately stained with a slight increase stain affinity in the red pulps. (mercuric bromophenol blue, 100X).

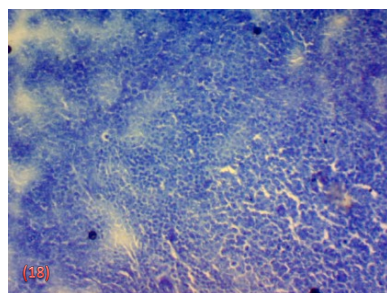


Fig. 18. AF mix after 2 weeks withdrawal period, the photomicrograph showed that highly atrophied white pulps were less stained, also moderately stained arterial wall was detected. Fatty vacuoles showed pale stain affinity but some congested blood sinuses were deeply stained. (mercuric bromophenol blue, 100X).

DISCUSSION

The histopathology evaluation of the spleen presented here suggested that AFB caused damage to splenic cells as exemplified by the vacuolar degenerated. This change was more pronounced after treatment by AF mixture. It was known that AFB₁ affects immune function in various animal species (Gaylor *et al.*, 1992). There were early

reports of a slight inflammatory response in rats due to AFB₁-induced injury in the liver (Butler, 1970). Suppression of the inflammatory response via suppression of kupffer cell activation in the liver by AFB₁ is in agreement with suppression of macrophage function as seen in the splenic histopathology (Hinton *et al.*., 2001& 2003). Also, the

changes with histopathology evaluation of the spleen with emphasis on the cell populations involved in the inflammatory response (Kodell *et al.*, 1987, Murdoch *et al.*, 1992). Immunotoxic effects of aflatoxin have been well documented in poultry (Celik *et al.*, 2000 ; Ortatatli *et al.*, 2005 ; Sur and Celik, 2005). Sur *et al.*, (2012) demonstrated that the dose caused slightly lymphoid cell depletion in lymphoid organs. Dietary aflatoxin induced immunosuppression in broilers and affected the thymus, bursa of Fabricius and spleen (Celik *et al.*, 2000 ; Ortatatli *et al.*, 2005). The hampered functioning of macrophages may be due to the cytotoxic action of AFB₁ (Raisuddin *et al.*, 1993). By used mercuric bromophenol blue stain for demonstration total protein in the present study, it showed pale stained affinity in splenic tissues in both treatments. After a withdrawal period for 2 weeks from AFB₂ and aflatoxin mix. the present data showed a partial recovery of splenic cells with some clear signs of repair. The red and white pulps appeared with more defined outlines.

REFERENCES

- 1-Abdelhamid AM, Arief H S M, Elkeraby F. and Dorra T M. (1995): Effect of some dietary supplements to aflatoxic diets of chicken II- effect on the tissue analysis. *J. Agric. Sci. Mansoura Univ.*, 20 (7) : 3227-3250.
- 2-Abdelhamid AM and Dorra TA. (1990): Study on the effect of feeding laying hens on separate mycotoxins (aflatoxin, patulin, or citrinin) contaminated diets on the egg quality and tissue constituents. *Arch. Anim. Nut., Berlin*. 40 (4): 305-315.
- 3-Angsubhakarn S, Get-Ngern P, Miyamoto M. and Bhamarapravati N. (1990): A single dose response effect of aflatoxin B₁ on rapid liver cancer induction in two strains of rats. *Int. J. Cancer*, 46: 664-668.
- 4- Barnes JM. (1967): Toxic fungi with special reference to aflatoxin. *Trop. Sci.*, 9: 64-75.
- 5-Batey RG. and Wang I. (2002):- Molecular pathogenesis of T lymphocyte induced liver injury in alcoholic hepatitis. *Front. Biosci.*, 7: 1662-1675.
- 6- Blaney BK and Williams KC. (1991) : Effective use in livestock feeds of mouldy and weather damage grain containing mycotoxins. Case histories and economic assessments pertaining to pig and poultry industries of Queensland. *Australian J. of Agricultural Research*, 42 : 995-1012.
- 7-Borker E. (1966):Mycotoxins feeds. *Adv. Appl. Microbiol.*, 8: 315-325.
- 8-Butler WH. (1970) : Liver injury induced by aflatoxin. *Prog. Liver Dis.*, 3: 408-418.
- 9-Chang C and Pan F. (1992) : Effects of low level aflatoxin on the immune function and growth performance of swine. M. Sc. Thesis, DVM, NTU, Taipei. Taiwan.
- 10-Choi YK, Jung KK, Chae KY, Jang I, Lee BD, Cole RA. and Cox RH.(1981): Handbook of Toxic Fungal Metabolites. New York: Academic Press. Inc., 1.
- 11-Celik I, Oguz H, Demet O, Donmez HH, Boydak M and Sur E. (2000): Efficacy of polyvinylpyrrolidone in reducing the immunotoxicity of aflatoxin in growing broilers. *British Poultry Science*, 41(4): 430-439.
- 12- Cole RA and Cox RH. (1981): Handbook of Toxic Fungal Metabolites. New York, Academic Press. Inc 1.
- 13- Drury R and Wallington E.(1980): Carleton's Histological Technique, 4th Ed. Oxford. Univ. Press, New York, Toronto. Pp.:115-119.
- 14-Dugyala RR and Sharma RP. (1996):-The effect of aflatoxin B₁ on cytokine in RNA and corresponding protein levels in peritoneal macrophages and splenic lymphocytes *Int. J. Immunopharmacol.*, 18: 599-608.
- 15-Dutu R and Maltezeanu G (1976): Histochemical manifestations of early and late changes induced by aflatoxin in rats. *Acta. Histochem.*, 57 (1): 34- 43.
- 16-Gaylor DW, Kadlubar FF, and Beland FA (1992) : Application of biomarkers to risk assessment. *Environ. Health Perspec.*, 98: 139-141.
- 17-Hinton DM, Myers MJ, Pertlioni A, Hines F, Raybourne RB, Sotomayor RE, Shaddock J, Warbritton A Chou, M and Pestka JJ (2001):-Enhanced histopathology with morphometry, immune-and in-situ staining in immunotoxicity studies of the mycotoxins, aflatoxin B₁ (AFB₁) and deoxynivalenol (DON) *Toxicologist*, 60: 1947-1957.
- 18-Hinton DM, Myers MJ, Raybourne RB, Carroll SF, Raybourne RB, Shaddock J, Warbritton A and Chou MW (2003): Immunotoxicity of aflatoxin B₁ in rats : Effects on lymphocytes and inflammatory response in a chronic intermittent dosing study. *Toxicological Sci.*, 73: 362-377.
- 19-Kodell RL, Gaylor DW and Chen JJ (1987): Using average lifetime dose rate for intermittent exposures to carcinogens. *Risk Anal.*, 7: 339-345.
- 20- Mazia D, Brewer P and Alfert M (1953): The cytochemical staining and measurement of protein with mercuric bromophenol blue. *Bull.*, 104:57-67.
- 21-Meyer H, Bronsch K Und Leibetsder J (1980): (Suppl) zu vorlesungen und ubungen in der

- tiernahrung. S-neu bearbeitete und erweiterte auflage verlag 8 prungmann, Hannover.
- 22- Methenitou G, Maravelias C, Athanaselis S, Dona A and Koutselinis A (2001): Immunomodulative effects of aflatoxins and selenium on human natural killer cell. *Vet. Hum. Toxicol.*, 43: 232-234.
- 23-Moon EY, Rhee DK and Pyo S (1999): Inhibition of various functions in murine peritoneal macrophages by aflatoxin B₁ exposure *in vivo*. *International Journal of immunopharmacology*, 21: 47-58.
- 24-Murdoch DJ, Krewski D and Wargo J (1992): Cancer risk assessment with intermittent exposure. *Risk Anal.*, 12: 569-577.
- 25-Nahm KK (1995): Effects of vitamin E and selenium supplementation to diets containing aflatoxin B₁ on the contents of liver lipids and various blood parameters in rats. *Asian- Austral. J. Anim. Sci.*, 8(4): 379-389.
- 26-Newberne PM, Carlton WW and Wogan GN. (1964): Hepatomas in rats and hepatorenal injury in duckling fed peanut meal or *Aspergillus flavus* extract. *Path. Vet.*, 1: 105-132.
- 27- Ortatatli M, O'guz H, Hatipoğlu F and Karaman M. (2005): Evaluation of pathological changes in broilers during chronic aflatoxin (50 and 100ppb) and clinoptilolite exposure. *Research in Veterinary Science*, 78(1): 61-68.
- 28-Osuji, Matutes E, Catovsky D, Lampert I and Wortherspoon A (2005): Histopathology of the spleen in T- cell large granular. *Am. J. Surgpathol*, 29(7):935-941.
- 29-Raisuddin, Singh KP, Zaidi SIA, Paul BU and Ray PK (1993) : Immunosuppressive effects of aflatoxin in growing rats. *Mycopathologia*, 124(3): 189-194.
- 30-Raisuddin, Singh KP, Zaidi S IA, Saxena AK and Ray PK (1990): Effects of aflatoxin on lymphoid cells of weanling rat. *J. App.Toxicol.*, 10(4):245-250.
- 31-Rastogi R, Srivastava AK and Rastogi AK. (2001): Long-term effect of aflatoxin B₁ on lipid peroxidation in rat liver and kidney:Effect of picroliv and silymarin. *Phytother.Res.*, 15(4):307-310.
- 32-Rati ER, Shantha T and Ramesthtl P(1991): Effect of long term feeding and withdrawal of aflatoxin B₁ and ochratoxin A on kidney cell transformation in albino rats. *Ind. J. Exp Bio.*, 29(9): 813-817.
- 33-Sirajudeen M, Gopi K, Tyagi JS, Moudgal RP, Mohan J and Singh R (2011): Protective effects of melatonin in reduction of oxidative damage and immunosuppression induced by aflatoxin B₁ – contaminated diets in young chicks. *Environ. Toxicol.*, 26(2):153-160.
- 34- Sur E and Celik I (2005): Effects of aflatoxin B₁ on the development of chicken thymus and blood lymphocyte alpha-naphthyl acetate esterase activity. *Vlaams Diergeneeskundig Tijdschrift.*, 74(6):432-439.
- 35- Sur E, Donmez HH, Boydak M and Ataman MB (2012): Effects of glucomannan on the sacculus rotundus and peripheral blood lymphocytes in New Zealand rabbits during aflatoxicosis. *The Scientific World Journal*. Under publication.
- 36-Verma RJ and Raval PJ (1992): Morphological alteration in rabbits under aflatoxin- induced Toxaemia. *J. Anim. Morphol. Physiol.*, 39: 95-98.
- 37-Watzl B, Neudcker C, Hansch GM, Rechkemmer G and Pool-Zobel BL (1999) : Short-term moderate aflatoxin B₁ exposure has only minor effects on the gut-associated lymphoid tissue of Brown Norway rats. *Toxicology*, 5(2): 93-102.

تأثير بعض الأفلاتوكسينات علي عضو ليمفي طحال ذكر الجرذ الأبيض (دراسة نسيجية)

ناهد أحمد عمر

قسم علم الحيوان - كلية العلوم بدمياط جامعة المنصورة

تمت الدراسة لمقارنة نوعين من السموم الفطرية من الأفلاتوكسينات (أفلاتوكسين ب₂ وخليط الأفلاتوكسينات) علي طحال ذكور الجرذان البيضاء.

تم تغذية عدد 50 من ذكور الجرذان البيضاء بعليقة متوازنة محتوية علي 1 مجم/كجم من وزن الجسم أفلاتوكسين (أفلاتوكسين ب₂ وخليط الأفلاتوكسينات) .

تم تجهيز قطاعات شمعية من الطحال لفحصها هستولوجيا بصبغة الهيماتوكسلين والإيوسين وكذلك صبغة البروموفينول الأزرق لفحص البروتين الكلي بأنسجة الطحال بعد أسبوعين و 4 أسابيع و 6 أسابيع وذلك مقارنة بمجموعة ضابطة (العليقة المتوازنة فقط)، تلي ذلك أسبوعين لإنسحاب الأفلاتوكسينات من الجرذان.

وقد أدت المعالجة بأفلاتوكسين ب₂ وكذلك بخلط الأفلاتوكسينات إلي تغير الشكل الطبيعي للطحال وظهور اضمحلال في خلايا الطحال وظهور نزيف دموي وفجوات دهنية وكذلك ظهور اختلافات عديدة بكمياء الأنسجة في محتوى البروتينات الكلية بخلايا الطحال مقارنة بالمجموعة الضابطة.

أما انسحاب المواد السامة من الجرذان لمدة أسبوعين فقد أظهر تحسنا واضحا في أنسجة الطحال وأكدت نتائج الفحوصات النسيجية أن المعالجة بأفلاتوكسين ب₂ منفردا قد أحدث تأثيرات أقوى علي النسيج من خلط الأفلاتوكسينات المكافئ له في الجرعات المعطاة علي أنسجة الطحال .