
A comparative study on the effect of black cherry powder , ethanolic extract and atorvastatin on hyperlipidemic rats

Suzan S. Ibraheim& Wesam M. Abd-Elrahman *

Abstract

Hyperlipidemia is one of the most public health problems in the modern era that increase the risk of several comorbidities such as cardiovascular disease and cancer. So that; this study was intended to compare the effect of black cherry (dried and ethanolic extract) with Atorvastatin (ator) in hyperlipidemic rats with hepatic injury. Thirty male albino rats weighing 190 ± 10 g used in this study and divided into equal five groups (6 rats each), **Group (1)**, as negative control group (-v) control received basal diet throughout the experiment period, while four others groups fed on high fat high fructose diet for 4 weeks to induce hyperlipidemia and divided into sub main groups: **group (2)**:as positive control group (+v) , **group (3)**:received daily gavages of atorvastatin (5mg/kg) , **group (4)**:received supplemented diet with dried black cherry(10%) and **group (5)**: received daily gavages of ethanolic extract black cherry (500 mg/kg) via a stomach tube . At the end of the experimental period (8 weeks), the feed intake (FI), body weight gain (gm.), feed efficiency ratio (FER) and relative liver weight were calculated. Serum liver enzymes (ALT, AST and Alp), total cholesterol, triglycerides, HDLc and LDLc and histopathological changes of liver were examined. Total antioxidant and total polyphenols and flavonoids for black cherry

* Nutrition and Food Science Dept., Faculty of Home Economics, Al-Azhar University, Egypt

extract were analyzed. The obtained results concluded that using black cherry (dried and ethanolic extract) improved all above biological and biochemical parameters. Total (Phenolic, flavonoids and antioxidant) contents were (4.39 ± 0.33 & 6.53 ± 0.46 and 85.94 ± 1.67) in black cherry respectively. The best results found by using ethanolic extract of black cherry that showed results closed to atorvastatin. Total phenolic content, total flavonoids content and antioxidant activity demonstrated that black cherry could be considered as a good source for polyphenols and other antioxidant compounds. According to the results, black cherry (dried and extract) could be used for improving lipid profile and liver functions in hyperlipidemic rats. **Key words:** triglyceride- total cholesterol-liver enzymes- total antioxidant- flavonoids.

دراسة مقارنة حول تأثير المسحوق والمستخلص الإيثانولي للكرز الأسود

وعقار الأتورفاستاتين في الجرذان المصابة بارتفاع دهون الدم

المستخلص العربي

يعتبر ارتفاع دهون الدم من أكثر مشاكل الصحة العامة في العصر الحديث والتي تزيد من خطر الإصابة بالعديد من الأمراض المصاحبة مثل أمراض القلب والأوعية الدموية والسرطان. ولهذا أجريت هذه الدراسة لمقارنة تأثير الكرز الأسود (المسحوق والمستخلص الإيثانولي) مع أتورفاستاتين (أتور) في الجرذان المصابة بارتفاع دهون الدم و إصابة الكبد. تم استخدام ثلاثين فأر ذكر ألبينو وزنها 190 ± 10 جراماً في هذه الدراسة. قسمت إلى خمس مجموعات متساوية (٦ فئران في كل مجموعة). المجموعة (١)، حيث تلقت المجموعة الضابطة السلبية (-v) نظاماً غذائياً أساسياً طوال فترة التجربة، بينما المجموعات الأربعة الأخرى تم تغذيتها على نظام غذائي غني بالدهون وعالي الفركتوز لمدة ٤ أسابيع لاحداث ارتفاع دهون الدم وقسمت إلى مجموعات رئيسية فرعية: المجموعة (٢): كمجموعة ضابطة إيجابية، المجموعة (٣): تلقيت جرعات يومية من أتورفاستاتين (٥ مجم / كجم) عبر الانبوبة المعدية، مجموعة (٤): تلقيت حمية مدعمة بمسحوق الكرز الأسود (١٠٪) والمجموعة (٥): تلقيت جرعة يومية من مستخلص الكرز الأسود الإيثانولي (٥٠٠ مجم / كجم) عن طريق أنبوب المعدة في نهاية فترة التجربة (٨ أسابيع) تم حساب كلا من المأخوذ الغذائي، وزن الجسم

المكتسب بالجرام , معدل كفاءة الغذاء والوزن النسبي للكبد . وتم فحص إنزيمات الكبد في الدم (ALT ، AST ، AIP) , الكوليسترول الكلي ، الدهون الثلاثية ، HDLc و LDLc والتغيرات النسيجية المرضية للكبد. تم تحليل إجمالي مضادات الأكسدة الكلية والبولي فينول والفلافونويدات في مستخلص الكرز الأسود. وخلصت النتائج التي تم الحصول عليها إلى أن استخدام مسحوق ومستخلص الكرز الأسود أدى إلى تحسن جميع التحاليل البيولوجية والبيوكيميائية. الجلوتاثيون (GSH). وقد كان المحتوى الكلي للفينولات والفلافونويدات ومضادات الأكسدة علي التوالي كما يلي (4.39 ± 0.33 , 6.53 ± 0.46 , 85.94 ± 1.67). أفضل النتائج التي تم التوصل إليها باستخدام المستخلص الإيثانولي للكرز الأسود حيث أظهرت نتائج قريبة من عقار الأوتورفاستاتين. أظهر المحتوى الفينولي الكلي ومحتوى الفلافونويد الكلي والنشاط المضاد للأكسدة أن الكرز الأسود يمكن اعتباره مصدرًا جيدًا للبوليفينول ومركبات مضادات الأكسدة الأخرى. وفقًا للنتائج ، يمكن استخدام مسحوق ومستخلص الكرز الأسود لتحسين دهون الدم ووظائف الكبد في الفئران المصابة بارتفاع دهون الدم.

الكلمات المفتاحية: جلسريدات ثلاثية- كوليستيرول كلي- إنزيمات الكبد- مضادات الأكسدة الكلية- الفلافونويدات

INTRODUCTION

Hyperlipidemia is a group of metabolic disorders characterized by the elevated levels of lipids that include cholesterol, cholesterol esters, phospholipids and triglycerides (Karam *et al.*, 2018). Lipid disorders are not depend on total serum cholesterol, but also on its distribution among different lipoproteins. The low density lipoproteins (LDL) are the major carriers of cholesterol towards tissues having atherogenic potential, while the high density lipoproteins (HDL) carry cholesterol from peripheral tissues to the liver. HDL thus gives protection against many cardiac problems and obesity. Although genetic factors recline behind these lipid disorders (Thirumalai *et al.*, 2014).

High-fat diet induces the development of metabolic syndrome, which consists of oxidative stress, initiated atherogenic dyslipidemia, a pro-inflammatory and pro-thrombotic state, high blood pressure, central obesity and cardiovascular disease (**Lasker et al., 2019**). Also, it has been established that consumption high amounts of refined carbohydrates (fructose) increases the risk of hyperlipidemia and may affect the liver (**Lozano et al., 2016**).

Atorvastatin is a synthetic type of HMG-CoA analogue that exhibits a substantial efficacy for decreasing total and low – density lipoprotein cholesterol (LDL) levels, triglycerides and modification of lipoprotein composition (**Abdelhalim and Somaia et al., 2019**).

Medicinal plants are a principal source in health care about 80 % world's population in the form of plant extracts or their active components as a result of their properties (**Shorinwa and Monsi, 2020**) . Several studies in animal models and in human subjects have actually confirmed that phenols in fruits and vegetables are bioavailable and protect against oxidative stress and free radical (**Luna-Vázquez, et al., 213**).

The cherry is a small nutrient-rich fruit garnering a great deal of attention as a no pharmacologic option for the treatment of a multitude of disease manifestations in recent years. Cherries contain vitamins A, C, E, and phenolic such as anthocyanin (**Collins et al., 2019**). Black cherry (*prunus serotina*) fruits possess a high content of phenolic compounds and display a significant antioxidant capacity. Phenolic composition of fruits strongly depends on ripening, genetic, and environmental factors. In the case of cherry fruits, it has been demon-

strated that phenolic compounds contributing to their antioxidant capacity differ significantly across species and variety within species (**Luna-Vázquez *et al.*, 213**).

Current scientific research results confirm the beneficial properties of black cherry extracts. The black cherry preparations can be a valuable raw material used in the food, pharmaceutical, and cosmetics industries as a source of bioactive compounds with multidirectional antioxidant activity (**Telichowska *et al.*, 2020**).

The objective of this study was to determine the effects of Black cherry as powder and extract on the level of serum lipid profile, liver function markers in rats fed high-fat diet.

MEATERIALS AND METHODS

Materials

- Fruits of black cherry were obtained from local market, Tanta, Egypt.
- Atorvastatin (Lipitor drug; LP) was obtained from Pfizer Company (Cairo, Egypt). Other chemicals used in this study were purchased from Sigma Chemical Co.
- The basal diet was prepared according to **Reeves *et al.*, (1993)** The vitamin mixture used in the experiment according to **Campbell, (1963)**. Also, Composition of mineral mixture was that of **Hegsted *et al.*, (1941)**.
- High fat high fructose diet was prepared according to **Lozano *et al.*, (2016)**

Animals:

Thirty male albino rats of *Sprague Dawley* strain (190 ± 10 g) were obtained from the laboratory animal house of Ophthalmic Research Institute, Giza, Egypt.

Methods**Preparation of plant materials**

Dried black cherry was prepared according to **Abd El-Gwad, Amira et al., (2018)**. Briefly, black cherry fruit carefully washed with tap water and dried in sunny oven at 50 ± 5 °C until arriving by the moisture in the final product to about 8% then minced in moulinex machine (Al Araby for Electronic Manufacture Company, Egypt) then were put in polyethylene bags and packed in cartoon boxes until used .

Preparation of crude ethanol plant extracts

Black berry fruits powder (60 g) were mixed with 80% (v/v) ethanol solution (300 mL) for 1 hr at 30°C by an overhead stirrer (Wise Stir HS-30D, Daihan Scientific, Wonju, Korea). The extract was filtered with filter paper. The filtrate was concentrated using a vacuum rotary evaporator at low temperature (40°C).

Experimental Design

Thirty matured male albino rats weighing between 190 ± 10 g were kept in individual stainless steel cages under hygienic conditions and fed one week on basal diet for adaptation. Preparation of basal diet according to **Reeves et al ., (1993)** then divided into equal five groups (6 rats each), **Group (1)**, as negative control group (v -) control received basal diet throughout the experiment period, while four others groups fed on high fat high fructose diet for 4 weeks to induce hyperlipidemia according to **Lozano et al., (2016)**.and divided into sub main groups: **group (2)**:as positive control group, **group (**

3): received daily gavages of atorvastatin (5mg/kg) according to **Zheng et al., (2018)** , **group(4):** received supplemented diet with dried black cherry (10%) and **group (5):** received daily gavages of ethanolic extract black cherry (500 mg/kg) via a stomach tube . During the experimental period (eight weeks), feed intake and body weights for every rat were recorded twice weekly. At the end of the experiment, the animals were fasted overnight, then the rats were anaesthetized and sacrificed, and blood samples were collected from the hepatic portal vein. Blood samples were taken and centrifuged for 10 minutes at 3000 revolutions per minute "r.p.m" to separate the serum.

Chemical proximate

The antioxidant activity was evaluated same as reported by **Lissi et al.,(1999)**.

Total phenolic was determined according to the method described by **Ranganna (2001)**. Total flavonoids were determined according to the procedure of **Marckam(1989)**.

Biological evaluation

Feed intake (FI), body weight gain (BWG gm.) and liver organ weight per body weight were calculated according to **Chapman et al., (1959)**. The feed efficiency ratio (FER) was calculated according to **Hosoya (1980)**.

Biochemical analysis:

Serum AST and ALT were determined according to **Reitman and Frankel (1957)**. Alkaline phosphatase (ALP) was performed according to the method of **Roy (1970)**. Also, serum total cholesterol (T.C), triglycerides (T.G), HDL-cholesterol, LDL-cholesterol according to **Allain et al.,**

(1974); Trinder and Ann (1969); Lopes - Virella *et al.*, (1977) and Friedwald *et al.*, (1972) respectively .

Histopathological examinations

The liver of sacrificed rats was taken and immersed in 10% formalin solution. The fixed specimens were then trimmed, washed and dehydrated in ascending grades of alcohol. They were then cleared in xylol, embedded in paraffin, sectioned at 4-6 microns thickness and stained with heamtoxylin and eosin for examining liver parts according to Carleton (1979).

Statistical analysis

Statistical analysis was carried out using one way analysis of variance (ANOVA) test followed by Duncan test through the program of statistical packages for the social science (SPSS) version 16. Results were expressed as mean \pm SD. The differences among means at $p \leq 0.05$ are considered significant (Snedecor and Cochran, 1989).

Results and discussion

Total phenolic, total flavonoid contents and antioxidant activity

Results of total phenolic content, total flavonoids and antioxidant capacity (ABTS) are shown in Table 1. The amount of total phenolics and total flavonoids in black cherry were 4.388 mg GAE/100 g and 6.533 mg QE/ 100 mg dry weight respectively. Another stable free radical cation, ABTS, was used to evaluate the antioxidant activity of black cherry extract. Where, a steady increase was observed in the percent-

age inhibition of the ABTS radicals by the black cherry extract (table 1).

In recent years, the interesting of polyphenols in the treatment of several diseases such as cardiovascular disease is increased because of their antioxidant actions (Reis *et al.*, 2016). Our results agree with (Telichowska *et al.*, 2020) who reported the beneficial properties of *P. serotina* extracts. They are attributed with a beneficial effect in the prevention of cardiovascular diseases and hypertension. Their antioxidant, anti-inflammatory, anti-nociceptive, antidiabetic and antimicrobial effects were also confirmed in the studies. Due to their content of anthocyanins, which show strong antioxidant properties, they can also be used in the pharmaceutical industry as a component of creams, gels and other care and disinfection preparations. Also, Luna-Vázquez, *et al.*, 2013 suggested that black cherry fruits are a rich source of natural antioxidants. Additionally, phenolic compounds could also exert health-promoting properties through others mechanisms besides their antioxidant activity.

Table (1): Total phenolic, total flavonoid contents and total antioxidant activity in black cherry extract

Total phenolic (mg of GAE /100g dry weight)	Total flavonoid (mg of QE/ 100 mg dry weight)	% Inhibition measured by the ABTS
4.39 ± 0.33	6.53 ± 0.46	85.94 ± 1.67

GAE: Gallic acid equivalent; QE: quercetin equivalents.

Biological evaluation:

Table (2) shows the mean value of body weight gain and liver weight in all treated groups compared with (-ve) control.

These parameters increased in (+ve) control while declined in treated groups particularly in black cherry extract and atorvastatin groups.

These results in line with **Lozno *et al.*, (2016)** who confirmed that high fat diet and high fructose increase body weight and demonstrated the role of oxidative stress in pathogenesis as well as in complications (hepatic and vascular) . Also , **Zeng-Jie Xu *et al.*, (2009)**, noticed that the high fat diet (HFD) fed rats were observed as significantly increased in point of body weight, epididymal fat weight and liver index (Liver index (LI): liver weight / body weight X 100%) comparing to the control group rats. The decreased in weight gain in groups treated with black cherry may be due to anthocyanin extract that caused a decrease in body weight gain in high fat fed rats as recorded by **(Dayar *et al.*, 2020)** .Also, these results conformed efficacy of Atorvastatin in reducing body weight gain and liver weight as reported by **Mohamed *et al.*,(2019)**.

Table (2): Effect of black cherry powder and ethanolic extract, and atorvastatin on body weight gain and liver weight of different experimental groups of hyperlipidemic rats (mean±SD)

Means in the same column with different superscript letters are significantly different at $p \leq 0.05$.

Groups	Body weight gain(gm)	liver weight
(-ve) control group	71.8± 3.71 ^b	8.88± .161 ^e
(+ve)control group	128.8±5.70 ^a	14.3±.263 ^a
atorvastatin	77.5± 6.34 ^b	10.5±.381 ^d
dried black cherry	77.5± 3.93 ^b	13.4±.377 ^b
Black cherry extract	76.3± 3.88 ^b	11.7±.668 ^c

Table (3) indicated to significant ($p \leq 0.05$) decrease in feed intake and feed efficiency ratio in (+ve) control group as compared to (-ve) control group. All treated groups with herbs showed decreased in previous parameters when compared with (-ve) control group. Atorvastatin and black cherry extract groups recorded the best results in feed Intake and feed efficiency ratio parameters.

The provision of fructose solutions changed the food consumption patterns through appetite suppression, where fructose content could interfere neuropeptides ghrelin and leptin production. Additionally, leptin secreted by white adipose tissue usually result in a decrease in energy usage thereby increasing the body weight and fat storage in rats as stated by **Handayani et al., (2020)**. All treated groups with herbs showed decreased in previous parameters when compared with (-ve) control group. Atorvastatin and black cherry extract groups recorded the best results in feed Intake and feed efficiency ratio parameters. These results could be due to cherries are considered a nutrient dense food with a relatively low caloric content and a significant amount of important nutrients and bioactive food components (**Van der Werf et al., 2018**).

Table (3): Effect of black cherry powder and ethanolic extract, and atorvastatin on total feed intake and feed efficiency ratio of hyperlipidemic rats (mean±SD)

Means in the same column with different superscript letters are significantly different at $p \leq 0.05$.

Groups	Total feed intake (g)	Feed Efficiency Ratio
(-ve) control group	1156.5±4.84 ^a	.107±.004 ^a
(+ve) control group	1086.6±1.96 ^c	.064±.005 ^d
atorvastatin	939.6±3.20 ^e	.081±.007 ^{ab}
dried black cherry	1094.3±4.41 ^b	.068±.004 ^c
Black cherry extract	1058.1±4.26 ^d	.073±.005 ^b

Effect of black cherry powder and ethanolic extract, and atorvastatin on lipid profile and liver enzymes of hyperlipidemic rats

Table (4) revealed that, significant ($p \leq 0.05$) increase in (Cholesterol , triglyceride and LDL) in (+ve) control group compared with (-ve) control group. While, these parameters decreased in all treated groups especially atorvastatin and black extract. On the other hand, HDL parameter recorded high increase in atorvastatin followed by black cherry extract group .

These results agree with **Munshi *et al.*, (2014)** who administrated that high fat high fructose , in rats demonstrated a significant increase in serum lipids, such as total, LDL, VLDL cholesterol, and TG along with a decrease in HDL cholesterol. Atorvastatin is a standard antihyperlipidemic drug, which is used for the treatment of dyslipidemia and the prevention of cardiovascular disease so the decreased in LDL, Cholesterol and triglyceride noted in the treated group with atorvastatin . Also, black cherry fruits have a high content of phenolic compounds such as chlorogenic acid, gallic acid, coffee acid, catechin, epicatechin and quercetin and kaempferol glycosides, which are directly related to the high antioxidant activity and the resulting vasodilating effect (**Telichowska *et al.*, 2020**). Cherry consumption could prevent alterations in lipids mobilization and utilization thought their beneficial effect on catalase, thus avoiding excess circulating lipids. Therefore, all these data highlight not only the improvement of systemic oxidative balance with cherry consumption but also an improvement of lipids profiles (**Van der Werf *et al.*, 2018**).

Table (5) showed significant ($p \leq 0.05$) increase in serum liver enzymes ; i.e (AST, ALT and ALP) in (+ve) control group. While, these parameters decreased in all treated groups especially at black cheery extract group followed by Atorvastatin group . the present study showed significant increase in serum liver enzymes ; i.e (AST, ALT and ALP) in (+ve) control group. Our results agree with **García-Berumen *et al.*, (2015)** who reported that diets containing high fat plus fructose induce more damage in liver than a diet containing only high fat . However, these parameters decreased in all treated groups especially at black cheery extract group followed by Atorvastatin group. These results agreement with **Zarei *et al.*, (2014)** who conducted that the activity of liver enzymes in the treatment groups receiving Atorvastatin (10mg / kg) decreased significantly. **Also, Martinelli *et al.*, (2020)** reported that the cherry-enriched diet reduced the fatty liver, and that anthocyanin-rich extracts may exert positive effects enhancing the activity of the hepatic peroxisome proliferator-activated receptor alpha (PPAR- α) and PPAR- α target acyl-coenzyme A oxidase mRNA.

Table (4): Effect of black cherry powder and ethanolic extract, and atorvastatin on lipid profile of hyperlipidemic rats (mean \pm SD)

Means in the same column with different superscript letters are significantly different at $p \leq 0.05$.

Groups	Cholesterol (mg/dl)	Triglyceride (mg/dl)	HDL(mg/dl)	LDL(mg/dl)
(-ve) control group	61.9 \pm 2.34 ^d	74.7 \pm 5.32 ^e	35.0 \pm 4.88 ^b	18.9 \pm 3.56 ^c
(+ve) control group	151.4 \pm 3.84 ^a	175.7 \pm 6.70 ^a	23.9 \pm 3.80 ^c	85.3 \pm 4.45 ^a
atorvastatin	97.2 \pm 4.06 ^c	94.1 \pm 6.62 ^d	40.0 \pm 3.96 ^a	30.1 \pm 1.41 ^d
dried black cherry	108.8 \pm 5.11 ^b	124.7 \pm 5.30 ^b	30.8 \pm 3.15 ^{bc}	61.9 \pm 4.10 ^b

Table (3): Effect of black cherry powder and ethanolic extract, and atorvastatin on liver enzymes of hyperlipidemic rats (mean±SD)

Means in the same column with different superscript letters are significantly different at $p \leq 0.05$.

Groups	ALT (U/L)	AST (U/L)	ALP (U/L)
(-ve) control group	21.7± 7.71 ^d	87.3± 3.93 ^d	127.5±3.84 ^e
(-ve) control group	54.0± 4.76 ^a	209.9±5.18 ^a	286.5±4.36 ^a
atorvastatin	39.7± 4.83 ^b	134.8 ±4.13 ^c	191.7 ±4.34 ^c
dried black cherry	41.2± 3.59 ^b	155.6±4.29 ^b	246.8 ±4.75 ^b
Black cherry extract	33.1± 3.95 ^c	136.3±4.30 ^c	177.6±6.43 ^d

Histopathology examination results

We examined the effects of high fat high fructose on liver tissues using histological examination. Our results indicate that, congested central vein, diffuse hydropic degeneration with macrovesicular steatosis in hepatocytes and occluded sinusoids. This results agree with **García-Berumen *et al.*, (2015)** when they found The highest degree of steatosis was observed in the high fat + fructose group, with 60% of hepatocytes with microvesicular steatosis and 80% with macrovesicular steatosis (in some cases, hepatocytes displayed both forms of steatosis).

Effect of treatment with Atorvastatin showed mild hydropic degeneration (black arrow) in hepatocytes and narrowed sinusoids was clear, enhances seminiferous tubule and closed to normal control. The available data indicate that

statins are not frequently responsible for liver injury, but there are several issues related to their usage in humans that require further research, such as Drug-drug interactions also increase the hepatotoxicity of statins prolonged use of statins and long-term effects of stains on hepatic histology(**Jabir and Jaffat, 2018**) . Also, effects of treatment with (dried and extract of black cherry) are clear. These positive effects could be due to the reduction of oxidative stress. Our results agree with **Martinelli et al. (2020)** who demonstrated that in the liver, cherry consumption decreased oxidative stress, through the inhibition of the NADPH oxidase subunit p22phox expression, nuclear factor erythroid-2 related factor 2 (Nrf2) degradation, and the formation of reactive oxygen species . Anthocyanins (i.e., cyanidin-3-O- β -glucoside) may avoid the development of liver impairment, reducing the lipid peroxidation or the oxidative stress by the induction of anti-oxidant enzymes.

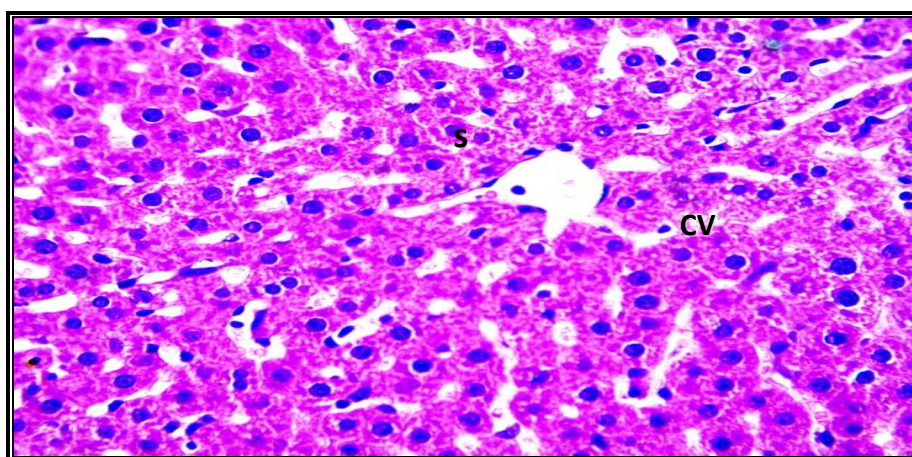


Photo 1: Microscopic pictures of H&E stained liver sections show normal hepatocytes arranged in radiating plates around a central vein with normal sinusoids (s) in control group.

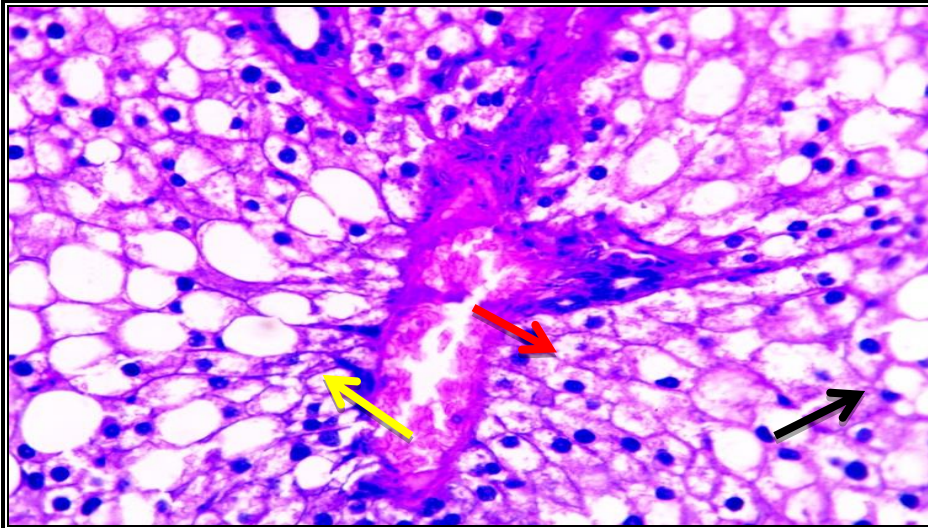


Photo 2: liver sections from untreated rat group kept on HFD+ high fructose show congested central vein (red arrow), diffuse hydropic degeneration (black arrow) with macrovesicular steatosis (yellow arrow) in hepatocytes and occluded sinusoids.

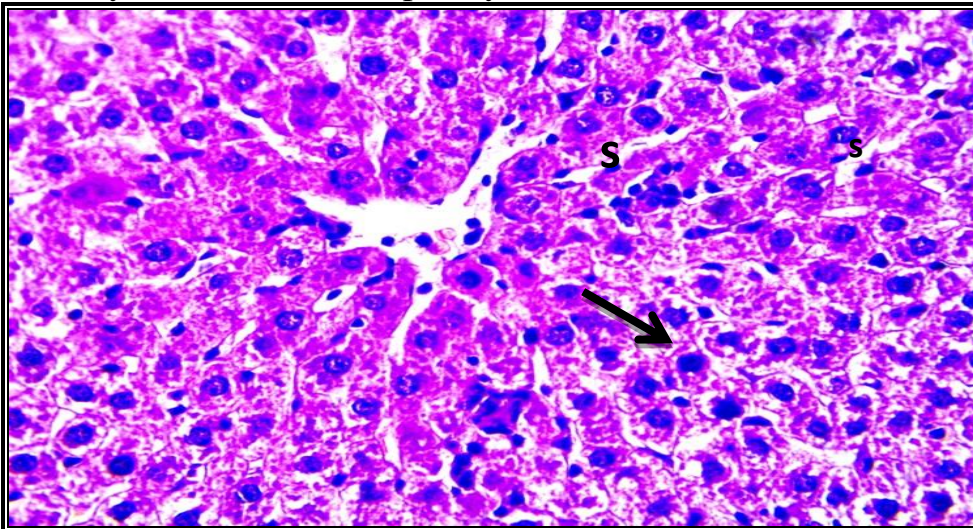


Photo 3: Liver sections from group treated with Atorvastatin show mild hydropic degeneration (black arrow) in hepatocytes and narrowed sinusoids (s).

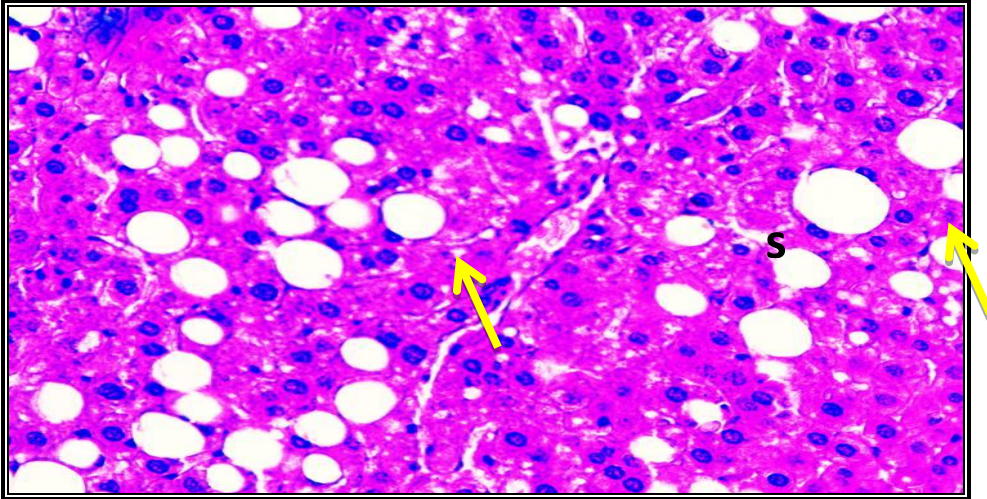


Photo 4: Liver sections from group treated with dried black cherry show diffuse hepatocytes swelling with dispersed macrovesicular steatosis (yellow arrow) and occluded sinusoids (s).

Photo 5: Liver sections from group treated with ethanolic extract of black cherry show diffuse moderate hepatocytes swelling (black arrow) and partially occluded sinusoids (s) X: 400 bar 50

Conclusion

In conclusion, the findings of the present study confirmed that black cherry could be considered as a good source for polyphenols and other antioxidant compounds. Also, ethanolic extract of black cherry had hypolipidemic effect, improv-

ing serum lipid profile closed to treatment with atorvastatin .Also; black cherry could improve liver enzymes activity.

References

Abd El-Gwad, Amira, E.; Abou Raya, M. A.; Abdelrasoul, E. A.; Mona M. Khalil. (2018): "Biological Effects of Dried and Extracted Golden berry on Diabetic Rats". Journal of Food and Dairy Sciences, 9, 12, 425-430. doi: 10.21608/jfds.2018.36112

Abdelhalim, Somaia Z.; Hegazi , Mona M. and El-Bagoury, M. M.H.(2019):

Influence of *Moringa oleifera* flaxseed oil and atorvastatin on hyperlipidemic male albino rats. Int. J cancer & biomedical research (IJCBR). 4(1): 13-23.

Allain , C.C.; Poon , L.S. and Chan , C.S. (1974): "Enzymatic determination of serum total cholesterol" . Clin. Chem. , 20 : 470-475 .

Carleton, H. (1979): " Histological Technique, 4th ed., p. 150. Oxford University Press, London.

Chapman, D.G.; Castilla, R. and Cambell, A.J. (1959): Evaluation of protein in food. In Method for the Documentation of protein Efficiency Ratio. Can. J. Biochem. Physiol., 37; 679-686.

Collins, M.W., Saag, K.G. and Singh, J.A. (2019): Is there a role for cherries in the management of gout? Therapeutic Advances in Musculoskeletal Disease. 17;11:1759720X19847018. doi: 10.1177/1759720X19847018. PMID: 31205513; PMCID: PMC6535740.

Dayar, E., Cebova, M., Lietava, J., Panghyova, E. and Pechanova, O. (2020) : Beneficial Effects of Cornelian Cherries on Lipid Profile and

NO/ROS Balance in Obese Zucker Rats: Comparison with CoQ10. *Molecules.*; 25(8):1922

Friedwald , W.T. ; Leve , R.I. and Fredrickson , D.S. (1972) : "Estimation of the concentration of low-density lipoprotein separated by three different methods". *Clin. Chem.*, 18: 499-502.

García-Berumen, C. I., Ortiz-Avila, O., Vargas-Vargas, M. A., Del Rosario-Tamayo, B. A., Guajardo-López, C., Saavedra-Molina, A., Rodríguez-Orozco, A. R., and Cortés-Rojo, C. (2019). The severity of rat liver injury by fructose and high fat depends on the degree of respiratory dysfunction and oxidative stress induced in mitochondria. *Lipids in health and disease*, 18(1): 78.

Handayani,D.; Ramadhan, A. ; Anindyanti, R.D. ; Innayah,A.M.; Sulistyowati,E. and Kusumastuty,I.(2020): Effects of Dietary Brown Rice on Carcass Composition and Nitric Oxide (NOx) Metabolite Levels in High-Fat High-Fructose Diet-induced Sprague Dawley Rats as Obesity Model. *Journal of Physics: Conference Series.volun (1665), 012007.*

Hosoya, N. (1980): Determination of feed efficiency ratio . Cited in Hosoya, N .; Inami , S. and Goto , S., eds. *Nutrition Experiments Using Small Animals.* Daiichi Shuppan, Tokyo, Japanese, pp:71.

Jabir, S.H. and Jaffat H. s.(2018): Effects of Atorvastatin Drug in Albino Male Rats. *Journal of Pharmaceutical Sciences and Research* 10 (11), 2924-2928.

Karam, I., Ma, N., Yang, Y-J. and Li, J-Y. (2018): Induce Hyperlipidemia in Rats Using High Fat Diet Investigating Blood Lipid and Histopathology. *J Hematol Blood Disord*4(1):104.

Lasker, S., Rahman, M.M., Parvez, F. et al.,(2019): High-fat diet-induced metabolic syndrome and oxidative stress in obese rats are ameliorated by yogurt supplementation. *Sci Rep.*; 9 (1):20026.

Lissi, E. ,Modak, B. , Torres, R. , Esochar, J. and Urzua, A.(1999) : *Free Radic. Res.* 30 471-477.

Lopes-Virella , M.F. ; Stone , S. ; Ellis , S. and Collwell , J. A. (1977) : "Cholesterol determination in high-density lipoprotein

separated by three different methods". Clin. Chem., 23 (5) : 882-891.

Lozano, I., Van der Werf, R., Bietiger, W., Seyfritz, E., Peronet, C., Pinget, M., Jeandidier, N., Maillard, E., Marchioni, E., Sigrist, S., & Dal, S. (2016): High-fructose and high-fat diet-induced disorders in rats: impact on diabetes risk, hepatic and vascular complications. Nutrition & metabolism, 13, (15): 2-13.

Luna-Vázquez, F. J., Ibarra-Alvarado, C., Rojas-Molina, A., Rojas-Molina, J. I., Yahia, E. M., Rivera-Pastrana, D. M., Rojas-Molina, A., & Zavala-Sánchez, M. Á. (2013). Nutraceutical value of black cherry *Prunus serotina* Ehrh. fruits: antioxidant and anti-hypertensive properties. Molecules (Basel, Switzerland), 18(12), 14597–14612.

Marckam, K.R. (1989) “Methods in Plant Biochemistry”, Academic Press, London, 16

Martinelli, I., Micioni Di Bonaventura, M. V., Moruzzi, M., Aman-tini, C., Maggi, F., Gabrielli, M. G., Fruganti, A., Marchegiani, A., Dini, F., Marini, C., Polidori, C., Lupidi, G., Amenta, F., Tayebati, S. K., Cifani, C., & Tomassoni, D. (2020). Effects of *Prunus cerasus* L. Seeds and Juice on Liver Steatosis in an Animal Model of Diet-Induced Obesity. Nutrients, 12(5), 1308..

Mohamed, A., W. M. Ibrahim, N. Zaki, S. Ali and A. M. Soliman. (2019):“Effectiveness of *Coelatura aegyptiaca* Extract Combination with Atorvastatin on Experimentally Induced Hyperlipidemia in Rats.” Hindawi Evidence-Based Complementary and Alternative Medicine Volume 2019, Article ID 9726137, 9 pages <https://doi.org/10.1155/2019/9726137>.

Munshi RP, Joshi SG, Rane BN. (2014): Development of an experimental diet model in rats to study hyperlipidemia and insulin resistance, markers for coronary heart disease. Indian J Pharmacol. 2014;46(3):270-276. doi:10.4103/0253-7613.132156

Ranganna, S. (2001) : Handbook of Analysis and Quality Control for Fruit and Vegetable Products. Tata McGraw-Hill publishing Co. Ltd, New Delhi

Reeves, P.G., Nielsen, F.H. and Fahmy, G.C. (1993): Final report of American Institute of Nutrition adhoc writing committee on the reformulation of AIN-76A rodent diet. *Journal of Nutrition*, 123: 1939-1951.

Reis, J.F., Monteiro, V.V., de Souza Gomes, R., do Carmo, M.M., da Costa, G.V., Ribera, P.C., Monteiro and M.C. (2016): Action mechanism and cardiovascular effect of anthocyanins: a systematic review of animal and human studies. *J Transl Med.*;14 (1):315.

Reitman , S. and Frankel , S. (1957) : "A colorimetric method for the determination of serum glutamic oxaloacetic and glutamic pyruvic transaminases". *Am. J. Clin. Path.* , 28 : 56- 63 .

Shorinwa ,o .A. and Monsi, B.(2020): Toxicological implications of the fruit of *Harungana madagascariensis* on wistar rats. *Clin Phytosci*, 6(2):1-9.

Snedecor, G.W. and Cochran, W. G. (1989): *Statistical Methods*. Eighth Edition, Iowa State University Press.

Telichowska, A., Kobus-Cisowska, J., Ligaj, M., Stuper-Szablewska, K., Szymanowska, D., Tichoniuk, M., & Szulc, P. (2020). Polyphenol content and antioxidant activities of *Prunus padus L.* and *Prunus serotina L.* leaves: Electrochemical and spectrophotometric approach and their antimicrobial properties, *Open Chemistry*, 18(1), 1125-1135.

Thirumalai, T.; Tamilselvan, N. and David, E. (2014): Hypolipidemic activity of Piper betel in high fat diet induced hyperlipidemic rat. *Journal of Acute Disease* .3(2):131-135.

Trinder , P. and Ann , S. (1969) : "Enzymatic colorimetric test with lipid clearing factor to determine triglycerides". *Clin. Biochem.* , 6 : 24-27 .

Van der Werf, R., Walter, C., Bietiger, W, Seyfritz, .E, Mura, C., Peronet, C., Legrandois, J., Werner, D., Ennahar, S., Digel, F., Mail-

lard-Pedracini, E., Pinget, M., Jeandidier, N., Marchioni, .E, Sigrist, S. and Dal, S. (2018): Beneficial effects of cherry consumption as a dietary intervention for metabolic, hepatic and vascular complications in type 2 diabetic rats. *Cardiovasc Diabetol.*;17(1):104.

Xu, J.Z, Fan, J.G., Ding, X.D., Qiao, L. and Wang, G.L. (2009): Characterization of High- Fat, Diet Induced, Non-alcoholic Steatohepatitis with Fibrosis in Rats. *Dig Dis Sci.* 55(4): 931–940.

Zarei, A., Changizi Ashtiyani, S., Taheri, S., and Rasekh, F. (2014): Comparison between effects of different doses of *Melissa officinalis* and atorvastatin on the activity of liver enzymes in hypercholesterolemia rats. *Avicenna journal of phytomedicine*, 4(1), 15–23.

Zheng, D., Cai, A., Xu, R., Mai, Z., Zhou, Y., Zeng, F., Li, L., & Mai, W. (2018): Effects and potential mechanism of atorvastatin treatment on Lp-PLA2 in rats with dyslipidemia. *Archives of medical science : AMS*, 14(3), 629–634.