

Original Article

PHOTOREFRACTIVE KERATECTOMY WITH COLLAGEN CROSS LINKING IN
SUSPICIOUS AND EARLY KERATOCONUS

Abdelallem, A.^{1(*)}, Abd El-badie, M.¹ & Radwan, G.²

¹ Ophthalmology dept., Faculty of Medicine, Al-Azhar Univ., Assiut, Egypt

² Ophthalmology dept., Faculty of Medicine, Sohag Univ., Sohag, Egypt

* E-mail: Ahmed4eye@yahoo.com

Received 18/6/2018

Accepted 25/9/2018

Abstract

Purpose: To study the efficacy and safety of PRK and corneal cross linking (CXL) For treatment of suspicious and early Keratoconus. **Methods:** fifty eyes of thirty two patients with suspicious and early keratoconus were included. all patient underwent Simultaneous PRK and corneal cross linking (CXL) The outcomes were evaluated at 18 months in all eyes. **Result:** 80 % percent of UNCVA postoperatively are equal to preoperatively BCVA or gained 1 or more lines 20 % only Lost 1 line, 62 % of the eyes are within 1.0D. of emmetropia. None of the eyes had > 2.0 D and 54 % of the eyes had Astigmatism by K-Reading within 1.0D. None of the eyes had > 2.0D. **Conclusion:** We concluded that The Combined non-topography-guided PRK and CXL is an effective procedures for correcting mild refractive error and improving visual acuity and safety option for arresting the ectatic progression, with improvement of corneal keratometric values in patients with suspicious and early keratoconus provided that we adhere to the selection criteria of that we recommend. However, future studies with larger cohorts of patients and longer follow-up periods are needed to determine the safety, efficacy, and stability of such procedure.

Keywords: Photorefractive Keratectomy, Collagen Cross Linking, keratoconus

1. Introduction

Keratoconus is a progressive, non-inflammatory, bilateral asymmetrical ectatic corneal disease, characterized by paraxial stromal thinning and weakening that leads to corneal surface distortion. Visual loss occurs primarily from irregular astigmatism and myopia, and secondarily from corneal scarring. Protrusion usually but not exclusively affects the axial and inferonasal cornea [1]. Forme Fruste Keratoconus (FFKC) diagnosed when screening patients for LASIK, positive

identification of a sub clinical form of keratoconus known as forme fruste keratoconus (FFKC) is important. Performing LASIK on patients with FFKC significantly increases the risk of developing ectasia. Therefore, it is prudent to identify such patients and if appropriate consider alternative corrective procedures such as phakic IOLs (e.g. Staar ICL) or photorefractive keratectomy (PRK) [2]. FFKC differs from keratoconus in that

the latter can be diagnosed clinically with use of slit lamp examination and characteristic pattern on corneal topography as discussed above. FFKC has no identifiable slit lamp signs, but corneal topography shows a cone pattern. In other words, FFKC is diagnosed by topography alone. FFKC may or may not exhibit astigmatism on manifest refraction and BSCVA may be 20/20 or it may be reduced [3]. Another finding of interest when evaluating a patient for LASIK is the subtle entity known simply as "inferior steepening". Like FFKC, this entity also is strictly a topography diagnosis. Slit lamp examination is unremarkable. Manifest refraction will usually not have any astigmatism and BSCVA is typically 20/20 (assuming no unrelated pathology is present such as amblyopia or macular scarring, for examples). Performing LASIK on these corneas can evoke a higher keratoectasia risk as well. There can be overlap between FFKC and inferior steepening, so these conditions are not mutually exclusive. FFKC topography maps tend to show marked steeper colors such as red, while inferior steepening may have normal curvatures, but the inferior pattern is the only unusual sign.

2. Patients and methods

2.1. Patients

This study included fifty eyes of 32 patients (31.2%) were male and (68.8%) were female, fig. (1) the mean age of study patients was 31.2 ± 4.2 years old operated on between November 2014 to November 2016 that had simultaneous PRK and CXL in cases of suspicious keratoconic 22 pt (62.5%) and early keratoconic 10 pt (37.5%). According to Lu and Azar scoring system 15 cases of suspicious with score of 2 and 7 cases with score of 3 Minimum corneal thickness 485 μm . Maximum corneal thickness 551 μm , Keratometric reading between 42.73 and 46.33 Ds. While all 10 cases with early keratoconic cases with score of 4, Minimum corneal

of topographic Criteria of Keratoconus When more than one of the following criteria are found, any of the above mentioned patterns is considered as frank KC, Forme Fruste Keratoconus, (FFKC), early stage Keratoconus, or at least a case of suspicion (according to the severity and amount of signs) [4]. On the sagittal map: Keratometric readings >48 Ds. SRAX $>22^\circ$, Superior-inferior difference (S-I) on the 5 mm circle >2.5 Ds, Inferior-Superior difference (I-S) >1.5 Ds, Corneal astigmatism on either surface should not be higher than 6 D; otherwise, it is a risk factor, Against the rule, astigmatism is considered suspicious [5]. On the thickness map, Cone-like shape. Superior-inferior at 5 mm circle >30 μm , Thinnest location <470 μm , Thickness at pachy apex-thickness at thinnest location >10 μm , Y coordinate value of the thinnest location >-500 μm , Difference in thickness between both eyes at thinnest locations >30 μm . On the elevation maps, Isolated island or tongue-like extension (BFS mode) on either surface, Values >12 μm within the central 5 mm on the anterior elevation map (BFTE mode), Values >15 μm within the central 5 mm on the posterior elevation map (BFTE mode) [6].

thickness 468 μm . Maximum corneal thickness 502 μm , Keratometric reading between 43.58 and 47.08 Ds. In keratoconus suspect there were 12 cases bilateral and 10 cases unilateral while in keratoconus there were 6 cases bilateral and 4 cases unilateral. In keratoconus suspect there were 12 cases females and 10 cases males while in keratoconus there were 10 cases were females. All patients finished one and half year follow up. Patients fulfill the following criteria minimum corneal thickness 450 μm , the ablation depth not more than 50 μm , Keratometric reading not more than 50 Ds, spherical equivalent can be corrected by ablation of 50 μm , treatment is aimed at correcting mainly the cylindrical part,

improvement of vision ≥ 2 lines decimal visual acuity scale and Informed consent of all patients. We excluded patients with prior corneal surgery, evidence of other corneal disease, Presence of significant central corneal opacity or scarring, women who are pregnant or nursing at the time of the initial treatment, patients with Systemic collagen vascular disease, dry eyes and ocular surface disease. Preoper-

rative and follow up examinations included UCVA, BSCVA, manifest refraction, slit lamp biomicroscopy, dilated fundus examination, corneal topography (CSO device). Before the surgery, patients were given detailed explanations of the possible implications and the surgical technique. All patients signed a written consent from in accordance with the Helsinki declaration. The ethical committee of Al-azhar University approved this study protocol.

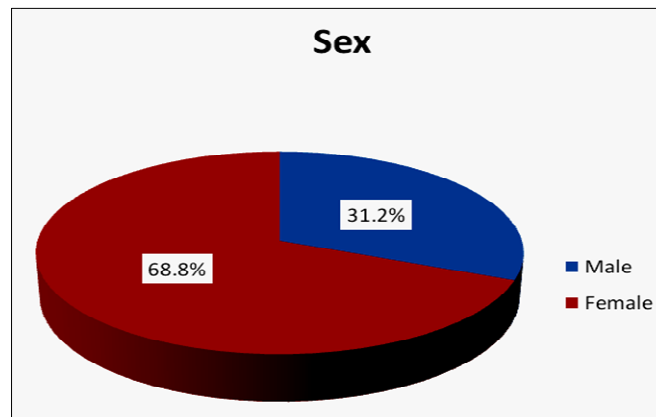


Figure (1) Distribution of patient's gender

2.2. Surgical technique

All patients had uneventful PRK with mitomycin C (MMC) followed by CXL. Thirty minutes before surgery, and Proparacaine 2% eye drops were used to anesthetize the ocular surface. The patients face was prepped with povidone-iodine 10%. The eyelashes were isolated using sterile drape. Corneal epithelium was removed by PTK. Stromal ablation was done using STAR S4 IR excimer laser system (Abbott, Germany) with 6 mm optical zone, 1.25 mm transition zone and 8.5 mm ablation zone. MMC 0.02% was applied for 20 seconds using mirocel sponge then vigorous irrigation with BSS was done then the patient was treated with riboflavin. We used ultrasound pachymetry to locate the central and thinnest

point. For CXL, 0.1% riboflavin with hydroxypropyl methylcellulose (Vibex Rapid; Avedrolnc, Waltham, MA, USA) applied to the corneal surface and spread with an irrigating cannula for 1.5 minutes. After the soaking, the corneal surface was washed thoroughly with balanced salt solution (BSS). A UVA beam (wave length, 365 nm) 9.0 mm in diameter was applied to the cornea in continuous fashion in a uniform circular pattern by the CXL device (Avedrolnc). The UVA exposure was performed for 90 seconds at power of 30 mW/cm² (total dose, 2.7 J/cm²). Patients were reviewed on the first and seventh postoperative days, and subsequently at 1 month, 3 months 6 months and one year and one and half year.

3. Results

This study included fifty eyes of 32 patient (31.2%) were male and (68.8%) were female. the mean age of study patients was 31.2 ± 4.2 years old operated on between November 2014 to

November 2016 that had simultaneous PRK and CXL in cases of suspicious keratoconus 22 pt (62.5%) and early keratoconous 10 pt (37.5%). All patients finished 18 months follow up.

3.1. Uncorrected visual acuity (UCVA)

The mean UCVA improved from 0.13 ± 0.12 preoperatively to 0.42 ± 0.13 at 3 months. UCVA continued to improve progressively until. As regards UCVA at last follow up we found that about 40 eye, 25 eye matched the preoperative BCVA and 15 eye gained one line while

10 eyes only lost one line little than the preoperative BCVA on decimals at the one and half year. The end of the 12 month 0.67 ± 0.15 ($P = 0.055$). A slight decrease at one and half year 0.6 ± 0.14 ($P < 0.001$). The improvement was statistically significant, tab (1), fig (2).

Table (1) Comparison between preoperative and postoperative follows up as regard UCVA

UCVA	Min.	Max.	Mean \pm SD	P1	P2	P3	P4	P5
Preoperative	0.05	0.50	0.12 ± 0.12					
After 1 Month	0.10	0.50	0.29 ± 0.13	<0.001**				
After 3 months	0.30	0.70	0.42 ± 0.13	<0.001**	<0.001**			
After 6 months	0.40	0.80	0.67 ± 0.15	<0.001**	<0.001**	<0.001**		
After 1 year	0.40	0.80	0.67 ± 0.14	<0.001**	<0.001**	<0.001**	<0.001**	
After 1.5 year	0.30	0.70	0.6 ± 0.14	<0.001**	<0.001**	<0.001**	<0.001**	<0.001**

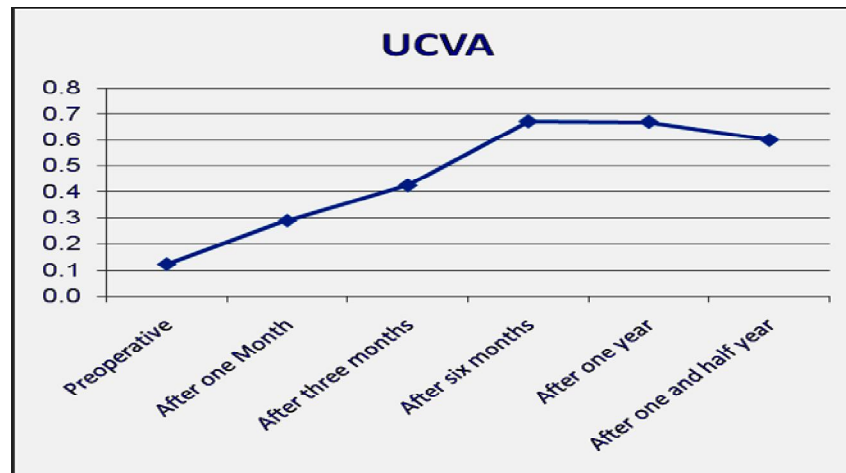


Figure (2) Comparison between preoperative and follow up as regards UCVA.

3.2. Best corrected visual acuity (BCVA)

The preoperative mean BCVA 0.65 ± 0.17 preoperatively showed a significant change ($P = 0.001$) at 3 month postoperatively (0.58 ± 0.17) ($P < 0.001$) and continued with improvement at 6 month 0.75 ± 0.17 and stabled over the follow-up period, reaching 0.75 ± 0.16 at 12 months ($P = 0.001$) and 0.75 ± 0.16 at one

and half year ($P = 0.001$) respectively. Ten eyes (20%) showed no improvement in BCVA in lines, thirty eyes (60%) gained one line, 10% gained two lines, 10% gained 3 lines, BCVA. No eyes lost any lines in BCVA at the one and half year follow-up, tab (2), fig (3).

Table (2) Comparison between preoperative and postoperative follows up as regard BCVA

BCVA	Min.	Max.	Mean \pm SD	P1	P2	P3	P4	P5
Preoperative	0.40	0.90	0.65 ± 0.17					
After 1 Month	0.30	0.80	0.47 ± 0.16	<0.001**				
After 3 months	0.40	0.80	0.58 ± 0.17	<0.001**	<0.001**			
After 6 months	0.40	0.90	0.75 ± 0.17	<0.001**	<0.001**	0.024*		
After 1 year	0.40	0.90	0.75 ± 0.16	<0.001**	<0.001**	0.024*	1.000	
After 1.5 year	0.40	0.90	0.75 ± 0.16	<0.001**	<0.001**	0.024*	1.000	1.000

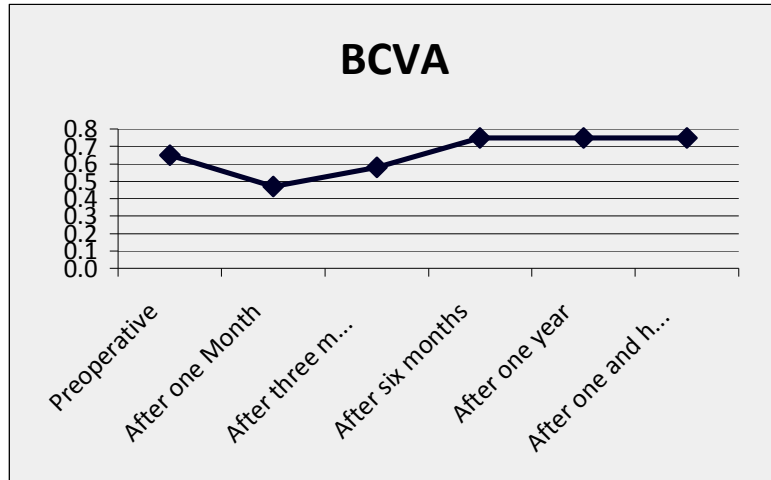


Figure (3) Comparison between preoperative and follow up as regards BCVA

3.3. Spherical equivalent (SE)

The mean spherical equivalent (SE) refraction decreased significantly from $3.26 \pm 2.78D$ preoperatively to $-0.92 \pm 0.46D$, $-1.08 \pm 0.4D$ and -1.47 ± 0.38 at 3 months ($P < 0.001$), 12 months and one and half year ($P < 0.001$) respectively. The

changes in spherical equivalent (SE) were statistically significant at 3 months SE improved (decreasing) with no significant changes but at 1 year slight increasing and at one year and half more increasing in SE occurred, tab (3), fig (4).

Table (3) Comparison between preoperative and postoperative follows up as regards SE

SE	Min.	Max.	Mean±SD	P1	P2	P3	P4	P5
Preoperative	-2.50	-6.50	-3.26±2.78					
After 1 Month	-0.50	-1.75	-0.99±0.39	<0.001**				
After 3 months	-0.25	-1.75	-0.92±0.46	<0.001**	<0.001**			
After 6 months	-0.25	-1.75	-0.94±0.45	<0.001**	0.002**	0.024*		
After 1 year	-0.25	-1.75	-1.08±0.4	<0.001**	0.013*	<0.001**	<0.001**	
After 1.5 year	-0.50	-2.00	-1.47±0.38	<0.001**	<0.001**	<0.001**	<0.001**	<0.001**

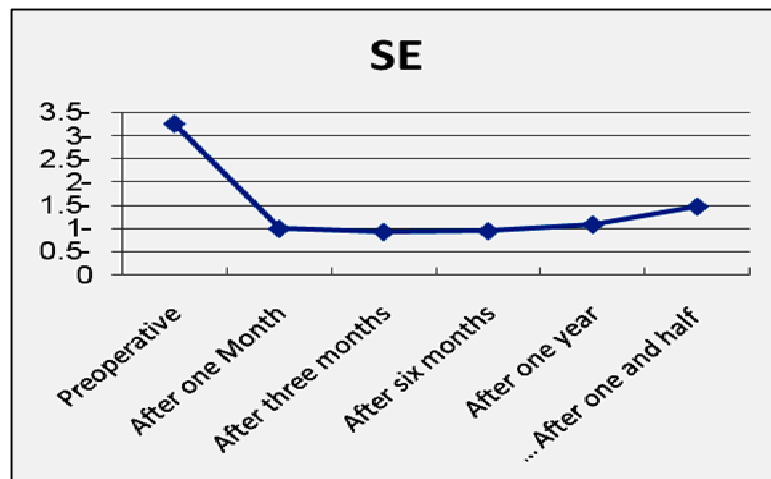


Figure (4) Comparison between preoperative and follow up as regards SE

3.4. Refraction of cylinder

The mean manifest refraction cylinder decreased from $-2 \pm 0.86D$ preoperatively to -0.61 ± 0.36 , $-0.82 \pm 0.27D$

and -1.14 ± 0.23 at 6 months ($P < 0.001$), 12 months ($P = 0.012$) and one and half year ($P < 0.001$) respectively, tab (4), fig

(5) The changes (decreasing) in manifest refraction of cylinder were significant at one months, 6 months while increased slightly at 12 months and more significant

at one and half year respectively. Slight regression about 54% of the eyes had Astigmatism by K Reading within 1.0D. None of the eyes had > 2.0D.

Table (4) Comparison between preoperative and postoperative follow up as regards cylinder :

Cylinder	Min.	Max.	Mean±S	P1	P2	P3	P4	P5
Preoperative	-1.00	-3.50	-2±0.86					
After 1 Month	0.00	-1.50	-0.61±0.36	<0.001**				
After 3 months	0.00	-1.50	-0.61±0.36	<0.001**	1.000			
After 6 months	-0.50	-1.50	-0.75±0.32	<0.001**	<0.001**	<0.001**		
After 1 year	-0.50	-1.25	-0.82±0.27	<0.001**	<0.001**	<0.001**	0.012*	
After 1.5 year	-0.75	-1.50	-1.14±0.23	<0.001**	<0.001**	<0.001**	<0.001**	<0.001**

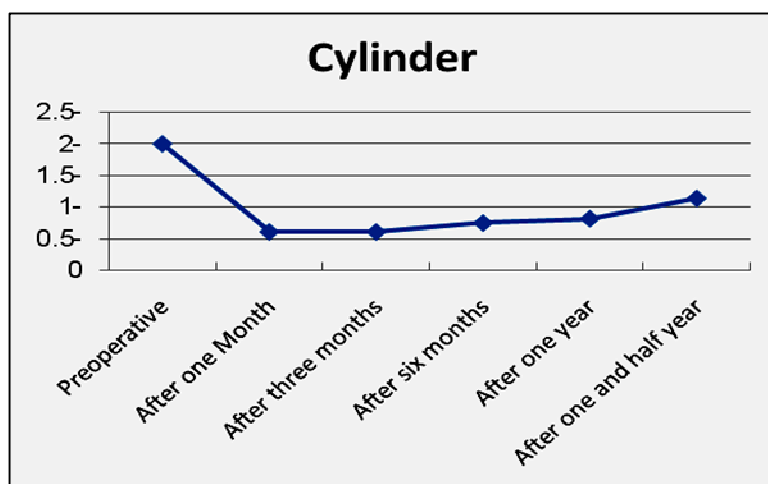


Figure (5) Comparison between preoperative and follow up as regards Cylinder

3.5. Keratometry

The mean average K-value (mean K) decreased from 44.47±1.16 to 42.16 ± 2.36, 42.34 ± 2.23 and 42.37 ± 2.22 D at 3, 12 and 1.5 years post operatively, a statistically significant reduction (P < 0.01), fig (6). The mean steepest keratometry (K max) were 45.49±1.25vs 43.23±2.33, 43.28±2.34 and 43.32±2.33D at 3.12 and

1.5 years post operatively (P < 0.001). Keratometric values appeared stable postoperatively, with no evidence of progression in K max over the follow up period. Postoperatively, a statistically significant reduction (P < 0.01), figs (7 & 8).

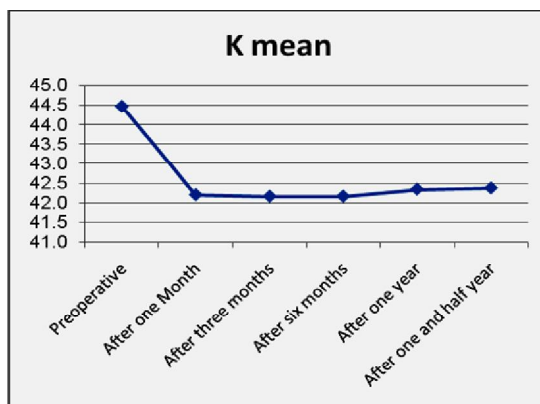


Figure (6) Comparison between preoperative and follow up as regards mean K

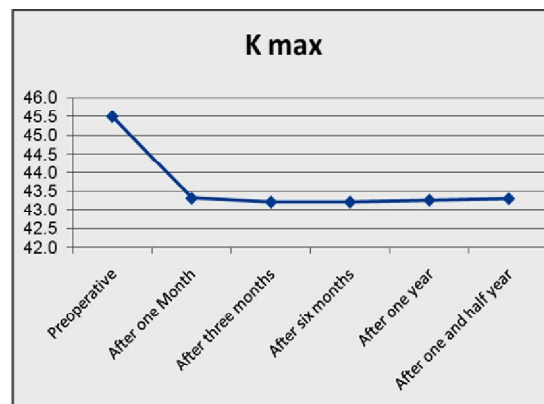


Figure (7) Comparison between preoperative and follow up as regards K max

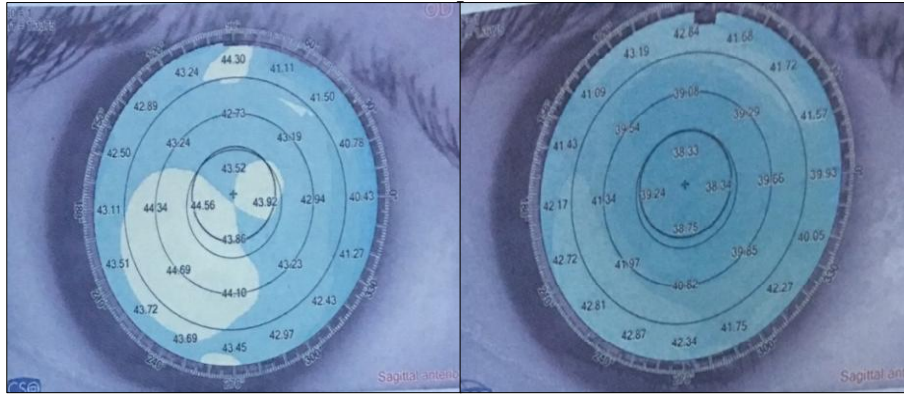


Figure (8) Right Pentacam image shows corneal inferior steepening before PRK extra and Left Pentacam image shows flattening of the steep cornea after ablation within safety till last follow up period.

The early complications including post-operative pain, no significant pain on postoperative day 1 was reported in 45% of the cases, while there were moderate pain in 25%, and severe pain in 30% of patients. This is most likely due to removal of epithelium. The patients were improved gradually by week after talking systemic nonsteroidal anti-inflammatory drugs (diclofenac sodium 50 mg twice daily). Delayed epithelial healing was reported if the epithelium did not heal by day 5 post procedure, epithelial healing time occurred in 75% of cases by day 4, 15% by day 5, and 10% delayed epithelial healing by day 10. The patients were improved completely after they treated with lubrication (carboxymethyl cellulose 1%, sodium hyaluronate, polyvidone 50 mg) 6 times daily and complete healing after one week later, fig. (9). Late complications including stromal haze, Transient stromal haze was noted in about 10% of the cases (5 eyes, with two eyes grade 1, two eyes grade 2 and one eye grade 3).

Only the eye with grade 3 haze was felt to have any possible impact on vision, although this eye still had a vision of 0.15 decimal compared to 0.3 preoperatively, and was continuing to regress and visual improvement till it completely relived by 6 month after surgery to reach 0.2 till last follow up while eyes with grade one resolved by 1 month and those with grade 2 improved by month 4 after procedures, fig. (10). Subepithelial corneal scar was noted in about 4% (2 eyes) with persistent scar beyond six months that didn't respond to the various interventions weren't felt to have any possible impact on vision as the scar were paracentral in both, although one eye still had a vision of 0.4 decimal compared to 0.3 preoperatively with improvement one line but the other one still had a vision of 0.5 decimal compared to 0.5 preoperatively, fig. (11). However none of these cases necessitated PKP. No ectatic progression no corneal melting, no infectious keratitis.

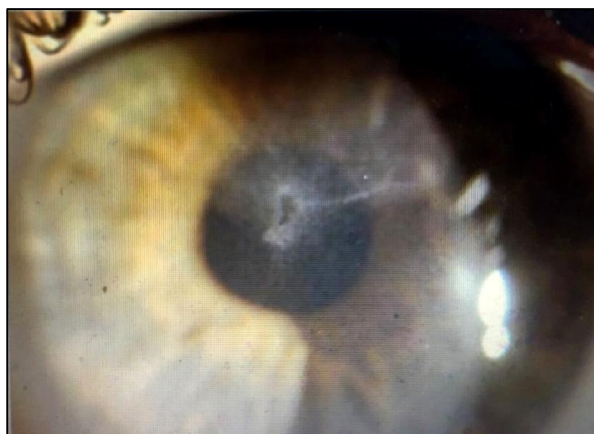


Figure (9) Delayed epithelial healing, stromal haze

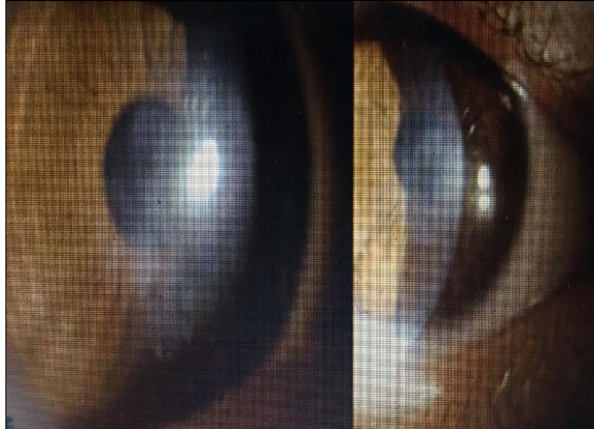


Figure (10) PRK-like haze, 1 year after improved with steroids

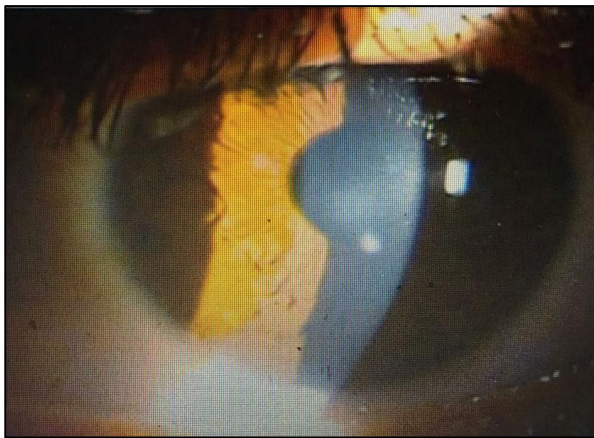


Figure (11) Faint scar and white spot

4. Discussion

The goal of simultaneous custom PRK and CXL is to offer keratoconus patients corneal stability as well as functional vision. Reaching functional vision involves improving UCVA, BCVA, and corneal irregularity so that patients are less dependent on contact lenses to achieve better quality of vision. Custom PRK is a predictable and effective technique to achieve remodeling of the corneal surface and rehabilitation of refractive impairment. CXL is capable of stabilizing the corrected cornea and inhibiting keratoconic progression. In this study we utilized non-topographic aspheric profiles derived from refraction and topography, combined with simultaneous CXL. In contrast, current treatment strategies use topographically derived treatment profiles with the intention of correcting aberrations. The use of topographic profiles however, assume that the shape change in the ectatic cornea predictably

responds to ablation shape. However, there are several potential causes of unpredictable response to topographic planning. Firstly, the use of topographic profiles ignores the biomechanical effects of such ablations in compromised cornea [7]. Secondly, the actual tissue ablation rate may differ in keratoconic tissue, with unexpected topographic effects. Thirdly, the measured and ablated surfaces differ unless a trans epithelial therapy is used, since the epithelial profile in keratoconus is irregular [8]. Finally and most significantly, cross linking itself has progressive effects on keratoconic topography, which are not accounted for [9,10]. Our rationale for non-topographic aspheric astigmatic profiles was minimize stromal ablation, while preserving beneficial effects of combining PRK and CXL. A transepithelial treatment was chosen to obtain a corrective effect based on the differential epithelial profile around

the cone, which has been shown to have a 'doughnut' distribution, thus the masking effect of the epithelium would tend to regularize the cone [11]. Notably, combined excimer laser ablation and CXL may also have a beneficial effect on keratoconus independent of topographic or refractive correction. This has been demonstrated in a recent series by Kymionis et al., where PTK epithelial removal for CXL resulted in superior visual outcomes compared to mechanical removal [12]. Although MMC in keratoconic PRK has been used, we felt that CXL induced keratocytes depopulation offsets the need for chemotherapy, particularly as the transepithelial treatment causes less haze [13]. Although we had initial concerns regarding potential haze, in this study PRK treatment was planned based on the patient's corneal thickness. Limited treatments of up to 50 μm were performed; the ablation depth was mapped out by modifying the target correction. CXL treatment was performed immediately following the ablation we demonstrated a rapid and significant improvement. As regards UCVA at last follow up we found that about 40 eye improved, 25 eye matched the preoperative BCVA and 15 eye gained one line while 10 eyes only lost one line little than the preoperative BCVA on decimals at the one and half year in comparison to preoperative BCVA. The efficacy index (postoperative mean decimal UDVA divided by preoperative mean decimal BCDVA) was 0.65 at three months after surgery, improved to 1.03 at 6 months, and continued without significant change at 12 months, but reaching 0.92 with slight decrease At one and half year matched. The standard deviation of UDVA was 0.12 ± 0.12 preoperatively and 0.67 ± 0.14 postoperatively with progression and stability over twelve months follow-up period. At one and half year slight regression occurred reaching 0.6 ± 0.14 . As regards BCVA at last follow up we found that about Ten eyes (20%) showed no improvement in BCVA in lines, 25 eyes (60%) gained one line, 10% gained two lines, 10% gained 3 lines, BCVA. no eyes lost one line in

BCVA at the one and half year follow-up in comparison to preoperative BCVA due to 3rd degree haze and sub epithelial scar affecting cornea after procedure. The safety index (postoperative mean decimal BCVA divided by preoperative mean decimal BCDVA) showed a progressive improvement from 0.89 at one month, reaching 1.15 at 6 months and settling at 1.25 at 12 months and remained stable at one and half year. Likewise, the standard deviation of CDVA was 0.65 ± 0.17 preoperatively and 0.75 ± 0.16 postoperatively with progression and stability over the follow-up period ($P = 0.001$). As regard astigmatism about 54% of the eyes had Astigmatism by K-Reading within 1.0 D and 63% of the eyes had Astigmatism by Refraction within 1.0 D. No eyes had > 2.0 D. A reduction in topographic astigmatism was observed after 18 months follow-up, with no significant improvement in visual outcomes. Corresponding to the positive change of UCVA and BCVA, we found a reduction of myopia. Probably due to regularization of the cornea, subjectively accepted cylinder was higher after CXL+ PRK in many cases. The underlying reason for the positive changes in visual acuity and refraction is the observed corneal flattening, as shown by the reduction of maximum and minimum keratometry values. Complications were found in five eyes of 50 eyes. Only one eye lost one line of BCVA due to prolonged central Descemet's folds and stromal edema up to 6 months, while other eyes with grade one stromal haze resolved by 1 month and those with grade 2 improved at 4 months after procedures. The major limitation of the study was the absence of a control group. We did not feel that a retrospective control group of CXL alone would be superior to comparison of existing large CXL series. A future study comparing topographic to non-topographic treatment is planned. Notwithstanding these issues, we feel that this technique shows promise as a preliminary intervention in suspect and early keratoconic patients. In addition, the follow-up period in our study was 18 months and due to the reports of progressive excessive corneal flattening [14,15] which may lead

to hyperopic shift up to several years after CXL [16] further studies with longer follow-up periods are needed to

further evaluate the long-term outcomes of this technique.

5. Conclusion

The Combined non-topography-guided PRK and CXL is an effective procedures for correcting mild refractive error and improving visual acuity and safety option for arresting the ectatic progression, with improvement of corneal keratometric values in patients with suspicious and early keratoconus provided that we adhere to the selection criteria of that we recommend. However, future studies with larger cohorts of patients and longer follow-up periods are needed to determine the safety, efficacy, and stability of such procedure.

References

1. Romero-Jiménez, M., Santodomingo-Rubido, J., Wolffsohn, J., Keratoconus W., A review. *Cont Lens Anterior Eye* 2010; 33 (4): 157-166.
2. Maeda, N., Klyce, S., Smolek, M., Thompson, H. Automated keratoconus screening with corneal topography analysis. *Investigative Ophthalmology & Visual Science* 1994; 35: 2749-2757.
3. Matalia, H., Swarup, R., Imaging modalities in keratoconus. *Indian J Ophthalmol.* 2013; 61 (8): 394-400.
4. Sinjab, M. *Quick guide to the management of keratoconus: A systematic step-by-step approach*, Springer, Germany, 2012, p. 26
5. Chan, C., Sharma, M., Boxer Wachler, B. Effect of inferior-segment intacs with and without C3-R on keratoconus. *J Cataract Refract Surg.* 2007; 33: 75-80.
6. Rathi, V., Mandathara, P., Dumpati, S. Contact lens in keratoconus. *Indian J Ophthalmol.* 2013; 61: 410-415.
7. Dupps, W., Wilson, S. Biomechanics and wound healing in the cornea. *Exp Eye Res.* 2006; 83: 709-720.
8. Stojanovic, A., Zhang, J., Chen, X., Nitter, T., Chen, S., Wang, Q. Topography-guided transepithelial surface ablation followed by corneal collagen cross-linking performed in a single combined procedure for the treatment of keratoconus and pellucid marginal degeneration. *J Refract Surg.* 2010; 26: 145-152.
9. Raiskup-Wolf, F., Hoyer, A., Spoerl, E., Pillunat, L. Collagen cross-linking with riboflavin and ultraviolet-A light in keratoconus: Long-term results. *J Cataract Refract Surg.* 2008; 34: 796-801
10. Tu, K., Aslanides, I. Orbscan II anterior elevation changes following corneal collagen cross-linking treatment for keratoconus. *J Refract Surg.* 2009; 25: 715-722.
11. Reinstein, D., Gobbe, M., Archer, T., Silverman, R., Coleman, D. Epithelial, stromal, and total corneal thickness in keratoconus: Three-dimensional display with artemis very-high frequency digital ultrasound. *J Refract Surg.* 2010; 26: 259-271.
12. Kymionis, G., Grentzelos, M., Kounis, G., Diakonis, V., Limnopoulou, A., Panagopoulou, S. Combined trans-epithelial phototherapeutic keratectomy and corneal collagen cross-linking for progressive keratoconus. *Ophthalmology.* 2012; 119(9): 1777-1784
13. Aslanides, I., Padroni, S., ArbaMosquera, S., Ioannides, A., Mukherjee, A. Comparison of single-step reverse trans-epithelial all-surface laser ablation (ASLA) to alcohol-assisted photorefractive keratectomy. *Clin Ophthalmol.* 2012; 6: 973-980.
14. Santhiago, M., Giacomini, N., Medeiros, D., Smadja, C., Bechara, S. Intense early flattening after corneal collagen cross-linking. *J of Refractive Surgery* 2015; 31 (6): 419-422.
15. Greenstein, S., Fry, K., Hersh, P. Effect of topographic cone location on outcomes of corneal collagen cross-

- linking for keratoconus and corneal ectasia. *J of Refractive Surgery* 2012; 28 (6): 397-405.
16. Kymionis, G., Tsoulnaras, K., Liakopoulos, D., Paraskevopoulos, T., Kouroupaki, A., Tsimbaris, M. Excessive corneal flattening and thinning after corneal cross-linking: Single-case report with 5-year follow-up. *Cornea* 2015; 34 (6): 704-706.