

Gross Anatomical Studies on the Fore Limb of the West African Giraffe (*Giraffa Camelopardalis peralta*).

Kenechukwu Tobechukwu Onwuama, Esther Solomon Kigir, Alhaji Zubair Jaji and Sulaiman Olawoye Salami.

Department of Veterinary Anatomy, University of Ilorin, Ilorin, Nigeria.

With 6 figures and one table.

Received September, accepted for publication October 2020

Abstract

This study on the Gross anatomy of the West African Giraffe's forelimb was aimed at investigating the unique morphological features and number of bones making up this region of the animal's skeleton. Two adult West African giraffe carcasses at different times after post-mortem examination were prepared to extract the bones via cold water maceration for use in the study. The Scapula presented a spine on its lateral surface, lacking a spinal tubercle and ended abruptly without the acromion process before reaching the glenoid angle. The proximal extremity of the humerus presented two intertuberal grooves separated by an intermediate tubercle. Its shaft was entirely smooth on all sides, lacking the deltoid tuberosity and teres major tubercle, while presenting a very shallow almost non-existent musculospiral groove at its lateral distal third. The Ulna bone was reduced to a thin plate as it runs the entire length of the radius before ending distally as the lateral styloid process. The 6 carpals were arranged in two rows of 4 proximal and 2 distal. The metacarpal (fused 3rd and 4th)

presented two condyles that anchored two digits with three phalanges and three sesamoids for each. The total number of bones making up the forelimb was accounted to be 46. In conclusion, this study provides a baseline data for further biological, archeological and comparative anatomical studies.

Keywords: Bone, Forelimb, Gross anatomy, Scapula, West African Giraffe.

Introduction

The West African giraffe (*Giraffa Camelopardalis*), the tallest living terrestrial mammal and largest ruminant is a representative of the graffidae family of the order artiodactyla consisting of one species and multiple subspecies (Fennessy *et al.*, 2016; Bercovitch *et al.*, 2017). It is a native of Africa, especially the sub-Saharan regions with their distribution including several fragmented parts of the continent (Hassanin *et al.*, 2007).

The West African Giraffe has been extirpated from much of their historical range due to different parts of their

body being used for different purposes (Kingdon, 1997), therefore being listed as vulnerable (Muller *et al.*, 2016. Fennesey *et al.*, 2018) with some subspecies even endangered (Bolger *et al.*, 2019). Though still found in numerous national parks and game reserves with a few in the wild (Pellow, 2001), its dwindling population has raised concerns for its protection and further domestication in private game reserves and zoos (Foley *et al.*, 2014). Although studies on the various physiological, behavioural and biological aspects of this mammal has been conducted, none has been documented on the detailed description of the bones that make up its skeleton. To this end, this study on the bones of the forelimb has been conducted to investigate normal gross features and number making up this region. It also serves as a foundation for comparative study to differentiate it from other ruminant domestic animals.

Materials and Methods

Two adult West African giraffe (*Giraffa camelopardalis peralta*) carcasses weighing 1,070kg and 812kg were obtained after post-mortem from the Department of Veterinary Pathology, University of Ilorin at different periods of time. They were transported to the Veterinary Anatomy gross laboratory, University of Ilorin, Nigeria for bone preparation as museum specimens. They were carefully de-fleshed using sharp knife and scalpel blades. The skin was removed, and muscles teased out,

leaving the bones with minimal soft tissue attachment before being transferred to a large container containing cold water enough to submerge the bones at room temperature. The container was covered airtight and placed under shade throughout the period of maceration with regular change of water. After completion, the water was drained, the bones were recovered, and sun dried. Photographs of recovered bones were taken individually. They were also articulated using glue, noting the bones that constituted the Manus of the forelimb.

Ethics approval: This study was granted exception from acquiring ethical approval because the specimen used where acquired as carcasses after post-mortem examination.

Results

The forelimb comprised bones of the Shoulder (Scapula), arm (Humerus), fore arm (Ulna and Radius), carpals, metacarpals and digits (Manus). They exhibited general and peculiar features similar to and different from other domestic animals previously studied. The average number of bones of the forelimb was established to be 46 as shown in table 1.

The **Scapula** presented a flat bone with two surfaces (lateral and medial), three borders (cranial, caudal and dorsal) and three angles (cranial, caudal and glenoid). The lateral surface presented two unequal parts; a smaller

cranio-dorsal supraspinous fossa and larger caudo-ventral infraspinous fossa divided by a scapular spine that begins 1.6 inches below the dorsal border before ending abruptly 3.6 inches above the glenoid angle. The dorsal border was slightly convex, cranial border was concave while the caudal border was convex at its proximal half and concave at its distal half. The scapular tubercle and Acromion processes were absent. The medial surface presented a shallow middle subscapular fossa. The facies serrata was not distinct. The glenoid angle presented a supraglenoid tubercle on its cranial border, a supraglenoid fossa close to its caudal border and a concave glenoid cavity ventrally for humeral head articulation. The coracoid tubercle was found caudal to the supraglenoid tubercle on the medial aspect of the glenoid angle.

The **Humerus** is a long bone with a shaft and proximal and distal extremities. The shaft presented smooth surfaces with a very shallow concave musculospiral groove on the distal third of its lateral surface. The teres major and deltoid tuberosities were absent. The proximal extremity presented caudally a convex head with a distinct neck, lesser tubercle cranio-medially; an intermediate tubercle flanked by two inter-tuberal groove and a raised greater tubercle craniolaterally. The distal extremity presented lateral and medial condyles cranially separated by a shallow sagittal groove;

lateral and medial epicondyles caudally separated by the deep olecranon fossa.

The fused **Ulna** and **Radius** were long bones, each possessed a shaft and proximal and distal extremities. They both had convex cranial and concave caudal surfaces. The Ulna was the slimmer of the two, fusing cranially on the caudal surface of the radius except at the large proximal interosseous space formed by the caudal and cranial border of the radius and ulna respectively. Its proximal extremity presented the olecranon ending in a tuber and the anconeal process that contributed to the formation of the notch. Its shaft is reduced in size to a thin plate as it runs the entire length of the radius before ending distally as the lateral styloid process. The radius was larger and placed cranially. Its proximal extremity presented a concave articular surface that blended with the notch for articulation with the condyle of humerus. Lateral and cranial tubercles were also noticed on this extremity. Its distal extremity presented extensor grooves cranially and formed the medial styloid process.

The **carpal bones** were six in number and were arranged in two rows. The proximal row comprised from medial to lateral; the radial carpal, intermediate carpal, ulna carpal and accessory carpal bones while the distal row comprised the fused second and third carpals and fourth carpal bones. The **Metacarpal** presented a long bone with a

shaft and two extremities (Proximal and distal). A shallow groove spanned the shaft length on the palmar surface only. The proximal extremity presented articular surfaces for carpal articulation and roughened surface for muscular attachment on its dorsal surface. The distal extremity comprised lateral and medial condyles separated by an intercondylar groove. Each condyle presented a median ridge.

Two **Digits** having three phalanges each were seen on each foot. The first and second Phalanges were small long bones with shaft and extremities that presented concave proximal and convex distal surfaces for articulations. The second phalanx was the shortest of the three bones. The third phalanx presented a long triangular shaped bone with a concave surface at its cranio-dorsal end (for articulation with the second phalanx), lateral, medial and ground surfaces. Six sesamoid bones were found on the palmar surface of each foot with two placed at the metacarpophalangeal joint and one at the distal interphalangeal joint of each digit.

Discussion

Bones of the forelimb of the West African Giraffe presented unique morphological features in comparison to those of other previously studied mammals. The appearance of the scapula with a slightly convex dorsal border, concave cranial border and a caudal border which was convex at its proximal half

and concave at its distal half was peculiar to this species, as it appears triangular in ruminants (Budras and Habel, 2003) and horses (Budras *et al.*, 2009) rhomboid in pigs (König and Liebich, 2004) and D-shaped in carnivores (Budras *et al.*, 2007). The scapular spine which begins 1.6 inches below the dorsal border lacks the spinal tuber and ends abruptly without the acromion process. This finding was somewhat similar to that of the horse and pig (Dyce *et al.*, 2010) except that the spine begins from the dorsal border and presented a spinal tubercle centrally that is small in the horse but large and caudally directed in the pig (König and Liebich, 2004). The absence of the acromion process suggested that the acromial part of the deltoideus muscle may be absent in this species. The Scapular spine also divides the lateral surface of the scapula into a very small supraspinous fossa and an extensive infraspinous fossa. This finding which is only similar to that reported in the sheep (Gamal, 2006) and goat (Gheorge, 2001) leads to conclusions on the extent of the supraspinatus and infraspinatus muscles which lodge in these fossae in the live animal. The coracoid tubercle in this species is seen as a process in all other domesticated species (Dyce *et al.*, 2010).

The shaft of the humerus of the Giraffe was unique and different from that of any reported domestic species. It was entirely smooth on all sides lacking the deltoid tuberosity and the teres major

tuberosity and presented a very shallow almost non-existent musculospiral groove. This also suggested that the deltoideus and teres major muscles may either be absent or not inserted on the shaft of the humerus. The absence of the deltoideus muscle is more likely since there was no acromion process. The presence of an intermediate tubercle flanked by inter-tuberal groove was only similar to that reported in the horse (Adams and Crabtree, 2012).

The uniqueness of the Ulna bone was seen in its reduced shaft to a thin plate as it runs the entire length of the radius before ending distally as the lateral styloid process. This was different from the horse's ulna shaft which though reduced, does not extend to the distal extremity to form the styloid process. The shafts of the other ruminants, pig and dog are better developed compared to that of this animal (König and Liebich, 2004; Evans and Delahunta, 2013).

The short cubic-shaped morphology of the carpal bones together with their numbers and arrangement were similar to those reported in other ruminants (Adams and Crabtree, 2012). The presence of the shallow sagittal groove palmarly and two distal condyles (lateral and medial) were the basis for assumption that the metacarpal bone was formed from the fusion of the 3rd and 4th metacarpal bones. This presentation was similar to the ruminants though a dorsal metacarpal groove is prominent in those species

while the ox (some breeds) have the rudimentary 5th metacarpal (Budras, and Habel, 2003). Also, the morphology, number and arrangement of the phalanges and sesamoids were similar to that reported in the ox, sheep and goat (Ashdown and Done, 2010; Hussain, 2010).

Conclusion

This study on the Gross anatomy of the Forelimb of the West African Giraffe (*Giraffa Camelopardalis peralta*) presented the numerical and morphological information on bones of this animal highlighting specific features, similarities and differences from other domestic mammals.

Acknowledgement

The authors wish to appreciate the department of Veterinary Pathology for their assistance in the acquisition of the specimens.

Funding

Authors declare that they received no funding from external body. The work was self-sponsored by the authors.

Conflicts of interest

The authors declare they have no conflict of interest associated with this work.

References

Adams, B and Crabtree, P. (2012): Comparative Osteology: A laboratory and Field Guide of common North

American Animals. Academic press. Oxford, U.K. pp. 156-214

Ashdown, R. R and Done, S.H. (2010): Color Atlas of Veterinary Anatomy Vol. 1: The Ruminants. 2nd edition. Mosby Elsevier. Pp. 3, 28.

Bercovitch, F.B., Berry, P.S.M; Dagg, A., Deacon, F., Doherty, J.B, Lee, D.E., Mineur, F., Muller, Z., Ogben, R., Seymour, R., Shorrocks, B and Tutchings, A. (2017): "How many species of giraffe are there?". *Current Biology*. 27 (4): R136-137.

Bolger, D., Ogotu, J., Strauss, M., Lee, D., Muneza, A., Fennessy, J., Brown, D. (2019): "Masai Giraffe" IUCN Red list of Threatened Species.

Budras, K. and Habel, R.E. (2003): Bovine Anatomy: An Illustrated text. First edition. Schlutersche GmbH and Co. Hannover, Germany. Pp. 35.

Budras, K., Mc-Carthy, P. H., Horowitz, A. and Berg, R. (2007): Anatomy of the Dog. Schlutersche Hannover, Germany. Pp. 40.

Budras, K., Sack, W. O and Rock, S. (2009): Anatomy of the Horse. 5th edition. Schlutersche Hannover, Germany. Pp. 33-35.

Dyce, K.M., Sack, W.O and Wensing, C.J.G. (2010): Text book of Veterinary Anatomy. Saunders Elseviers, St. Lois Missouri. U.S.A. 4th edition. Pp 407-414.

Evans, H.E and De-lahunta, A. (2013): Miller's Anatomy of the Dog. Elsevier Saunders. U.S.A. pp. 85-126.

Fennessy, J., Marais, A., Tutchings, A. (2018): "Giraffa camelopardalis peralta" IUCN Red list of Threatened Species.

Fennessy, J., Bidon, T., Reuss, F., Kumar, V., Elkan, P., Nilsson, M.A., Vamberger, M., Fritz, U and Janke, A. (2016): "Multi-locus analysis reveal four giraffe species instead of one". *Current Biology*. 26 (18): 2543-2549.

Foley, C., Foley, L., Lobora, A., De Luca, D., Msuha, M., Davenport, T. R. M and Durant, S.M. (2014): A field Guide to the Larger Mammals of Tanzania. Princeton University Press. Pp. 179.

Gamal, E.A. (2006): Atlas Anatomy of Sheep. The Academic Bookshop Egyptian joint stock co. Cairo. Pp. 10-17.

Gheorge, M.C. (2001): Guide to regional ruminant Anatomy based on the dissection of the Goat. 1st edition. Wiley-Blackwell.

Hassanin, A., Ropiquet, A., Gourmand, B.L., Chardonnet, B., Rigoulet, J. (2007): "Mitochondrial DNA variability in Giraffa camelopardalis: consequences for taxonomy, Phylogeography and conservation of giraffes in West and central Africa". *Comptes Rendus Biologies* 330 (3): 173-183.

Hussain, M.S (2010): Essentials of Caprine Anatomy. 1st edition. Faculty of Veterinary Science, University of Agriculture, Faisalabad. Pp.10-22.

Kingdon, J. (1997): The kingdon field guide to African Mammals. *Academic Press*. Pp. 339-344.

König, H.E and Liebich, H (2004). Veterinary Anatomy of Domestic mammals: Textbook and colour Atlas. Schattauer, Stuttgart, Germany. Pp. 27-90

Müller, Z., Bercovitch, F., Brand, R., Brown, D., Brown, M., Bolger, D., Carter, K., Deacon, F., Doherty, J.B., Fennessy, J., Fennessy, S., Hussein, A.A., Lee, D., Marais, A., Strauss, M., Tutchings, A and Wube, T. (2016): “*Giraffa camelopardalis*” IUCN Red list of Threatened Species.

Pasquini, C., Spurgeon, T. and Pasquini, S. (1997): Anatomy of Domestic Animals: Systemic and

Regional approach. SUDZ Publishing, U.S.A. pp. 72-89.

Pellow, R.A. (2001): “Giraffe and Okapi”, In MacDonald, D. (ed.). The Encyclopedia of Mammals of the World. Vol.1. The Johns Hopkins University Press. Baltimore, U.S.A and Lndon, U.K.

Prothero, D.R and Schoch, R.M. (2003): Horns, Tusks and Flippers: The Evolution of Hoofed Mammals. John Hopkins University Press. Pp. 67-72.

Swaby, S. (2010): “Giraffe”. In Harris, T. (ed.). Mammal Anatomy: An Illustrated Guide. Marshall Cavendish. Pp. 64-84.

Corresponding author:

Kenechukwu Tobechukwu Onwuama

E-mail: kenexcares@yahoo.com

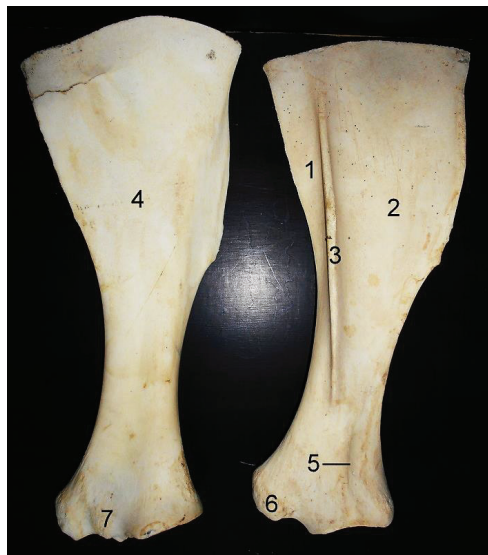

Fig (1): Scapula of the West African Giraffe (*Giraffa Camelopardalis peralta*) 1, Supraspinous fossa; 2, Infraspinous fossa; 3, Scapula spine; 4, Subscapular fossa; 5, Supraglenoid fossa; 6, Supraglenoid tubercle; 7, Coracoid tubercle.

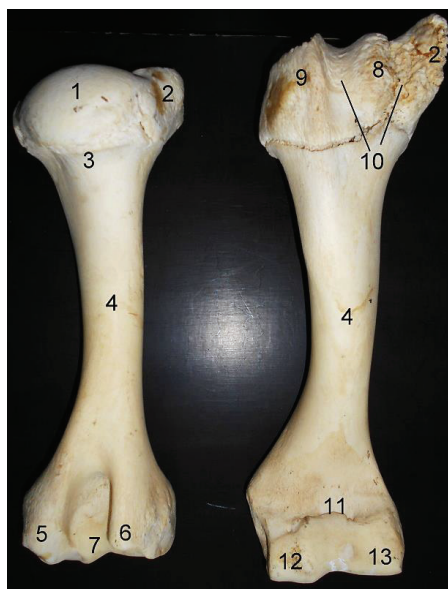


Fig (2): Humerus of the West African Giraffe (*Giraffa Camelopardalis peralta*) 1, Head; 2, Greater tubercle; 3, Neck; 4, Shaft; 5, Medial epicondyle; 6, Lateral epicondyle; 7, Olecranon fossa; 8, Intermediate tubercle; 9, Lesser tubercle; 10, Bicipital groove; 11, Radial fossa; 12, medial condyle; 13, Lateral condyle.

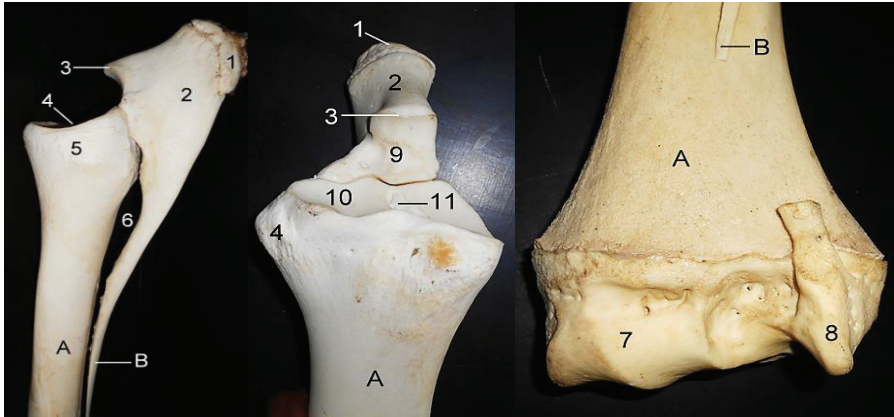


Fig (3): Radius and Ulna of the West African Giraffe (*Giraffa Camelopardalis peralta*) lateral and cranial views of proximal extremity and caudal view of distal extremity. A, Radius; B, Ulna. 1, Olecranon tuber; 2, Olecranon; 3, Anconeal process; 4, 10, Radial articular facet; 5, Radial head; 6, Interosseous space; 7, Articular surface; 8, Lateral styloid process; 9, Sigmoid or trochlear notch; 11, sagittal ridge.

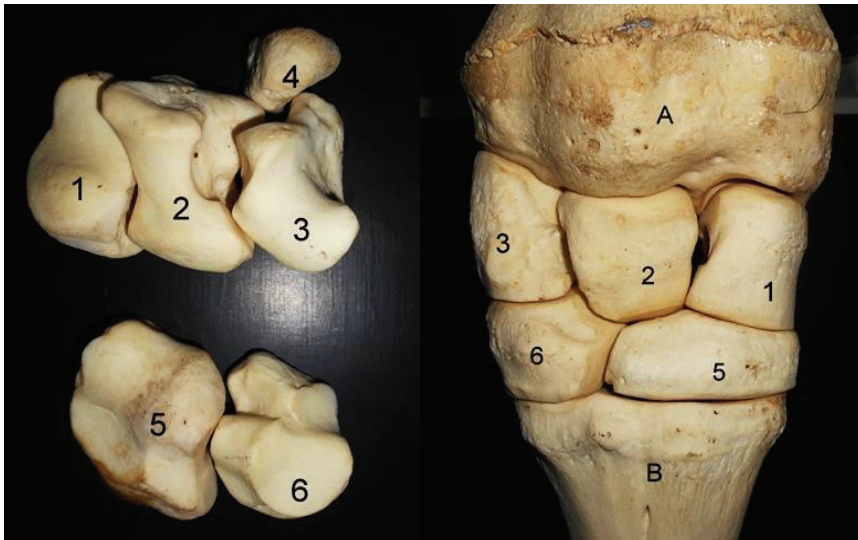


Fig (4): Carpals of the West African Giraffe (*Giraffa Camelopardalis peralta*) showing articular surfaces and dorsal view. A, Radius; B, Metacarpal; 1, Radiocarpal; 2, Intermediate carpal; 3, Ulna carpal; 4, Accessory carpal; 5, 2nd and 3rd carpal fused; 6, 4th carpal.

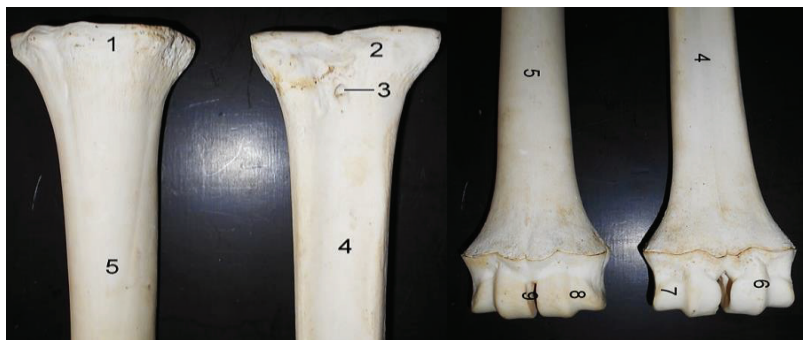

Fig (5): Proximal (left) and distal (right) halves of Metacarpal bones of the West African Giraffe (*Giraffa Camelopardalis peralta*) Dorsal (left) and palmar (right) views. 1, proximal extremity; 2, Head; 3, Nutrient foramen; 4, Metacarpal groove; 5, Shaft; 6, Median ridge; 7, Lateral condyle; 8, Medial condyle; 9, Intercondylar groove.

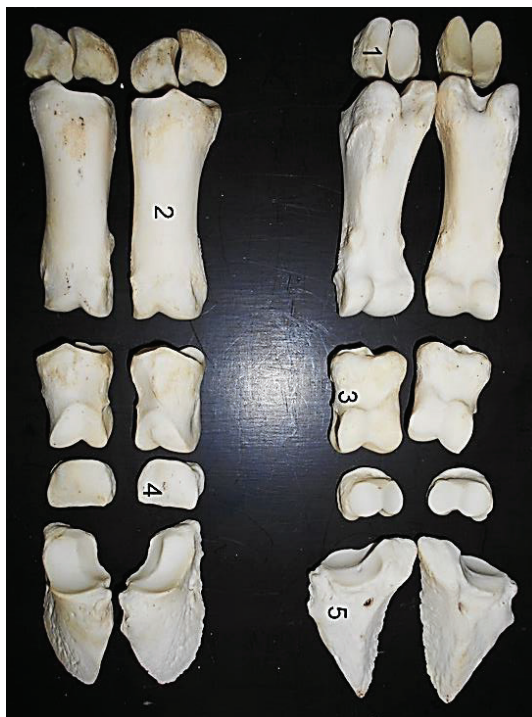


Fig (6): Digits of the West African Giraffe (*Giraffa Camelopardalis peralta*) dorsal and palmar views. 1, Proximal sesamoid; 2, Proximal phalanx; 3, Middle phalanx; 4, Distal sesamoid; 5, Distal phalanx.

Table (1): Number of bones of the Fore limb of the West African Giraffe (*Giraffa Camelopardalis peralta*)

Bones	Num- ber
Scapula	2
Humerus	2
Ulna	2
Radius	2
Carpals	12
Metacarpals	2
First phalanx	4
Second phalanx	4
Third phalanx	4
Sesamoid	12
Total average:	46

Animal species in this Issue

Giraffe (*Giraffes Camelopardalis*)



Kingdom: Animalia & Phylum: Chordata & Class: Mammalia & Order: [Artiodactylaa](#)
&Family: [Giraffidae](#) &, Genus: *Giraffa* & Species: *Giraffes camelopardalis*

The **giraffe** (*Giraffa*) is an African [artiodactyl mammal](#), the [tallest](#) living terrestrial animal and the largest [ruminant](#). It is traditionally considered to be one [species](#), *Giraffa camelopardalis*, with nine [subspecies](#). However, the existence of up to eight [extant](#) giraffe species has been described, based upon research into the [mitochondrial](#) and [nuclear DNA](#), as well as morphological measurements of *Giraffa*. Seven other species are extinct, prehistoric species known from fossils.

The **Nubian giraffe** (*G. c. camelopardalis*), is found in eastern South Sudan and southwestern Ethiopia, in addition to Kenya and Uganda. It has sharply defined chestnut-coloured spots surrounded by mostly white lines, while undersides lack spotting. The median lump is particularly developed in the male. Around 2,150 are thought to remain in the wild, with another 1,500 individuals belonging to the Rothschild's ecotype. With the addition of Rothschild's giraffe to the Nubian subspecies, the Nubian giraffe is very common in captivity, although the original phenotype is rare- a group is kept at Al Ain Zoo in the United Arab Emirates. In 2003, this group numbered 14.

Source: Wikipedia, the free encyclopaedia