

Effect of systemic isotretinoin on semen parameters and sperm ultrastructure in male patients treated for acne vulgaris : An electron microscope study

Original Article

Moustafa M. K. Eyada¹, Rashad M. Mostafa², Saad R. Mahgoub³, Mohamed Azab⁴

Departments of ¹Dermatology, Venereology and Andrology, ^{2,4}Andrology, Infertility and Sexually Transmitted Diseases, Faculty of Medicine, Suez Canal University, Ismailia, ³Department of Dermatology and Venereology, Port Said Prison Hospital, Ministry of Interior, Port Said, Egypt

ABSTRACT

Background: Acne vulgaris (AV) is a common dermatological problem that affects males and females in the adolescent period and early adulthood. Isotretinoin is the treatment of choice for moderate to severe cases of AV, as it provides complete cure with minimal scarring. Males receiving isotretinoin are always concerned about its adverse effects, especially on their fertility potential.

Objective: To study the effect of systemic isotretinoin on semen parameters and sperm ultrastructure of male patients treated for AV.

Patients and Methods: This study was carried out on 40 male patients with resistant AV presented to the Dermatology Clinic, Suez Canal University Hospital. A total cumulative dose of 120 mg/kg of systemic isotretinoin was given to all patients over a period of 6 months. Computer-assisted semen analysis and sperm ultrastructure assay using transmission electron microscopy were done for all patients before and after the course of treatment.

Results: After the course of systemic isotretinoin, a statistically significant increase in sperm concentration (million/ml), progressive sperm motility %, and morphologically normal sperms % was observed. By transmission electron microscopy, all sperm ultrastructural parameters and sperm structure dimensions were not significantly changed after isotretinoin use.

Conclusion: Systemic isotretinoin in AV is a safe modality of treatment with no harmful adverse effects on semen parameters, sperm morphology, or sperm ultrastructure after 6 months of use.

Key Words: Semen parameters, systemic isotretinoin, transmission electron microscopy.

Received: 24 July 2020, **Accepted:** 24 August 2020.

Corresponding Author: Mohamed Azab, Department of Andrology, Infertility and Sexually Transmitted Diseases, Faculty of Medicine, Suez Canal University, Ismailia, Egypt, **Tel.:** +20 122 456 0152, **E-mail:** dr.mohamed_azab@yahoo.com

ISSN: 2090-6048, 2020

INTRODUCTION

Acne vulgaris (AV) is a chronic disease affecting the pilosebaceous follicular unit. It presents with polymorphic lesions, including symptoms of swelling, comedones, erythema, and inflammation, and later on in ~43%, scarring can occur, especially in severe or neglected cases. AV is the commonest skin disease in Europe and USA^[1,2]. It affects ~80% of males and females in adolescent and young adult periods and can persist in late adulthood in many circumstances^[3]. Symptoms and consequences of AV usually cause marked distress, anxiety, low self-esteem, and social phobias in the affected person, and it affects his/her family members and interpersonal relationships^[4].

Treatment of AV depends on disease type, severity, and complications, and it ranges from topical therapies including topical antibiotics, retinoids, sulfur, azelaic acid,

and benzoyl peroxide in mild conditions to oral therapy including systemic antibiotics, hormonal therapy, and systemic isotretinoin in moderate to severe conditions^[2].

Isotretinoin is known to be the active metabolite of retinol, which is vitamin A acid^[5]. Its molecule contains 13-cis-retinoic acid (RA), which is a tretinoin stereoisomer. It gains its high and rapid response by affecting cell survival, cellular differentiation, cell-cycle progression, and apoptosis^[6].

Systemic isotretinoin is the drug of choice for severe and persistent cases of acne resistant to treatment with other modalities, as it acts on all etiopathological stages of acne formation efficiently and rapidly^[7].

Systemic isotretinoin has many reported common adverse effects^[8]. These adverse effects are categorized into teratogenicity, clinical adverse effects including

cutaneous or extracutaneous changes, and abnormal laboratory findings^[9]. The most important adverse effect of isotretinoin is teratogenicity. Systemic isotretinoin intake in pregnant female or female in childbearing period, whatever the dose, may cause in most of cases major fetal malformations, spontaneous abortion, or premature birth^[10].

Effect of isotretinoin on male fertility was studied in earlier studies, which revealed increased semen parameters after isotretinoin intake like sperm concentrations and sperm motility^[11]. More recently, positive effects of isotretinoin on sperm parameters were found in male patients receiving isotretinoin. These effects were referred mostly to its proliferative and regenerative effects on the testes in addition to its neutral effect on sex hormone levels^[7].

The conventional semen analysis evaluating sperm microscopic characteristics such as sperm count, morphology, and motility is the cornerstone to assess fertility potential in males^[12]. Transmission electron microscope (TEM) is considered the best technique to study internal sperm environment, to find out the disruption of internal sperm organelles, and to measure accurately changes in sperm dimensions that interfere with normal fertilizing potential in spite of normal morphological sperm appearance with the light microscope^[13].

The aim of this study was to explore the effect of systemic isotretinoin on semen parameters and sperm ultrastructure using TEM of male patients treated for AV, to discover clearly if it has harmful effect on sperm parameters or morphology on the ultrastructural level or not.

PATIENTS AND METHODS

This study was carried out as a prospective study. Patients were recruited from the Dermatology and Andrology Clinics, Suez Canal University Hospital, and a relevant private sector, Cleopatra IVF Center, Ismailia, Egypt, during the period from June 2018 to May 2019.

Patients selection

A total of 43 patients were randomly recruited according to the following eligibility criteria. Inclusion criteria were male patients aged more than 18 years, with normal semen analysis and treated with systemic isotretinoin for AV. Exclusion criteria were patients who used systemic isotretinoin before or had medical contraindications to its use, patients with azoospermia or leukocytospermia, and patients with andrological or medical conditions affecting semen parameters.

Methods

All the studied patients were subjected to the following.

Full history taking and complete clinical examinations. Dermatological examination was done to determine

distribution, type, and severity of acne and body weight assessment. Genital examination was performed to exclude other andrological factors that can affect sperm parameters in the follow-up period. Laboratory investigations included complete blood picture, lipid profile, kidney function tests, and liver function tests, which were performed before the study and every month during the period of drug intake.

Systemic isotretinoin dose and duration of therapy

The dose of isotretinoin was dependent on body weight and acne severity. The average duration of treatment was ~6 months, and dose was 0.5 mg/kg/day till total cumulative dose of 120 mg/kg^[14]. The drug used was generic, known as Netlook (10, 20, and 40 mg) capsules (Al Andalous pharmaceutical Company, Cairo, Egypt). The drug was taken with fatty meals like milk or yoghurt once or twice per day for the predetermined period; all patients had follow-up visits every month to detect clinical response to treatment, to assess treatment regularity and compliance, for detection and management of adverse effects, and to check the periodical laboratory investigations. Empty medication strips were checked every visit to make sure that the patient took the drug regularly. No other systemic drugs or topical medications containing retinoids were prescribed during follow-up period to avoid drug bias.

Clinical adverse effects experienced by the patients included dry lips, dry hair, skin xerosis, eye xerosis, depressed mood, and body aches and fatigue. All these adverse effects were mild, and during follow-up, we prescribed suitable treatment for these adverse effects like skin emollients, artificial tears, hair oils, and anti-inflammatory drugs. These effects did not necessitate stoppage of isotretinoin. All periodical investigations done were in the normal ranges or slightly elevated. Minor changes occurred were accepted and did not lead to discontinuation of the medication.

Computer-assisted semen analyses

Semen analysis was done before and after the treatment course of systemic isotretinoin. Analysis was done by the same person using computer-assisted semen analysis (Mira Lab CASA, WLJY /9000 type Mira Lab semen analyzer, Weili color sperm analysis). Results were interpreted using WHO 2010 guidelines^[15].

Transmission electron microscope examination

Sperm ultrastructure assessment was done before and after treatment course by using TEM (Morgagni 268D electron microscopes, FEI, Hillsboro, Oregon, USA) in Electron Microscope Unit, Al-Azhar University, Cairo, Egypt. For preparing TEM examination, semen samples in phosphate buffered saline were centrifuged at 500g for 5 min, and then the pellet was fixed for 30 min at room temperature in a solution of 2.5% glutaraldehyde in 0.1 M sodium cacodylate buffer (pH 7.4) containing 0.03 M calcium chloride. Samples were washed twice with sodium cacodylate buffer (pH 7.4) and then postfixed with 1%

osmium tetroxide for 1 h at 4°C. Postfixed cells were dried with a graded ethanol series finishing with pure ethanol and finally immersed in Dow epoxy resin^[16]. To assess sperm ultrastructure changes by TEM, at least 80 complete undisturbed sperms were examined for structural defects. Findings were counted and divided into the following

categories: normal forms, head deformity, cytoplasmic residues, chromatin condensation failures, acrosomal alterations, neck defects, midpiece defects, principal piece and end-piece defects, and immature forms^[17]. The mean frequencies of these parameters were measured for every patient before and after isotretinoin treatment (Fig. 1).

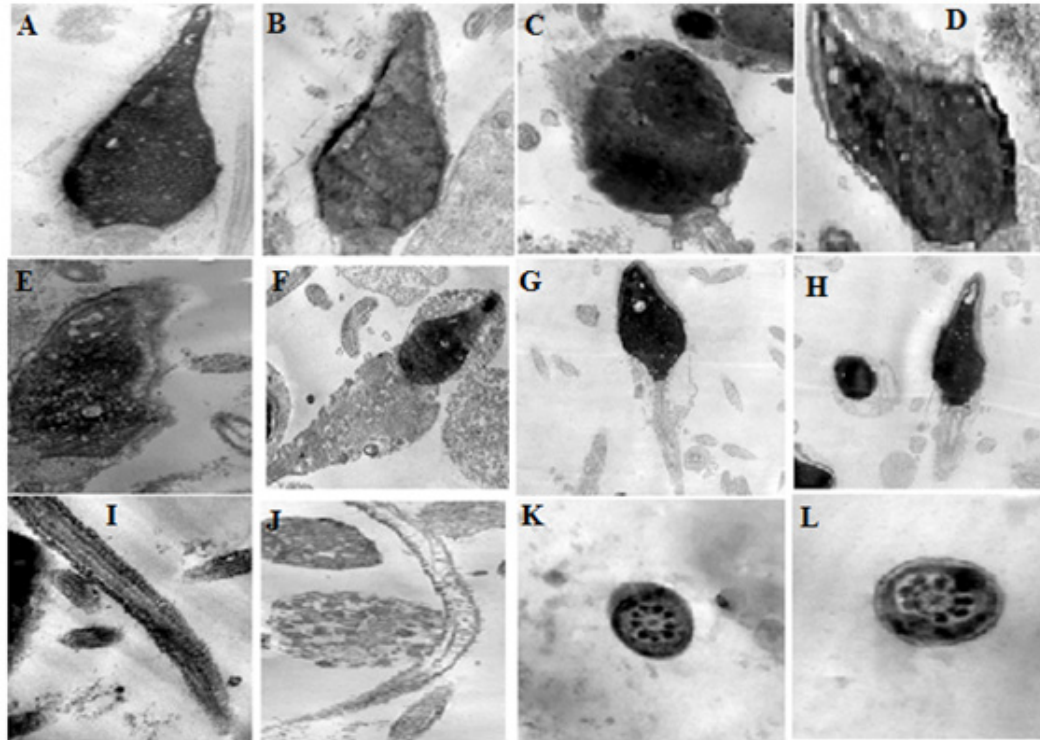


Fig. 1: Different sperm ultrastructural abnormalities seen by transmission electron microscope. (a, b) Normal sperm acrosome and head. (c, d) Abnormal sperm acrosome and head. (e) Abnormal chromatin condensation. (f, g) Cytoplasmic droplets and abnormal midpiece. (h) Abnormal neck midpiece. (i, l) Abnormal tail and end piece.

To make more objective assessment and numerical measurable difference for sperm ultrastructure changes after isotretinoin treatment than before treatment, additional evaluation method was used by measuring sperm structure dimensions (length, girth, and surface areas) like head length (μm), head width (μm), head area, acrosome length (μm), acrosome area, acrosome area of head (%), middle-piece length (μm), middle-piece width (μm), and tail length (μm). These measures were assessed for every patient, and the mean measure for each parameter had been recorded before and after treatment intake to be compared.

Ethical considerations

This study was approved by the Institutional Review Board and the Ethics Committee of Faculty of Medicine, Suez Canal University. All participants signed an informed consent form containing all needed data about aim and benefits of the study, isotretinoin doses and precautions, drug–drug interactions, and expected adverse effects.

Statistical analysis of the data

Data were managed using Statistical Package of Social Sciences (SPSS), version 20. Descriptive statistics were presented as mean \pm SD for quantitative variables and as percentage for qualitative variables. For relations between qualitative variables, χ^2 test was used. Significance value was less than or equal to 0.05.

RESULTS

The present study was carried out on 43 male patients with AV treated with systemic isotretinoin for at least 6 months; three patients were dropped off from follow-up, and the study continued on 40 patients. The mean age of enrolled patients was 23.25 ± 3.75 years and ranged between 18 and 38 years. A total of 29 (70.25%) patients were single and 11 (29.75%) patients were married (Table 1).

Table 1: Distribution of the studied cases according to sociodemographic data (N=40)

Age	
Minimum–maximum	18.0–38.0
Mean ±SD	23.25±3.75
Median	25.0
Residence [n (%)]	
Urban	29 (72.5)
Rural	11 (27.5)
Marital status [n (%)]	
Single	27 (67.5)
Married	13 (32.5)

Semen parameter changes after systemic isotretinoin therapy revealed that there was a statistically significant improvement in sperm concentration (million/ml), progressive sperm motility, and morphologically normal sperms before and after treatment, with statistically insignificant improvement concerning sperm count per ejaculate, total motile ratio, or sperm vitality. Mean sperm concentration was 75.76±28.40 million/ml before treatment versus 86.44±35.64 million/ml after treatment. Mean progressive motility was 51.20±4.93% before treatment versus 58.81±10.85% after treatment. Percentage of morphologically normal sperms was 42.82±2.49%

before treatment versus 47.50±3.52% after treatment (Table 2). Electron microscope examination of sperm ultrastructure and morphometry before and after systemic isotretinoin intake revealed that normal sperm percentage was increased after treatment than before (38.6±17.4 vs. 35.2±15.5%, respectively, $P>0.05$). All other sperm parameter frequencies (normal forms, head deformity, cytoplasmic residues, chromatin condensation failure, acrosomal alterations, neck defects, midpiece defects, principal piece and end-piece defects, and immature forms) were not significantly changed after isotretinoin than before isotretinoin treatment (Table 3).

Table 2: Distribution of the studied cases according to semen parameters before and after systemic isotretinoin treatment (N=40)

Semen parameter	Before treatment (mean ±SD)	After treatment (mean ±SD)	P value
Concentration (million/ml)	75.76±28.40	86.44±35.64	<0.001*
Count per ejaculate (million/ejaculate)	185.7±102.5	208.6±156.8	0.057
Progressive motility (%)	51.20±4.93	58.81±10.85	0.031*
Total motile ratio (%)	68.96±11.15	69.34±6.23	0.071
Morphologically normal sperms (%)	42.82±2.49	47.50±3.52	0.023*
Vitality (%)	65.79±6.01	69.41±7.18	0.078

*Statistically significant at P value less than or equal to 0.05 between the two groups.

Table 3: Distribution of the studied cases according to sperm ultrastructural changes by transmission electron microscope before and after systemic isotretinoin treatment (N=40)

Sperm parameters	Before treatment (mean±SD)	After treatment (mean ±SD)	P value
Normal forms (%)	35.2±15.5	38.6±17.4	0.067
Head deformity (%)	6.8±4.2	5.1±5.0	0.371
Cytoplasmic residues (%)	17.4±11.9	15.2±13.4	0.098
Chromatin condensation failure (%)	4.9±4.1	5.1±3.9	0.421
Acrosomal alterations (%)	11.5±14.7	10.2±12.9	0.124
Neck defects (%)	2.5±5.9	1.9±3.1	0.086
Midpiece defects (%)	3.1±6.8	4.7±6.6	0.541
Principal piece and end-piece defects (%)	6.3±7.1	4.8±6.1	0.051
Immature forms (%)	14.7±12.8	16.9±13.1	0.124

*Statistically significant at P value less than or equal to 0.05 between the two groups.

Regarding sperm's main parts' dimension change, there was no significant change in all sperm part measures (acrosome, head area, middle piece, and sperm tail) after the period of treatment than before treatment, denoting that use of systemic isotretinoin had no significant effect on sperm ultrastructure (Table 4).

Correlation between sperm ultrastructure and

morphometry using TEM on one hand and patient's age, sperm concentration per ml, and sperm progressive motility before use of isotretinoin on the other hand revealed that there was no statistically significant correlation between sperm morphometry and these parameters, whereas only head and acrosome areas in electron microscope analysis were significantly correlated with morphologically abnormal sperm percentage (Table 5).

Table 4: Distribution of the studied cases according to sperm structure dimensions using transmission electron microscope before and after isotretinoin treatment (N=40)

Sperm parameter	Before treatment (mean \pm SD)	After treatment (mean \pm SD)	<i>P</i> value
Head length (μ m)	5.08 \pm 0.4	5.99 \pm 0.5	0.153
Head width (μ m)	2.75 \pm 0.42	3.06 \pm 0.43	0.915
Head area (μ m ²)	11.99 \pm 2.41	14.68 \pm 3.01	0.941
Acrosome length (μ m)	2.86 \pm 0.78	2.69 \pm 0.69	0.468
Acrosome width (μ m)	1.76 \pm 0.43	1.99 \pm 0.43	0.503
Acrosome area (μ m ²)	4.76 \pm 1.84	4.32 \pm 1.65	0.899
Acrosome area of head (%)	37.06 \pm 14.54	35.39 \pm 14.83	0.655
Middle-piece length (μ m)	6.29 \pm 0.73	6.23 \pm 0.73	0.699
Middle-piece width (μ m)	0.68 \pm 0.19	0.75 \pm 0.16	0.054
Tail length (μ m)	43.9 \pm 0.36	45.4 \pm 0.38	0.503

Statistically significant at *P* value less than or equal to 0.05 between the two groups.

Table 5: Correlation between sperm structures dimensions using transmission electron microscope with age and semen parameters before the use of systemic isotretinoin

Sperm parameter	Before treatment (mean \pm SD)	After treatment (mean \pm SD)	<i>P</i> value
Head length (μ m)	5.08 \pm 0.4	5.99 \pm 0.5	0.153
Head width (μ m)	2.75 \pm 0.42	3.06 \pm 0.43	0.915
Head area (μ m ²)	11.99 \pm 2.41	14.68 \pm 3.01	0.941
Acrosome length (μ m)	2.86 \pm 0.78	2.69 \pm 0.69	0.468
Acrosome width (μ m)	1.76 \pm 0.43	1.99 \pm 0.43	0.503
Acrosome area (μ m ²)	4.76 \pm 1.84	4.32 \pm 1.65	0.899
Acrosome area of head (%)	37.06 \pm 14.54	35.39 \pm 14.83	0.655
Middle-piece length (μ m)	6.29 \pm 0.73	6.23 \pm 0.73	0.699
Middle-piece width (μ m)	0.68 \pm 0.19	0.75 \pm 0.16	0.054
Tail length (μ m)	43.9 \pm 0.36	45.4 \pm 0.38	0.503

Table 5: Correlation between sperm structures dimensions using transmission electron microscope with age and semen parameters before the use of systemic isotretinoin

		Age	Sperm count million/ml	Progressive motility %	Motile ratio %	Normal sperms (%)
Head length (µm) (pre)	<i>P</i>	0.311	0.019	0.157	0.159	-0.277
	<i>p</i> -value	0.051	0.908	0.334	0.328	0.042*
Head width (µm) (pre)	<i>P</i>	0.117	0.069	0.067	0.125	0.321
	<i>p</i> -value	0.471	0.674	0.681	0.441	0.023*
Head area (µm ²) (pre)	<i>P</i>	0.241	0.086	0.153	0.191	0.176
	<i>p</i> -value	0.134	0.599	0.345	0.239	0.017*
Acrosome length (µm) (pre)	<i>P</i>	0.203	0.089	0.036	-0.083	0.089
	<i>p</i> -value	0.208	0.585	0.823	0.611	0.586
Acrosome width (µm) (pre)	<i>P</i>	0.245	0.010	0.172	0.016	0.021
	<i>p</i> -value	0.128	0.950	0.289	0.921	0.079
Acrosome area (µm) (pre)	<i>P</i>	0.307	0.089	0.121	-0.092	0.050
	<i>p</i> -value	0.054	0.585	0.458	0.574	0.015*
Acrosome area (µm ²) (pre)	<i>P</i>	0.186	0.032	0.148	-0.165	-0.036
	<i>p</i> -value	0.251	0.844	0.361	0.308	0.824
Middle-piece length (µm) (pre)	<i>P</i>	-0.003	0.041	0.081	0.143	0.009
	<i>p</i> -value	0.987	0.803	0.619	0.379	0.954
Middle-piece width (µm) (pre)	<i>ρ</i>	0.034	0.323	0.084	-0.017	-0.247
	<i>p</i> -value	0.834	0.760	0.606	0.915	0.125
Tail length (µm) (pre)	<i>ρ</i>	0.044	0.158	0.014	0.090	0.152
	<i>p</i> -value	0.790	0.331	0.932	0.579	0.349

DISCUSSION

AV pathogenesis is multifactorial, including four related mechanisms: hyperkeratinization of the follicular orifices, sebum hyperproduction, infection with *Propionibacterium* acnes, and inflammation. Isotretinoin therapy is a form of systemic retinoids that is considered the preferred treatment in patients with resistant acne and patients with moderate to severe acne who are not responsive to systemic antibiotics^[18]. Isotretinoin provides a potent therapeutic option in dermatology other than AV treatment, like rosacea, seborrheic dermatitis, warts, dissecting cellulitis of the scalp, lupus miliaris disseminatus, hidradenitis suppurativa, and many other dermatological conditions with accepted success and efficacy^[19].

Systemic isotretinoin has well-known adverse effects, including mucous and cutaneous adverse effects, elevated liver enzymes, dyslipidemia, inflammatory bowel disease, depression, and the most frightening serious adverse effect teratogenicity^[20]. Strict contraceptive measure and pregnancy prevention programs must be used in childbearing age women during isotretinoin therapy intake and for a period of at least 1 month after its stoppage^[21].

Systemic isotretinoin effect on male fertility is an important issue that was not fully understood. Animal

studies demonstrated that isotretinoin can cause impairment of spermatogenesis in rats and increased testicular germ cell apoptosis if given in a dose of 2 mg/ml/day for 21 days by reduction in the number of cyclin D1 and E2F-positive cells^[22]. In humans, systemic isotretinoin was reported to have a favorable positive effect on male fertility through its regenerative and proliferative effects on the testes^[7].

In the present study, we tried to determine the actual effect of systemic isotretinoin on male fertility potential not only by gross semen analysis changes but also by assessing sperm morphology and ultrastructural changes using TEM before and after treatment course.

In the current work, we found that main semen parameters significantly improved after systemic isotretinoin therapy. Mean sperm concentration was improved from 75.76±28.40 million/ml before treatment to 86.44±35.64 million/ml after treatment ($P<0.05$). Mean progressive motility was improved from 51.20±4.93% before treatment to 58.81±10.85% after treatment ($P<0.05$). Mean percentage of morphologically normal sperms was improved from 42.82±2.49% before treatment to 47.50±3.52% after treatment ($P<0.05$). These results were reported after a maximum period of 6 months of systemic isotretinoin treatment and a cumulative dose of 120 mg/kg, with exclusion of other factors that can

affect sperm production or morphology, which provided a reliable results and drug effect bias avoidance.

Our results were in agreement with Vogt and Ewers^[23] who studied the effect of isotretinoin on spermatogenesis in humans and found that no significant change in the semen parameters occurred in healthy men after isotretinoin treatment by 3 months, whereas increased sperm concentrations in patients with varicocele was noticed after isotretinoin use. In the same line, Çinar *et al.*^[7] reported significant change in semen parameters after systemic isotretinoin treatment with positive effect, especially sperm concentration, total progressive motile sperm, normal morphology, and vitality.

Amory *et al.*^[24] carried out a single-armed pilot study on 19 infertile men with oligoasthenozoospermia aged from 21 to 60 years to determine the effect of systemic isotretinoin therapy on sperm parameters. They reported that the median sperm concentration had been changed from 2.5 million/ml before treatment to 3.8 million/ml after treatment ($P=0.006$). No significant improvement in total sperm motility was also reported. There was a trend toward improved sperm morphology but was not significant^[24].

Mechanism of action of isotretinoin on spermatogenesis is incompletely understood, but increased intratesticular 13-cis-RA level that correlates strongly with the levels of the ALDH1A enzymes was suggested^[25]. ALDH1A enzymes are decreased in the testes of men with abnormal semen parameters^[26]. In addition, high levels of CYP26 expression, which is the enzyme that metabolizes RA to inactive metabolites, in the peritubular myoid cells, might begin to increase at 10th day postnatal and continue in a high concentration through 20th day postnatal to adulthood^[27]. We hypothesize that isotretinoin may improve semen parameters in males by increased morphogenesis, immune modulation, epithelial cell proliferation and differentiation, reduction of lipid synthesis through inhibition of terminal differentiation, stimulation of angiogenesis, and inhibition of carcinogenesis^[28].

TEM is characterized by its ability to explore the inner environment of cells, providing a more full approach to assess sperm pathology and to achieve an accurate diagnosis, to choose the more appropriate therapeutic option^[13]. TEM is the most accurate method assessing teratozoospermia in males either fertile or not; heterogeneous alterations in the shape of different sperm components that affect the fertilizing capacity of male patient can be discovered by electron microscope despite normal appearance by light microscope, which may reflect the functional and structural disorders of the altered sperms^[29]. Ultrastructural defects of spermatozoa by electron microscope had been studied by many authors, and different classifications were taken into consideration^[17,30-32].

All researchers who studied the effect of systemic isotretinoin on sperm parameters used conventional semen analysis to judge on this effect. In this study, we had used

computer-assisted semen analysis, and in addition, we were the first to use TEM as a precise method to study sperm ultrastructure, sperm structure dimensions, and sperm morphology before and after treatment to study accurately if systemic isotretinoin had a harmful effect on male fertility potential or not.

Kotwicka *et al.*^[17] studied sperm ultrastructure changes in the 49 infertile couples undergoing in vitro fertilization technique. They reported eight ultrastructural parameters to be measured by TEM in spermatozoa of infertile men, which included acrosomal alterations, chromatin condensation failure, cytoplasmic residues, head deformity, neck defects, midpiece defects, main piece and end-piece tail defects, and immature forms. This evaluation of the proportion of abnormal sperms was dependent on the sperm volume and shape. They concluded that ultrastructural evaluation of sperms can facilitate male fertility diagnosis and might give explanations for failed assisted reproduction techniques. They recommended that TEM spermatozoa examination in patients with failed in vitro fertilization before intracytoplasmic sperm injection was mandatory and gave more success rates.

Visco *et al.*^[33] classified the abnormalities of spermatozoa by TEM according to sperm structures into (a) head abnormalities, which included nucleus shape and/or chromatin and/or inclusions and/or vacuoles; plasma membrane, preserved or fragmented; and acrosome, hypoplastic or irregular; (b) neck and midpiece defect abnormalities, which included mitochondria, irregular or regular; plasma membrane, preserved or fragmented; and axoneme, numerical and/or morphological alterations of the microtubules and/or inner outer dynein arms; and (c) tail defects, which included axoneme, numerical and/or morphological alterations of the microtubules and/or inner outer dynein arms; dense fibers and fibrous sheath (irregular); and combined defects, such as presence of more than one of the aforementioned defects.

In the current work, we studied spermatozoa by TEM; we used the classification of Kotwicka *et al.*^[17] as the main method for assessment of the difference of sperm ultrastructure. We found that normal sperm percentage was increased after treatment than before treatment (38.6 ± 17.4 vs. $35.2\pm 15.5\%$, respectively, $P>0.05$). Some sperm parameters were insignificantly improved after treatment like head deformity, cytoplasmic residues, acrosomal alterations, neck defects and principal piece, and end-piece defects, whereas other sperm parameters like chromatin condensation failure, midpiece defects, and immature forms deteriorated insignificantly after isotretinoin than before isotretinoin treatment.

We used additional method of TEM evaluation of sperms by measuring mean sperm structure dimensions like head length (μm), head width (μm), head area (μm^2), acrosome length (μm), acrosome area (μm^2), acrosome area of head (%), middle-piece length (μm), middle-piece

width (μm), and tail length (μm) as a measurable scale of tracking change in sperm structures after treatment course, which was a confirmatory method of sperm ultrastructure assessment. Results in this issue showed that no significant change occurred in sperm dimensions including head length (μm), head width (μm), head area (μm^2), acrosome length (μm), acrosome area (μm^2), acrosome area of head (%), middle-piece length (μm), middle-piece width (μm), and tail length (μm) after 6 months of systemic isotretinoin therapy or total cumulative dose of 120 mg/kg which is a more confirmed evidence of systemic isotretinoin safety on male fertility.

In the current study, we found also no statistically significant correlation between sperm structure dimensions by TEM and patient's age, sperm concentration per ml, and sperm progressive motility, whereas only head and acrosome areas in TEM examination were significantly correlated to morphologically abnormal sperms percentage.

Limitations of the study were the small sample size, poor patient compliance to long treatment periods, side effects of the administered drug, and cost and unavailability of electron microscope examination. Another limitation of the study was follow up of semen parameters and sperm ultrastructural changes only at the end of isotretinoin treatment course. It would be better if semen parameters and sperm ultrastructural changes had been re-measured again after 3 or 6 months after the end of isotretinoin course as adverse effects of drug could occur after a period of time of termination of treatment course.

CONCLUSION

Systemic isotretinoin has no harmful effect on semen parameters. Isotretinoin had a positive effect on some semen parameters (sperm concentration, progressive sperm motility, and morphologically normal sperms). Systemic isotretinoin after 6 months of use had no negative effects on sperm morphology or ultrastructure using TEM.

CONFLICT OF INTEREST

There are no conflicts of interest.

REFERENCES

- Bhate K, Williams H. Epidemiology of acne vulgaris. *Br J Dermatol* 2013; 168:474–485.
- Bettoli V, *et al.* Challenges and solutions in oral isotretinoin in acne: reflections on 35 years of experience. *Clin Cosmet Investig Dermatol* 2019; 12:943.
- Dréno B, *et al.* Adult female acne: a new paradigm. *J Eur Acad Dermatol Venereol* 2013; 27:1063–1070.
- Guerra-Tapia A, Asensio Martinez A, Garcia Campayo J. The emotional impact of skin diseases. *Actas Dermosifiliogr* 2015; 106:699–702.
- Cořta CS, *et al.* Oral isotretinoin for acne. *Cochrane Database Syst Rev* 2018; 11:Cd009435.
- Nelson AM, *et al.* 13-cis retinoic acid induces apoptosis and cell cycle arrest in human SEB-1 sebocytes. *J Invest Dermatol* 2006; 126:2178–2189.
- Çinar L, *et al.* The effect of systemic isotretinoin on male fertility. *Cutan Ocul Toxicol* 2016; 35:296–299.
- Thiboutot DM, *et al.* Practical management of acne for clinicians: an international consensus from the Global Alliance to Improve Outcomes in Acne. *J Am Acad Dermatol* 2018; 78:S1–S23.e1.
- Sonthalia S, *et al.* Nocebo effect in dermatology. *Indian J Dermatol Venereol* 2015; 81:242.
- Holst H, Muhari-Stark E, Lava SA. Teratogenicity of systemic isotretinoin. *Minerva Pediatr* 2018; 70:107–109.
- Török L, Kádár L, Kása M. Spermatological investigations in patients treated with tretinate and isotretinoin. *Andrologia* 1987; 19:629–633.
- Aitken RJ, Baker MA. Oxidative stress, sperm survival and fertility control. *Mol Cell Endocrinol* 2006; 250:66–69.
- Moretti E, Sutura G, Collodel G. The importance of transmission electron microscopy analysis of spermatozoa: Diagnostic applications and basic research. *Syst Biol Reprod Med* 2016; 62:171–183.
- Penna P, Meckfessel MH, Preston N. Fixed-dose combination gel of adapalene and benzoyl peroxide plus doxycycline 100 mg versus oral isotretinoin for the treatment of severe acne: efficacy and cost analysis. *Am Health Drug Benefits* 2014; 7:37.
- Tocci A, Lucchini C. WHO reference values for human semen. *Hum Reprod Update* 2010; 16:559–559.
- Ricci G, *et al.* Ultrastructural morphology of sperm from human globozoospermia. *Biomed Res Int* 2015; 2015:798754.
- Kotwicka M, *et al.* Human spermatozoa ultrastructure assessment in the infertility treatment by assisted reproduction technique. *Arch Androl* 2007; 53:297–302.
- Zaenglein AL. Acne vulgaris. *N Engl J Med* 2018; 379:1343–1352.
- Forbat E, Ali FR, Al-Niामी F. Dermatological indications for the use of isotretinoin beyond acne. *J Dermatolog Treat* 2018; 29:698–705.
- Melnik BC. Apoptosis may explain the pharmacological mode of action and adverse effects of isotretinoin, including teratogenicity. *Acta Derm*

-
- Venereol 2017; 97:173–181.
21. Lam C, Zaenglein AL. Contraceptive use in acne. *Clin Dermatol* 2014; 32:502–515.
 22. Gencoglan G, Tosun M. Effects of isotretinoin on spermatogenesis of rats. *Cutan Ocul Toxicol* 2011; 30:55–60.
 23. Vogt HJ, Ewers R. 13-cis-retinoic acid and spermatogenesis. *Hautarzt* 1985; 36:281–286.
 24. Amory JK, *et al.* Isotretinoin administration improves sperm production in men with infertility from oligoasthenozoospermia: a pilot study. *Andrology* 2017; 5:1115–1123.
 25. Arnold SL, *et al.* Importance of ALDH1A enzymes in determining human testicular retinoic acid concentrations. *J Lipid Res* 2015; 56:342–357.
 26. Amory JK, *et al.* Levels of the retinoic acid synthesizing enzyme aldehyde dehydrogenase-1A2 are lower in testicular tissue from men with infertility. *Fertil Steril* 2014; 101:960–966.
 27. Wu JW, *et al.* Expression of the retinoic acid-metabolizing enzymes RALDH2 and CYP26b1 during mouse postnatal testis development. *Asian J Androl* 2008; 10:569–576.
 28. Zouboulis CC. Isotretinoin revisited: pluripotent effects on human sebaceous gland cells. *J Invest Dermatol* 2006; 126:2154–2156.
 29. Moretti E, *et al.* Immunolocalization of aquaporin 7 in human sperm and its relationship with semen parameters. *Syst Biol Reprod Med* 2012; 58:129–135.
 30. Zamboni L. Sperm structure and its relevance to infertility. An electron microscopic study. *Arch Pathol Lab Med* 1992; 116:325–344.
 31. Bartoov B, *et al.* Quantitative ultramorphological analysis of human sperm: fifteen years of experience in the diagnosis and management of male factor infertility. *Arch Androl* 1999; 43:13–25.
 32. K pker W, Schulze W, Diedrich K. Ultrastructure of gametes and intracytoplasmic sperm injection: the significance of sperm morphology. *Hum Reprod* 1998; 13 Suppl 1:99–106.
 33. Visco V, *et al.* Morphological sperm defects analyzed by light microscopy and transmission electron microscopy and their correlation with sperm motility. *Int J Urol* 2010; 17:259–66.
-