

**The Effect of Bone Marrow Aspirate Concentrate
on Bone Regenerate During Mandibular
Distraction Osteogenesis Experimental Study
Research project**

Mohammad Seif El-Nsr Ali El-Nadi

Research project

Submitted in partial fulfillment of the requirements for master degree in oral and maxillofacial surgery

by

Mohammad Seif El-Nsr Ali El-Nadi

BDS 2011

Ain shams university

Supervisors

Dr/ HebaAbdulwahedSleem

Associate Professor

Department of Oral and Maxillofacial Surgery,

Faculty of Dentistry, Ain Shams University

Dr/ Karim Mohamed Mahmoud AbdelMohsen

Lecturer

Department of Oral and Maxillofacial Surgery,

Faculty of Dentistry, Ain Shams University

Effect of Mesenchymal Stem Cells (Bone Marrow Aspirate Concentrate) Application on Bone Physical and Mechanical Properties (Experimental study)

Aims & Objectives: Distraction osteogenesis (DO) is technique performed in different craniofacial and cleft lip/palate treatment protocols. The aim of this study is to assess the effect of Mesenchymal stem cells (MSCs); added in the form of Bone Marrow Aspirate Concentrate (BMAC) on DO bone regenerate physical properties.

Material & Methods: 6 goats were undergone bilateral DO where the right side was enhanced with BMAC as a Study group (Group A) while the left side kept non assisted as a Control group (Group B). Group A was enhanced by addition of BMAC (The distracted site received 1million MSCs). Radiographic assessment measured the bone density, the Three-Dimensional (3D) bone quantity and volume. The three point bending test assessed the biomechanical strength of the distracted bone.

Results: Assessment of bone density showed a NS ($P = 0.48$) increase in bone density in group (A) (mean BD= 1634.17 HU, SD = 64.6 HU) compared to (B) (mean BD= 1566.67 HU, SD= 217.55 HU). Assessment of Bone Height (BH) showed NS ($P = 0.072$) increase in BH in group (A) (mean BH= 16.46 mm, SD =0.82 mm) compared to (B) (mean BH= 15.6 mm, SD=0.56 mm). Assessment of bone width (BW) showed NS ($P = 0.44$) increase in bone width in group (A) (mean BW= 5.03 mm, SD =0.69 mm) compared to (B) (mean BW= 4.68 mm, SD=0.82 mm).

Assessment of bone volume showed a NS ($P = 0.15$) increase in bone volume in group (A) (mean BV/TV= 49.47 %, SD =4.5 %) compared to (B) (mean BV= 43.9 %, SD=7.5 %). Assessment of Biomechanical testing (three-point bending test) showed a NS ($P = 0.71$) increase in bone strength in group (A) (mean BD= 511.67 N, SD = 189.08N) compared to (B) (mean BD= 467.83 N, SD= 201.11 N).

Discussion& Summary: The combined results showed a correlated improvement in bone physical properties. However, none of the results was of statistical significance which mandates further assessment because physical properties are the properties which will affect the clinical outcome of MSCs application.

Introduction:

Distraction osteogenesis (DO) is technique performed in different craniofacial and cleft lip/palate treatment protocols. The distraction osteogenesis in maxillofacial region is a treatment protocol proposed by McCarthy et al. in 1992 to generate bone and soft tissue volume; to overcome the congenital deficiency present in the mandible and surrounding soft tissue. (1,2).

Mesenchymal Stem Cells (MSCs) was a protocol advocated by several authors to enhance distracted bone quality. In a recent review published by Yang et al.(3) they found 16 articles concerned with MSCs application during DO all of them focused on bone microscopic quality. However, only 4 articles focused on mechanical properties and 4 articles focused on bone volume; although

mechanical properties and bone volume have direct effect on clinical outcome of procedure and decrease of healing time and early distractor removal.

Material and Methods

An experimental study was conducted to evaluate the effect of MSCs in form of Bone Marrow Aspirate Concentrate (BMAC) on bone volume and bone mechanical properties; which wouldn't have been feasible in the clinical study due to the ethical concerns. The surgical protocol followed El Hadidi et al. (4) surgical an anesthetic protocol on goats.

1. Animal grouping and housing

The study followed the guideline of research ethical committee code of practice for animal care and housing in the authors institute. 6goats of average weight (10 kg) were housed in Animal house of Faculty of Medicine. Animals were kept there for at least one week preoperatively for adaptation and observation by a veterinarian before the beginning of the procedure. Animals were undergone bilateral DO where the right side was enhanced with BMAC as a Study group (Group A) while the left side kept non assisted as a Control group (Group B).

2. Operative procedure

A) Anesthetic protocol:

Surgeries was done in aseptic condition in the animal house of Faculty of Medicine. Animals was pre-medicated by 1.0 mg/Kg Xylazine IV which is a sedative; The recommended dose is 1.0 and intravenous anesthetic 25 mg/kg Sodium Thiopental and maintained by 10 mg/Kg ketamine hydrochloride 1 mg every minute.

B) Surgical protocol

The right submandibular and submental

area was shaved prior to procedure. The area was scrubbed with Povidone-iodine 10-12% before the incision. Local anesthetic articaine 4% with 1:200,000 epinephrine field block was injected to reduce postoperative pain. The incision was done using size 15 Bard Parker surgical blades. A vertical osteotomy was done in the right-side of mandible using low speed hand piece associated with copious irrigation by saline followed by complete osteotomy using chisel and mallet. A stainless-steel mono-directional distractor was fixed in place at both osteotomy ends by two 2.0 mm mini screws. Trial activation and deactivation was made to assure function. An anterior skin puncture was done to allow exit of distractor activation screw through the skin for activation during distraction procedure. (Figure 1)

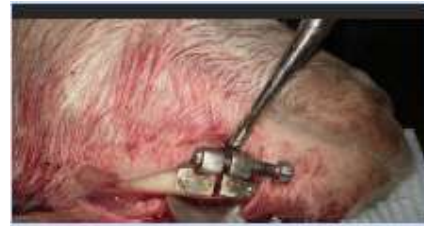

Figure 1: Distractor fixed in place

Cefotaxime 100 mg covered animal once daily for five days post-operative and pain was controlled by Diclofenac Potassium Intramuscular injection. Animal sacrifice was performed by injecting overdose thiopental and animals was incinerated in faculty of medicine medical incinerator.

3) Mesenchymal stem cell preparation:

The aim of the current article was to assess the clinical significance of MSCs application. The use of MSCs in clinical studies is prohibited in many countries due ethical concerns related to direct use of MSCs (5). However, the use of BMAC which is rich with MSCs is allowed due to its autologous nature and no external intervention or multiplication of cells and is accepted

in clinical practice (6). As a result of the allowance of BMAC in clinical practice in current research BMAC was used as source of MSCs.

Stem cells were prepared to be injected in group (A). Bone Marrow was aspirated using wide bore gauge spinal needle from iliac crest to harvest stem cell. Bone marrow was treated by Ficoll(6) protocol to prepare MSCs in form of BMAC. The aspirated bone marrow was mixed with Phosphate Buffered Saline (PBS) in ratio 4:1. The mixture was titrated over Ficoll 400 and centrifuged at 2,000 rpm for 20 minutes. The undifferentiated mesenchymal stem cells aggregate in form of buffy layer which was by pipette. The buffy layer was diluted by PBS again and recentrifuged twice to ensure high concentration of MSCs.

4) Assessment of experiment results:

The amount of bone regenerate formation was measured in two dimensions. The buccolingual dimensions, superoinferior dimensions and bone volume was assessed by two observers radiographically by Cone Beam Computed Tomography in addition to the bone density at fixed parameters (84 Kv, 4 mA and 12 Sec) using Sidexs software (Sirona, Germany).

Biomechanical testing (three-point bending test) was done at week four after sacrifice. All specimens were subjected to three-point bending testing using an electronic material testing machine Lloyd LR5K (Ametek, United Kingdom). The specimens were positioned and fixed on the base plate, and the three-point bending load was applied at rate

of two mm/min until the specimen rupture(7).(Figure 2)




Figure 2: A sample in Lloyd LR 5K mechanical testing machine

Results:

Assessment of Bone Height (BH) showed NS ($P = 0.072$) increase in BH in group (A) (mean BH= 16.46 mm, SD =0.82) compared to (B) (mean BH= 15.6 mm, SD=0.56). Assessment of bone width (BW) showed NS ($P = 0.44$) increase in bone width in group (A) (mean BW= 5.03 mm, SD =0.69) compared to (B) (mean BW= 4.68 mm, SD=0.82). Assessment of bone volume showed a NS ($P = 0.15$) increase in bone volume in group (A) (mean BV/TV= 49.47 %, SD =4.5 %) compared to (B) (mean BV= 43.9 % mm³, SD=7.5 %) (Figure 3-Figure 4).

Assessment of bone density showed a NS ($P = 0.48$) increase in bone height in group (A) (mean BD= 1634.17, SD =64.6) compared to (B) (mean BD= 1566.67, SD=217.55)

Assessment of Biomechanical testing (three-point bending test) showed a NS ($P = 0.71$) increase in bone strength in group (A) (mean BD= 511.67 N, SD =189.08N) compared to (B) (mean BD= 467.83 N, SD=201.11 N)

Discussion

Assessment of bone biomechanical strength was assessed by three point bending test. Up to our knowledge only four studies were concerned with assessment of biomechanical strength of distracted bone enhanced by MSC. The results showed increase in bone strength indicating more rapid healing in agreement with Takamine et al (15), Sunay et al. (19), Nomura et al. (20) and Xu et al. (16). However, the results showed no statistical significance increase in bone strength.

In the current study there was improvement in strength, density and bone volume. However, the improvement was of no statistical significance, but there was a correlated increase in strength, volume and density which proves that BMAC may fasten the healing of the distracted sector.

Further examination should be done to evaluate the effect of MSCs in form of BMAC on distracted. And until new observation is published in literature our article still recommends soft tissue augmentation of affected side prior to distraction osteogenesis either by fat or fillers to improve volume defects (21,22). The article also recommend classic consolidation time till BMACs proves in future article it effect on fastening the bone healing.

References

1. McCarthy, J. G., Schreiber, J., Karp, N., Thorne, C. H., & Grayson, B. H. (1992). Lengthening the human mandible by gradual distraction. *Plast Reconstr Surg*. 1992 Jan;89(1):1-8.
2. Swennen G, Schliephake H, Dempf R, Schierle H, Malevez C. Craniofacial distraction osteogenesis: A review of literature: Part 1: Clinical studies. *Int J Oral Maxillofac Surg*. 2001;30:89–10
3. Yang Y., Lin S., Wang B., Gu W., and Li G. Stem cell therapy for enhancement of bone consolidation in distraction osteogenesis A contemporary review of experimental studies. *Bone Joint Res*. 2017 Jun; 6(6): 385–390.
4. El Hadidi YN, El Kassaby M, Ahmed SA, Khamis NS. Effect of Mesenchymal Stem Cell Application on the Distracted Bone Microstructure: An Experimental Study. *Journal of Oral and Maxillofacial Surgery*. 2016 Jul 31;74(7):1463-e1.
5. Gilbert DM. "The future of human embryonic stem cell research: addressing ethical conflict with responsible scientific research". *Med Sci Monit*. 2004 May;10(5): 99-103
6. Sauerbier S, Stricker A, Kuschnierz J, Bühler F, Oshima T, Xavier SP, Schmelzeisen R, Gutwald R. In vivo comparison of hard tissue regeneration with human mesenchymal stem cells processed with either the FICOLL method or the BMAC method. *Tissue Eng Part C Methods*. 2010 Apr;16(2):215-23.
7. Kokoroghiannis C, Charopoulos I, Lyritis G, Raptou P, Karachalios T, Papaioannou N. Correlation of pQCT bone strength index with mechanical testing in distraction osteogenesis. *Bone*. 2009 Sep;45(3):512-6.
8. Mommaerts MY, Nagy K. Is early osteodistraction a solution for the ascending ramus compartment in hemifacial microsomia? A literature study. *J Craniomaxillofac Surg*. 2002;30:201–7
9. Emara KM, Ghafar KAA, and Al Kersh MA. Methods to shorten the duration of an external fixator in the management of tibial infections. *World J Orthop*. 2011 Sep 18; 2(9): 85–92.
10. Shruthi, M., Ashok, k. S., Annapurna, P.D.(2012) Importance of stem cells in dentistry. *Annals and Essences of Dentistry*.2012;4(2):75-8. 4.
11. Kitoh H, Kitakoji T, Tsuchiya H, Katoh M, Ishiguro N. Distraction osteogenesis of the lower extremity in patients with achondroplasia/hypochondroplasia treated with transplantation of culture-expanded bone marrow cells and platelet-rich plasma. *J Pediatr Orthop*. 2007;27:629–634

12. Aykan A, Ozturk S, Sahin I, Gurses S, Ural AU, Oren NC, et al. Biomechanical analysis of the effect of mesenchymal stem cells on mandibular distraction osteogenesis. *J Craniofac Surg.* 2013;24:e169–e175.

13. Ma D, Ren L, Yao H, Tian W, Chen F, Zhang J, et al. Locally injection of cell sheet fragments enhances new bone formation in mandibular distraction osteogenesis: a rabbit model. *J Orthop Res.* 2013;31:1082–1088

14. Sato K, Haruyama N, Shimizu Y, Hara J, Kawamura H .Osteogenesis by gradually expanding the interface between bone surface and periosteum enhanced by bone marrow stem cell administration in rabbits.*Oral Surg Oral Med Oral Pathol Oral RadiolEndod.* 2010 Jul;110(1):32-40.

15. Takamine Y, Tsuchiya H, Kitakoji T, Kurita K, Ono Y, Ohshima Y, Kitoh H, Ishiguro N, Iwata H. Distraction osteogenesis enhanced by osteoblastlike cells and collagen gel. *ClinOrthopRelat Res.* 2002 Jun;(399):240-6.

16. Xu J, Wang B, Sun Y, Wu T, Liu Y, Zhang J, Lee WY, Pan X, Chai Y, Li G.Human fetal mesenchymal stem cell secretome enhances bone consolidation in distraction osteogenesis. *Stem Cell Res Ther.* 2016 Sep 10;7(1):134.