

## **Volumetric analysis of Submucosal palatal island flap in soft tissue ridge augmentation in the maxillary esthetic zone: A Randomized controlled clinical study**

*Esraa Abdelhameed\*, Ahmad Abd El Aziz\*\*, Mohamed El-Mofty\*\*\* and Mohamed Wagdy\*\*\*\**

### **ABSTRACT**

**Aim:** The aim of this randomized-controlled clinical trial was Assessment of **volume gained using** submucosal palatal island flap for soft tissue ridge augmentation in the maxillary esthetic zone and compare it with subepithelial connective tissue graft in the amount of volume gained, post-surgical pain, patient satisfaction and healing time of both treatment modalities.

**Subjects and methods:** Twenty patients were included in the study for soft tissue augmentation procedure in the maxillary esthetic zone . They were divided into two groups, ten received submucosal palatal island flap and tenreceived subepithelial connective tissue graft . quantitative three-dimensional (3D) analysis based on laser scanning was used for the measurement of volume gain and horizontal changes of alveolar profile 3months after soft tissue augmentation

### **Results:**

Regarding the volume gained Control group ( $32 \pm 24.74\text{mm}^3$ ) had a significantly higher mean value of soft tissue volume gained than the study group ( $12.60 \pm 10.71\text{mm}^3$ ).

\*B.D.S, Faculty of Dentistry, Ain Shams University, 2012

\*\*Associate Professor of Oral Medicine, Periodontology and Oral Diagnosis, Faculty of Dentistry, Ain Shams University

\*\*\*Associate Professor of Oral Medicine, Periodontology and Oral Diagnosis, Faculty of Dentistry, Ain Shams University

\*\*\*\*Lecturer of Oral Medicine, Periodontology and Diagnosis, Faculty of Dentistry, Ain Shams University

Linear measurement values were higher in control group ( $7.85 \pm 0.58$ ) than the study group ( $7.65 \pm 0.85$ ) but the difference was not significant 3 months post-operative. The mean value of (VAS) scores in the control group was significantly higher than the study group 10 days after the surgery, 1 month and 3 months post-operative. The mean value of gingival swelling, gingival color score and bleeding index were higher in control group than study group but difference was not significant. There was no significant correlation between healing index and post-surgical pain

**Conclusion** we can conclude that: both soft tissue augmentation techniques were effective in increasing the volume of defective alveolar ridges in single tooth gaps in the anterior maxilla. The quantitative volumetric assessment revealed a significantly greater volume gain with the subepithelial connective tissue graft in comparison to the submucosal palatal island flap 3 months after surgery. However, Submucosal palatal island flap is less painful, with less gingival swelling score and gingival color score than sub epithelial connective tissue graft. Also, there was no difference observed in bleeding index

## INTRODUCTION

Soft tissue esthetics is a concern not only related to smile design, but also to missing gingival tissues around a tooth /implant or beneath a fixed prosthesis. Sound prosthetic rehabilitation requires a good hard, and soft tissue foundation for success. Localized ridge defects pose a major problem in both esthetics and function of a prosthesis (*Gasparini 2004*).

There is a high incidence of residual ridge deformity following anterior tooth loss. The ridge deformity is directly related with the volume of the root structure and associated bone that is missing or has been destroyed. Localized alveolar ridge defect refers to the volumetric deficit of the limited extent of the bone and soft tissue within the alveolar process (*Gasparini 2004*).

The loss of teeth alters the form of the

alveolar crest in 91% of cases. Alveolar ridge width decreases by 50% in the first year after a tooth extraction. As extraction sites heal, the largest change occurs on the labial and coronal aspects of the alveolar ridge, bringing with it a loss in both horizontal and vertical ridge dimensions. Any change in the alveolar hard and soft tissue ridge profile is undesirable functionally and esthetically (*Grunder et al. 1996*).

The goals of soft tissue augmentation surrounding implants is to create adequate zone of attached non-mobile tissues with intimate adaptation to emerging implant structure and reconstructing soft tissue architecture (*Palacc & Nowzari 2000*). Minimum 3 mm of peri-implant mucosa, referred to as the biologic width, is required for a stable epithelial connective tissue attachment to form as a protective mechanism for the underlying bone (*Dhir 2012*).

Grafting tissues and materials available for soft tissue augmentation can be classified broadly as autologous or synthetic. The ideal material should match the surrounding tissue in texture, pliability, color, be inert with respect to the patient's own tissues. These materials are either surgically implanted or injected (*Anthony et al. 2000*).

The classic procedures using autogenous soft tissue materials can broadly be divided into 3 major groups :- free gingival grafts (FGG), subepithelial connective grafts (SCTG) and various types of roll and pedicle flap (*Breault et al. 2004*). Clinical studies demonstrated various techniques to be successful, resulting in greater flexibility for the choice of the reconstruction material (*Jung et al. 2008*). However, such augmentation techniques do have certain shortcomings, including morbidity and necrosis of the transplanted mucosa. These shortcomings have led to the development and use of alternative augmentation materials Such as: allogeneic, xenogeneic, and synthetic (alloplastic) materials (*Hämmerle & Jung 2008*)

The concept of avoiding the secondary donor surgical site adds great appeal to

materials that represent an alternative to autogenous donor sites for soft tissue grafting. Although these new materials do not surpass the gold standard, they do provide patient satisfaction and esthetics and are available in abundance (*Fu et al. 2012*)

## AIM OF THE STUDY

Volumetric analysis of the use of submucosal palatal island flap for soft tissue ridge augmentation in the maxillary esthetic zone.

Comparison between submucosal palatal island flap and subepithelial connective tissue graft in volumetric amount of soft tissue augmentation, post-surgical pain, patient satisfaction and healing time of both treatment modalities in the maxillary esthetic zone.

## SUBJECTS AND METHODS

### Patient selection

Twenty patients were selected from the outpatient clinic in faculty of dentistry Ain shams university at the department of oral diagnosis, oral medicine and periodontology. The sample size was determined according to statistical power analysis done by statistician.

A comparison was carried between two groups regarding Volume gained post-surgical pain, patient satisfaction and healing time of both treatment modalities in the maxillary esthetic zone.

### Inclusion criteria:-

- Healthy adult patients as evidenced by Burkett's oral medicine health history questionnaire..
- Both genders.
- Age 20-50
- Having one missing tooth in the maxillary esthetic zone
- Patients indicated for prosthetic rehabilitation either by implant or fixed

prosthesis with soft tissue defect.

- Edentulous from at least 3 months.

### Exclusion criteria:

- Smokers.
- Pregnant and breast feeding females.
- Decisionally impaired individuals (mentally retarded, prisoners and handicapped patients)
- Patients with chronic or aggressive periodontitis in the neighboring teeth.

### Malocclusion.

### Patient grouping

20 patients were randomly divided into two groups (each of 10 patients). Group 1 (Study group): received Submucosal palatal island flap ,Group 2 (Control group) received Subepithelial connective tissue graft

### presurgical Preparation

- Full conventional periodontal treatment including supra, sub gingival scaling were performed.
- Teeth were examined for caries, periapical infection and restorative procedure in order to be treated.
- Immediately prior to the surgery, Alginate impression was taken and poured into cast model.

### Surgical procedures:

-Just prior to surgery About 10 ml intravenous blood was obtained from from the patient without anticoagulant and immediately centrifuged at 3000 rpm (approximately 400g) for 10 minutes.

-Coagulation started immediately and 3 parts quickly appear in the tube : a packed red blood cells at the bottom, acellular plasma at top and the PRF clot in between.

-The PRF was gently removed from the tube separating it from the RBC base and compressed between two sterile gauzes moistened with normal saline to get the membranes. (*Dohan et al., 2006*).

-Prior to the surgical procedure for the 2 groups :-

1-Patients were instructed to rinse for 30 sec with 0.2% chlorhexidine gluconate solution.

2-The area subjected to surgery was anesthetized by infiltration anesthesia using local anesthetic solution 4% articaine with 1:100,000 epinephrine\*.

### **Group 1 (Study group):-**

-Using a no.15 scalpel blade, a palatal paracrestal full thickness incision was made in accordance to the length of the edentulous area.

-Another partial thickness incision was made in the palatal mucosa 3 mm apical to the first one and extended anteriorly according to the size of defect .

-Dissection of the mucoperiosteal flap and the underlying preparation of a subepithelial connective tissue graft.

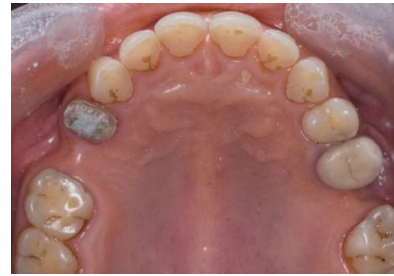- A sharp incision of the subepithelial tissue was then made parallel to the first incision in the same manner to harvest a connective tissue graft, but leaving it attached in the anterior region (*Khoury 2000*).

-The connective tissue was elevated, as in palatal rotational flaps and was passed underneath a full-thickness tissue tunnel that was previously prepared on the palatal side.

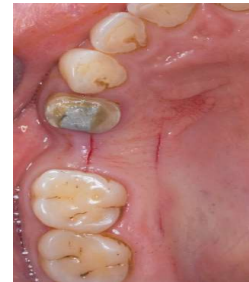-The connective tissue was inserted under the buccal mucosa and sutured with 6/0 polypropylene\*\* without any tension and left for primary healing. Finally, PRF membrane was used to cover the donor site by cross over sutures using 6/0 polypropylene.

\* Artinibsa 40 mg/0.01 mg/ml Inibsa, Spain

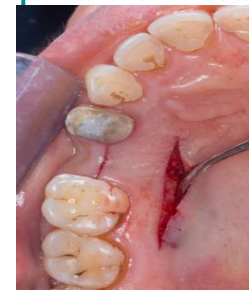\*\* Dtek : polypropylene non-absorbable, monofilament, synthetic surgical suture 5/0 manufactured by Huaiyin china for demophorius Cyprus .



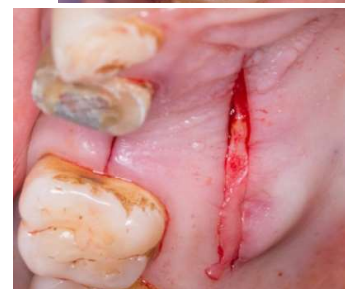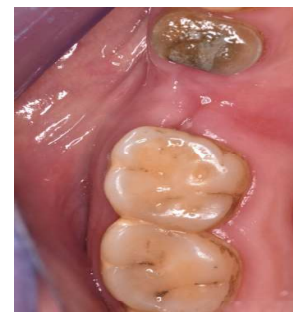**Figure (1): Preoperative occlusal view**



**Figure(2): Crestal incision and Second incision 5 mm palatal to the crestal one**

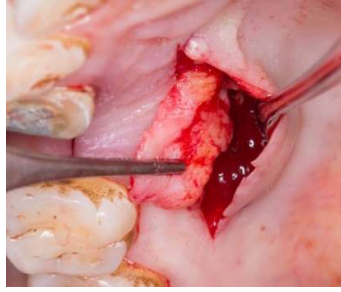


**Figure (3): Sharp incision of the subepithelial tissue**

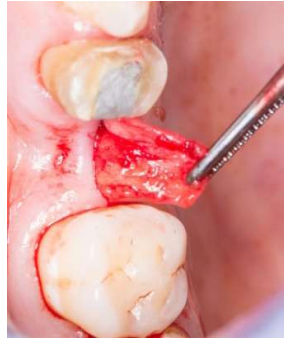

**Figure (4): Harvesting connective tissue graft**

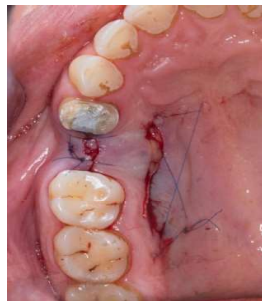




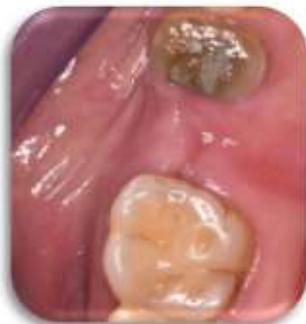**Figure (5): Connective tissue graft**



**Figure (6): The rotated flap was passed underneath a full-thickness tissue tunnel**



**Figure (7): Cross over suture of the palate**



**Figure (8): Site of graft at 2 weeks post-operative**

## Group 2 (Control group):-

### Recipient Site Preparation:-

-A subepithelial pouch was created in the

recipient site using a no.15 scalpel blade.

- Partial thickness incision was done mid crestally extending deep up to the mucogingival junction.

- Subepithelial connective tissue graft harvested from palate was placed in the pouch and flap was sutured coronally using 6/0 polypropylene. Donor site preparation:-

-The connective tissue graft was harvested from the palate using de-epithelialization technique. The length of the graft was in accordance to the length required at the recipient site .

- A rectangular shaped partial thickness incision was made, keeping the periosteum intact.

- The epithelium was then removed from the graft by scrapping.

- The remaining connective tissue harvested was then trimmed and adapted to the recipient site.

- Finally, PRF membrane was used to cover the donor site by cross over sutures using 6/0 polypropylene.

### Post- surgical management:

-Systemic antibiotics was prescribed (amoxicillin+clavulanic acid 1 g every 12 hours for 7 days post-surgically\*) and analgesics (Ibuprofen 600 mg every 12 hours for 3 days post surgically\*\*). 0.2% chlorhexidine gluconate\*\*\* mouth rinse was prescribed (twice a day).

-Sutures were removed after 10 days.

\*Augmentin: Broad spectrum antibiotic, manufactured by medical union pharmaceuticals, "penicillin plant" Abu Sultan, Ismailia, Egypt.

Brufen 600mg manufactured by Hamol limited, Reckitt for Abbott India Laboratories.

Hexitol HCL 125mg/100ml Arab Drug Company for pharmaceutical & chemical industries, Cairo, Egypt.

-Patients were recalled after 10 days, 1 month and 3 months for reevaluation.

-Three months after soft tissue ridge augmentation another alginate impression was taken and poured into cast model , patients were recalled for the prosthetic fabrication.

## CLINICAL ASSESSMENT

### 1-Volumetric measurements:

Cast models were obtained from alginate impressions to be used for comparison of tissue dimensions at baseline and at 3 months postoperative. Casts were optically scanned with a 3D camera (figure11&12). The image analysis system was visualized with a versatile graphic software.. The postoperative cast was superimposed with the already stored preoperative image. as figure (13). The scanned cast images were superimposed and subtracted and soft tissue was determine for any volume changes.

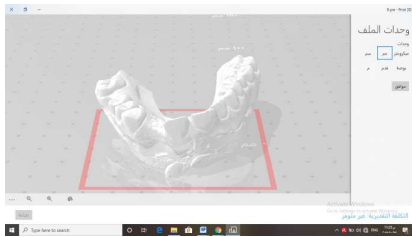


Figure (9): Scanning of pre-operative cast using optically scanned with a 3D camera.

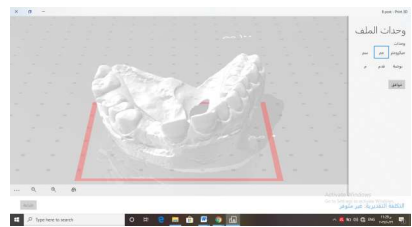


Figure (10): Scanning of post-operative cast using optically scanned with a 3D camera

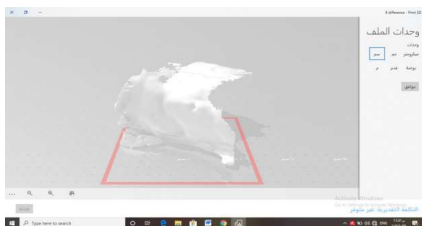


Figure (11): Subtraction of scanned casts

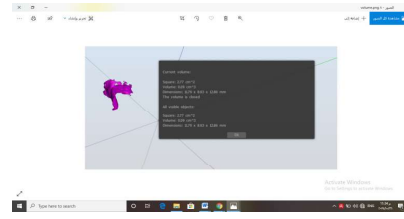


Figure (12): Volume difference between pre and post-operative casts

### 4-Evaluation of post-surgical pain

-According to the American Pain Society guidelines for pain management the most used scale is the Visual Analogue Scale (VAS) grading pain by no pain at 0 level to maximal pain at level 10 (*Williamson et al., 2005*).

- The intensity of pain was evaluated and recorded at intervals of 10 days – 1 month and 3 months post-operative

### 5-Evaluation of patient satisfaction

-The questionnaire was used to determine the level of satisfaction composed of 5 items (surgical time – pain –Discomfort –sequential visits – learning about treatment process) after 10 days from the surgery [*Jae-Mok Lee et al., 2002*].

-Each item was constructed as an opinion statement and was administrated with a 4 point likert formate (strongly agree-agree–disagree–strongly disagree).

### 6-Evaluation of healing time :

-Clinical measurements were taken at three time points (immediately after the surgery – at 10 days – 3 months after surgery).

-The following parameters were used: (*Hagenaar et al., 2004*)

1- Swelling of the soft tissues.

- 2- Color of the gingiva.
- 3- Bleeding index.
- 7- Statistical analysis:

Statistical analysis was performed with IBM® SPSS® Statistics Version 25 for Windows . Numerical data were presented as mean, standard deviation (SD).

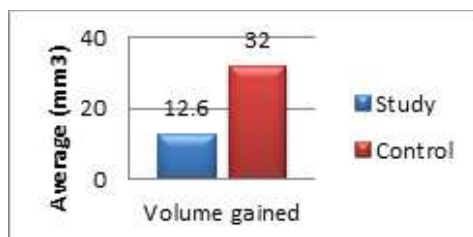
## RESULTS

### 1- Volumetric measurement:

Control group ( $32 \pm 24.74 \text{mm}^3$ ) had a significantly higher mean value of soft tissue volume gained than the study group ( $12.60 \pm 10.71 \text{mm}^3$ ) ( $p=0.035$ ).

**Table (1):** Mean and Standard deviation (SD) values for volume gained in different groups

Volume gained (Mean±SD)		p-value
Study	Control	
$12.60 \pm 10.71 \pm \text{mm}^3$	$32.00 \pm 24.74 \pm \text{mm}^3$	0.035*



**Figure (13):** Bar chart showing average volume gained ( $\text{mm}^3$ )

### 2- Post-surgical pain (VAS):

At 10 days after the surgery the control group ( $8.20 \pm 0.79$ ) had a significantly higher mean value of (VAS) scores than the study group ( $6.70 \pm 0.67$ ) ( $P=0.001$ ).

1 month post-surgical showed that the control group ( $5.90 \pm 0.88$ ) had a significantly higher mean value of (VAS) scores than the study group ( $2.80 \pm 1.14$ ) ( $P=0.001$ ).

\* ® IBM Corporation, NY, USA.

\*\* ®SPSS, Inc., an IBM Company.

After 3 months the control group ( $1.60 \pm 0.52$ ) had a significantly higher mean value of (VAS) scores than the study group ( $0.40 \pm 0.52$ ) ( $P < 0.001$ ).

## 3- Healing time

### A-Gingival swelling score:

At Baseline The control group ( $0.40 \pm 0.52$ ) had a higher mean value of gingival swelling score than the study group ( $0.20 \pm 0.42$ ) yet the difference was not significant ( $P=0.481$ ).

10 days post-surgical The control group ( $0.50 \pm 0.53$ ) had a higher mean value of gingival swelling score than the study group ( $0.20 \pm 0.42$ ) yet the difference was not significant ( $P=0.280$ ).

3 Months post-surgical The control group ( $0.10 \pm 0.32$ ) had a higher mean value of gingival swelling score than the study group ( $0.00 \pm 0.00$ ) yet the difference was not significant ( $P=0.739$ ).

### B-Gingival color score:

At Baseline The control group ( $0.40 \pm 0.52$ ) had a higher mean value of gingival color score than the study group ( $0.30 \pm 0.48$ ) yet the difference was not significant ( $P=0.739$ ).

At 10 days post-operative The control group ( $0.90 \pm 0.74$ ) had a higher mean value of gingival color score than the study group ( $0.60 \pm 0.52$ ) yet the difference was not significant ( $P=0.436$ ).

At 3 Months The control group ( $0.30 \pm 0.48$ ) had a higher mean value of gingival color score than the study group ( $0.10 \pm 0.32$ ) yet the difference was not significant ( $P=0.481$ ).

### C-Bleeding index:

At Baseline Both groups had the same value of bleeding index ( $0.40 \pm 0.52$ ).

At 10 days post-operative the control group ( $1.10 \pm 0.57$ ) had a higher mean value of bleeding index than the study group ( $0.80 \pm 0.42$ ) yet the difference was not significant ( $P=0.353$ ).

3 Months post-operative Both groups had the same value of bleeding index ( $0.60 \pm 0.52$ ).

### 4- Correlation between healing index and

post-surgical pain:

There was no significant correlation between healing index and post-surgical pain in both study and control

group ( $r_s = -0.163, p = 0.390$ ).

### 5- Patient satisfaction

Figure (14): Bar chart showing percentage of answers to the patient satisfaction questionnaire

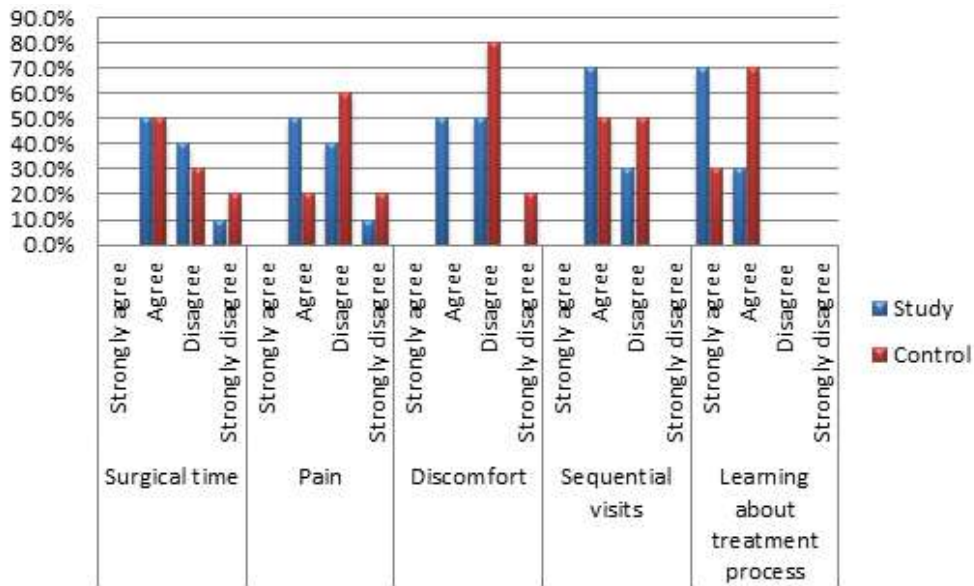


Figure (14): Bar chart showing percentage of answers to the patient satisfaction questionnaire

## DISCUSSION

Partially edentulous patients frequently have localized alveolar defects which impair the prosthetic restoration of damaged ridge area causing aesthetic, phonetic and oral hygiene complications ([Cannizzaro & Leone 2003](#)).

Various techniques have been employed to restore the damaged ridge like guided bone regeneration,

bone grafts, bone substitutes, and soft tissue ridge augmentation. Soft tissue ridge augmentation techniques includes the epithelial connective tissue graft, subepithelial connective tissue graft and pedicle graft technique ([Deepak&Gurpreet2014](#)).

This study was designed as a randomized, controlled clinical trial to compare 2 soft tissue augmentation surgeries used to alter contours of alveolar ridge by quantifying dimensional volume changes before the surgery and 3 months after surgery.

Also it compare post-surgical pain, patient satisfaction and healing time of both treatment modalities in the maxillary esthetic zone. Twenty patients with one missing tooth in the maxillary esthetic zone were included in the study. The patients were divided into 2 equal groups ; Group 1 (Study group ) who received submucosal palatal island flap and Group 2 (Control group) who received subepithelial connective tissue graft

The results demonstrated that both groups showed significant increase in soft tissue volume. Control



group ( $32.00 \pm 24.74 \text{ mm}^3$ ) had a significantly higher mean value of soft tissue volume gained than the study group ( $12.60 \pm 10.71 \text{ mm}^3$ ). A comparative study was conducted by **Studer et al.** to compare 2 soft tissue augmentation surgeries (free full-thickness gingival graft and a subepithelial connective tissue graft) at 1 and 3.5 months after surgery. The mean volumetric gain for the CT graft group was significantly greater than that of the FG graft group at 1 month ( $187 \text{ mm}^3$  vs  $117 \text{ mm}^3$ ). It may be due to improved nutrition of the grafted connective tissue in the recipient site during the critical first week of healing in comparison to the FG graft (**Studer et al. 2000**).

Case series presents a novel pedicle CT technique by incorporating a palatal tunnel through which the pedicle is channeled to the recipient site. The clinical observation in the case series reveals significant gains in soft-tissue height and volume of treated sites. Tunnel modification contributes to the vascular supply of the pedicle, whereas the overlying palatal mucosa stabilizes the graft in the desired position over the defect site. (**Alain et al. 2013**).

Regarding VAS of our study, there was a significant difference in the (VAS) scores found in different follow up intervals in study group ( $p < 0.001$ ). Value recorded after 10 days ( $6.70 \pm 0.67$ ) showed the highest mean value followed by 1 month ( $2.80 \pm 1.14$ ) while the lowest value was found after 3 months ( $0.40 \pm 0.52$ ). The control group has a significant difference in the (VAS) scores found in different follow up intervals ( $p < 0.001$ ). Value recorded after 10 days ( $8.20 \pm 0.79$ ) showed the highest mean value followed by 1 month ( $5.90 \pm 0.88$ ) while the lowest value was found after 3 months ( $1.60 \pm 0.52$ ). Intergroup comparison showing that at 10 days post-operative The control group ( $8.20 \pm 0.79$ ) had a significantly higher mean value of (VAS) scores than the study group ( $6.70 \pm 0.67$ ). Assessment of pain 1 month post-operative showing that The control group ( $5.90 \pm 0.88$ ) had a significantly higher mean value of (VAS) scores than the study group ( $2.80 \pm 1.14$ ). At 3 month post-operative, The control group

( $1.60 \pm 0.52$ ) had a significantly higher mean value of (VAS) scores than the study group ( $0.40 \pm 0.52$ ).

**Pandit et al.** conducted a study to compare two techniques of harvesting connective tissue (unigraft knife method & Langer and Langer technique) and their effects on healing pattern include the measurement of postoperative pain at day of surgery, 1st, 4th, and 12th week postoperatively. Patients in both the groups exhibited pain at 1 week follow up which was higher in Group I (unigraft knife group) than Group II (Langer and Langer trap door technique), but it was statistically not significant. Post-operative pain was also assessed as per the number of NSAID pills taken by the patients in both the groups. It was found to be similar at 1 week postoperative interval, and no analgesic pill intake was reported by any patient at 4 and 12 weeks follow-up intervals. When all the parameters of the post-operative pain, i.e. VAS and NSAIDs pills taken were analyzed collectively, the amount of pain reported at 1 week in both the groups was significantly higher than at subsequent time intervals (**Pandit et al. 2019**).

Regarding gingival swelling score immediately after the surgery the control group ( $0.40 \pm 0.52$ ) had a higher mean value of gingival swelling score than the study group ( $0.20 \pm 0.42$ ) yet the difference was not significant. The control group ( $0.50 \pm 0.53$ ) had a higher mean value of gingival swelling score than the study group ( $0.20 \pm 0.42$ ) at 10 days post-operative yet the difference was not significant. At 3 months after the surgery the control group ( $0.10 \pm 0.32$ ) had a higher mean value of gingival swelling score than the study group yet the difference was not significant.

Bleeding index of the Study group showing no significant difference in the values of bleeding index found in different follow up intervals. The highest mean value was found after 10 days ( $0.80 \pm 0.42$ ) followed by 3 months ( $0.60 \pm 0.52$ ) while the lowest value was found at baseline ( $0.40 \pm 0.52$ ). In the Control group there was a significant difference in the values of bleeding index found in different follow up

intervals. The highest mean value was found after 10 days ( $1.10 \pm 0.57$ ) followed by 3 months ( $0.60 \pm 0.52$ ) while the lowest value was found at baseline ( $0.40 \pm 0.52$ ). Pairwise comparisons showed value found after 10 days to be significantly higher than the value found at baseline .

## CONCLUSIONS

It may be concluded that both soft tissue augmentation techniques were effective in increasing the volume of defective alveolar ridges in single tooth gaps in the anterior maxilla. The quantitative volumetric assessment on the buccal and crestal aspects of a single tooth pontic space revealed a significantly greater volume gain with the subepithelial connective tissue graft in comparison to the submucosal palatal island flap 3 months after surgery. However, Submucosal palatal island flap is less painful, with less gingival swelling score and gingival color score than sub epithelial connective tissue graft.

## REFERENCES

- Alain H. Romanos, Nicolaas C. Geurs and Ramzi V. Pedicle Connective Tissue Graft With Novel Palatal Tunneling. *clin Adv Periodontics* 2013;3:191-
- Anthony P. Sclafani, Thomas Romo III, Andrew A. Jacono, Steven McCormick, Rubina Cocker, Andrew Parker. Evaluation of Acellular Dermal Graft in Sheet (AlloDerm) and Injectable (Micronized AlloDerm) Forms for Soft Tissue Augmentation Clinical Observations and Histological Analysis. *Arch Facial Plast Surg.* 2000;2:130-136.
- Breault, L. G., Lee, S. Y., Mitchell, N. E. Fixed prosthetics with a connective tissue and alloplastic bone graft ridge augmentation: a case report. *J Contemp Dent Pract* 2004;5, 121–111
- Deepak Grover & Gurpreet Kaur. Soft tissue ridge augmentation using “roll technique” – A case report. *IAIM*, 2014; 1(4): 80-85.
- Dhir S. Significance and clinical relevance of biologic width to implant dentistry. *J Interdiscip Dent* 2012;2:84-91
- Dohan DM, Choukroun J, Diss A, Dohan SL, Dohan AJ, Mouhyi J, Gogly B. Platelet-rich fibrin (PRF): a second-generation platelet concentrate. Part II: platelet-related biologic features. *Oral Surgery, Oral Medicine, Oral Pathology, Oral Radiology, and Endodontology.* 2006 Mar 31; 101(3):e45-50.
- Fu JH, Su CY, Wang HL. Esthetic soft tissue management for teeth and implants. *J Evid Based Dent Pract* 2012;12(3 Suppl):129–42.
- Gasparini. Double-fold connective tissue pedicle graft: A novel approach for ridge augmentation. *J Periodontics Restorative Dent* 2004;24:280-7.
- Hagenaaers S, Louwense PHG, Timmerman MF, Van der Velden U, Van der Weijden GA: Soft-tissue wound healing following periodontal surgery and Emdogain application. *J Clin Periodontol* 2004; 31: 850–856.
- Hämmerle CHF, Jung RE. Ridge augmentation procedures. In: Lindhe J, Lang NP, Karring T, eds. *Clinical Periodontology and Implant Dentistry*. 5th ed. Oxford, United Kingdom: Blackwell; 2008:1089.
- Jae-Mok Lee ,keun Bae Song ,Hee Yong Sohn ,Seong Hwa Jeong ,and Ho Kwen .comparison between patient expectation before and satisfaction after periodontal surgical treatment.*J Clin periodontol sep.* 2002.
- [Jung RE](#), [Holderegger C](#), [Sailer J](#), [Khraisat A](#), [Suter A](#), [Hämmerle CH](#). The effect of all-ceramic and porcelain-fused-to-metal restorations on marginal peri-implant soft tissue color: a randomized controlled clinical trial. [Int J Periodontics Restorative Dent.](#) 2008 Aug;28(4):357-65.

- Palacci P, Nowzari H., Soft tissue enhancement around dental implants. *Periodontology* 2000, 47, 2008, 113–132

- Williamson A, Hoggart B. Pain: a review of three commonly used pain rating scales. *J Clin Nurs* 2005;14(7):798–804 198.

- [Cannizzaro G](#), [Leone M](#). Restoration of partially edentulous patients using dental implants with a microtextured surface: a prospective comparison of delayed and immediate full occlusal loading. [Int J Oral Maxillofac Implants](#). 2003 Jul-Aug;22-512:(4)18.

effects on healing pattern at palate and recession coverage at recipient site. *Contemp Clin Dent* 2016;7:3-10.

- Grunder U, Spielman HP, Gaberthul T. Implant –supported single tooth replacement in the aesthetic region : A complex challenge. *Pract periodontics Aesthet Dent* 1996;8:835-842

- Pandit N, Khasa M, Gugnani S, Malik R, Bali D. Comparison of two techniques of harvesting connective tissue and its effects on healing pattern at palate and recession coverage at recipient site. *Contemp Clin Dent* 2016;7:3-10.

- Studer, S. P., Lehner, C., Bucher, A., & Schärer, P. Soft tissue correction of a single-tooth pontic space: A comparative quantitative volume assessment. *Int J Periodontics Res Restorative Dent*, 2000; 83(4), 402–411.

