

A rare case of two compound odontomes preventing both maxillary permanent central incisors from erupting: A Case report

Wael A. Hussein, Dina Y. Fouad** and Tamer A. Nasr****

Abstract

Impaction of both central incisors is considered a rare situation. From amongst the many reasons for this condition, the presence of odontomes is commonly found to cause this situation. The odontomes are the most common odontogenic tumor, with its compound subtype usually present in the anterior region and the complex subtype in the posterior region. A case is presented whereby 2 central incisors in a 8-year-old male patient were impacted due to the presence of 2 compound odontomes.

Keywords: Odontome, Impacted Central Incisor, odontogenic tumor

Introduction

Impaction of maxillary central incisors is not a frequently occurring case, and its management is challenging. The prevalence of such impaction has been reported to be 0.13%¹ to 2.6%.² The cause of maxillary central incisor impaction can be classified in either hereditary or environmental.³ Hereditary factors includes genetic factors⁴, cleft lip and palate, supernumerary teeth, cleidocranial dysostosis, odontomes, generalized retarded eruption and gingival fibromatosis.⁵ While environmental factors include trauma, early loss of deciduous teeth, cyst formation, endocrinal deficiencies and bone disease.⁶

The term odontoma was first used by Paul Broca in 1867. Odontomes are defined by the World Health Organization as "benign odontogenic tumor composed of odontogenic epithelium and odontogenic ectomesenchyme with dental hard tissue formation"⁸ Nowadays, it is rather considered a hamartomatous malformation than a benign tumour.⁹ Odontomes were subclassified according to their origin,

* Department of Oral & Maxillofacial Surgery, Misr International University

** Department of Oral & Maxillofacial Surgery, Misr International University

*** Associate Professor – Department of Oral & Maxillofacial Surgery, Misr International University

clinical presentation and location and appearance. Worth classified them according to their origin into ectodermal, mesodermal and mixed ectodermal and mesodermal.¹⁰ While according their clinical presentation and location, they were further classified into central (present inside bone), peripheral (present in soft tissue covering teeth) and erupted odontomes.¹¹

Odontomes are asymptomatic lesions present in children or young adults, usually discovered accidentally during routine radiography.¹² Odontomes are the most common odontogenic tumour in the oral cavity with 67% incidence in the maxilla. With Complex odontomes less common than the compound subtype with a ratio of 1:2. Complex odontomes are more common in the posterior region while compound odontomes in the anterior region.⁹

The management of impacted teeth with odontomes hindering their eruption varies according to several factors which include unfavorable impacted tooth root formation, severe intrusion, infection or avulsion of impacted permanent tooth. The management could include but are not limited to surgical removal of odontoma and impacted permanent tooth, removal of odontoma with salvation of impacted permanent tooth to give a chance for eruption – as obstruction is removed, or orthodontical traction of impacted permanent tooth.⁶ The recurrence of odontomes are extremely rare and prognosis is usually very favorable following their excision.¹³

Case Report

A 8-year old male patient was presented to Misr International University Dental Clinic Complex with a chief complain of social problems and poor esthetics due to missing of anterior teeth. The patient was examined thoroughly with history showing no apparent medical conditions, no obvious familial history of any disturbances and no extraoral or intraoral anomalies. Radiographic examination using periapical radiographs showed 2 masses occlusal to both impacted central incisors and the patient was referred to radiological

assessment. 3-D Cone- beam Computed Tomography (CBCT) was done and showed two tooth-like masses palatal to the two maxillary permanent incisors as shown in [Figure 1-4].

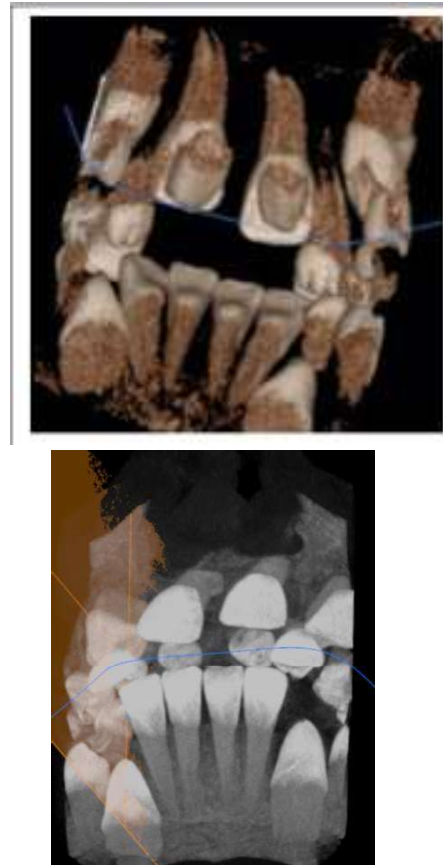

Figure 1: 3D reconstruction CBCT - showing 2 tooth-like masses palatal to both central incisors

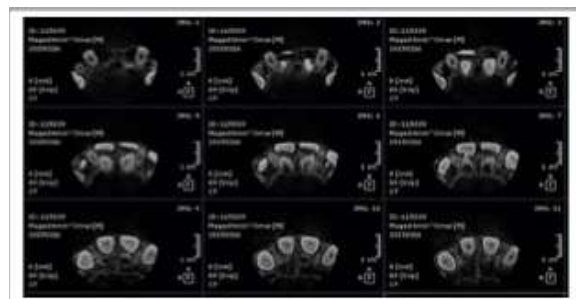


Figure 2: Cross Section View of CBCT - showing 2 odontomes palatal to both maxillary central incisors

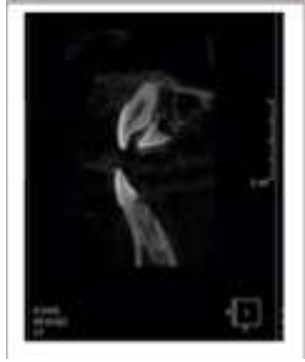

Figure 3: Axial View - showing Right Central incisor and palatal odontome.

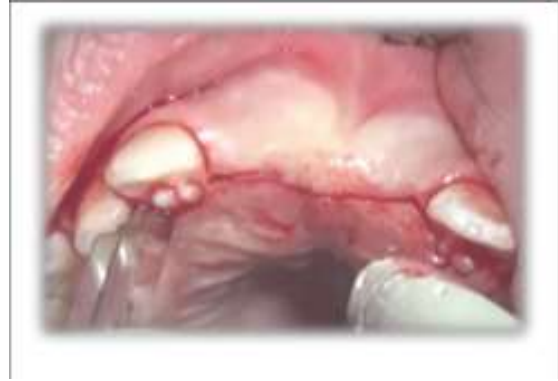

Figure 5: Intraoral photography showing crestal incision from canine to canine

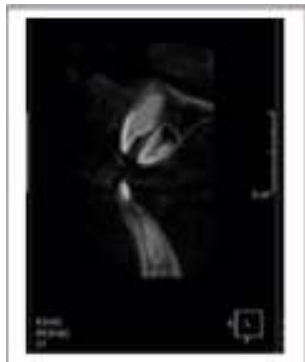

Figure 4: Axial View - showing Left Central incisor and palatal odontome.

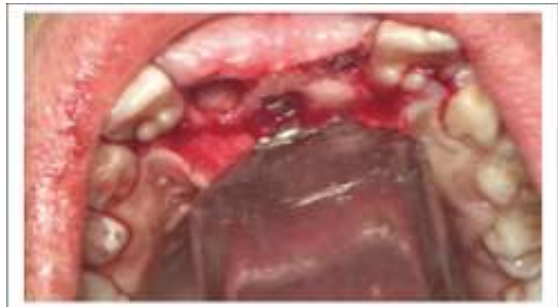

Figure 6: Intraoral photography showing refelected palatal flap, with odontomes visible.

After assessment of CBCT and consultations with orthodontic department team, it was concluded that both odontomes would be surgically excised to allow both permanent central incisors to erupt. Follow up period was set for 18 months, after which orthodontic traction would be done if both failed to erupt. The surgical procedure included an infiltration of 4% Articaine both buccally and palatally, crestal incision from the canine to the canine of the opposite side [Figure 5] with the subsequent reflection of a palatal flap [Figure 6]. No buccal flap was raised to preserve the integrity of the follicles of both impacted central incisors.

Both odontomes are then removed using a straight apexo elevator [Figure 7] and flap is repositioned in place again and sutured using 3-0 silk suture in interrupted fashion [Figure 8].

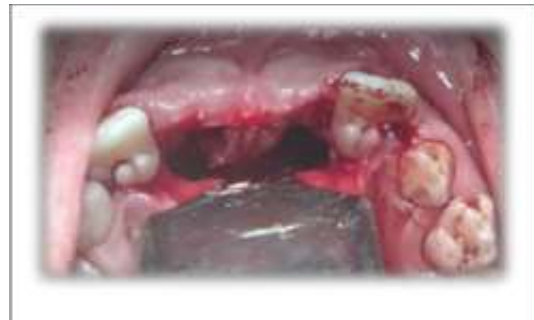

Figure 7: Intraoral photography showing surgical site following removal of both odontomes.

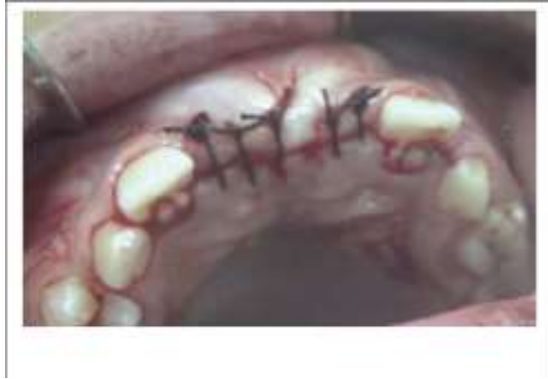

Figure 8: Intraoral photography showing flap repositioned in place and sutured.

A palatal stent was then placed to reduce hematoma and stabilize the palatal flap [Figure 9]. Both surgically removed odontomes were sent for histopathological examination [Figure 10]. Histopathological examination concluded that both lesions were compound odontomes.

Follow up radiographs were done on 6 months, 12 months and 18 months interval postoperatively and showed significant movement of both central incisors incisally. The Right Central Incisor erupted at 12 months as shown in [Figure 11-12] and radiographic examination showed significant movement of left central incisor too [Figure 13].

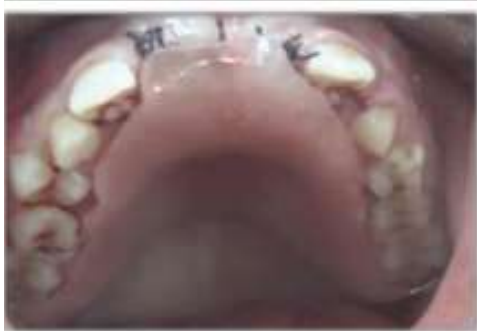

Figure 9: Intraoral photography showing palatal stent secured in position.

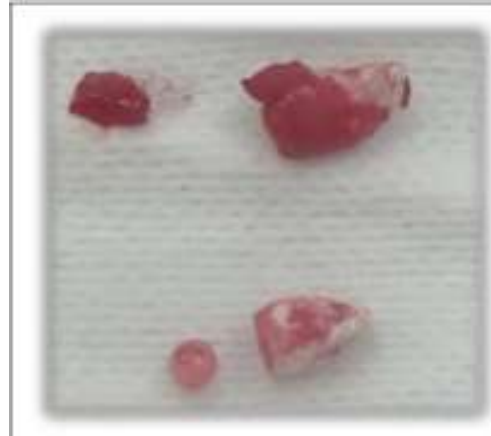


Figure 10: Surgically excised Odontomes

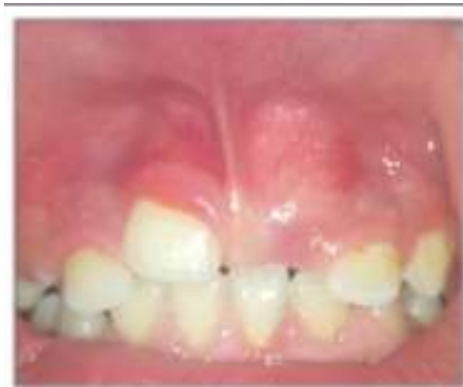

Figure 11: Intraoral Frontal View showing eruption of Right central incisor and bulge of Left Central Incisor at 12 months postoperative.

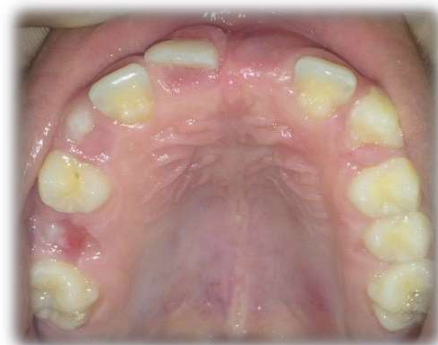

Figure 12: Intraoral Occlusal View showing eruption of Right central incisor and bulge of Left Central Incisor at 12 months postoperative.

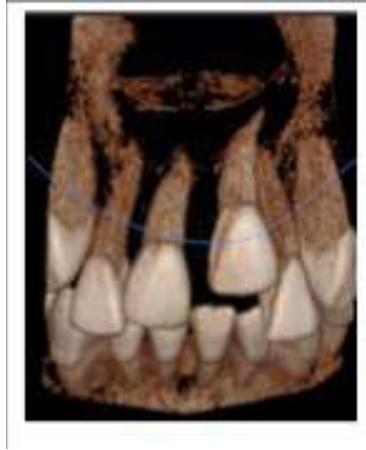

Figure 13: 3D reconstruction CBCT showing significant eruption of both central incisors after 12 months postoperatively.

After 18 months postoperative the left central incisor failed to erupt as seen in intraoral frontal and occlusal photographs [Figure 14-15] and therefore after consultation with orthodontic department team surgical exposure was done [Figure 16-17].

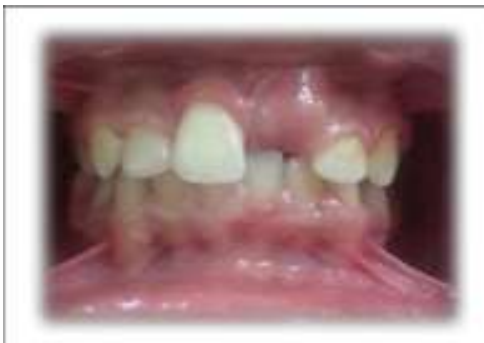

Figure 14: Intraoral Frontal View at 18 months postoperative showing failure of left central incisor to erupt and complete eruption of Right central incisor.

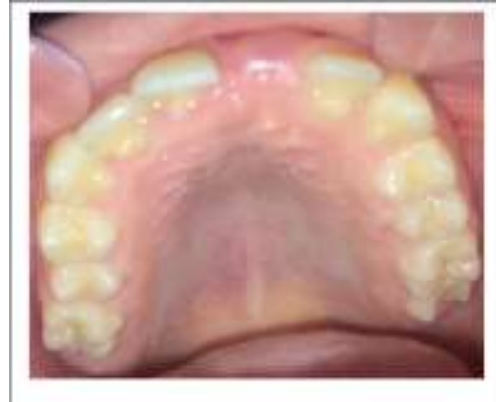

Figure 15: Intraoral Occlusal View at 18 months postoperative showing failure of left central incisor to erupt and complete eruption of Right central incisor.

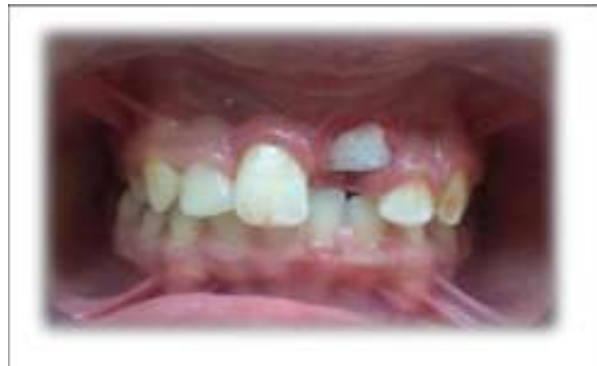

Figure 16: Intraoral Frontal View showing surgical exposure of Left central Incisor.

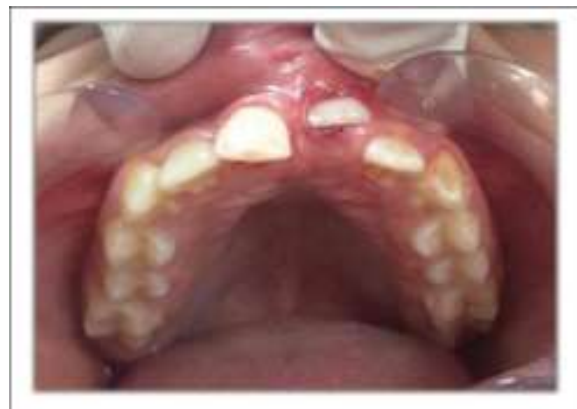

Figure 17: Intraoral Occlusal View showing surgical exposure of Left central Incisor.

Both central incisors were erupted by the 24 months postoperative and no recurrence was observed. Patient confirmed their eruption but failed to show up for further follow up.

Discussion

Odontomes are a hamartomatous condition and is considered the most common odontogenic neoplasm of the oral cavity. They are usually diagnosed during routine radiographic examination of the jaws. Although they are usually asymptomatic, they may cause pain, swelling, paresthesia, root resorption, bone expansion and teeth displacement.¹⁴ Odontomes can also hinder the eruption of permanent teeth.¹⁵ Therefore management of such cases should be well coordinated between the oral surgeon and orthodontist to utilize all possible treatment options in the benefit of the patient. Early diagnosis and management are key factors in salvaging the permanent teeth. Radiologically findings may be variable depending on amount of enamel and dentin in the lesion, which in early stages the lesion may appear radiolucent complicating the diagnosis. Differential diagnosis must be established to exclude both ameloblastic fibromatoma, ameloblastic fibroma,⁷ Gardner syndrome, Hermann syndrome and basal cell nevus syndrome.¹²

Surgical enucleation is the treatment of choice for odontomes.¹⁶ Histologically, odontomas are composed of varying amounts of enamel, pulp tissue, enamel organ and cementum. The rate of recurrence is extremely low, therefore prognosis is usually very favorable.¹⁷

Conclusion

The early diagnosis and management of impacted central incisors hindered by compound odontomes is crucial in preserving the teeth. Orthodontic consultation is also necessary to reach the most esthetic and functional outcome for the patient. Odontomes removed by surgical excision have very favorable prognosis and rare cases of recurrence is mentioned in the literature.

References:

1. Mac Phee CG. The incidence of erupted supernumerary teeth in consecutive series of 4000 school children. *Br Dent J* 1935; 58: 59–60.
2. Di Biase DD. Midline supernumeraries and eruption of maxillary central incisors. *Transactions of the BSSO* 1968–1969; 83–88.
3. Hitchen AD. The impacted maxillary incisor. *Dent Pract Dent Rec* 1970; 20: 423–33.
4. Peck S, Peck L, Kataja M. Concomitant occurrence of canine malposition and tooth agenesis: Evidence of orofacial genetic fields. *Am J Orthod Dentofacial Orthop.* 2002; 122(6):657-60. <https://doi.org/10.1067/mod.2002.129915PMid:12490878>
5. Bishara SE. Impacted maxillary canines: a review. *Am J Orthod Dentofacial Orthop.* 1992; 101(2):159-71. [https://doi.org/10.1016/0889-5406\(92\)70008-X](https://doi.org/10.1016/0889-5406(92)70008-X)
6. O. Yaqoob, J. O'Neill, T. Gregg, J. Noar, M. Cobourne, and D. Morris, "Management of unerupted maxillary incisors," 2010, <https://www.rcseng.ac.uk/dental-faculties/fds/publications-guidelines/clinical-Guidelines/>.
7. Shafer WG, Hine MK, Levy BM. Cysts and tumours of the jaws. In: Shafer WG, Hine MK, Levy BM, Tomich CE, editors. *A Textbook of Oral Pathology*. 4th ed. Philadelphia: WB Saunders Company; 1997. pp. 308–11.
8. Praetorius F, Piatelli A. Odontoma. In: Barnes L, Eveson JW, Reichart P, Sidransky D, editors. *WHO Classification of Tumours. Pathology and Genetics: Head and Neck Tumours*. 5th ed. Lyon: IARC Press; 2005. p. 310. [Google Scholar]
9. Baldawa RS, KhanteKC, Kalburge JV, Kasat VO. Orthodontic management of an impacted maxillary incisor due to odontoma. *Contemp Clin Dent.* 2011;2(1):37- 40.<https://doi.org/10.4103/0976-237X.79312> PMID:22114453 PMCID:PMC3220174

10. Worth HM. Principles and practice of oral radiologic interpretation. 2nd ed. Chicago: Year Book Medical Publishers, Incorporated; 1963.

11. Junquera L, de Vicente JC, Roig P, Olay S, Rodriguez-Recio O. Intraosseous odontoma erupted into the oral cavity: an unusual pathology. *Med Oral Patol Oral Cir Bucal*. 2005; 10(3):248-51. PMID:15876969

12. Soluk Tekkesin M, Pehlivan S, Olgac V, Aksakalli N, Alatli C. Clinical and histopathological investigation of odontomas: Review of the literature and presentation of 160 cases. *J Oral Maxillofac Surg*. 2012;70:1358–61.

13. White SC, Pharoah MJ. Benign tumours of the jaws. In: White SC, Pharoah MJ, editors. *Oral Radiology: Principles and Interpretation*. 5th ed. Missouri: Mosby; 2004. pp. 424–8.

14. de Oliveira BH, Campos V, Marçal S. Compound odontoma-Diagnosis and treatment: Three case reports. *Pediatr Dent*. 2001;23:151–7.

15. Hidalgo-Sánchez O, Leco-Berrocal MI, Martínez-González JM. Meta-analysis of the epidemiology and clinical manifestations of odontomas. *Med Oral Patol Oral Cir Bucal*. 2008;13:E730–4.

16. Kaban LB, Troulis MJ. Dentoalveolar surgery. In: Kaban LB, Troulis MJ, editors. *Pediatric Oral and Maxillofacial Surgery*. Philadelphia: Saunders; 2004. p. 140.

17. Kamakura S, Matsui K, Katou F, Shirai N, Kochi S, Motegi K. Surgical and orthodontic management of compound odontoma without removal of the impacted permanent tooth. *Oral Surg Oral Med Oral Pathol Oral Radiol Endod*. 2002;94:540–2.

