

Clinical and radiographic evaluation of alveolar bone changes following ridge preservation with two different biomaterials

*Elsayed A.E. Ahmed**, *Mansour M. Hussien*** and *Atef M. Hasanneen****

Abstract

Objectives: To evaluate the clinical and radiographic alveolar bone changes following ridge preservation with two different alloplasts, biphasic calcium phosphate (BCP) & tricalcium phosphate (TCP). **Methods:** Randomized, clinical trial was done on 20 patients for alveolar ridge preservation after tooth extraction, and divided into 2 groups according to graft material. Group I, 10 patients and their sockets were filled by (β -TCP) and covered with collagen membrane barrier. Whereas the group II, 10 patients and their sockets were filled by (BCP) and covered with collagen membrane barrier. Standardized periapical radiography were taken for both groups at 4 different times, baseline time directly after tooth extraction (BL), after filling the dental socket by grafting material (GR), after 4 months from grafting (4M) and after 6 months from grafting (6M), to measure alveolar height changes at these different times. Cone beam computed tomography had been done for every patient at 2 different times for measuring bone density, after filling the dental socket by grafting material (GR), after 6 months from grafting (6M). **Results:** In the TCP as well as BCP the changes in mesial height (Mh) and distal height (Dh), representing possible radiographic hard tissue loss at the mesial and distal site. It was found that the BCP had an increase in bone density measurements than the TCP. **Conclusion:** Both groups presented similar radiographic alveolar bone changes for alveolar ridge preservation; however BCP seems to give good results at increased bone density than TCP after 6M from grafting.

* BDS, 2005, Faculty of Dentistry, Mansoura University, Dentist at Ministry of Health.

** Professor, Department of Oral and Maxillofacial Surgery Faculty of Dental Medicine, Boys, Cairo, Al-Azhar University.

*** Lecturer, Department of Oral and Maxillofacial Surgery Faculty of Dental Medicine, Boys, Cairo, Al-Azhar University.

Introduction

Periodontal disease, periapical pathology and mechanical trauma often result in bone loss prior to tooth removal⁽¹⁾. Furthermore, traumatic extraction has also been associated with additional loss of bone. In the healing phase after extraction, alveolar bone undergoes additional atrophy as a result of the natural remodeling process^(2,3). It has been suggested that if the alveolar ridge is not preserved at the time of tooth extraction or tooth loss, alveolar ridge height and width may be lost^(3,4). Preserving the alveolar ridge at the time of tooth extraction helps to minimize difficulties during subsequent implant placement⁽²⁾.

A variety of materials are available for post-extraction ridge preservation. Autografts are biocompatible and have the potential to form new bone through osteogenesis, osteoinduction, and osteoconduction^(5,6). However, autogenous bone grafts present several disadvantages, such as a limited amount of material, donor site morbidity, unpredictable bone quality, and post-operative discomfort⁽⁷⁾. Several types of bone substitutes are commercially available, including allografts, xenografts, and alloplasts^(5,6,8). Bone substitutes ideally should be able to form new bone and be biocompatible, completely resorbable, non-antigenic, non-carcinogenic, inexpensive, and pose no risk of disease transmission.

An alternative to the golden standard - autogenous bone graft - is biphasic calcium phosphate (BCP) containing hydroxyapatite (HA) and β -tricalcium phosphate (β -TCP). Recently BCP is used as bone substitute material for dental and orthopedic applications. The chemical composition of BCP resembles the inorganic part of the natural bone matrix⁽⁹⁾.

Guided bone regeneration (GBR), is a method which originates from guided tissue regeneration (GTR), and is based on a concept of separating bone from soft tissue, which favors proliferation of regeneration-potent cells and their differentiation in the desired tissue type⁽¹⁰⁾.

Therefore the current study was to evaluate

the effect of Bi phasic calcium phosphate (75 % HA & 25 % β -TCP) that could be of a significant role in alveolar ridge preservation than β -Tri calcium phosphate.

Patients and Methods:

Study Population: Twenty patients were participated in this study. They were selected from those attending outpatient clinic Of Oral and Maxillofacial Surgery Department; faculty of Dental Medicine, Al-Azhar University, Boys, Cairo, and the age was ranged from 18-35 years. They were complaining of badly broken unrestorable teeth, all patients had a treatment plan for extraction of these teeth.

Study design: Randomized, clinical trial.

Inclusion criteria: Adult patients were selected according to the following criteria, patients with non-restorable hopeless single rooted teeth or remaining roots indicated for extraction, in maxilla having at least one neighboring tooth.

Exclusion criteria: Patients having debilitating uncontrolled systemic diseases, presence of acute infection, and heavy smokers.

Patient Grouping: The patients were divided randomly according to grafting material into 2 groups

Group I: 10 patients with 10 hopeless single rooted teeth indicated for extraction, sockets preservation were done using (adbone®TCP 99,9% TCP Italy) and Atelo-Collagen Type I Membrane Hypro-Sorb® F 15×20 mm bilayer bioresorbable barrier. Germany

Group II: 10 patients with 10 hopeless single rooted teeth indicated for extraction, sockets preservation were done using (adbone® BCP Italy) Composition: 75% Hydroxyapatite;25% β -TCP and Atelo-Collagen Type I Membrane Hypro-Sorb® F 15×20 mm bilayer bioresorbable barrier. Germany

Pre-operative evaluation: All patients were prepared for surgery by the following

1.Clinical examination: All the patients

were subjected to a complete history taking, including: name, age, gender, occupation, residency, chief complaint, general condition, life style, socioeconomic background, medical and dental history.

2. Radiographic Examination: Panoramic radiography was done preoperatively for every patient to give general view about periodontal and alveolar bone status, and to exclude any pathosis.

Surgical Procedures: All Surgical Procedures carried out under strict aseptic condition. By means of intracrevicular incisions under local anaesthesia**** Artinibsa articaine hydrochloride 4%. Minimally extended to the neighbouring teeth, a full-thickness mucoperiosteal flap was elevated 3–4 mm from the buccal/lingual bone crest in the area of the tooth to be extracted. No vertical releasing incisions were used and an effort was made to preserve the interproximal papillae. The tooth that was badly decayed and non-restorable a traumatically extracted by means of periostomes, attempting to preserve the surrounding osseous walls as much as possible.

Group I: The (β -TCP) was mixed with aspirated 2ml of autologous patient blood (was taken from median cubital vein) in sterilized small glass dish, then injected in extraction socket by bone curette. Then the membrane was added and the flap replaced to its original site. Suturing done by absorbable suture***** **Group II:** The (BCP) was mixed with aspirated 2ml of autologous patient blood (was taken from median cubital vein) in sterilized small glass dish, then injected in extraction socket by bone curette. Then the collagen membrane was added and the flap replaced to its original site. Suturing done by absorbable suture.

**** ARTINIBSA 40 mg/0.01 mg/ml ,composition per cartridge 1.8 ml: Articaine hydrochloride 72 mg, Epinephrine 0.018 mg (equivalent to 0.0324 mg of epinephrine bitartrate) Excipients: sodium chloride, sodium metabisulphite, hydrochloride acid and water for injections, Laboratorios Inibsa, S.A. Made in Spain

***** Pegesorb polyglycolic acid(PGA) ,20mm, 3/8 cutting, 90 cm violet, 3/0, Dogsan Tibbi Malzema San, A S, Rize Cad. No: 151, Trabzon, Turkey

Post-Operative Instructions: All the patients asked to bite on gauze and rinsed with 0.2%chlorhexidine–digluconatemouthwash***** from the second day for the first two post-operative weeks, wound healing assessment together with oral hygiene had been followed up by the same investigator regularly after surgery

Medications: Systemic antibiotics (Amoxicillin 500mg ***** and Metronidazole 500mg*****) had been administered three times per day for the first post-operative week and Paracetamol 500mg***** had been prescribed upon patient discretion for post-operative pain control3 times daily.

Post-operative assessment: Patients were recalled weekly during the first month. Then after 4 months, and at 6 months.

Clinical evaluation: Assessment of soft tissue healing after one week from surgery by wound healing index score.

1. Uneventful healing, without gingival oedema, discomfort.
2. Uneventful healing, with slight gingival oedema, discomfort, erythema.
3. Poor healing, significant gingival oedema, erythema, patient discomfort, flap dehescence.

The healing of post extraction sites of all patients were uneventful and satisfactory by qualitative clinical regular intervals, no signs of infection in or around the wound sites were observed, and the soft tissue healing progressed normally.

***** Orovex delicate mouthwash 250 ml, Thymol + menthol + glycerin + sodium saccharine + sodium monofluorophosphate + chlorhexidine, Macro group pharmaceuticals.

***** AMOXIL Amoxicillin:500mg antibiotic Quantity : 2 boxes (20 Capsules / Boxes) GlaxoSmithKline ***** Flagyl (Metronidazole), SANOFI 500 mg tabs, It is effective against only anaerobic pathogens, but is safe to use in conjunction with many other antibiotics for mixed infections.

***** Paracetamol is an analgesic and antipyretic, 500 mg tab, Each Tablet contains the active ingredient Paracetamol 500mg, GlaxoSmithKline.

Radiographic Evaluation:

Paralleling periapical technique by help of plastic film holder^{*****} and occlusal index silicone bite was done at 4 times after tooth extraction Baseline (BL) after application of alloplastic bone graft (GR), after 4 months (4M) and after 6 months (6M).

Linear radiographic measurements: The distances from the alveolar BC at the mesial (MbhR), central (CbhR) , and distal (DbhR) aspects of the socket to the cementum–enamel junction (CEJ) or restoration margin of the neighboring to the extraction teeth were measured at (BL, GR, 4M and 6M). The periapical x-rays were digitalized by HP Scanjet G3110 Photo Scanner drivers^{*****}, linear measurements were done by DBSWIN 5.7.0^{*****} (fig1).

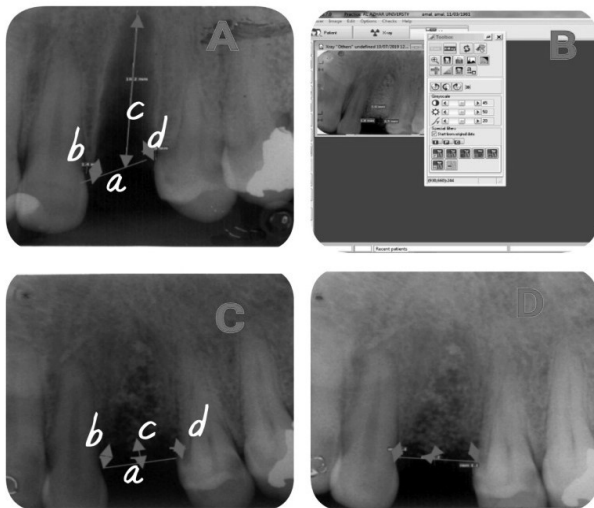


Fig 1: Periapical radiograph showing linear measurements by DBSWIN 5.7.0 software programm at mesial , central, and distal at different time intervals

A) BL B)GR C)4M D)6M

a.Drawing line connecting CEJ of the two neighboring teeth.

b.Mesial height

c.Central height

d.Distal height

Cone beam computerized tomography was done at 2 times after application of alloplast bone graft (GR), after 6 months (6M), to help in measuring differences in bone density between 2 times (fig 2).

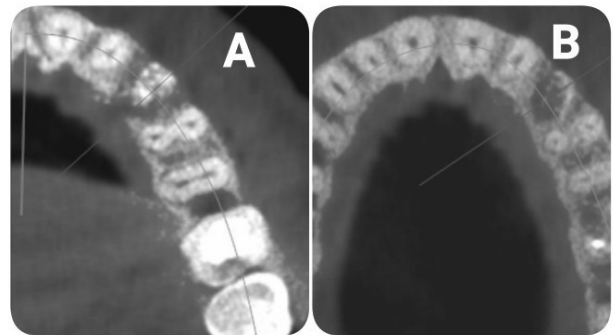


Fig 2: Cross section CBCT showing

A: Bone density at GR

B: Bone density after 6M

Statistical analysis:

Data were fed to the computer and analyzed using IBM SPSS software package version 20.0. **Outcomes:** In regard to changes in mesial heights measurements there was no statistically significant difference between the groups from base line to 6M (Table1).

***** POSICIONADOR CONE, Film Holder from MAQUIRA DENTAL PRODUCTS, Made in BRAZIL .

***** Version: 14.5 Operating systems: Windows 7 (32-bit) Release date: Sep 10, 2015.

***** DBSWIN Imaging Software, Supports Microsoft Windows 7 -32 bit / -64 bit, Microsoft Windows 8 -64 bit, Microsoft Windows 10 -64 bit, Microsoft Windows Server 2012, Microsoft Server 2016.

Table 1: Comparison between the two studied groups according to mesial height

Mesial height measurements in (mm)	I (n = 10)		II (n = 10)		t	p
	Mean	±SD.	Mean	±SD.		
Baseline	2.39	0.77	2.21	0.71	0.542	0.595
Grafting time	1.22	0.39	1.22	0.36	0.000	1.000
4 months after grafting	1.85	0.46	1.87	0.14	0.130	0.899
6 months after grafting	2.49	0.46	2.11	0.42	1.933	0.069

t: Student t-test p: p value for comparing between the studied groups

In regard to changes in central heights measurements there was no statistically significant difference between the groups from baseline to 6M (Table2).

Table 2: Comparison between the two studied groups according to central height

Central height measurements in (mm)	I (n = 10)		II (n = 10)		t	p
	Mean	±SD.	Mean	±SD.		
Baseline	17.47	1.76	16.86	1.54	0.824	0.420
Grafting time	1.24	0.33	1.21	0.21	0.243	0.811
4 months after grafting	2.69	0.75	2.32	0.46	1.330	0.200
6 months after grafting	3.74	0.49	3.32	0.45	2.007	0.060

t: Student t-test p: p value for comparing between the studied groups

In regard to changes in distal heights measurements there was no statistically significant difference between the groups from baseline to 6M (Table3).

Table 3: Comparison between the two studied groups according to distal height

Distal height measurements in (mm)	I (n = 10)		II (n = 10)		t	P
	Mean	±SD.	Mean	±SD.		
Baseline	1.91	0.40	2.01	0.60	0.437	0.667
Grafting time	0.90	0.27	0.84	0.24	0.528	0.604
4 months after grafting	2.01	0.15	2.09	0.30	0.752	0.462
6 months after grafting	2.71	0.28	3.20	0.56	2.454	0.029

t: Student t-test p: p value for comparing between the studied groups

In regard to changes in bone density measurements there was a statistically significant difference between mean changes in the groups GR to 6M (Table4)

Table 4: Comparison between the two studied groups according to bone density

Bone density	I (n = 10)		II (n = 10)		t	p
	Mean	±SD.	Mean	±SD.		
Grafting time	475.60	89.80	506.50	87.90	0.778	0.447
6 months after grafting	567.40	93.60	657.5	98.79	3.068*	0.005*

t: Student t-test p: p value for comparing between the studied groups

Discussion:

The primary aim of this randomized clinical trial was to assess whether the use of a ridge preservation material significantly minimizes alveolar ridge resorption following tooth extraction. The present investigations indicated that alveolar ridge preservation with either (adbone®TCP

99,9% TCP Italy) or (adbone®BCP Italy) Composition: 75% Hydroxyapatite;25% (β -TCP) covered with Atelo-Collagen Type I Membrane Hypro-Sorb® F 15×20 mm bilayer bioresorbable barrier, Germany , resulted in radiographic bone-level changes. The mean differences between the two groups were not statistically significant. In addition, within each group, the mean values taken at baseline were not statistical different to the values taken at 6M indicating that interproximal bone could be fully preserved following ridge preservation with both biomaterials.

In the present investigation, the radiographic analysis on the same patients showed a small decrease in the interproximal radiographic bone levels at 4 and 6 months following operation in both groups. In the TCP group (I), the changes in Mh and Dh, representing possible radiographic hard tissue loss at the mesial and distal site, were 0.10 ± 0.89 mm and 0.80 ± 0.52 mm , respectively, at 6 months following tooth extraction (BL–6M). For the same period (BL–6M) in the BCP group (II), the Mh and Dh showed a mean difference of 0.10 ± 0.51 mm and 1.19 ± 0.69 mm, respectively, indicating a mild interproximal bone loss.

Intraoral radiographic examination to assess bone levels following tooth extraction^(11,12), or to detect changes in infrabony defects after regenerative treatment, has been used at previous clinical studies^(13,14). However, such type of analysis has specific limitations as an assessment tool, starting from the fact that periapical radiographs provide only two-dimensional images of three-dimensional structures. Therefore, it was important that the images were taken under standardized conditions (film type, time of exposure, film processing) at a standardized projection geometry⁽¹⁵⁾.

In addition to linear radiographic measurements, the present study evaluated hard tissue changes in density using CBCT scan from grafting time to 6 months. Multi slice and cone beam CT images are frequently used to determine mineral density of craniofacial

structures. Yet, there is no consensus regarding the accuracy of CBCT for this type of analysis. While some studies advocate its use, others advocate that CBCT is not an adequate tool for this type of evaluation because the intensity values of CBCT are influenced by the characteristics of the system and by the scanned object⁽¹⁶⁾.

There was a statistically significant difference between the two groups; group II showed a higher bone density than group I The mean bone density of group II was (506.50 ± 87.90 GV) at Grafting time, while the group I was (475.60 ± 89.80 GV) at Grafting time. By time passing and introducing CBCT after 6 months and measuring bone density it was found that an increase in measurement in group II (657.5 ± 98.79 GV) than in group I (567.40 ± 93.60 GV), showing that there was a statistically significant difference between the two groups and it may be attributed to percentage of HA in the components of BCP in the group II, that prolong the time of alloplast before complete replacement by natural bone and giving more time for ridge preservation.

The application of GBR has been advocated for the promotion of new bone formation and for the preservation of the volume and contour of the alveolar ridge following tooth extraction. Also reported that the application of resorbable barriers without bone grafting procedures can reduce alveolar ridge resorption following tooth extraction⁽¹⁷⁾.

In conclusion, the use of β -TCP with collagen membrane type I as a barrier in the present study, was effective in socket preservation and significantly minimized ridge resorption in mesial, central and distal bone heights as well as BCP and the two materials were able to increase the quality of the novel bone and enhance the rate of bone formation due to osteoconductive property, with some significant increase in bone density in BCP group than TCP group.

References

1. Schropp L, Wenzel A, Kostopoulos L, Karring T. Bone healing and soft tissue contour changes following single-tooth extraction: a clinical and radiographic 12-month prospective study. *Int J Periodontics Restor Dent*. 2003; 23:313–323
2. Levine RA, Horowitz RA. Bone reconstructive surgery for implant site preparation. *Functional Esthetics & Restorative Dentistry*. 2007; 1: 20-28
3. Iasella JM, Greenwell H, Miller RL, et al. Ridge preservation with freeze-dried bone allograft and a collagen membrane compared to extraction alone for implant site development: a clinical and histologic study in humans. *J Periodontol*. 2003; 74:990-999.
4. Nevins M, Camelo M, De Paoli S, et al. A study of the fate of the buccal wall of extraction sockets of teeth with prominent roots. *Int J Periodontics Restorative Dent*. 2006; 26:19-29.
5. Guarnieri, R.; Aldini, N.N.; Pecora, G.; Fini, M.; Giardino, R. Medial-grade calcium sulfate hemihydrate (surgiplaster) in healing of a human extraction socket—Histologic observation at 3 months: A case report. *Int. J. Oral Maxillofac. Implants* 2005; 20: 636-641.
6. Torres-Lagares, D.; Bonilla-Mejias, C.; Garcia-Calderon, M.; Gallego-Romero, D.; Serrera-Figallo, M.A.; Gutiérrez-Pérez, J.L. Prospective assessment of post-extraction gingival closure with bone substitute and calcium sulphate. *Med. Oral Patol. Oral Cir. Bucal* 2010; 15: 774–778.
7. Vos, M.D.; Raghoobar, G.M.; van der Wal, J.E.; Kalk, W.W.; Vissink, A. Autogenous femoral head as grafting material for mandibular augmentation. *Int. J. Oral Maxillofac. Surg*. 2009; 38: 1320–1323.
8. Ten Heggeler, J.M.; Slot, D.E.; van der Weijden, G.A. Effect of socket preservation therapies following tooth extraction in non-molar regions in humans: A systematic review. *Clin. Oral Implants Res*. 2011; 22: 779–788.
9. Frenken, J. W. F. H., Bouwman, W. F., Bravenboer, N., Zijdeveld, S. A., Schulten, E. A. J. M., & ten Bruggenkate, C. M. The use of Straumann® Bone Ceramic in a maxillary sinus floor elevation procedure: A clinical, radiological, histological and histomorphometric evaluation with a 6-month healing period. *Clinical Oral Implants Research* . 2010; 21: 201–208.
10. Hockers T, Abensur D, Valentini P, Legrand R, Hammerle CH. The combined use of bioresorbable membranes and xenografts or autografts in the treatment of bone defects around implants. A study in beagle dogs. *Clin Oral Implants Res* 1999; 10: 487–98.
11. Aimetti, M., Pigella, E. & Romano, F. Clinical and radiographic evaluation of the effects of guided tissue regeneration using resorbable membranes after extraction of impacted mandibular third molars. *International Journal of Periodontics and Restorative Dentistry*. 2007: 27: 51–59.
12. Munhoz, E.A., Ferreira, J.O., Yaedu, R.Y. & Granjeiro, J.M. Radiographic assessment of impacted mandibular third molar sockets filled with composite xenogenic bone graft. *Dentomaxillofacial Radiology* . 2006:35: 371–375.
13. Zybutz, M., Rapoport, D., Laurell, L. & Persson, G.R. Comparisons of clinical and radiographic measurements of inter-proximal vertical defects before and 1 year after surgical treatments. *J Clin Periodontology* 2000:27: 179–186.
14. Linˆares, A., Cortellini, P., Lang, N.P., Suvan, J. & Tonetti, M.S. European research group on periodontology (ErgoPerio). Guided tissue regeneration/ deproteinized bovine bone mineral or papilla preservation flaps alone for treatment of intrabony defects. II: radiographic predictors an outcomes. *Journal of Clinical Periodontology* 2006:33: 351–358.
15. Wenzel, A. & Sewerin, I. Sources of noise in digital subtraction radiography. *Oral Surgery Oral Medicine Oral Pathology* 1991:71: 503–508.

16. Razi T, Niknami M, Alavi Ghazani F. Relationship between Hounsfield Unit in CT Scan and Gray Scale in CBCT. J Dent Res Dent Clin Dent Prospects. 2014 ; 8 :107-10.

17. Vance, G.S., Greenwell, H., Miller, R.L., Hill, M., Johnston, H. & Scheetz, J.P. Comparison of an allograft in an experimental putty carrier and a bovine-derived xenograft used in ridge preservation: a clinical and histologic study in humans. The International J Oral & Maxillofac Implants 2004:19: 491–497.