

Effect of implant supported overdenture with different bar attachment modalities on the implant and overdenture supporting structure

Ahmed Abdelaty Salama^{}, Hany Ibrahim Eid^{**} and Shaimaa Lotfy Mohamed Ouda^{***}*

Purpose: This study examined effect of clip and Retention.sil as bar method of attachment on the implant and overdenture supporting structure.

Material and methods: In a randomized-controlled clinical trial, 14 edentulous males

patients (mean age 57.5 years) were equally assigned to two groups. In each patient, two implants were inserted in the canine area of the mandible using a two-stage surgical protocol. After 3 months, the implants were connected with resilient bars. Mandibular overdentures were retained to the bars with either clips (group I) or Retention.sil (group II). Peri-implant and vertical alveolar bone changes were evaluated radiographically. Evaluations were performed at the time of overdenture insertion (M0), 6 months (M6) and 12 months (M12) after overdenture insertion.

Results: There was a statistically significant difference in vertical alveolar bone changes between bar and Retention.sil. The clip vertical alveolar bone loss where been higher than that of Retention.sil in all situations.

Conclusion: After 12 months of using bar-implant-retained mandibular overdenture, the Retention.sil attachment had significantly decreased vertical bone loss when compared with the clip attachment.

Key words: clip attachment, Retention.sil, implants, mandible, and overdenture.

^{*} M.D.S, B.D.S., Ain Shams University

^{**} Professor of Prosthodontics, Ain Shams University

^{***} Assistant Professor of Prosthodontics, Ain Shams University

Introduction:

Implant supported overdenture which used to be considered as alternative line of treatment for conventional denture in treatment of completely edentulous mandible, now a day duo to the high success rate of 2-implant retained overdenture, it consider by many author as the standard of care for edentulous patients⁽¹⁾.

Implant supported overdentures improved oral health related quality of life for edentulous patients compared to conventional dentures. In a systematic review comparing between different treatment modalities of completely edentulous patient according to the initial treatment and maintenance costs during the follow-up period, it was found that overdenture supported by two implants might be the most cost-effective protocol over the long term⁽²⁾.

One of the main objectives of overdenture treatment is preservation of the residual ridge and reducing the rate of alveolar bone resorption. This could be achieved by controlling the amount of stress transmitted to the implant and overdenture supporting structure^(1, 3).

Implant supported overdenture which defined as any removable dental prosthesis that covers and rests on one or more implants has many advantage over the conventional one these advantage are like minimizing anterior bone loss, increasing occlusal efficiency and improving esthetics, stability, retention, support, speech and chewing efficiency of the prosthesis^(4, 5). These are what make many studies show higher satisfaction scores for patients with implant-retained overdentures compared to patients with conventional dentures, while patients treated with conventional dentures became more dissatisfied with time^(6, 7).

The implant is more preferable to be placed in the canine region one in each side duo to greatest height of available bone is located in the anterior region, also away from anatomic limitations especially the inferior alveolar nerve bundle. ⁽⁸⁾

Implant may be attached to the denture base

by unsplinted attachment like ball attachment or by splinted attachment like bar attachment.

Ball attachment less costly, less technique sensitive, easier to clean and the mucosal hyperplasia is more easily reduced with ball attachment than the bar attachment. ⁽⁹⁾

Bar attachment is a bar spanning over an edentulous area joining the abutment. The denture fits over the bar and may connect to it by one or more sleeves. ⁽¹⁰⁾

The bar attachment can classify into two main category bar units and bar joints. Bar units has parallel walls providing rigid fixation with frictional retention and they allow no movement between denture and bar. Bar joints has rounded or semi rounded contour which allow the prosthesis to rotate slightly during mastication which give it stress-braking action, so it minimizes forces on the abutment. Which make it the bar of selection in case of low number of abutments. ⁽¹¹⁾

Clip attachment is the most commonly used type of attachment with bar. It fabricated from varies type of material metal and nonmetal with different snap-in friction, it permits hinge like movement between prosthesis and bar. ⁽⁵⁾

Soft liners are polymers which are soft at mouth temperature because their glass transition temperature is below 37c. This property allows them to close under the bar, which gives the prosthesis retention.

Materials made of acrylic and silicon are mainly used for soft denture lining at present. The silicone soft lining materials are chemically stable and thus the elasticity can be maintained, but as they do not directly adhere to acrylic resin, an adhesive is necessary. The bond strength is not yet sufficient. In addition, as the silicone rubber is porous, food debris, which stagnates inside the pores, enhances the growth of fungi such as *Candida albicans*, leading to the formation of fungal colonies. On the other hand, acrylic soft lining materials adhere strongly to the acrylic resin denture base, but the added plasticizer will gradually diffuse onto the surface of the resin and will be leached out by the saliva, resulting in a

liner that will gradually harden. Also, there is a problem of bacterial contamination which may be due to the roughness of the surface or water sorption of the material. Thus, since soft denture lining materials are likely to be contaminated, the materials are required to be minimally contaminated from the viewpoint of oral hygiene.^(12, 13)

Resilient denture liner was suggested to be used as an attachment for bar/implant-retained overdentures. The resilient liners provide several advantages including availability, load distribution to the implants, patient comfort and absorption of occlusal force⁽⁸⁾.

In this regard, silicone materials with different retention levels especially developed to be used as matrices, such as Retention.Sil (Bredent) that has 3 options according to the detachment force desired (200, 400, 600 gf), the adhesive force of the prosthesis is set by selecting one of the three existing harnesses of retention.sil. Soft - medium - hard.

The aim of this study was to evaluate the peri-implant tissue health of mandibular overdentures retained to the implants using resilient liner or clip attachments. The null hypothesis was that there will be no significant difference in peri-implant tissue response to either type of attachments.

Materials and Methods:

Patients' selection:

Fourteen completely edentulous patients were selected from the outpatient clinic, Prosthodontic Department, Faculty of Dentistry, Ain Shams University. Included patients were required to have healthy mucosa, sufficient interarch space as well as sufficient bone height in the inter-foraminal region of the mandible and good bone quality. Patients with diabetes, osteoporosis, smoking habits or systemic diseases were excluded. The maxillary and mandibular casts were mounted on a mean value articulator at the correct occlusal vertical dimension according to provisional centric relation record to evaluate adequate interarch

distance, maxillomandibular relationship, parallelism between the upper and lower ridges, and the presence of at least 15 mm vertical space for the lower denture. On the mounted casts, waxed up upper and lower dentures were fabricated, the mandibular dentures were duplicated into transparent heat cured acrylic resin to be used as radiographic stent for a cone beam computed tomography "CBCT" after fixation of four gutta-percha markers labially between lower lateral incisors and canines, and canines and first premolars in both sides (Fig1).

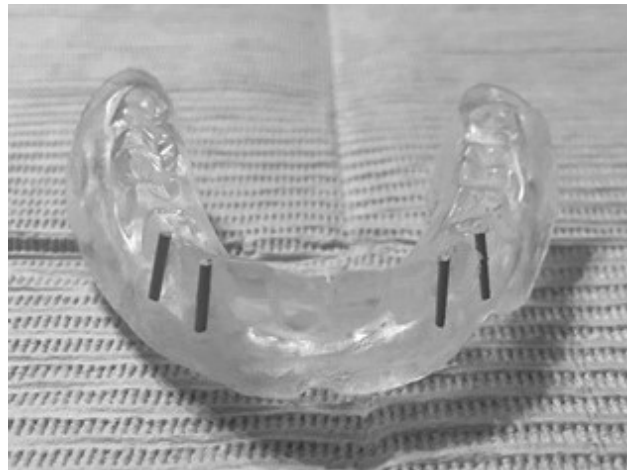


Fig 1: radiographic stent

The CBCT was used to check for the position of vital structure, detect the presence of any pathological changes within the bone and measurement of bone height and width at the canine areas. New upper and lower complete denture were construction for each patient according to conventional method, the lingualized concept of occlusion was used for setting up the teeth. Patients accepted enrollment in this study after being explained about its protocol and objectives and they all signed an informed consent. The patients were informed about the two treatment strategies that could be followed and were asked to participate in the study without prior knowledge of which treatment they were going to receive. Patients were assigned equally to receive either clip (group I) or resilient liner attachment (group II) using special computer software. Based on this assignment, seven patients were included in each group.

Surgical procedure:

A broad-spectrum antibiotic was prescribed for all patients 48 hours before surgery, continued for five days after surgery, patients were instructed to maintain good oral hygiene. Patient radiographic stent was used as surgical stent after cutting of two holes of 5mm width through the fitting surface of the stent corresponding to the selected position of implant insertion, Infiltration anesthesia was given at the corresponding region bilaterally, initial perforation of the cortical bone was made using the lance drill through the surgical stent. An incision was made in mid-crestal position to elevate full-thickness flap, the preparation of osteotomy was done according to manufacturer's protocol, then parallelism was verified using paralleling rods (Fig 2), before two root form implant 3.3 mm in diameter and 12 mm in length were placed at the canine region first manually by screwdriver and then by a ratchet until the implant platform became in the same level with bone. The cover screws were then threaded to the implants. Finally, interrupted sutures were made to close the flap using (000) black silk sutures. Ten days later after surgery, the sutures were removed and the dentures were relieved slightly over the area of implants, the patients were instructed to perform meticulous oral hygiene measure and to shift their diet to more solid food gradually after three to four weeks.

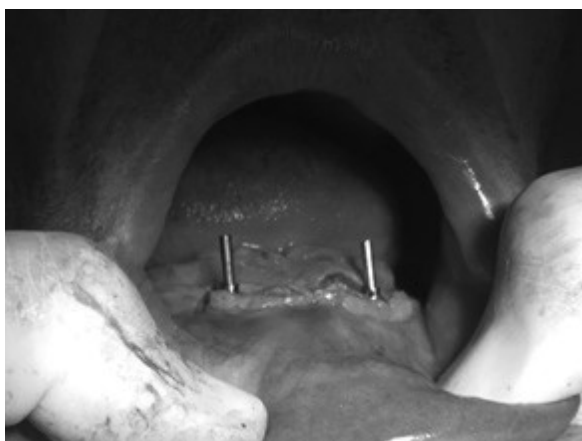


Fig 2: Paralleling rods

Prosthetic procedure:

After 3 months, the implant sites were

located using the tip of the probe guided by the surgical stent previously used during surgery. A tissue punch was used to expose the covering screws, the cover screws were removed, and the healing abutments were attached to implants. Alginate impressions of the lower residual ridges were made to obtain study casts with healing abutments in position, before construction of the special tray with the conventional method a wax block with a height of 15mm and thickness of 8 mm adapted over the residual ridge between the two healing-abutment replica and cover them (Fig 3). After two weeks, the healing abutments were removed, the transfer copings were screwed onto the implant and were linked together by scaffolding of dental floss, resin temporary crown material**** was applied to scaffolding of dental floss, then the impression was made by medium body silicon impression material***** in the special tray. The implant analogues were screwed to the copings and the cast was poured with type IV dental stone.



Fig 3: Wax block over the residual ridge between the two healing-abutment

the straight abutment was screwed to the implant analogues and shortened in length to 4mm above the gingival margin, Wax pattern coping***** was fabricated on each abutment and was connected to a preformed castable bar***** with wax. The bar was adjusted

**** CharmTemp Crown: Dentkist Inc., Korea.

***** Zhermach thixoflex medium: Zhermack SpA, Italy.

***** Dentaurum Milling Wax: DENTAURUM GmbH & Co. KG, Germany.

***** Resin bar vsp-fs: Bredent GmbH & Co.KG,

to be away from the anterior ridge by about 2-3mm (Fig4), the




Fig 4: Wax pattern

copying and bar wax pattern had been casted into metal using conventional wax elimination technique. The prepared abutments were unscrewed from implants analog and screwed to implants inside the patient's mouth after removal of healing collars, the proper seating and adaptation of the bars were checked before final cementation by resin cement^{*****}.

Attachment pick-up:

Suitable block out for the undercut beneath the bar was carried out using a light cured gum-protecting material^{*****} (Fig 5). Enough relief was made in the fitting surface of the denture.

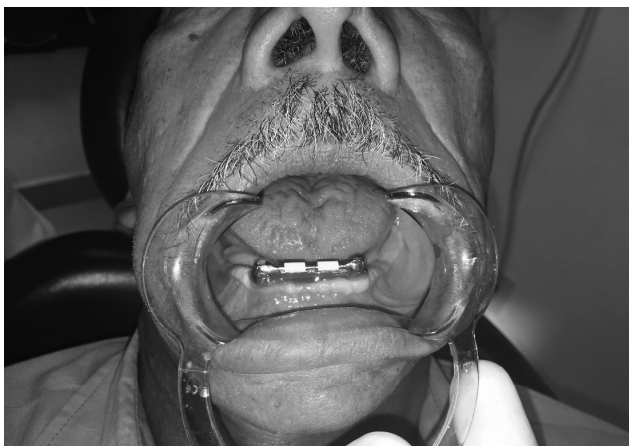


Fig 5: Block out for the undercut

Germany.
 ***** G-CEM Capsule: GC corporation, Tokyo, Japan.
 ***** Denu Dam Light Curing: HDI Inc., Korea.

For group I: Two retentive yellow clips^{*****} were placed over the bar, castable self-cured acrylic resin^{*****} was then mixed according to the manufacturer's instructions until reaching the dough stage and then placed into the fitting surface of the denture

For group II: Primer^{*****} was applied using disposable brushes then dried at air for 3 minutes. A thin coat of retention.sil^{*****} was applied to fill the fitting surface of the denture (relieved area of the denture). Then the steps were completed as group I.

Radiographic evaluation:

The radiographic evaluation the bone height changes around the implants and on the posterior alveolar ridge, it was carried out by CBCT after the overdenture insertion, six months and twelve months later. The bone height was measured between two reference points. The first point was the implant apex the second is the highest level of the alveolar crest at the mesial and distal aspects of the implants. The bone height of the residual ridge was measured bilaterally in the 2nd molar area, by measuring 30mm distal to the implant, then measure the bone height from the alveolar crest to the basal bone.

Statistical Analysis:

Statistical analysis was performed with IBM® SPSS® Statistics Version 25 for Windows. Data were presented by mean and standard deviation (SD). Mixed Analysis of Variance (ANOVA) was used to assess effect of bar material time, and site over bone loss followed by simple main effect with Bonferroni correction. The significance level was set at $P \leq 0.05$.

***** Joint snap-in matricesvsp-gs: Bredent GmbH & Co.KG, Germany.
 ***** Pi-Ku-Plast HP 36: Bredent GmbH & Co.KG, Germany.
 ***** Multisil-Primer: Bredent GmbH & Co.KG, Germany.
 ***** retention.sil 600: Bredent GmbH & Co.KG, Germany.

Results:

All patients attended to the follow up recall visits. Patients conveyed satisfaction as regards function, retention and stability of their appliances. Clinically, no pain was elicited with palpation or percussion, no exudates was observed in relation to the implants.

Table (VII): Mean values (mm), standard deviation (SD) and test of significance of peri-implant bone height change for group I versus group II during the follow up period

	Group I	Group II	P value
Changes from 0 to 6 Months	0.89±0.35	0.15±0.06	≤0.001*
Changes from 6 to 12 Months	0.58±0.14	0.13±0.06	≤0.001*
Changes from 0 to 12 Months	1.47±0.34	0.29±0.11	≤0.001*

Mean values of peri-implant bone height changes for attached bar design and Retention.Sil groups revealed statistical significant difference during all follow up period, Pairwise comparison was done according to Bonferroni test.

Comparison between peri-implant bone height from loading to the 12 months after loading, the mean recorded changes with clip attached bar design showed statistically significant higher value than that with Retention.Sil material.

Table (II): Mean values (mm), standard deviation (SD) and test of significance of posterior alveolar ridge height change for group I versus group II during the follow up period

	Group I	Group II	P value
Changes from 0 to 6 Months	0.73±0.04	0.38±0.06	≤0.001*
Changes from 6 to 12 Months	0.60±0.04	0.26±0.05	≤0.001*
Changes from 0 to 12 Months	1.33±0.08	0.64±0.10	≤0.001*

Mean values of posterior alveolar ridge

height changes for attached bar design and Retention.Sil groups revealed statistical significant difference during all follow up period, Pairwise comparison was done according to Bonferroni test.

Comparison between posterior alveolar ridge height from loading to the 12 months after loading, the mean recorded changes with clip attached bar design showed statistically significant higher value than that with Retention.Sil material.

Discussion:

This randomized control trial was conducted to assess and compare the effect of different bar attachment modalities on the implant retained mandibular overdenture supporting structures.

all patients were selected with no medical history of any systemic diseases to avoid the effect of systemic diseases on the condition of the bone and the healing process of the implant. Conditions such as anemia, diabetes, hypertension and nutritional disorders have a detrimental effect on the vascular supply and soft tissue quality. Failure may arise from impaired host healing, interruption of bone to implant interface after abutment connection and infection⁽⁹⁾.

To standardize the forces applied to the overdenture supporting structures, the opposing arch was selected completely edentulous as choosing different opposing arch occlusion; completely dentate arch, partially dentate with fixed or removable restoration will create different amount of occlusal stress applied on the implant retained overdenture which could affect the result⁽¹⁰⁾.

A special type of chair-side self-curing acrylic resin which does not generate heat was used to avoid gingival irritation of the tissues around implants during pick up procedure of bar clip for **group I**, acrylic resin was mixed and applied in the dough stage to avoid polymerization shrinkage of the acrylic⁽¹¹⁾.

Retention.sil is a silicon with very high tenacious strength was used in overdenture fitting surface over the bar as modality of bar attachment for **group II** due to its availability and easy to manipulation, As recommend by the manufactural the periods Retention.sil to be used not exceed 24 months, this is why we didn't need to replace Retention.sil in follow up period^(12, 13).

In this study, a statistically significant decrease in peri-implant bone height was detected for both studied groups at the end of twelve months follow-up period. A total change of 1.47 mm in group I (Clip bar) and 0.29 mm in group II (Retention.Sil). This amount of reduction plunged within the acceptable range of implant success and it agreed with the findings of **Cox and Zarb**⁽¹⁴⁾.

Although clip attachment allows hinge motion when vertical force is applied, the findings of the present study demonstrates that the use of Retention.Sil as a matrix over the bar attachment showed significant improvement in bone height changes of the implants' abutments compared to clip. These results may be attributed to several factors. The use of Retention.Sil acts as a shock absorber, which in turn reduces the magnitudes of loading transmission to the implant-bone interface. In addition, Retention.Sil housing completely obturates the space around the ball so it minimizes plaque and microbial adhesion that cause peri-implant tissue inflammation, bone loss and pocket formation. The cushion like shock-absorbing ability of the Retention.Sil reduces the stress applied to the implants, which in turn reduces peri-implant bone loss. These results are consistent with results from similar previous studies^(8, 15, 16).

In this study, a statistically significant decrease in posterior alveolar ridge height for both studied groups were detected at the end of 12 months follow-up period. A total change of 1.33 mm in group I (Clip bar) and 0.64 mm in group II (Retention.Sil) was found, which showed statistically significant improvement in bone height changes of the posterior alveolar ridge in Retention.Sil group in compared to

clip group. These results may be attributed to using of Retention.Sil permits all range of motion in all direction to the prothesis unlike clip attachment which allows hinge motion only, this lead to wide distribution of the load especially in the region just next to the implants' abutment, also the forces are directed more favorably in a more vertical direction in relation to the posterior alveolar ridge⁽¹⁷⁾.

Conclusion:

Within the limitation of the results obtained from this study, it could be concluded that:

1. The bone loss around the implant and in posterior alveolar ridge height in clip retained and Retention.Sil groups show a significant bone loss after twelve months of denture insertion.
2. The bone loss around the implant and in posterior alveolar ridge height show a greater amount in clip attachment group than in Retention.Sil group, and this different was found to be statistically significant.

References:

1. **Feine J, Carlsson G, Awad M.** Mandibular Two-Implant Overentures as First-Choice Standard of Care for Edentulous Patients. Report on McGill Consensus Statement on Overdentures. *Int J Oral Maxillofac Implants.* **2002**;601-2.
2. **Zhang Q, Jin X, Yu M, Ou G, Matsui H, Liang X, et al.** Economic Evaluation of Implant-Supported Overdentures in Edentulous Patients: A Systematic Review. *Int J Prosthodont.* **2017**;30(4):321-6.
3. **Toolson LB, Taylor TD.** A 10-year report of a longitudinal recall of overdenture patients. *J Prosthet Dent.* **1989**;62(2):179-81.
4. The Glossary of Prosthodontic Terms: Ninth Edition. *J Prosthet Dent.* **2017**;117(5S):e1-e105.

5. **Misch CE.** Prosthetic Options in Implant Dentistry. Contemporary Implant Dentistry. III: Elsevier Health Sciences; **2007.** p. 92 - 104.
6. **Mendes FA, Borges TF, Goncalves LC, de Oliveira TR, do Prado CJ, das Neves FD.** Effects of new implant-retained overdentures on masticatory function, satisfaction and quality of life. *Acta Odontol Latinoam.* **2016;**29(2):123-9.
7. **Fontijn-Tekamp FA, Slagter AP, Van Der Bilt A, Van THMA, Witter DJ, Kalk W, et al.** Biting and chewing in overdentures, full dentures, and natural dentitions. *J Dent Res.* **2000;**79(7):1519-24.
8. **Brignardello-Petersen R.** Resilient liner-retained overdentures seem to have a lower rate of mechanical complications than clip-retained overdentures in patients with 2 implant-supported bar-retained overdentures. *J Am Dent Assoc.* **2017;**148(9):e125.
9. **Chrcanovic BR, Kisch J, Albrektsson T, Wennerberg A.** Factors Influencing Early Dental Implant Failures. *J Dent Res.* **2016;**95(9):995-1002.
10. **Al-Magaleh WR, Abbas NA, Amer AA, Abdelkader AA, Bahgat B.** Biting Force and Muscle Activity in Implant-Supported Single Mandibular Overdentures Opposing Fixed Maxillary Dentition. *Implant Dent.* **2016;**25(2):199-203.
11. **Ranadive NN, Nadgere JB, Iyer J, Rathi PJ.** Enhancing Retention Using Overdentures with Bar Attachment: A Case Report. *Journal of Contemporary Dentistry.* **2019;**9(1):37-43.
12. **Preoteasa E, Imre M, Lerner H, Tancu AM, Preoteasa CT.** Narrow Diameter and Mini Dental Implant Overdentures. *Emerging Trends in Oral Health Sciences and Dentistry.* **2015;**241.
13. **Pommer B, Mailath-Pokorny G, Haas R, Busenlechner D, Furhauser R, Watzek G.** Patients' preferences towards minimally invasive treatment alternatives for implant rehabilitation of edentulous jaws. *Eur J Oral Implantol.* **2014;**7 Suppl 2:S91-109.
14. **Cox JF, Zarb GA.** The longitudinal clinical efficacy of osseointegrated dental implants: a 3-year report. *Int J Oral Maxillofac Implants.* **1987;**2(2):91-100.
15. **MA EL.** Prosthetic aspects and patient satisfaction with resilient liner and clip attachments for bar- and implant-retained mandibular overdentures: a 3-year randomized clinical study. *Int J Prosthodont.* **2012;**25(2):148-56.
16. **Gibreel M, Fouad M, El-Waseef F, El-Amier N, Marzook H.** Clips vs Resilient Liners Used With Bilateral Posterior Prefabricated Bars for Retaining Four Implant-Supported Mandibular Overdentures. *J Oral Implantol.* **2017;**43(4):273-81.
17. **Elsyad MA, Mohamed SS, Shawky AF.** Posterior Mandibular Ridge Resorption Associated with Different Retentive Systems for Overdentures: A 7-Year Retrospective Preliminary Study. *Int J Prosthodont.* **2017;**30(3):260-5.