



Effect of Aqueous Extract of Chicory (*Cichorium intybus* L.) Root on Sperm Parameters, Testicular Tissue and Testosterone in Adult Mice Exposed to Diazinon



CrossMark

Mahdeyeh Ahmadi¹, Neda Dastyar² and Seyed Hassan Eftekhari Vaghefi³

¹Head of Student Research Committee, Jiroft University of Medical Science, Jiroft, Kerman, Iran.

²Msc of midwifery, Department of midwifery, Jiroft University of Medical Sciences, Jiroft, Iran.

³Professor of Anatomical Sciences, Department of Anatomy, School of Medicine, Kerman University of Medical Sciences, Kerman, Iran.

OBJECTIVE: the effects of diazinon (DZ) on some sperm parameters, testicular tissue and testosterone of mice and the effect of *Cichorium intybus* L. root extract (chicory extract) on reducing its effects were studied. **Material and Methods:** 70 adult male balb/c mice were studied in five treatments (control, DZ, chicory, two compounds of DZ and chicory) in vitro. DZ toxin was injected intraperitoneally at 30 mg/kg for one month (5 consecutive days and 2 days rest) and concentrations of 100 and 200 mg/kg chicory extract were fed. The effects of DZ and chicory pretreatment on sperm parameters, testicular tissue and testosterone were investigated.

Results: DZ showed a significant effect on all parameters of sperm, testicular tissue and testosterone ($P < 0.01$). DZ reduced sperm viability by 62% but pretreatment with 100 mg/kg chicory extract reduced approximately 24% of DZ effects. Straight moving decreased and zig-zag moving, vibrating and non-motile motility increased in sperms. The greatest effect of DZ on sperm morphological abnormalities was increased sperms with tail malformations. Exposure to DZ decreased the sperm count by more than 70%. In addition, weight, size, Leydig, spermatogonia, primary spermatocyte and spermatid cells and serum levels of testosterone were decreased ($P < 0.01$). Chicory extract at the dose of 100 and 200 mg/kg ($P < 0.01$) reduced the effects of DZ but on increasing the dose, its detoxifying effect is reduced.

Conclusions: Exposure to DZ reduced male fertility. Chicory extract at a concentration of 100 mg/kg can reduce the detoxifying effect of DZ.

Keywords: Testosterone, Mice, Animals, Chicory, Diazinon.

Introduction

Organophosphates (OPs) are among the most commonly used insecticides globally. OPs have been widely used in agricultural and household applications to control pest insects [1]. DZ is an organophosphate insecticide that can cause

irreversible damage [2]. This toxin is absorbed from skin, conjunctiva, respiration and food [3]. DZ causes damage in liver [4-6], kidney [4,7] and Pancreas [4,8]. DZ causes apoptosis in brain cells [9]. Cancer, infertility, nervous-endocrine disorders and immunological disorders are also caused by DZ. DZ decreases LH, FSH levels,

Corresponding author: Seyed H. E. Vaghefi, E.mail: sheftekhari vaghefi@kmu.ac.ir, Tel. +98 34 3132 5600
(Received 10/01/2021; Accepted 15/04/2021)

DOI. 10.21608/ejvs.2021.57447.1213

©2021 National Information and Documentation Centre (NIDOC)

sperm count and testosterone level and causes destructive changes in seminiferous tubules [10,11]. Researches have shown that carbon ion irradiation (CIR) damages the sperms' DNA and increases apoptosis in spermatogenic cells, which eventually damages the reproductive system [12].

Medicinal plants, as potential sources of health-promoting compounds, have been used to treat various human diseases for thousands of years [4]. In traditional medicine, plants such as the compositae family (Asteraceae) including chicory have been mentioned to have anti toxic effects. Alpha-amyrin, Taraterone, Baurenylacetate, amyllum, carbohydrates, proteins, Polyacetylenes, lipids and tretinoin are the chemical compounds in chicory [13]. Jurgoński *et al.* found that chicory root increases blood sugar and has ameliorative effects on kidney and heart [14]. Chicory is very effective in eliminating liver toxins [15] and help to control diabetes [16]. Studies have shown that Cyclophosphamide causes a reduction in the weight of testis and activity of spermatogenic but chicory extract reduces these effects with its antioxidant properties [17]. Bitter chicory increases the ovulation rate compared to cereals [18].

Chemical drugs often have side-effects, so it is necessary to obtain herbal medicine that can replace chemical drugs. Therefore, the present study was designed to determine the effects of chicory extract in counteracting the hazardous effect of diazinon on sperm parameters, testicular tissue and testosterone in adult mice.

Materials and Methods

Plant material and extraction

This study conducted in 2019. The roots of Common chicory (*Cichorium intybus*) were collected from a local market for herbs and medicinal plants. The Staff members of Agriculture at the University of Jiroft authenticated the identity of the plants. The roots were washed, dried and milled. After that, the powder was passed through a mesh (particle size: 10 mm). The powdered material was extracted with water at room temperature for 7 days in a conical flask with continuous shaking and stirring. The extract was filtered and dried by evaporation in a hot air oven at 50°C [19].

Chemical

For this study, technical DZ 98% was purchased from Ariashimi Company. DZ was prepared by adding 0.2 ml of DZ to 10 ml of emulsion distilled water [11].

Animals and treatments

Adult male mice (Balb/c race) (8 weeks old, approximately 20-25 g) were obtained from the animal breeding unit at the Afzalipour Faculty of Medicine in kerman. The mice were housed at 23± °C and 55± 5% relative humidity, with 12 h dark/light cycle and *ad libitum* access to food and water. All mice were acclimatized in metal cages for one week prior to the experiment to ensure normal growth and behavior [19]. After the acclimatization period, the rats were randomly divided into 5 groups of 14 animals each based on literature:

Group I: Control group, received 0.5 ml distilled water by gavage on 35 consecutive days.

Group II: received chicory extract at the dose of 100 mg/kg by gavage on 35 consecutive days using the expert consolations.

Group III: received DZ by Intra Peritoneal injection of 30 mg/kg using the expert consolations. On 35 days (5 consecutive days and 2 days rest).

Group IV: received chicory extract at the dose of 100 mg/kg by gavage and after 20 min injection of 30 mg/kg DZ on 35 days (5 consecutive days and 2 days rest).

Group V: received chicory extract at the dose of 200 mg/kg by gavage and after 20 min injection of 30 mg/kg DZ on 35 days (5 consecutive days and 2 days rest).

The animals were killed by Chlorohydrate, 35 days after the latest injection and the quality of sperm, testicular tissue and testosterone were assessed. This study approved by institutional review board and ethics committee of Kerman University of Medical Science.

Epididymal sperm preparation

After 35 days, a small part of the cauda epididymis of each mouse was dissected and located in 1 mL of pre-warmed (26± 1°C) Hams F10 medium based on literature. Gentle tearing of the tissue was done to make spermatozoa swim out into the culture medium. The dishes were placed in the incubator for 15 min.

Sperm parameters

Normal morphology, viability, sperm motility, and sperm count were evaluated for at least 200 sperm from each animal. The morphologically normal spermatozoa and the percentage of viable sperm cells were assessed by Papanicolaou's staining and Eosin test respectively [20]. Motility

was expressed as the percentages of progressive motility including Straight moving (Grade A) (These are the strongest spermatozoa and swim fast in a straight line.), Zig-zag moving and Vibrating (Grade B) (These spermatozoa also move forward but tend to travel in a curved or crooked motion.) and Non-motile (Grade C) (These spermatozoa are entirely immotile and fail to move at all.) [21].

Morphometrical parameters of the testis

Structural changes in testicular tissue were examined and the following parameters were recorded: weight and size of testis, Leydig, Spermatogonia, primary spermatocytes, spermatids cells which was measured by light microscope equipped by eyepiece graticule [11].

Evaluating serum levels of Testosterone

Testosterone was assessed by using competitive chemiluminescent immunoassay kit (DRG Co, Germany, and Pishtaz Teb, Iran).

Statistical analysis

Statistical analysis was carried out using SPSS version 22.0. The differences between means were compared for statistical significance by one way ANOVA and Tukey post hoc test. Differences was considered significant at $p < 0.05$.

Results

Sperm parameters

The means of sperm parameter in different groups of adult male mice are demonstrated in table 1. Compared with control group, DZ decreased viability ($P < 0.01$). Pretreatment with chicory extract decreased DZ effect ($P < 0.01$) and the effect of 200 mg/kg chicory extract was less than 100 mg/kg. There was no significant difference in viability between groups treated with chicory extract and control groups ($P < 0.01$).

DZ affected all sperm motility, in which straight moving (Grade A) were reduced significantly, and zig-zag moving and vibrating (Grade b) and non-motile (grade C) were increased ($P < 0.01$). Pretreatment with 100 and 200 mg/kg chicory extract reduced DZ effect, in which the percentage of sperms were increased in (Grade A) and sperm motility in (Grad B) and (Grad C) were decreased ($P < 0.01$). In this study chicory extract had no significantly effect on sperm movement, compared to control group.

Mouse treated with DZ showed significantly ($P < 0.01$) increased number of morphological abnormalities in sperms. Pretreatment with 100 and 200 mg/kg chicory extracts reduced DZ effects and the effect of 200 mg/kg was less than 100 mg/kg ($P < 0.01$). Chicory extract reduce the morphological abnormalities compare to control group ($P < 0.01$).

DZ significantly decrease the sperm count compared to control groups ($P < 0.01$). Conversely, significant increases were detected in group IV and group V compare to group III. There was no significant difference in Sperm count between groups treated with chicory extract and control groups ($P < 0.01$). Seminiferous tubules in mice showed in fig 1. The results of this study show that in DZ group the seminiferous tubules had different degrees of destruction and tearing. The tubules had growth delay and some were canalized, and degenerated germinal cells were observed. However most of the tubules had little spermatogonia and primary spermatocyte cells. The testicles had atrophy necrosis, and the intra tubule space had less development in DZ group than control group, while in control group there were more sexual cells in seminiferous tubules sections, and testosterone levels were decreased and disorders increased. Leydig cells in interstitial tissue in DIA group were significantly reduced, compared to control group, and in some sections, there were no Leydig cells in interstitial tissue.

Morphometrical parameters of the testis

Results of Morphometrical parameters of the testis of the mice from all groups are summarized in Table 2. The results show that DZ caused a significant reduction in weight and size (length, width, diameter) compared to control group ($p < 0.01$). Pretreatment with 100 and 200 mg/kg chicory extract had positive effects on reducing the effects of DZ on testicular weight and size ($p < 0.01$). The effect of 200 mg/kg chicory extract was less than 100 mg/kg. Application of chicory extract alone had no significant effect on testicular size and weight ($P > 0.05$).

The number of Leydig, Spermatogonia, spermatocyt, spermatids cells in mice fed chicory extract was not significantly different from the control group ($P > 0.05$). DZ caused a significant reduction in those cells ($p < 0.01$) and pretreatment with 100 and 200 mg/kg chicory extract reduced DZ effects. The effect of 200 mg/ml chicory extract was less than 100 mg/kg ($p < 0.01$).

TABLE 1. Sperm parameters changes in mice exposed to DZ and chicory extract

Parameters	State	Group I	Group II	Group III	Group IV	Group V
Viability (%)	-	79.6 ±4.3 ^c	76.6±5.5 ^c	30.3±5.1 ^a	50.3±6.4 ^b	43.4±3.5 ^{ab}
	Grad A	70.4±6.5 ^c	66.2±6.4 ^c	11.4±4.3 ^a	39.3±7.5 ^b	28.3±4.3 ^b
Motility (%)	Grad B	18.3±2.6 ^a	20.4±5.5 ^a	45.3±5.4 ^c	32.4±2.3 ^b	38.1±4.5 ^{bc}
	Grad C	12.6±2.5 ^a	13.3±6.7 ^a	76.4±4.4 ^c	41.2±5.5 ^b	44.2±4.6 ^b
Morphological abnormalities (n)	Abnormal head	2.7±1.1 ^a	3.3±1.5 ^{ab}	8.3±1.6 ^c	5.3±1.4 ^{ab}	7±1.1 ^{bc}
	Abnormal neck	4.3±1.4 ^a	5.2±1.6 ^{ab}	10±1.1 ^c	7.3±0.6 ^{ab}	8.4±0.6 ^{bc}
	Abnormal tail	2.4±1.5 ^a	3±1.7 ^a	10.7±2.1 ^c	5±1.1 ^{ab}	8.4±1.6 ^{bc}
Sperm count	-	1652069±130603.5 ^c	1548021.7±107132.6 ^c	426022±59633.4 ^a	972029±59633.1 ^b	830180.7±57271.2 ^b

The data is presented as mean and standard deviation, Within rows, means followed by the same letter are not significantly different according to tukey (0.05).

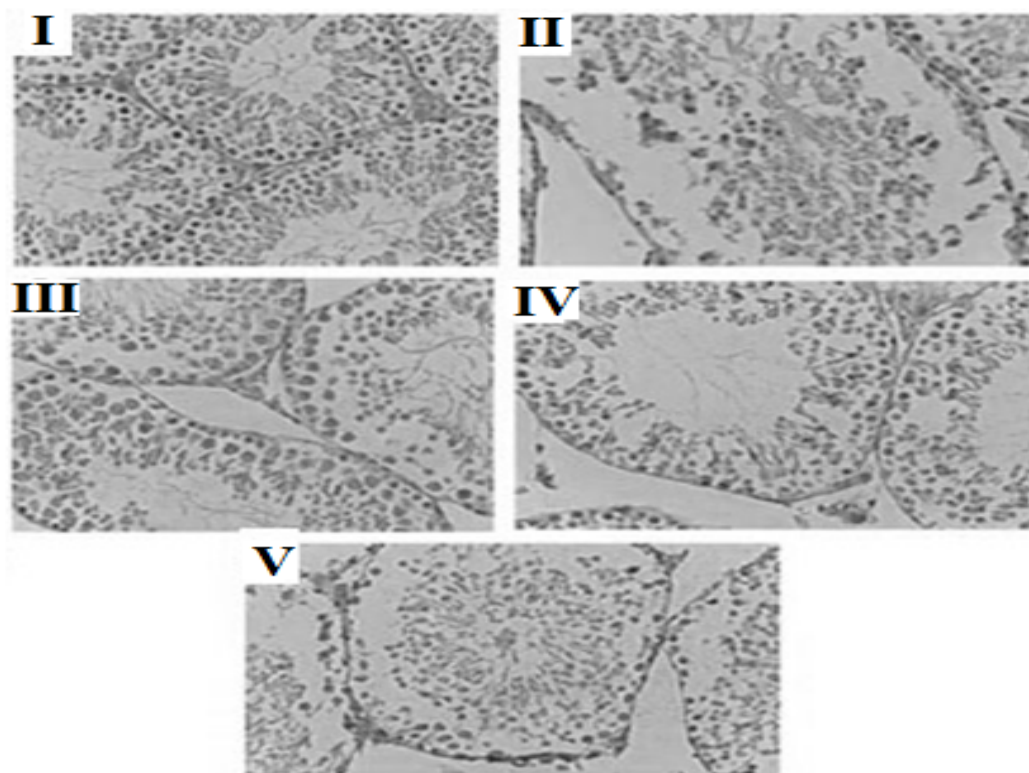


Fig. 1. Seminiferous tubules in mice. The indexes shown in the figures represent group I to V.

Group I: Active spermatogenesis was increased and more sperm cells were seen. Blood vessels are visible in the connective tissue between the tubes of Leydig cells.

Group II: Cellular irregularities were observed in the seminiferous tubules and increasing the distance of these tubes. Leydig cells decreased in connective tissue.

Group III: Active spermatogenesis, significant thickness of the epithelium and border of the seminal vesicles, integration between them and Leydig cells.

Group IV: Sperm cell wall and cells show better order than diazinon group

Group V: Structural changes in seminiferous tubules with delayed

TABLE 2. Testicular tissue parameter and testosterone changes in mice exposed to DZ and chicory extract

Parameters	Group I	Group II	Group III	Group IV	Group V
Weight(kg)	0.117±0.003 ^b	0.111±0.009 ^b	0.078±0.004 ^a	0.092±0.004 ^a	0.085 ±0.004 ^a
Length (mm)	8.21±0.5 ^c	7.99±0.37 ^c	4.82±0.24 ^a	7.02±0.09 ^b	6.69 ±0.22 ^b
Width(cm)	5.83±0.06 ^c	5.62±0.15 ^c	3.49±0.35 ^a	4.6±0.18 ^b	4.23±0.12 ^b
Diameter(cm)	5.49±0.23 ^c	5.38±0.25 ^c	3.23±0.22 ^a	4.06±0.17 ^b	3.67±0.25 ^{ab}
Leydig cells (%)	32.3±1.88 ^d	31.7±2.21 ^d	15.7±3.33 ^{ac}	25.3±2.21 ^{bc}	21.3±2.21 ^{ab}
Spermatogonia cells	52.3±2.75 ^c	49.2±3.79 ^c	20.1±2.96 ^a	33.1±2.96 ^b	25.9±4.48 ^{ab}
Primary spermatocyte cell (µm)	99.7±6.99 ^c	95.9±9.98 ^c	37.3±5.33 ^a	66.7±8.38 ^b	43.6±6.81 ^a
Spermatid cells(µm)	63.5±3.43 ^c	60.4±3.09 ^c	18.1±2.28 ^a	30.1±3.34 ^b	21.8±4.72 ^{ab}
Serum levels of testosterone (ng/dL)	2.16±0.38 ^c	1.86±0.71 ^{bc}	0.33±0.14 ^a	1.13±0.35 ^{abc}	0.79±0.22 ^{ab}

The data is presented as mean and standard deviation, Within rows, means followed by the same letter are not significantly different according to tukey (0.05).

Exposure to DZ decreased serum levels of testosterone in mice, but chicory extract reduced the effects of DZ on decreasing testosterone levels ($P<0.01$). Increasing the dosage of chicory extract was not effective in more decreasing the effect of DZ on serum levels of testosterone.

Discussion

DZ is an organophosphate compound that is commonly used in agriculture but has negative health effects on living organisms. The presence of pesticide residues in the environment and food products is a serious warning and should be evaluated at clinical levels. Evaluation of fertility decline due to pesticides among human models is unauthorized. In the scientific community, pre-clinical animal studies provide a lot of information because it imitates similar function and metabolism.

In the present study, compared with control group, rats treated with DZ alone showed significantly ($P<0.05$) decreased in percent of viability (by 62%) and sperm count (by 74.2%). The data from sperm motility analysis demonstrated that DZ has adverse effect on the straight moving. In addition, zig-zag moving and vibrating and non-motile increased. The result showed that morphological abnormalities in the neck are significantly higher in DZ group. Our results showed that chicory extract was able to exert an effect over the damage, induced by an exposure to the DZ, on all the analyzed parameters of mice sperm. The present results are consistent with those of other researchers who investigated the effect of DZ on sperm parameters [22-25, 11]. DZ damages sperm chromatin through

phosphorylation of protamine in nucleus and so it has a negative effect on the male reproductive system [26]. Several intra cellular components such as energy contents, plasma membrane mediators for ionic exchange and axoneme structure and composition are responsible for sperm movement [27]. Organophosphates affect sperm motility by disturbing synthesis of ATP or energy pooling besides a significant increase in percentage of broken sperms [28].

In quantitative analysis, there were significant differences between testis weight and size exposed to DZ and the controls. Furthermore, DZ caused significant reduction in Leydig, spermatogonia, primary spermatocyte and spermatid cells and a serum levels of testosterone. So, DZ were sufficient to cause disorganization on the level of testes structure. We observed that chicory extract could reduce the damage considerably in comparison with the DZ group. Compared to the DZ group, the chicory extract pretreated group (100 mg) had increased testicle weight and size besides there were more Leydig, spermatogonia, primary spermatocyte and spermatid cells. The results of the present study support previous research into DZ-induced changes in testicular tissue and confirm the reproductive toxicity following DZ exposure [10, 11, 22, 29-31]. DZ induces the production of oxidative stress by alteration of antioxidant enzyme activity and increasing lipid peroxidation [32, 33]. Increased oxidative stress in the testis is associated with the suppression of Leydig cell steroidogenesis [34], disruption of spermatogenesis [2], and implications for male fertility [23].

Likewise, it has been demonstrated that chicory extract produces an Improvement in the sperm abnormalities and Testicular tissue damage of mice treated by DZ. Chicory contained high phenolic contents, especially in leave and roots [35]. The therapeutic effect of chicory extract is to reduce toxicity [13]. The study of Fatahi *et al.* [11] on the sperm parameters of Varicocele patients showed that chicory extract improves sperm parameters [36]. Jamshidzadeh *et al.* [37] found that chicory extract in 200 mg/kg reduces Carbon tetrachloride toxicity in liver but in 400 mg/ml has toxic effect [37].

Conclusion

Our study supported the detrimental impacts that DZ has adverse effects on testes and sperm quality in the male mice. It was shown that chicory extract can reduce these effects because of its antioxidant properties. In the present study, chicory extract group at concentrations of 100 mg/kg and 200 mg/kg could partially reduce DZ toxic effects besides the concentration of 200 mg/kg chicory had less effect than 100 mg/kg. The present study showed that chicory's anti toxic effect decreases as the dose increases.

Acknowledgements

The authors express appreciation to the Jiroft University of Medical sciences, Student Research Committee for its support of this investigation.

Conflict of interest

The authors have declared that no conflict of interest exists.

Funding statement

Self-funding

Ethical consideration

This study approved by institutional review board and ethics committee of Kerman University of medical science.

References

1. Colovic, M., Krstic, D., Petrovic, S., Leskovic, A., Joksic, G., Savic, J., Franko, M., Trebse, P. and Vasic, V. Toxic effects of diazinon and its photodegradation products. *Toxicol. Lett.*, **193**, 9-18(2010).
2. Sarabia, L., Maurer, I. and Bustos-Obregon, E. Melatonin prevents damage elicited by the organophosphorous pesticide diazinon on mouse sperm DNA. *Ecotoxicology and Environmental Safety*, **72**(2),663-668. (2009).
3. Boucard, T.K., McNeill, C., Bardgett, R.D., Paynter, C.D. and Semple, K.T. The impact of synthetic pyrethroid and organophosphate sheep dip formulations on microbial activity in soil. *Environmental Pollution*, **153**(1),207-214 (2008).
4. Estakhri, M.A., Shokrzadeh, M., Jaafari, M.R., Karami, M. and Mohammadi, H. Organ toxicity attenuation by nanomicelles containing curcuminoids: Comparing the protective effects on tissues oxidative damage induced by DZ. *Iranian Journal of Basic Medical Sciences*, **22**(1),p17 (2019).
5. Mossa, A.T., Heikal, T.M. and Omara, E.A. Liver damage associated with exposure to aspirin and diazinon in male rats and the ameliorative effect of selenium. *Biomedicine & Aging Pathology*, **4**(2),137-145(2014).
6. Abdelsalam, E.B. and Ford, E.J. The effect of induced liver, kidney and lung lesions on the toxicity of levamisole and diazinon in calves. *Journal of Comparative Pathology*, **97**(6),619-627(1987).
7. Tsitsimpikou, C., Tzatzarakis, M., Fragkiadaki, P., Kovatsi, L., Stivaktakis, P., Kalogeraki, A., Kouretas, D. and Tsatsakis, A.M. Histopathological lesions, oxidative stress and genotoxic effects in liver and kidneys following long term exposure of rabbits to diazinon and propoxur. *Toxicology*, **307**,109-114 (2013).
8. Gokcimen, A., Gulle, K., Demirin, H., Bayram, D., Kocak, A. and Altuntas, I. Effects of diazinon at different doses on rat liver and pancreas tissues. *Pesticide Biochemistry and Physiology*, **87**(2),103-108 (2007).
9. Mrema, E.J., Rubino, F.M., Brambilla, G., Moretto, A., Tsatsakis, A.M. and Colosio, C. Persistent organochlorinated pesticides and mechanisms of their toxicity. *Toxicology*, **307**,74-88 (2013).
10. Elmazoudy, R.H. and Attia, A.A. Endocrine-Disrupting and cytotoxic potential of anticholinesterase insecticide, diazinon in reproductive toxicity of male mice. *Journal of Hazardous Materials*, **209**,111-120(2012).

11. Fatahi, E., Parivar, K., Joursaraei, S. and Moghadamnia, A.A. The effects of diazinon on testosterone, FSH and LH levels and testicular tissue in mice. *Iranian Journal of Reproductive Medicine*, **7** (2),59-64(2009).
12. Li, H.Y., Zhang, H., Miao, G.Y., Yi, X.I., Chao, S.U., DI, C.X., Yang, L.I., Liu, Y.Y., Zhang, X., Fei, X. and Shuai, X.U. Simulated microgravity conditions and carbon ion irradiation induce spermatogenic cell apoptosis and sperm DNA damage. *Biomedical and Environmental Sciences*, **26**(9),726-734(2013).
13. Du, H., Yuan, S. and Jiang, P. Chemical constituents of *Cichorium intybus* L. Zhongguo Zhong yao za zhi= Zhongguo zhongyao zazhi, *China Journal of Chinese Materia. Medica.*, **11**, 682-683(1998).
14. Jurgoński, A., Juśkiewicz, J., Zduńczyk, Z. and Król, B. Caffeoylquinic acid-rich extract from chicory seeds improves glycemia, atherogenic index, and antioxidant status in rats. *Nutrition*, **28**(3),300-306(2012).
15. Li, G.Y., Gao, H.Y., Huang, J., Lu, J., Gu, J.K. and Wang, J.H. Hepatoprotective effect of *Cichorium intybus* L., a traditional Uighur medicine, against carbon tetrachloride-induced hepatic fibrosis in rats. *World Journal of Gastroenterology: WJG*, **20**(16),47-53(2014).
16. Pushparaj, P.N., Low, H.K., Manikandan, J., Tan, B.K. and Tan, C.H. Anti-diabetic effects of *Cichorium intybus* in streptozotocin-induced diabetic rats. *Journal of Ethnopharmacology*, **111**(2),430-434(2007).
17. Jalali, A.S., Hasanzadeh, S. and Malekinejad, H. *Achillea millefolium* inflorescence aqueous extract ameliorates cyclophosphamide-induced toxicity in rat testis: stereological evidences. *Chinese Journal of Natural Medicines*, **10**(4),247-254(2012).
18. King BJ, Robertson SM, Wilkins JF, Friend MA. Short-term grazing of lucerne and chicory increases ovulation rate in synchronised Merino ewes. *Animal Reproduction Science*, **121**(3-4),242-248(2010).
19. El-Sayed YS, Lebda MA, Hassinin M, Neoman SA. Chicory (*Cichorium intybus* L.) root extract regulates the oxidative status and antioxidant gene transcripts in CCl4-induced hepatotoxicity. *PLoS one*. **10**(3),e0121549(2015).
20. Kondracki Stanisław, Anna Wysokińska, Magdalena Kania, and Krzysztof Górski. "Application of two staining methods for sperm morphometric evaluation in domestic pigs." *Journal of Veterinary Research*, **61**(3),345-349(2017)
21. Mangoli, E., Talebi, A.R., Anvari, M. and Pouretezari, M. Effects of experimentally-induced diabetes on sperm parameters and chromatin quality in mice. *Iranian Journal of Reproductive Medicine*, **11**(1),p53 (2013).
22. Bustos-Obregon, E., Gonzalez, J.R. and Espinoza, O. Melatonin as protective agent for the cytotoxic effects of diazinon in the spermatogenesis in the earthworm *Eisenia foetida*. *Italian Journal of Anatomy and Embryology= Archivio Italiano di Anatomia ed Embriologia.*, **110**(2 Suppl.1), 159-165(2005).
23. Pina-Guzman, B., Solis-Heredia, M.J. and Quintanilla-Vega, B. Diazinon alters sperm chromatin structure in mice by phosphorylating nuclear protamines. *Toxicology and Applied Pharmacology*, **202**(2), 189-198(2005).
24. Masouleh, F.F., Amiri, B.M., Mirvaghefi, A.R. and Nemtollahi, M.A. In vitro effects of diazinon on male reproductive tissue and sperm motility of Caspian kutum (*Rutilus frisii kutum*). *Research Journal of Environmental Toxicology*, **5**(2),108-116(2011).
25. Sarabia, L., Espinoza-Navarro, O., Maurer, I., Ponce, C. and Bustos-Obregón, E. Protective effect of melatonin on damage in the sperm parameters of mice exposed to diazinon. *Int. J. Morphol.*, **29**(4),1241-1247(2011).
26. Sánchez-Peña, L.C., Reyes, B.E., López-Carrillo, L., Recio, R., Morán-Martínez, J., Cebrían, M.E. and Quintanilla-Vega, B. Changes on sperm chromatin structure in organophosphorus agricultural workers. *Toxicol. Appl. Pharmacol.*, **196**, 108-113(2004).

27. Bobe, J. and Labbé, C. Egg and sperm quality in fish. *General and Comparative Endocrinology*, **165**(3),535-548(2010).
28. Okamura, A., Kamijima, M., Ohtani, K., Yamanoshita, O., Nakamura, D., Ito, Y., Miyata, M., Ueyama, J., Suzuki, T., Imai, R. and Takagi, K. Broken sperm, cytoplasmic droplets and reduced sperm motility are principal markers of decreased sperm quality due to organophosphorus pesticides in rats. *Journal of Occupational Health*, **51**(6),478-487 (2009). DOI: 10.1539/joh.19019.
29. Uzunhisarcikli, M., Kalender, Y., Dirican, K., Kalender, S., Ogutcu, A. and Buyukkomurcu, F. Acute, subacute and subchronic administration of methyl parathion-induced testicular damage in male rats and protective role of vitamins C and E. *Pesticide Biochemistry and Physiology*, **87**(2),115-122(2007).
30. Wang, D., Kamijima, M., Okamura, A., Ito, Y., Yanagiba, Y., Jia, X.F., Naito, H., Ueyama, J. and Nakajima, T. Evidence for diazinon-mediated inhibition of cis-permethrin metabolism and its effects on reproductive toxicity in adult male mice. *Reproductive Toxicology*, **34**(4),489-497(2012).
31. Adamkovicova, M., Toman, R., Cabaj, M., Massanyi, P., Martiniakova, M., Omelka, R., Krajcovicova, V. and Duranova, H. Effects of subchronic exposure to cadmium and diazinon on testis and epididymis in rats. *Scientific World Journal*, **2014**, Article ID 632581, 9 pages (2014). <http://dx.doi.org/10.1155/2014/632581>
32. Akturk, O., Demirin, H., Sutcu, R., Yilmaz, N., Koylu, H. and Altuntas, I. The effects of diazinon on lipid peroxidation and antioxidant enzymes in rat heart and ameliorating role of vitamin E and vitamin C. *Cell Biology and Toxicology*, **22**(6),455-461(2006).
33. Sutcu, R., Altuntas, I., Buyukvanli, B., Akturk, O., Ozturk, O., Koylu, H. and Delibas, N. The effects of diazinon on lipid peroxidation and antioxidant enzymes in rat erythrocytes: role of vitamins E and C. *Toxicology and Industrial Health*, **23**(1),13-17(2007).
34. Alahyary, P., Poor, M.I., Azarbaijani, F.F. and Nejati, V. The potential toxicity of diazinon on physiological factors in male rat. *Pakistan Journal of Biological Sciences*, **11**(1),127-130(2008).
35. Conforti, F., Sosa, S., Marrelli, M., Menichini, F., Statti, G.A., Uzunov, D., Tubaro, A. and Menichini, F. The protective ability of Mediterranean dietary plants against the oxidative damage: the role of radical oxygen species in inflammation and the polyphenol, flavonoid and sterol contents. *Food Chemistry*, **112**(3),587-594(2009).
36. Eftekhaari, E., Fallahi, S. and Malekzadeh, K. Anti-oxidant effects of herbal supplements on seminal parameters. *Iranian Journal of Reproductive Medicine*, **13**(4) Supplement (1), Abstract ,Apr 2. (2015). Abstracts of the 6th Yazd International Congress and Student Award in Reproductive Medicine with 1st Reproductive Genetic Congress.
37. Jamshidzadeh, A., Khoshnoud ,M.J., Dehghani, Z. and Niknahad, H. Hepatoprotective activity of Cichorium intybus L. leaves extract against carbon tetrachloride induced toxicity, *iranian Journal of Pharmaceutical Research (IJPR)*, **5** (1), 41-46 (2006).