

THE AMELIORATING EFFECT OF MENTOFIN® ON RESPIRATORY SYSTEM OF BROILER CHICKENS CHALLENGED WITH *MYCOPLASMA GALLISEPTICUM* STRAIN IN ASSIUT GOVERNORATE

AL SHIMAA, R.SAYED¹; MARWA, A.AHMED²; MOSTAFA, A. SHEHATA³; MOEMEN, A. MOHAMED³; SABRY, I. EISSA⁴ AND MARWA, M. SAFWAT³

¹ Animal Health Research Institute, Assiut.

² Department of Pathology, Faculty of Veterinary Medicine, Aswan University, Egypt.

³ Faculty of Veterinary Medicine, Assiut University.

⁴ Chief Researcher of Mycoplasma Dept. Animal Health Research Institute Agriculture, Research Center, Doki, Giza.

Received: 31 December 2019; Accepted: 31 January 2020

ABSTRACT

The current study was conducted to investigate the impact of Mentofin® in protection of the respiratory system of broiler chickens challenged with *Mycoplasma gallisepticum* (MG) strain. One hundred and five – one day old chicks were randomly divided into three equal groups (35 chicks /group) and reared in isolated rooms. Group (A) MG challenged, Group (B) was treated with Mentofin® and MG challenged and Group (C) control –ve group (not challenged with MG and not treated with Mentofin®). At 1st week of age, an intra-tracheal challenge of the birds with MG strain (containing 1 x 10⁶cfu/ mL/bird) was given to A and B. Mentofin® was administered orally for 6 days, beginning from 8th day of ages to 13th day of ages. Tracheal and lung samples for histopathological examination were collected from chicken at 9th day to 14th day of age and at 28th day of age. In MG-challenged birds (group A) histopathological lesions included mucosal hyperplasia, mucus accumulation, tracheal deciliation, inflammatory cells infiltration and goblet cell hyperplasia in tracheal tissues, moreover, congestion and pneumonic foci in lung tissues. The histopathological lesions of birds treated with Mentofin® and MG challenged (group B) revealed a significant reduction in histopathological lesions in tracheal and lung tissues. Mentofin® was able to reducing respiratory problems, and recommended to be used as a prophylaxis treatment and supportive treatment with antibiotic in cases of *mycoplasma gallisepticum* infection.

Keywords: *Mycoplasma Gallisepticum* isolation, PCR, Mentofin®, Histopathological examination.

INTRODUCTION

Mycoplasma gallisepticum (MG) is the most pathogenic avian mycoplasmas that cause respiratory infection in poultry. *M. gallisepticum* causes chronic respiratory disease (CRD) in chickens and have been reported to cause serious economic losses (Osman *et al.*, 2009). The clinical signs of avian mycoplasmosis are sneezing, coughing, and respiratory rales; ocular and nasal discharge; decreased feed intake and increased morbidity. Increasing mortality in birds with MG infection caused by concurrent bacterial and/or viral infection has been widely reported (Raviv and Kleven, 2009).

Mycoplasma gallisepticum infection has tropism primarily for mucosal membranes of the respiratory tract, conjunctiva and sinuses (Levisohn and Kleven,

2000).The organism usually enters the host via the respiratory tract; upper airways and trachea are the preferred sites of infection for most of the strains of MG (Kleven, 1997).

Mentofin®, a natural herbal product consisting of some essential volatile fatty acids and natural herbal essences (10% eucalyptus oil, 10% menthol, 33% liquid builders, and 47% saponins) Rehman *et al.* (2013). The essential oils of *Eucalyptus* species possess important biological activities including antibacterial, anti-inflammatory, diaphoretic, antiseptic, analgesic effects (Cimanga *et al.*, 2002) and antioxidant properties (Damjanović-Vratnica *et al.*, 2011), and safely used in broiler and layer chicken production, the product was able to help in preventing respiratory disease complexes (Barbour *et al.*, 2005), increasing performance and strengthening the immune system (Bragg, (2004 and 2006); Carli *et al.*, 2008).

The aim of this study was to estimate the Mentofin® effect on respiratory system of Mentofin® treated groups following a challenge with *Mycoplasma*

Corresponding author: Dr. Marwa, M. Safwat
E-mail address: merovet84@gmail.com
Present address: Faculty of Veterinary Medicine, Assiut University.

gallisepticum through gross and histopathological evaluation.

MATERIALS AND METHODS

I-Isolation and Identification of the *Mycoplasma* from birds suspected to be infected:

A) Sampling:

One hundred and twelve (112) samples including lung and trachea were collected from 112 freshly dead and slaughtered broiler chickens showing respiratory manifestation (watery to mucoid nasal discharge, sneezing, gasping, tracheal rales and conjunctivitis) were collected from different localities in Assiut with ages ranged from (20-35 days), weren't vaccinated against *Mycoplasma gallisepticum*.

B) Procedures for isolation of *Mycoplasma* (Sabry and Ahmed, 1975):

Samples were placed on PPLO broth and brought to the laboratory of avian and rabbit diseases Department, Assiut University for subsequent culturing on PPLO media that containing horse serum, dextrose, yeast extract and thallium acetate with penicillin. Broth bottles were incubated at 37°C for 3-4 weeks before being discarded as negative samples; however the agar plates were incubated under reduced oxygen tension in humidified candle treated with Mentofin® (EWABO - Germany) and *MG* challenged, Group C (control -ve group not challenged with *MG* and not treated with Mentofin®). At 1st week of age, an intra-tracheal challenge of the birds with *MG* strain (containing 1 x 10⁶cfu / mL/bird) was given to (A and B) groups. Mentofin® was given to (B) groups.

Essential oils of Mentofin® were administered for 6 days, beginning from 8th day to 13th day of age.

Mentofin® was diluted in V/V of 0.025 mL/100 mL of drinking water. Each treated bird started receiving the diluted Mentofin®, twice a day (morning and evening), in a volume of 1mL/bird/time in the drinking water. Group C (control group not challenged with *MG* and not treated with Mentofin®).

Histopathological examination

Tracheal and lung samples for histopathological examination were collected from chicken at 9th day to 14th day of age and at 28th day of age. Three birds were slaughtered from each group and trachea and lung were collected and fixed in 10% buffered neutral formalin. The fixed tissues were embedded in paraffin, sectioned at 4 µm thick and stained with haematoxylin and eosin H&E (Bancroft and Stevens, 1993). The slides were examined under light microscope.

jar then examined microscopically for *Mycoplasma* colonies after 48 hrs. and daily up to 7-10 days for "fried-egg shape colonies", then subjected to arginine deamination and glucose fermentation tests for biochemical characterization according to (Enro and stipkovits, 1973).

C) Polymerase Chain Reaction (PCR) for detection of *Mycoplasma gallisepticum*:

The extraction of bacterial DNA was performed using QIAamp manual kit according to manufacturer's instructions. Two specific oligonucleotide primers for identification of *M.gallisepticum* were used for detection of *MGc2* specific gene for *M.gallisepticum*. The sequence of primer forward (F) was (5'- CGC AATTTG GTC CTA ATC CCC AAC A-3').The sequence of primer reverse(R) was (5'-TAAACC CAC CTC CAG CTT TAT TTC C-3') (Garcia *et al.*, 2005). Amplification was performed by heating the sample for 4 minutes at 94°C for initial denaturation. After this step forty cycles were performed as follows: Denaturation for 20 sec. at 94°C, annealing for 40 sec. at 58°C and extension for 1 minute at 72°C with the exception of final extension step was held for 7 minutes for final extension. The analysis of PCR amplified products was done by using 8µl of amplified PCR product, mixed with 2µl loading dye and electrophoresed through 1% agarose gel and DNA was visualized by UV fluorescence after ethidium bromide staining.

II- The evaluating effect of Mentofin® on the experimentally challenged birds with isolated *M. gallisepticum*:

Birds: One hundred five–one day old broiler chicks Ross (308) from breeder farm were used in the present study, with an average body weight of 37-40 gm, obtained from El Qusia Assiut. Chicks were housed in a well-isolated floor pens under complete hygienic conditions. Chicks were reared in a complete block design provided with wood shaving litter, plastic feeders and waters. Chicks were fed ad libitum on commercial broiler ration.

Preparation of Challenge Strain:

Isolated field *M. gallisepticum* strain was morphologically, molecularly characterized and subjected to sequencing for detection of partial *16s rRNA gene* with accession number in GenBank (15mgAsyut-Egypt-2016) used in preliminary study after counting using colony forming unit method according to Jett *et al.* (1997) for detection of the pathogenicity and evaluation of Mentofin® as a reducing agent of histopathological lesions which caused by *MG* infection.

Experimental design:

One hundred and five– one day old chicks were randomly divided into three equal groups (35 in each group).Group (A) *MG* challenged, Group (B) was

RESULTS

From 112 trachea and lung pooled samples 6 were suspected to be positive for *Mycoplasma gallisepticum* isolation with incidence rate (5.36%). Microscopically the shape of colony was fried egg

appearance as showing in (fig.1), biochemically glucose fermentation test was positive and negative to arginine. *M. gallisepticum* strain detected by PCR using *MGc2* gene gave a characteristic common band at 300 bp fragment (fig. 2).

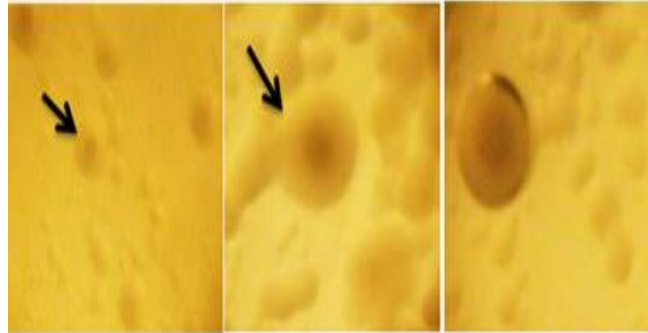


Fig. (1): colonial appearance of *Mycoplasma gallisepticum* isolates by dissecting microscope (fried egg appearance).

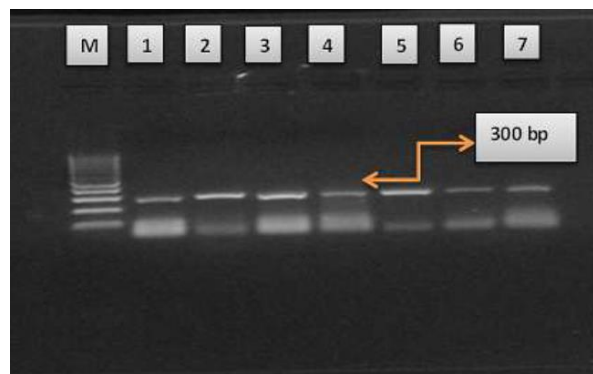


Fig. (2): *Mycoplasma gallisepticum* detected by PCR using *mgc2* gene Positive samples produce band (300 bp), Lane M: 100 bp DNA Ladder, Lane 1, 2, 3, 4, 5, 6 and 7 were positive samples Produce band (300 bp).

Results of experimental infection

Clinical findings in infected group (A) (challenged group), Chicks in infected group were dull, depressed with ruffled feather, coughing and sneezing, nasal discharges and open mouth breathing with moist rales.

Gross Pathology of infected group (A) , trachea showed the evidence of congestion and

hemorrhages. Lung revealed dark red color appearance and congestion (fig.3), air sacculitis was observed in air sacs, these become cloudy thickened and covered with caseous exudates. Gross pathology of group (B), trachea showed no evidence of congestion and hemorrhages. Lung revealed normal color and no congestion. Air sacs appear normal as thin-walled and no cloudiness.

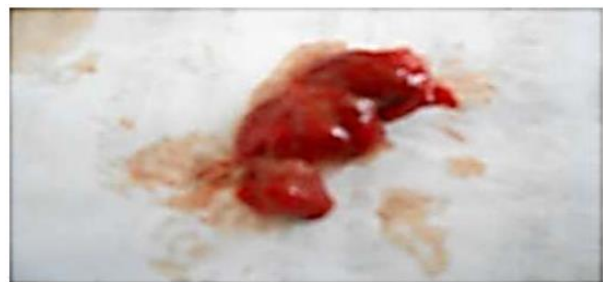

Fig. (3): showing gross pathology of *Mycoplasma gallisepticum* on trachea and lung which represented in congestion and hemorrhages on both tissues

Histopathological evaluation:

The histopathology of the tracheal sections in birds of the challenged group (A) showed mucosal hyperplasia. This microscopic lesion of mucosal hyperplasia was reduced in group (B) Mentofin[®] treated and *MG* challenged as shown in (fig 4a-5a).

Tracheal sections with mucus accumulation in bird challenged group (A) versus clear tissue in tracheal sections of birds treated with Mentofin[®] and *MG* challenged group (B) are shown in (figs 4b-5b).

Tracheal deciliated tissue from a *MG* challenged bird deprived of Mentofin[®] treatment in group (A). There was an apparent reduction in tracheal deciliation in *MG* challenged and Mentofin[®] treated (group B) as shown in (fig 4c-5c).

The inflammatory cells infiltration in lamina propria of tracheal mucosa was reduced in *MG* challenged and Mentofin[®] treated group (B) in comparison to group A- challenged bird deprived of Mentofin[®] treatment as shown in (fig 4d-5d).

Trachea with goblet cell-hyperplasia was observed in group A, (*MG* challenged and deprived of Mentofin[®]) which was absent in Group B, (*MG* challenged and Mentofin[®] treated) as trachea appeared normal with normal goblet cells (fig 4e-5e).

Normal tracheal tissue was showed in group C (control group, not challenged and not treated).

Histopathological examination of the lung revealed marked congestion and pneumonic foci in birds of the challenged group (A), Mentofin[®] caused relieve somewhat histological lesions in lung from mild to no congestion and no pneumonic foci in *MG* challenged and Mentofin[®] treatment group (B) as in (fig 4f-5f).

Normal lung tissue was showed in group C (control group, not challenged and not treated)

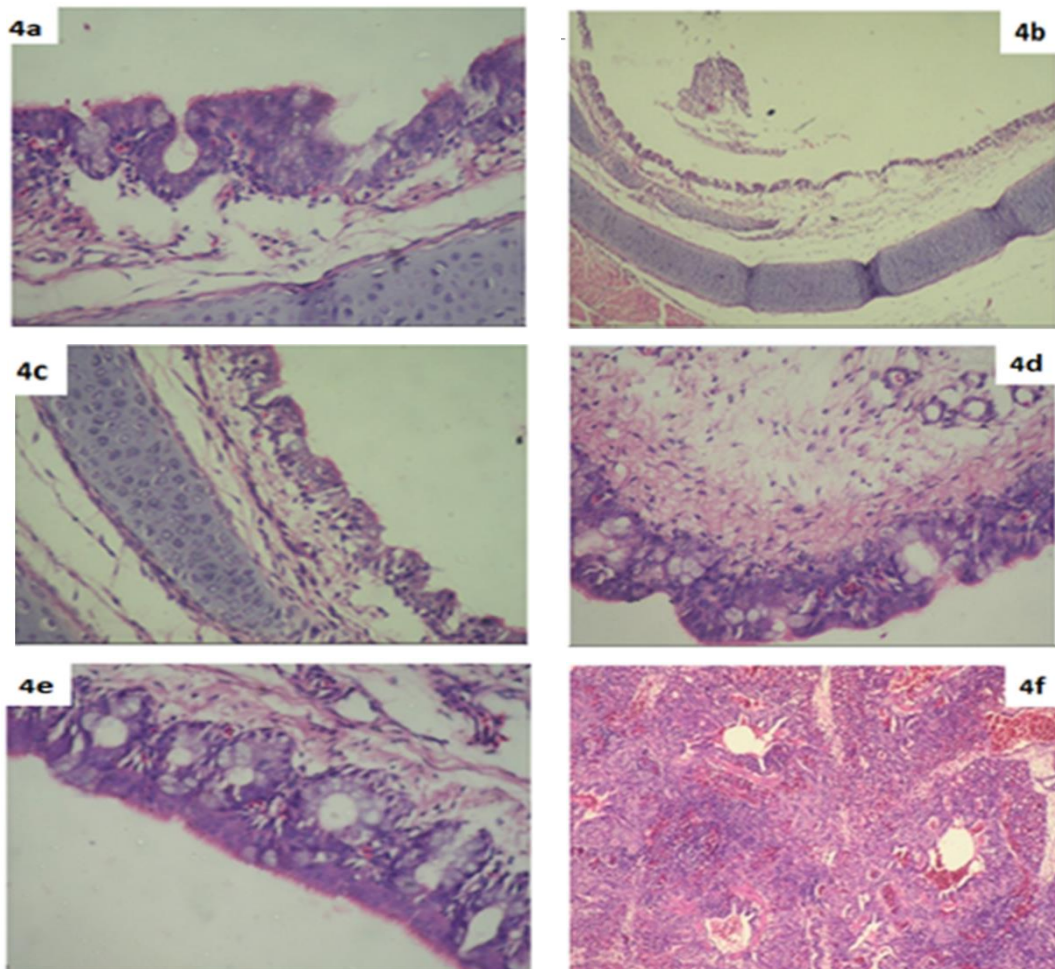


Fig. (4a): Tracheal section showing mucosal hyperplasia in group A (*MG* challenged and Mentofin deprived).

Fig. (4b): Tracheal section showing accumulations of mucus in tracheal lumen in group A (*MG* challenged and Mentofin deprived).

Fig. (4c): Tracheal section showing deciliation in group A (*MG* challenged and Mentofin deprived).

Fig. (4d): Tracheal section showing high inflammatory cells infiltration in group A (*MG* challenged and Mentofin deprived).

Fig. (4e): Tracheal section showing hyperplasia in goblet cells in group A (*MG* challenged and Mentofin deprived).

Fig (4f): Lung section showing multiple pneumonic foci and congestion in group A (*MG* challenged and Mentofin deprived).

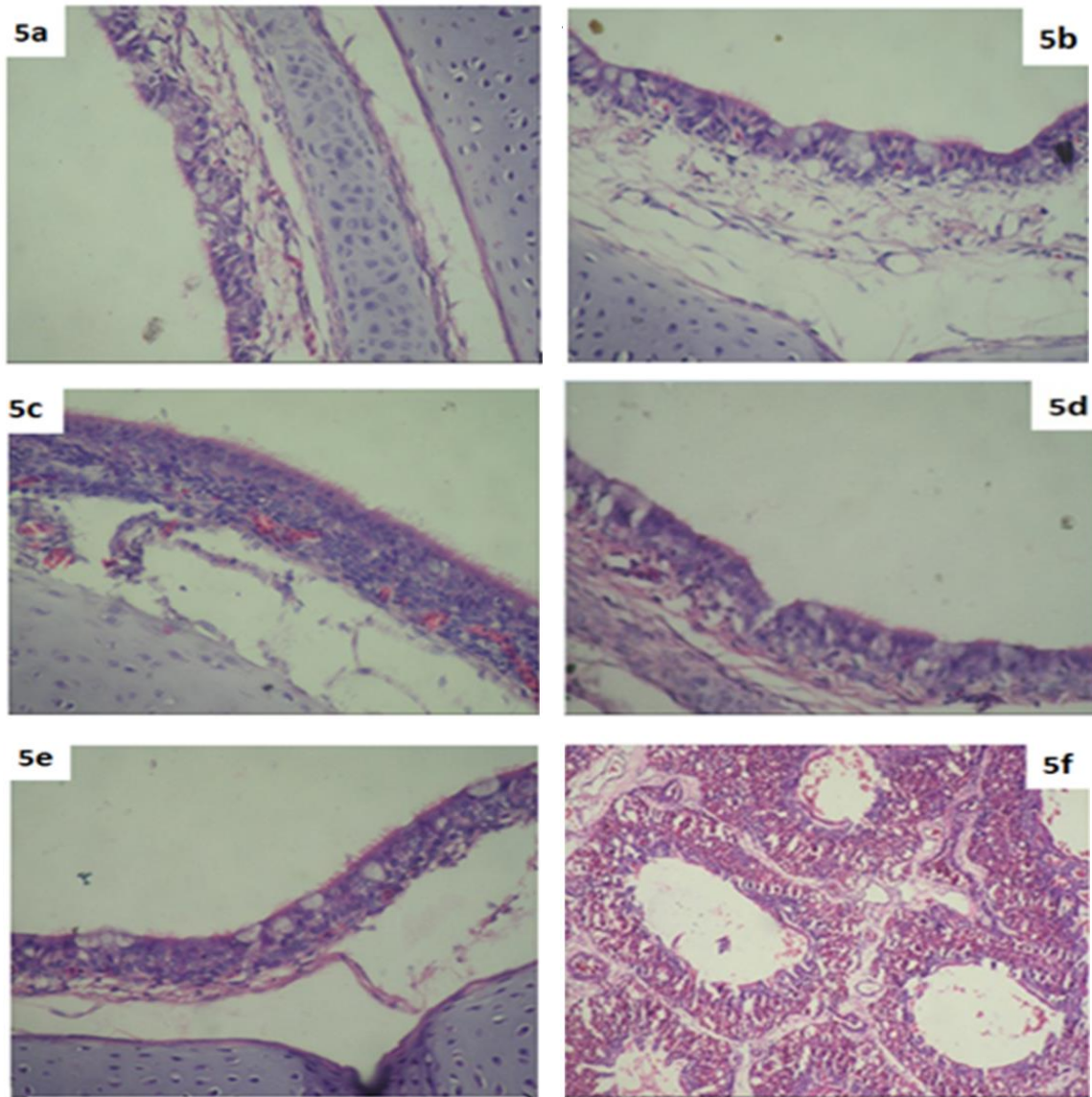


Fig. (5a): Tracheal section showing absence of mucosal hyperplasia in group B (MG challenged and Mentofin treated).

Fig. (5b): Tracheal section showing clear of mucus in tracheal lumen in group B (MG challenged and Mentofin treated).

Fig. (5c): Tracheal section showing normal ciliated in group B (MG challenged and Mentofin treated).

Fig. (5d): Tracheal section showing low inflammatory cells infiltration in group B (MG challenged and Mentofin treated).

Fig. (5e): Tracheal section showing goblet cells within normal in group B (MG challenged and Mentofin treated).

Fig. (5f): Lung section showing no pneumonic foci and no to mild congestion in group B (MG challenged and Mentofin treated)

DISCUSSION

In this study the percentage of isolation and identification of *Mycoplasma gallisepticum* of collected samples (112 lung and trachea) was 5.36 % (6 out of 112 samples). These results accepted with those results of Shaker (1995) who found that the overall isolation rate was 4.04% for *M.gallisepticum*, On the other hand our results do not go hand by hand with those of Stalkecht *et al.* (1998) they could isolate *M.gallisepticum* from naturally

infected chickens through the classical methods at rate of 30%. This confusion may be due to several causes such as number of birds, media used, cultivation and age of birds.

Molecular techniques, such as polymerase chain reaction (PCR), are established and are sensitive, fast and highly specific methods for the detection of *Mycoplasma* (Garcia *et al.*, 2005). Several PCR primers targeting different genes of *MG* were

described previously (Collett *et al.*, 2005) in which *MGc2* one is preferable.

The percentage of samples detected by using *MGc2* gene was (46.88%) 15 out of 32 samples. This result in agreement extent with Gondal *et al.* (2015) who detected of the nucleic acid of *MG* by using PCR from tracheal tissue 42.47% by using specific primer of *MG*. On other hand this result confuses with Eissa *et al.* (2008) who used PCR identification of the obtained isolates of 5 *MG* isolates from broiler chickens (14.25%).

In an examined trial for testing the effect of Mentofin® in reduction of the lesions of *MG* infection, the challenged group (A) exhibited dullness, depression with ruffled feather and various respiratory signs and there were serious involvement of trachea, lungs, air sacs in postmortem examination in opposite to the control group C (not challenged and not treated) that did not exhibit any clinical and pathological changes and similar results reported by Islam *et al.* (2011).

The histopathological changes of trachea in the challenged (group A), were in the form of deciliation, mucosal and goblet Cell hyperplasia, mucus accumulation, and inflammatory cells infiltration. Our results are in concordance with Barbour *et al.* (2006); Khairy *et al.* (2012) and Stipkovits *et al.* (2012), and the pulmonary histopathological changes, were in the form of congestion, pneumonic areas, the obtained results are in agreement with those mentioned by Eissa, (2001); Dardeer *et al.* (2004) and Ahmed (2005). Furthermore, Stipkovits, (1995) mentioned that the *Mycoplasma* enters the respiratory tract and attaches to the cilia and the surface of the epithelial cell lining of the respiratory tract. The *Mycoplasma* produces various toxic metabolites, besides the depletion of the amino acids, fatty acids and DNA precursors. Such products disturb the normal function of the epithelial cells of the mucous membrane of the respiratory tract. A decrease of the excretion of mucus and motility of the cilia or even their destruction can be observed. These factors help the *Mycoplasma* to move down to the lungs and air sacs causing their damage and Volatile oils that existed in Mentofin could be recommended as an alternative natural safe way to the drugs in controlling *MG* infection to overcome the problems of drug resistance and the common drug tissue residues under our field condition (El-Ghany, 2008).

The mechanism by which the volatile oils can relief the respiratory sings was explained by Page, (2004); Zakay-Rones *et al.* (2004) and Salari *et al.* (2006). Those authors suggested that the active ingredients of *Eucalyptus* spp can protect the first line of defense in the poultry host through the thinning of

the mucus in the respiratory tract which could help in its outward flow, pushing with it the microorganisms, preventing their colonization, and thus protecting the cilia from consequent damage.

Concerning to the histopathological findings in group B (which challenged and treated with Mentofin®), revealed the effectiveness of Mentofin® in comparison to group A. Improving in cilia and decreasing hyperplasia in mucosa and goblet cell and clear mucus and low inflammatory cells infiltration were observed of trachea. These results are in accordance with Barbour *et al.* (2006). Who evaluated the histopathological changes of eucalyptus and peppermint oils treated versus deprived broilers subjected to three different natures of challenges (*MG*, H9N2, and a combination of *MG/H9N2*) they found that this treatment resulted in significant decrease in tracheal deciliation in *MG* and *MG/H9N2*-challenged birds, significant decrease in tracheal goblet cells degeneration in *MG*-and *MG/H9N2*-challenged birds, significant decrease in tracheal mucus accumulation in *MG*-challenged birds, and significant decrease in heterophil infiltration in *MG/H9N2*- challenged birds. The previously mentioned authors detected that there is synergism among the active ingredients of *Eucalyptus* spp. And peppermint for providing protection of the goblet cells in the upper respiratory system.

The results concerning to group B in comparison to group A may be presumed due to the action of volatile oils in liquefaction and loosening of the respiratory thick sticky exudates which could be expelled by the birds and consequently reduced the hypoxia, improved breathing and finally increased the feed intake and body weights. In the present study we found that Mentofin® in group B caused relieve to some extent to histopathological lesion in lung.

ACKNOWLEDGMENT

The authors would like to thank Prof. Dr/ Awad Abd El-Hafez Ibrahim, Department of Avian and Rabbit Diseases, Faculty of Veterinary Medicine, Assiut University, for his sincere revision of the paper.

REFERENCES

- Ahmed, NAM. (2005): Experimental pathological studies on some drugs of quinolones group in broiler chicks. M.V.Sc. Thesis, Pathology Dept., Fac. Vet. Med., Zag. Univ.
- Bancroft, J.D. and Stevens, A. (1993): Theory and practice of histologic techniques. 3rd Ed. Long Man Group limited. pp. 113-305.
- Barbour, E.K.; Dankar, S. and Jaber, L. (2005): Essential oils of *Eucalyptus* and peppermint

- improve the homogeneity of immune responses and performance in MG/H9N2-infected broilers. *J Am Holistic Vet Med Assoc*; 24: 23-27.
- Barbour, E.K.; El-Hakim, R.G.; Kaadi, M.S.; Shaib, H.A.; Gerges, D.D. and Nehme, P.A. (2006): Evaluation of the histopathology of the respiratory system in essential oil-treated broilers following a challenge with *Mycoplasma gallisepticum* and/or H9N2 influenza virus. *International Journal of Applied Research in Veterinary Medicine*, 4 (4), 293.
- Bragg, B. (2004): Evaluation of the safety of the continual use of the product, Mentofin for spraying of layer chickens. Evaluation of the safety of the continual use of the product, Mentofin for spraying of broiler chickens.
- Bragg, R.R. (2006): Determination of the minimum inhibitory concentrations (MIC) of Mentofin against Newcastle Disease virus with a 15 min contact period.
- Carli, K.T.; Onat, K. and Gunaydin, E. (2008): Application of Mentofin in broilers with clinical Infectious Bursal Disease to reduce *Escherichia coli* related problems after vaccination against Newcastle Disease. *Turk J Vet Anim Sci*, 32, 73-79.
- Cimanga, K.; Kambu, K.; Tona, L.; Apers, S.; DeBruyne, T.; Hermans, N.; Totte, J.; Pieters, L. and Vlietinck A.J. (2002): Correlation between chemical composition and antibacterial activity of essential oils of some aromatic medicinal plants growing in the Democratic Republic of Congo. *Journal of Ethno pharmacology* 79: 213- 220.
- Collett, S.R.; Thomson, A.D.D.K.; York, A.D.B. and Bisschop, S.P.R. (2005): Floor pen study to evaluate the serological response of broiler breeders after vaccination with TS-11 strain *Mycoplasma gallisepticum* vaccine. *Avian Dis.* 49: 133–137.
- Damjanović-Vratnica, B.; Đakov, T.; Šuković, D. and Damjanović, J. (2011): Antimicrobial effect of essential oil isolated from *Eucalyptus globulus* Labill. From Montenegro. *Czech Journal of Food Science*, 27(3): 277–284.
- Dardeer, M.A.; Yousseif, A.I. and Tantawy, L.A. (2004): Pathological studies on chickens experimentally infected with field strain of *Mycoplasma gallisepticum* and vaccinated with *Mycoplasma gallisepticum* vaccine. *Minufiya Vet. J.*, 3(2): 547-559.
- Eissa, A.M. (2001): Clinico pathological studies on the effect of aivlosin as anti mycoplasmal drug in chickens. PhD Thesis, Clinical Pathology Dept., Faculty of Vet. Med., Zag.Univ.
- Eissa, S.I.; Abd-Elaziz, E.E. and Zienab, R.M. (2008): Study of The Variability Between *Mycoplasma Gallisepticum* Strains Isolated From Broiler Chickens, Turkey And Ducks By Using Random Amplified Polymorphic DNA (RAPD). 9th Vet.Med.,Zag. Conference (20-22) August, Port-Said.
- El-Ghany, W.A.A. (2008): Assessment of the efficacy of certain antibiotics and volatile oils for the treatment of induced *Mycoplasma gallisepticum* infection in broiler chickens. *Journal of the Egyptian Veterinary Medical Association*, 69(1), 283-307.
- Enro, H. and Stipkovits, L. (1973): bovine mycoplasmas, cultural and biochemical studies. *Acta-vet. Scand.*,14: 450-463.
- Garcia, M.; Ikuta, N.; Levisohn, S. and Kleven, S.H. (2005): Evaluation and comparison of various PCR methods for detection of *Mycoplasma gallisepticum* infection in chickens. *Avian Dis.* 49(1): 125- 132.
- Gondal, M.A.; Rabbani1, M.; Muhammad, K.; Yaqub2, T.; Babar , M.E. ; Sheikh1, A.A. ; Ahmad1, A.; Shabbir, M.Z. and Khan, M.I. (2015): Characterization of *Mycoplasma Gallisepticum* isolated from commercial poultry flocks, *The Journal of Animal & Plant Sciences*, 25(1)Page: 108-113, ISSN: 1018-7081.
- Islam, A.; Aslam, A.; Chaudhry, Z. I.; Ahmed, M.U.D.; Rehman, H U.; Saeed, K. and Ahmed, I. (2011): Pathology of *Mycoplasma gallisepticum* in Naturally Infected Broilers and its Diagnosis through PCR. *Prevalence*, 48(22), 46.
- Jett, B.D.; Hatter, K.L.; Huycke, M.M. and Gilmore, M.S. (1997): Simplified agar plate method for quantifying viable bacteria. *Biotechniques* 23, 648–650.
- Khairy, N.; Ammar, A.M.; Eissa, S.I. and Hashem, Y. (2012): Molecular studies on *M. gallisepticum* and avian pathogenic *E. coli* induced infections in broilers. *Zag. Vet. J.*, 40(6): 130- 144.
- Kleven, S.H. (1997): Changing expectations in the control of *Mycoplasma gallisepticum*. *Acta Vet Hung* 45(3): 299–305.
- Levisohn, S. and Kleven, S.H. (2000): Avian mycoplasmosis (*Mycoplasma gallisepticum*). In: Diseases of poultry: world trade and public health implications. C. W. Beard and S. McNulty, eds. Office International des Epizooties, Paris, France. pp. 425–442.
- Osman, K.M.; Aly, M.M.; Amin, Z.M. and Hasan, B.S. (2009): *Mycoplasma gallisepticum*: an emerging challenge to the poultry industry in Egypt. *Rev. Sci. Tech. O.I.E.*, 28(3): 1015-1023.
- Page, L. (2004): *Healthy Healing: A Guide to Self-Healing for Everyone*. 12th ed. Sarasota FL: Book world services, 42-44.
- Raviv, Z. and Kleven, S.H. (2009): The development of diagnostic Real Time TaqMan PCRs for

- the four pathogenic avian mycoplasmas. *Avian Dis*, 53, 103-107, DOI: 10.1637/8600.1.
- Rehman, S.R.; Muhammad, K.; Yaqub, T.; Khan, M.S.; Hanif, K. and Yasmeen, R. (2013): Antimicrobial activity of Mentofin and its effect on antibody response of broilers to Newcastle disease virus vaccine. *The Journal of Animal and Plant Sciences*, 23(4): 1008-1011. *Microbiology* 149:2307–2316. Doi: 12949158.
- Sabry, M.Z. and Ahmed, A.A. (1975): Evaluation of culture procedure for primary isolation of avian Mycoplasmas from female genitalia of farm animals. *J. Egypt, Vet. Med. Ass.*, 35: 18-34.
- Salari, M.H.; Amine, G. and Shirazi, M.H. (2006): Antibacterial effects of *Eucalyptus globulus* leaf extract on pathogenic bacteria isolated from specimens of patients with respiratory tract disorders. *Clin. Microbiol. Infect.*, 12: 194-196.
- Shaker, M.M. (1995): Microbiological studies on mycoplasma infection in poultry. Ph. D. Thesis. Faculty of Vet. Med., Cairo Univ.
- Stalckencht, D.E.; Luttrell, M.P.; Fischer, J.R. and Kleven, S.H. (1998): Potential of the transmission of the finch strain of *M. gallisepticum* between house finches and chickens. *Avian Dis.*, 42: 352-358.
- Stipkovits, L. (1995): The use of antimicrobials in breeders. *International Health Review*, 27:30.
- Stipkovits, L.; Glavits, R.; Palfi, V.; Beres, A.; Egyed, L.; Denes, B.; Somogyi, M. and Szathmary, S. (2012): Pathologic lesions caused by co infection of *Mycoplasma gallisepticum* and H3N8 Low Pathogenic Avian Influenza virus in chickens. *Vet. Pathol.*, 49(2): 273-283.
- Zakay-Rones, Z.; Thom, E. and Wollan, T. (2004): Randomized study of the efficacy and safety of oral elderberry extract in the treatment of influenza A and B virus infections. *J. Intern. Med. Res.*, 32: 132- 140.

التأثير المحسن للمنتوفين على الجهاز التنفسي للدجاج اللحم الذي يواجه تحدياً مع سلالة الميكوبلازما غاليسيتيكوم في محافظة أسيوط

الشيماة رفيق سيد ، مروة احمد احمد ، مصطفى عبد المطلب شحاتة ، مؤمن عبد العظيم ، صبري اسماعيل عيسى ، مروة محمد صفوت

E-mail: merovet84@gmail.com Assiut University web-site: www.aun.edu.eg

أجريت هذه الدراسة لبيان تأثير مركب المنتوفين في حماية الجهاز التنفسي لبداري التسمين تحت عدوتها بيمكروب الميكوبلازما جالسيتيكوم. تم استخدام ١٠٥ ككتوت تسمين عمر يوم واحد من سلالة روس ٣٠٨ من إنتاج شركة اسيوط للاستثمار وقد قسمت الطيور الي ٣ مجموعات المجموعة الاولى (A) تمت عدوتها بالميكوبلازما المجموعة الثانية (B) عولجت بالمنتوفين وتمت عدوتها بالميكوبلازما المجموعة الثالثة (C) تركت كمجموعة ضابطة بدون عدوي او علاج وبعمل الفحوصات الباثولوجية النسيجية للمجموعة الاولى (A) التي تمت عدوتها بالميكوبلازما وجد تراكم المخاط بالقصبة الهوائية مع تدمير اهدابها وحدوث زيادة في عدد الخلايا الكاسية وهي الخلايا المسؤولة عن افراز المخاط مع ظهور التهابات بالقصبة الهوائية بالاضافة الى حدوث زيادة في عدد خلايا الغشاء المخاطي المبطن للقصبة الهوائية علاوة على ذلك وجدنا التهاب واحتقان في أنسجة الرئة. اما بالنسبة للمجموعة الثانية (B) التي تم علاجها بالمنتوفين بعد اصابتها معمليا بالميكوبلازما جالسيتيكوم وجد انخفاض كبير في الافات المرضية في أنسجة القصبة الهوائية والرئة.