

## **yEndoscopic-Assisted Laparoscopic Management of Hepatic Hydatid Cyst**

**Mohamed Ismail Seleem<sup>1</sup> and Sameh M. Seif<sup>2</sup>**

1-Department of Hepato-bilio-pancreatic Surgery

2-Tropical Medicine Department,

National Hepatology and Tropical Medicine Research Institute

Cairo-Egypt

### **Abstract**

**Background :** Because of limited experience, controversies still exist about the laparoscopic management of hepatic hydatid cysts. In this study, we are presenting our early experience with this new technique of endoscopic-assisted laparoscopic management of hepatic hydatid cyst compared with open surgery.

**Patients and Methods:** Between January 2000 and July 2010 fifteen patients (12 males and 3 females) with hepatic hydatid cysts were referred from gastro-entriology unit at National Hepatology and Tropical Medicine Research Institute. All patients had a single, large hepatic hydatid cyst. Patients received a preoperative course of Albendazole for one month. Six patients underwent open surgery and nine patients underwent EAL technique. All patients in the EAL group had pre-operative ERCP to rule out any biliary communication. Operative time, hospital stay, post-operative complications and follow-up were recorded.

**Results:** Mean operative time was 206 minutes in the open surgery group compared with 110 minutes in EAL group. The mean hospital stay was 22.3days in open group and 8days in EAL group. All patients required insertion of intra-abdominal drain. At a maximum follow-up of 9 years, only two patients developed post-operative bile leak in the open group and treated conservatively.

**Conclusion:** We concluded that endoscopic-assisted laparoscopic technique is a safe, simple and promising methods with a potentially low risk of intra-abdominal spillage compared with open surgery.

**Key words:** Hydatid cyst, hepatic, endoscopic, laparoscopic.

### **Abbreviations:**

EAL (Endoscopic-Assisted Laparoscopic)

ERCP(Endoscopic retrograde cholangiopancreatography)

WHO(World Health Organization)

PAIR(percutaneous aspiration , injection & reaspiration)

## Introduction

Hydatid cyst is a parasitic disease; the majority of cases are caused by *Echinococcus (E) granulosus*. Hydatid disease is still endemic in certain geographic areas. It is the most common cause of liver cysts in the world and had become a worldwide health problem. Migration and inter-continental travel help to spread the disease being prevalent in other countries. The liver is the most commonly involved organ followed by the lung (*Sayek I, 1983*). Without treatment cysts grow and may eventually form fistulas into adjacent organs or rupture into the peritoneal cavity requiring emergency surgery (*Chavtem et al., 1983*). Older cysts have an increased risk of exogenous daughter cyst formation, which is an important factor for recurrence of disease after surgery (*Guntz M, 1973*) (*Magistrelli et al., 1991*) (*Slaoui & Settaf, 1992*) (*Kammerer & Schantz, 1993*). Medical therapy is insufficient to cure the disease, although stabilization has been reported with albendazole alone or combination with praziquantel. (*Nahmias et al., 1994*) (*Luchi et al., 1997*) (*Mohamed et al., 1997*) (*Franchi et al., 1999*). Multiple modalities of treatment of hydatid cyst, from percutaneous drainage, to surgery either open or laparoscopic (*Chavtem et al., 1983*). Surgery remain the cornerstone of radical treatment for cystic echinococcosis (*Amman & Echert, 1995*). Hepatic hydatid cysts have been subjected to laparoscopic surgery since 1992 (*Mompean et al., 1993*). However, the controversies about the laparoscopic treatment of liver hydatidosis have not been resolved. The choice of therapy depends on several factors: general condition of the patient, numbers and localization of the cyst, the surgeon's expertise, and the type of hospital where such surgery is performed, including the possibility of intensive post – operative care. The objectives of any surgical treatment are (a) inactivation of scolices, (b) protection of spillage of cyst contents, (c) elimination of all viable elements of the cyst, and (d) management of the residual cavity of the cyst (*Iskender &*

*Demiral, 2001*) We developed (created) a new EAL technique for the treatment of hepatic hydatid cysts, which fulfils all the objective criteria for surgery. The aim of this study is to present of our new technique and to evaluate the safety and efficacy of this technique compared to open technique.

## Patients and Methods

Fifteen patients (12 males and 3 females) with mean age 46 years (range, 18-62y), were referred with solitary hepatic hydatid cyst. All were submitted to full history and clinical examination, routine blood investigation included hydatid titre. All patients had chest X ray (to exclude chest hydatidosis), abdominal ultrasonography and computed tomography. The stage of the disease was determined according to *Gharbi et al.* ultrasound classification; (stage I, pure fluid collection; stage II, collection with split wall; stage III, fluid collection with septa; stage IV, heterogeneous echogenicity; stage V, reflecting thick walls). The both surgical techniques were explained to all patients (patient has his own right to chose the technique followed by consent). ERCP is mandatory for EAL group (to rule out biliary communication). All patients were received pre-operative course of Albendazole (10mg/kg) for one month which was continued for three months post-operatively. All patients were received prophylaxis dose of 1.5gm Cefuroxime on induction. The operative time, hospital stays, complication were recorded.

### EAL –technique.

The procedure was performed with the patient under endotracheal general anaesthesia and placed in a supine position on operating table. The surgeon stood on the right side of the patient and the first assistant on the opposite side. The monitors will be placed at the head of the table. Through an infra-umbilical incision. Carbon dioxide pneumoperitoneum will be carried out using Veress needle. In patients with prior open abdominal operations, the abdominal

cavity will be entered by using the open technique of Hasson . Laparoscopic exploration will be performed with a zero degree laparoscope. Another 10mm port will be placed according to the location of the cyst, with addition of another 5mm port, if needed. After localization and release of adhesions using electrocautery on curved scissors or with Harmonic scalpel (Ethicon Endo-Surgery, Inc, Cincinnati, Ohio). The selection area for aspiration will be packed off with 4'' x 4'' pieces of gauze soaked in hypertonic saline solution (16.5%) and introduced through the 10mm port. The cyst fluid will be aspirated with a 50-ml syringe attached to a needle, an equivalent volume of hypertonic saline (16.5%) will be re-injected into the cyst. After 10-minute waiting period to inactive the cyst contents, another aspiration – injection carried out. A guide wire will be introduced through the aspirating needle followed by the nephroscopic dilators (figure-1). Using the nephroscopic suction, the contents of the cyst and the germinative membrane will be aspirated under direct vision. The cavity will be irrigated with hypertonic saline solution (16.5%). A final exploration will be made using laparoscope and the cyst wall partially excised by using electrocautery on curved scissors or with Harmonic scalpel (figure-2) .

Omental pedicle flap will be used to pack the cavity and a suction drain will be left behind. Drains will be removed depending on the amount of drainage. All patients underwent post-operative abdominal ultrasonography before removal of the drains to exclude any collection. Patients will be evaluated initially at 3 months, the six monthly abdominal ultrasonography or computed tomography.

## Results

Mean operative time was 206 min in the open surgery group compared with 110 min in EAL group. The mean hospital stay was 22.3 days in open surgery group and 8 days in EAL group. All patients required insertion of intra-abdominal drain in both

groups. At a maximum follow-up of 9 years, two patient developed post-operative bile leak in the open group and treated conservatively. One patient in EAL group was difficult to be completed and converted to open surgery, because of many scolices (figure-3). This patient was presented after 6 months with recurrence, he required another attempted of open surgery. One patient presented after failure of three attempt of percutaneous aspiration drainage technique, for Hydatid cyst at segment VII who operated with EAL technique successfully. Neither wound infection nor mortality was recorded.

## Discussion

Hydatidosis is endemic in the Mediterranean region. In humans, 50-75% of hydatid in the liver, 25% are found in the lungs, and 5 – 10% are distributed along the arterial system (*Barnes & Lillemoe, 1997*) .In principle, all tissues can be affected, however, in around 80% of patients a solitary cyst occurs in one organ(*Pawlowski et al., 2001*) .In this series, all cases were a solitary hepatic cyst, 3 cases were in left lobe and 12 cases were in the right lobe of the liver.

Allergic reactions are also encountered in open procedures(*Bilge & Sozuer, 1992*) and even gross spillage in patients with ruptured hydatid cysts causes mild allergic symptoms in 17% to 25% of the cases(*Gunay et al., 1999*) .Our technique decreases the risk of allergic reactions caused by peritoneal spillage during debridement and removal of cyst contents, but still there is a need for safer techniques for initial cannulation of the cyst, although we did not encounter any spillage with the use of the nephroscope instrument.

It is well known that, albendazole, a broad spectrum anthelmintic drug, is effective for preventing recurrence and secondary hydatidosis(*Gunay et al., 1999*) ,the safety and efficacy of this drug have been shown in various studies, however, there is no consensus on the duration of use of the medication for cyst sterilization. The required duration of medical treatment has not been definitively determined but is no less than 3 months(*WHO, 1996*) .We

follow the WHO guidelines, pre-operative treatment with chemotherapy should begin at least 4 days to one month Albendazole before surgery(WHO, 1996).In the present study, albendazole 10 mg/kg/ day was used for one month preoperative and 3 months following the surgical procedure to prevent recurrence. Although several scolicidal agents such as hypertonic saline solution , formalin, silver nitrate, povidone-iodine, cholrhexidine, and a combination of cetrimide and cholrhexidine, have been used for the purpose of in activation, there is no consensus on which is the best agent(Sozuer *et al.*, 2002) .We use to irrigate the cysts cavity with hypertonic saline (16.5% sodium chloride) followed by isotonic saline in our cases. During surgery the administration of scolicidal agents into the cyst cavity, should performed and after a waiting period of 10-15 minutes, the cavity should be aspirated; followed partial or, total cystectomy should be performed(Erel *et al.*, 2008) .In the current study, all of our patients received conservative surgical interventions. Partial cystectomy was performed in all patients. Both external tube drainage and omentopexy were performed for cavity management in our patients.

Complications of hepatic hydatid cysts are perforation of the cyst, either internally or externally as a result of increased intracystic pressure and secondary bacterial infection (Sayek & Onat 2001). In hydatid cysts of the liver, spontaneous or traumatic perforation into the peritoneum can occur in 2-7% of the cases, followed by secondary infection, jaundice, and an anaphylactic reaction(Barnes & Lillemoe, 1997) .One case in this series was presented with symptoms and signs of perforation after a trial of percutaneous drainage. The laparoscopic approach has the usual advantage of being less invasive, leading to a shorter hospital stay and reduced wound complication; however, the recent reports on PAIR are encouraging for management of uncomplicated cyst. (Akcan *et al.*, 2007)(Filice & Brunetti 1997).

Akcan *et al.*, reported that liver cysts grow as much as 2 cm per year, and nearly 5 years is required for recurrence. Recurrences before this period are probably cysts that had been missed during exploration . In the present study, one case of recurrence was happen after six months. We do think it was because of spillage. There was no mortality in the present series, although in ideal conditions the operation mortality rate ranges from 0.9% to 3.6% (Adrien, 2001). We concluded that endoscopic-assisted laparoscopic technique is a safe, simple and promising methods with a potentially low risk of intra-abdominal spillage compared with open surgery.

## References

- Adrien G.S. (2001): Medical treatment of liver hydatidosis. *World J. Surg.*;25,15-20
- Akcan A, Akyildiz H, Artis T, Ozturk A, Deneme MA, Ok E, et al.(2007): Peritoneal perforation of liver hydatid cysts:clinical presentation, predisposing factors, and surgical outcome. *World J Surg*;31:1284-1291
- Amman R, Echert J(1995): Clinical diagnosis and treatment of echinococcosis in humans. In *Echinococcosis and hydatid disease*, Thompson, R.C.A., Lymbery, A.J.,editors, Oxford, CAB International, pp.411-463.
- Barnes SA, Lillemoe KD(1997): Liver abscess and hydatid cyst disease.In:Zinner MJ, Schwartz SI, Ellis H, editors. *Maingot's Abdominal Operations*.10<sup>th</sup> ed. Stamford (CT):Appleton & Lange;1997.p.1513-1545.
- Bilge A,Sozuer E.M.(1992): Diagnosis and surgical treatment of hepatic hydatid disease. *HPB Surg.*;6:57-64.
- Chavtems R, Buhler L, Gold B, Chilcott M, Morel P, Mentha G.(2003): Long term results after complete or incomplete surgical resection of liver hydatid disease. *Swiss Med Wkly*;133:258-262
- Erel S,Kilicoglu B, Kismet K, Gollu A, Akkus MA.(2008): Peritoneal hydatid cyst perforation:a rare cause of emergency abdominal surgeries. *Adv Ther*;25:943-950
- Filice C, Brunetti E.(1997): Use of PAIR in human cystic echinococcosis. *Acta Trop*;64:95-107
- Franchi C, Di vico B, Teggi A.(1999): Long- term evaluation of patients with hydatidosis treated with benzimidazole carbamates. *Clin Infect Dis*; 29:304-309.

- Gharbi H.A., Hassine W., Brauner M.W., Dupuch K.(1981): Ultrasound examination of hydatid liver. *Radiology*; 139:459.
- Guntz M.(1973): Les bases anatomo-physiopathologiques du traitement chirurgical du kyste hydatique du foie. *Min Chir*; 28:708.
- Gunay K., Taviloghe K., Berber E., Ertekin C.(1999): Traumatic rupture of hydatid cyst: 12-years experience from an endemic region. *J. Trauma*;46:164-167
- Iskender S, Demiral O.(2001):Diagnosis and treatment of uncomplicated hydatid cyst of the liver. *World J.Surg.*;25:21-27
- Kammerer WS, Schantz PM.(1993):Echinococcal Disease. *Infect Dis Clin North Am*; 7:605-618.
- Luchi S, Vincenti A, Messina F, Parenti M, Scasso A, Campatelli A. (1997):Albendazole treatment of human hydatid tissue. *Scand J Infect Dis*; 29:165-167.
- Magistrelli P, Masetti R, Coppola R, Messina A, Nuzzo G, Piciocchi A. (1991):Surgical treatment of hydatid disease of the liver: a 20 year experience. *Arch Surg*; 126:518- 522.
- Mohamed AE, Yasawy MI, Al Karawi MA. (1998): Combined albendazole and praziquantel versus albendazole alone in the treatment of hydatid disease. *Hepatogastroenterology*; 45:1690-4.
- Mompean JAL, Paricio PP, Campas RR, Ayllon JG.(1993):Laparoscopic treatment of a liver hydatid cyst. *Br J Surg*.;80:907-908
- Nahmias J, Goldsmith R, Soibelman M(1994): el-On J. Three-to-7 year follow –up after albendazole treatment of 68 patients with cystic echinococcosis (hydatid disease). *Am Trop Med Parasitol*; 88:294-304.
- Pawlowski ZS, Eckert J, Vuitton DA, Ammann RW, Kern P, Craig PS, et al(2001): Echinococcosis in humans: clinical aspects, diagnosis and treatment. In: Eckert J, Gemmell MA, Meslin FX, in humans and animals: a public health problem of global concern. Paris(FR): World Organisation for Animal Health and World Health Organisation;p.20-71
- Sayek I. (1983):Hydatid disease of the liver. *Hacettepe Med J*; 16: 84-92
- Sayek I, Onat D.(2001): Diagnosis and treatment of uncomplicated hydatid cyst of the liver, *World J Surg*;25:21-27. Review.
- Slaoui A, Settaf A.(1992): Chirurgie des kystes hydatiques du foie. Casablanca: *edition Ideale*;
- Sozuer EM,Ok E, Arslan M. (2002):The perforation problem in hydatid disease. *Am J Trop Med Hyg*;66:575-577
- WHO Informal working group on echinococcosis(1996): Guidelines for treatment of cystic and alveolar echinococcosis in humans. *Bull.W.H.O.*;74:231

## Figures


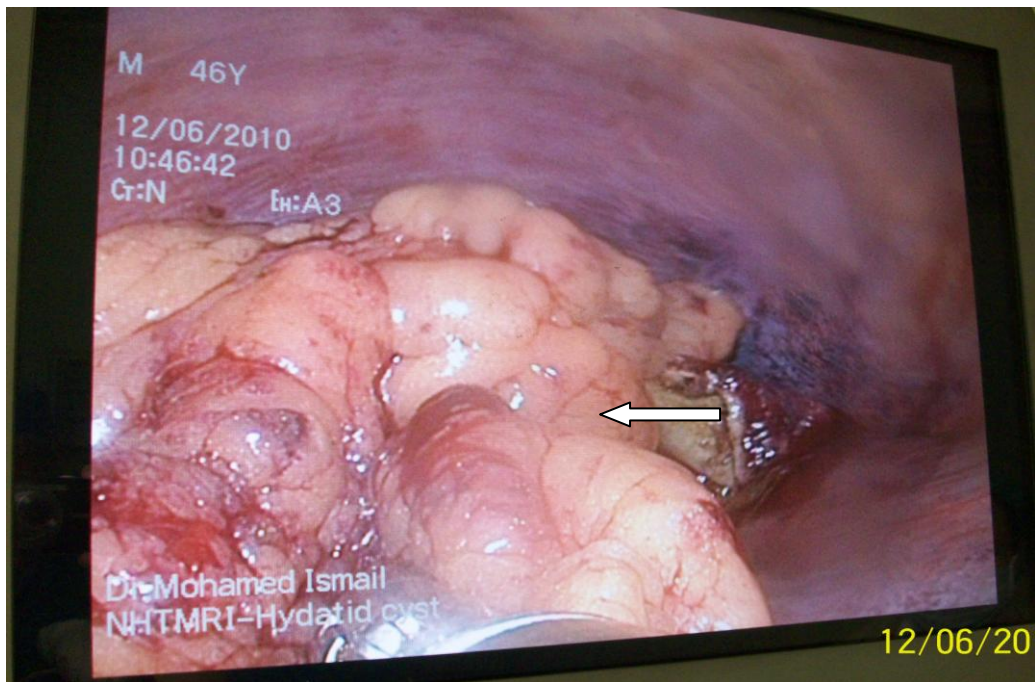


Figure-1: The nephroscopy instrument.



*Figure-2: The arrow is pointed at the margin of the cyst after partial excision and packed with omental flap.*



*Figur-3: A lot of scoliosis removed from the converted case.*

## استخدام المنظار الجراحي كوسيلة علاجية لتفريغ أكياس هايداتيد الكبدية

محمد اسماعيل سليم<sup>1</sup>, سامح محمد سيف الدين<sup>2</sup>

- 1- قسم جراحة الكبد والجهاز الهضمي والقنوات المرارية
  - 2- قسم الأمراض المتوطنة
- المعهد القومي لأبحاث الأمراض المتوطنة والكبد-القاهرة

### المقدمة والهدف من الدراسة:

تعتبر الخبرة المحدودة لإستخدام المنظار الجراحي في علاج أكياس الهايداتيد الكبدية عائقاً أمام توسيع استخدام هذه الطريقة العلاجية مقارنة بالشق الجراحي المعتاد , لذا فإن هذه الدراسة تطبق إستخدام المنظار الجراحي مع عدد من الحالات المصابة .

تم إجراء هذه الدراسة ما بين عامي 2000-2010 على 15 مريض (12 رجل و 3 سيدات ) مصابين بكيس هايداتيد وحيد في الكبد , تم إعطاؤهم جميعاً عقار ألبيندازول لمدة شهر قبل الجراحة وتم تقسيمهم الى مجموعتين:

المجموعة الأولى : وتشمل ستة مرضى تم عمل تفريغ للكيس باستخدام الشق الجراحي المعتاد  
المجموعة الثانية : وتشمل تسعة مرضى تم عمل تفريغ للكيس باستخدام المنظار الجراحي

### نتائج الدراسة :

أثبتت هذه الدراسة أمان وفاعلية تفريغ أكياس هايداتيد الكبدية باستخدام المنظار الجراحي مقارنة بالشق الجراحي المعتاد