

## **Hepatic Expression of the Proliferative Marker Ki-67 and cell cycle p53 Protein in chronic hepatitis C (A histopathological and immunohistochemical study)**

**Azza Hegazy<sup>1</sup>, Nashwa A. Zaki<sup>2</sup> Sameh seif<sup>3</sup> and Nagwa Abd-Wahab<sup>4</sup>**

Pathology<sup>1</sup>, Biochemistry<sup>2</sup>, Tropical Medicine<sup>3</sup> & Community Medicine<sup>4</sup>  
Departments, National Hepatology and Tropical Medicine Research Institute

### **Abstract**

#### **Aim and background:**

To evaluate hepatic expression of the nuclear proliferative marker Ki-67 and the cell cycle marker p53 oncoprotein in chronic hepatitis C in relation to the advanced stages of liver fibrosis in HCV positive Egyptian patients.

#### **Material & Methods:**

Paraffin-embedded liver biopsy specimens were studied from 21 untreated patients with chronic HCV infection. All patients were HCV antibody positive, as determined by a commercially available enzyme-linked immunosorbent assay kit. Patients having other etiologies for chronic liver disease including HBV infection were not included in this study. Liver biopsies were obtained percutaneous. All biopsies were fixed in formalin, embedded in paraffin, and sectioned by microtome with a thickness of 5 µm. Routine specimen processing involved staining slides with hematoxylin and eosin (5 levels), Masson's trichrome stain (5 levels), for a total of 10 levels per specimen. All levels were screened. All specimens were examined by two pathologists, and classified by consensus for all abnormal histological findings. The histological activity index (or histological grade) was determined using Ishak grading scheme<sup>22</sup> expressed as a semiquantitative score for portal inflammation (0-4), lobular activity sporadic lytic foci (0-4) and parenchymal confluent necrosis (0-6), and piecemeal necrosis(0-4). The extent of fibrosis (or histological stage) was determined using Ishak score (0-6). Steatosis was scored according to **Keliner et al 2005**, from grade 0 to 3; where S0 = no steatosis or less than 5% (low or medium power evaluation) of parenchymal involvement by fatty changes, S1 (mild) = 5%-33%, S2 (moderate) = >33%-66% and S3 (severe) > 66% of the hepatocytes are involved by fatty changes. Expression of p53 and Ki67 were determined by immunohistochemistry, using avidin-biotin-peroxidase.

#### **Results:**

Liver histology: The studied group (n = 21) involved 16 males and 5 females (male to female ratio 3.3:1). The histopathological findings of HCV infection, including portal lymphoid infiltration, periportal piecemeal necrosis, lymphocyte infiltration of the lobules, hepatocellular necrosis, steatosis and fibrosis, were studied. The age ranged from 31 to 59 years old with mean of 44.86 ± 8.74, males 76.2%, females 23.8%. P53 expression was positive in 52.4% and negative in 47.6%. cytoplasmic localization dominated over nuclear expression. Ki 67 was negative in 81% of cases and positive in 19%

of cases, all cases in stage 6 were positive for p53 while there were no difference in the other stages of fibrosis, and this relation was statistically significant.

There was no relation between the grade of necro-inflammation and the expression of p53, and this result was statistically non significant. There was a relation between the percent of

steatosis and the expression of p53 as percent of positivity increases with the increase of the percent of steatosis, and this result was statistically significant using independent sample t test and regression test. All negative cases for P53 have negative Ki67 but this rule is not applied on positive cases for P53, and this relation was not statistically significant

There was no relation between the grade of necro-inflammation and the expression of Ki67, and this result was statistically non significant.

### Conclusion:

Hepatic expression of the nuclear proliferative marker Ki-67 and the cell cycle marker p53 oncoprotein in chronic hepatitis C in relation to advanced stages of liver fibrosis in HCV positive patients are expressed in a considerable present of cases which should be candidates for follow up for early detection of hepatocellular carcinoma.

### Introduction

Chronic hepatitis HCV infection is a major risk factor for the development of hepatocellular carcinoma (HCC) through a multistep pathway that involves viral and non-viral-dependent pathophysiological steps (Idilman ; et al 1889), (Nakamoto; et al 1998), (Koike ;et al 1999). HCV, an RNA virus, exerts its oncogenic effect by inducing a mutator phenotype through the action of its proteins (Matsubara et al 1990), (Moriya et al., 1998) ., (Machida et al ., 2004). Increased DNA synthesis *per se* is not sufficient to induce carcinogenesis unless genetic alterations, induced by various factors, appear and gradually accumulate, the nuclear proliferative marker Ki-67 was found to be related to dysplastic liver changes and hepatocellular carcinoma (HCC). (Ledda-Columbano et al., 1996) ., (Wong et al., 1999). One of the genes, most extensively studied in animal and human hepatocarcinogenesis, is the *p53* tumour suppressor gene. (Tabor et al., 1997). *P53* encodes a nuclear phosphoprotein that controls normal cell proliferation, DNA repair and apoptotic cell death. (Cox et al.,1995), ( Jacks et al., 1996 ). The wild-type *p53* protein has a short half-life and is expressed in very low amounts, precluding its detection by immunohistochemical approaches under normal conditions. ( Porter et al., 1992).

However, exposure of cells to a variety of stress factors, results either in an increased rate of synthesis and stability of wild *p53*, or mainly in the production of a mutated protein with a longer half-life, which may

become detectable by immunohistochemistry. (Porteret al., 1992) .,(Cox et al.,1995), (Livni llan Y et al.,1995), (Jacks et al., 1996 ), (Tabor et al., 1997),. Mutations of *p53* are common in human HCC, vary considerably in different geographical regions, ranging from 10 to 60% in incidence and have been associated with histological grade, size of tumour and age of the patients. (Jaskiewicz et al.,1995) .,(Tabor et al., 1997), (Qin, et al., 1997). Overexpression of *p53* in HCC is not necessarily correlated with mutations of the gene. (Bourdon et al., 1995), (Kang et al., 1998). The development of HCC seems to be preceded by foci of altered hepatocytes. These foci are composed of differentiated liver cells that show characteristic metabolic and molecular aberrations and gradually progress via various intermediate forms to a malignant phenotype (Farber et al., 1992). In this setting, the proposed sequence of hepatocarcinogenesis is evolving through chronic hepatitis/cirrhosis to small foci of dysplasia, a low/high-grade dysplastic nodule and finally to HCC. Morphologically the dysplastic nodule is characterized by zones of cells with increased nuclear density and rarely foci of decreased reticulin staining and isolated glandular structures (International working Party,1995).

### Patients and Methods

Paraffin-embedded liver biopsy specimens were studied from 21 untreated patients with chronic HCV infection. All patients

were HCV antibody positive, as determined by a commercially available enzyme-linked immunosorbent assay kit. Patients having other etiologies for chronic liver disease including HBV infection were not included in the study.

Liver biopsies were obtained percutaneous, ultrasound-guided by a Menghini needle 14G with 1.6 mm internal diameter. All biopsies were fixed in formalin, embedded in paraffin, and sectioned by microtome with a thickness of 5  $\mu$ m. Routine specimen processing involved staining slides with hematoxylin and eosin (5 levels), Masson's trichrome stain (5 levels), for a total of 10 levels per specimen. All levels were screened. All specimens were examined by two pathologists, and classified by consensus for all abnormal histological findings. The histological activity index (or histological grade) was determined using Ishak grading scheme (Ishak et al.,1995) expressed as a semiquantitative score for portal inflammation (0-4), lobular activity sporadic lytic foci (0-4) and parenchymal confluent necrosis (0-6), and piecemeal necrosis(0-4). The extent of fibrosis (or histological stage) was determined using Ishak score (0-6). Steatosis was scored according to (Kelliner et al 2005), from grade 0 to 3; where S0 = no steatosis or less than 5% (low or medium power evaluation) of parenchymal involvement by fatty changes, S1 (mild) = 5%-33%, S2 (moderate) = >33%-66% and S3 (severe) > 66% of the hepatocytes are involved by fatty changes.

### Immunohistochemistry

Expression of p53 and Ki67 were determined by immunohistochemistry, using avidin-biotin-peroxidase. Sections on coated slides were dewaxed in xylene, taken through ethanol to water to rehydrate. The sections were microwaved in 10  $\mu$ m sodium citrate buffer (pH 6,0) at 10 min intervals for a total of 20 min. Endogenous peroxidase activity was blocked by incubating the sections in a solution of 3% hydrogen peroxide for 20 minutes at room temperature. After washing in PBS the

sections were incubated with the primary monoclonal mouse anti-human Ki67 (1:50), monoclonal mouse anti-human p53, clone DO7 (Dako) (1:100), overnight at 4 C°. The sections were washed with PBS and incubated with a biotinylated secondary antibody for 30 minutes, followed by incubation with streptavidine-biotin-peroxidase complex (DAKO) for further 30 minutes, at room temperature. Staining was carried out using a solution 3-3'diaminobenzidine (DAB-Sigma), containing 1% hydrogen peroxide and lightly counterstained with Harris hematoxylin.

Sections known to express high levels of p53 and Ki67 were included as positive controls, while negative control slides omitted the primary antibody. Ki67 labelling index was determined by observing 100 nuclei in areas of the section with the highest labelling rates, and was considered positive when 10% or more of cells were stained<sup>24</sup>. The sections were judged positive for p53 when 5% or more cells were stained as described by (Nakamura et al 2005 and Meara et al.,2007).

### Results

Liver histology: The studied group (n = 21) involved 16 males and 5 females (male to female ratio 3.3:1). The histopathological findings of HCV infection, including portal lymphoid infiltration, periportal piecemeal necrosis, lymphocyte infiltration of the lobules, hepatocellular necrosis, steatosis and fibrosis, are shown in table ( 1 ).

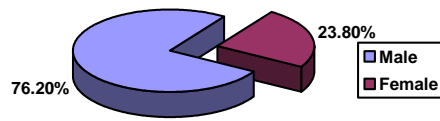
The age ranged from 31 to 59 years old with mean of  $44.86 \pm 8.74$ , males 76.2%, females 23.8% .

P53 expression was positive in 52.4% and negative in 47.6%. cytoplasmic localization dominated over nuclear expression as was also found by Xinwei et al.,2006<sup>27</sup>.

Ki 67 was negative in 81% of cases and positive in 19% of cases, Figures 1-4.



## Hepatic Expression....



**Table (2)** showed that all cases in stage 6 were positive for p53 while there was no difference in the other stages of fibrosis, and this relation was statistically significant.

**Table (3)** showed that there was no relation between the grade of necro-inflammation and the expression of p53, and this result was statistically non significant.

**Table (4)** showed that there was a relation between the percent of steatosis and the expression of p53 as percent of positivity increases with the increase of the percent of steatosis, and this result was statistically significant using independent sample t test and regression test.

**Table (6)** showed that all negative cases for P53 have negative Ki67 but this rule is not applied on positive cases for P53, and this relation is not statistically significant

**Table (7)** showed that there was no relation between the grade of necro-inflammation and the expression of Ki67, and this result was statistically non significant.

**Table ( 1 ): Showing the expression of P53 & Ki-67 in chronic hepatitis C patients:**

Serial No	Sex	Age	Portal	Periportal	Lytic	Confluent	Steatosis	NI	Fibrosis	P53	Ki-67	Dysplasia
001	F	31	3	2	2	2	40%	9/18	6	+	+	-
002	M	37	3	3	2	0	10%	8/18	6	+	-	-
003	M	45	3	3	2	0	10%	8/18	6	+	-	-
004	M	50	3	3	2	1	10%	9/18	6	+	+	-
005	M	40	2	2	2	0	30%	6/18	6	+	-	-
006	F	47	2	2	2	0	5%	6/18	6	+	-	-
007	M	43	3	3	2	2	5%	10/18	6	+	+	-
008	M	55	3	3	2	1	10%	9/18	5	+	-	-
009	M	56	3	2	2	2	20%	9/18	5	+	-	-
010	M	50	3	2	2	1	5%	8/18	5	-	-	-
011	F	35	2	1	3	0	5%	6/18	5	-	-	-
012	M	36	2	1	2	2	0	7/18	5	-	-	-
013	M	39	4	2	3	1	0	10/18	5	-	-	-
014	M	51	2	2	2	0	5%	6/18	5	-	-	-
015	M	48	2	2	2	0	10%	6/18	4	-	-	-
016	f	33	2	1	2	0	0	5/18	4	-	-	-
017	M	38	1	0	1	0	0	2/18	4	+	-	-
018	F	37	1	1	1	0	5%	3/18	4	+	-	-
019	M	54	2	1	2	0	0	5/18	4	-	-	-
020	M	59	3	2	3	1	0	9/18	4	-	--	-
021	M	58	4	4	2	3	10%	13/18	4	-	+	-

**Table (2): Relation between p53 and stage of fibrosis**

Stage of fibrosis	P53				P value
	Positive		Negative		
	N	%	N	%	
4	2	28.6	5	71.4	< 0.05
5	2	28.6	5	71.4	
6	7	100	0	0	

**Table (3): Relation between P53 and NI grade**

NI grade	P53				P value
	Positive		Negative		
	N	%	N	%	
2/18	1	100	0	0	> 0.05
3/18	1	100	0	0	
5/18	0	0	2	100	
6/18	2	40	3	60	
7/18	0	0	1	100	
8/18	2	66.7	1	33.3	
9/18	4	66.	2	33.3	
10/18	1	100	0	0	
13/18	0	0	1	100	

**Table (4): Relation between p53 and percent of steatosis**

Steatosis	P53				Total N
	Positive		Negative		
	N	%	N	%	
0%	1	16.7	5	83.3	6
5%	3	50	3	5	6
10%	4	66.7	2	33.	6
20%	1	100	0	0	1
30%	1	10	0	0	1
40%	1	100	0	0	1

Steatosis	P 53		Significance
	Positive	Negative	
Mean ±SD	13.18±12.1	3.5±4.11	< 0.05
Std. Error	3.65	1.3	

Hepatic Expression....

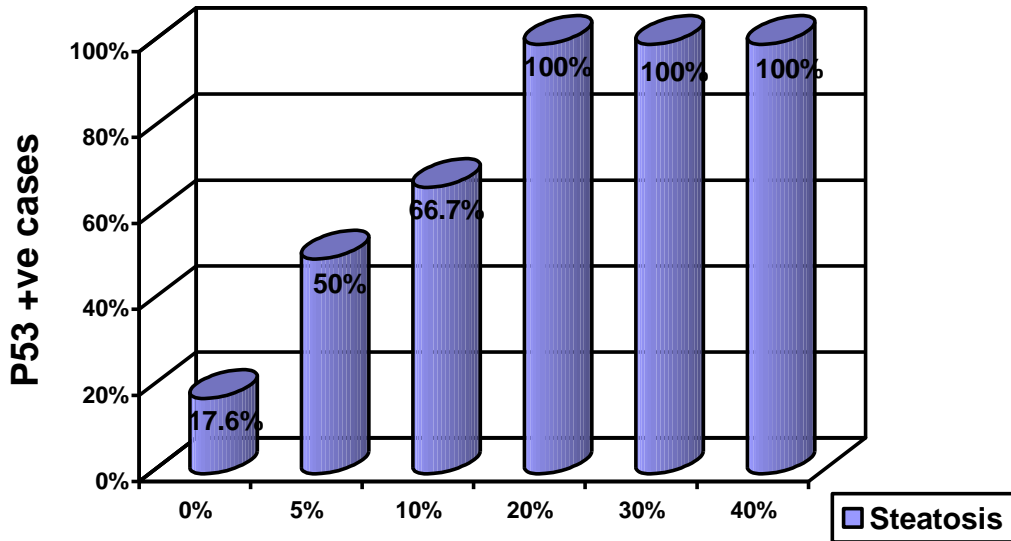


Table (5) : Relation between Ki 67 and stage of fibrosis

Stage of fibrosis	Ki 67				P value
	Positive		Negative		
	N	%	N	%	
4	1	14.3	6	85.7	> 0.05
5	0	0.0	7	100	
6	3	42.9	4	57.1	

Table (6): Relation between p53 and Ki-67

		Ki-67				P value
		Positive		Negative		
		N	%	N	%	
P53	Positive	3	27.3	8	72.7	> 0.05
	Negative	1	10	9	90	

**Table (7): Relation between Ki-67 and NI grade**

NI grade	Ki-67				P value
	Positive		Negative		
	N	%	N	%	
2/18	0	0	2	100	> 0.05
3/18	0	0	1	100	
5/18	0	0	2	100	
6/18	0	0	3	60	
7/18	0	0	3	100	
8/18	0	0	1	33.3	
9/18	2	33.3	4	66.7	
10/18	1	100	0	0	
13/18	1	100	0	0	

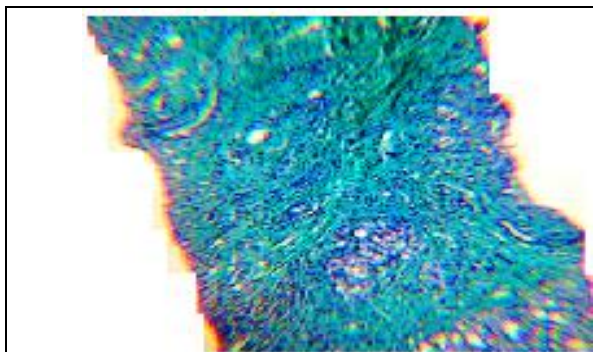


Figure ( 1 ): Showing a case of chronic hepatitis with advanced fibrosis. Masson's trichrome stain (X100).

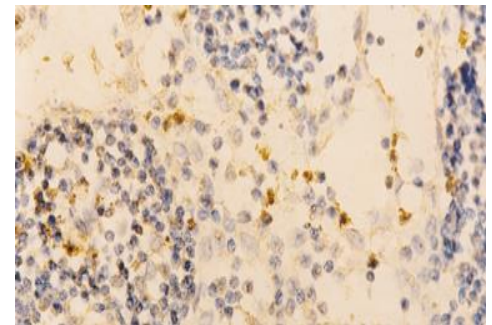


Figure ( 2 ): Showing a case of chronic hepatitis expressing Ki67 protein (X100).

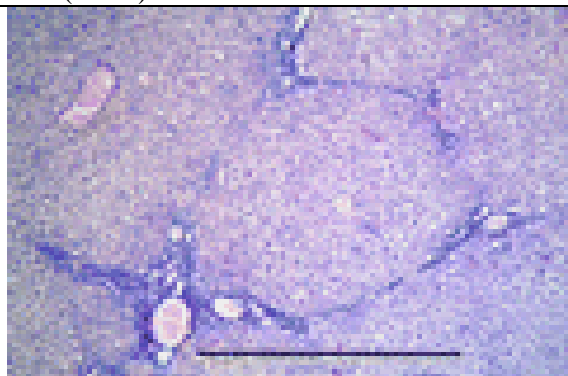


Figure ( 3 ): Showing a case of chronic hepatitis, stage 6 fibrosis, H&E (X100).

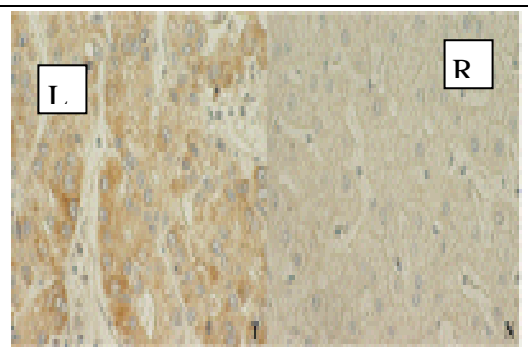


Figure ( 4 ): Showing a case of chronic hepatitis expressing positive cytoplasmic staining of P53 protein (Left ), on the right negative staining (X100).



## Discussion

Hepatitis C virus (HCV) infection account for a vast majority of viral hepatitis cases in many geographical areas. Since patients currently asymptomatic with relatively mild disease will eventually progress to the end stage liver disease and develop hepatocellular carcinoma (HCC). Currently, there is no vaccine against HCV and antiviral treatment is not only expensive but relatively toxic and is sufficiently ineffective in treating all of the patients (Anthony P et al., 1978). This underscores the need for more effective therapies. A better understanding of the molecular mechanisms underlying the pathology of chronic HCV infections could be helpful in identifying novel therapeutic targets against the disease .

The hallmarks of chronic HCV infection in the liver are inflammation, necrosis, hepatocellular damage and fibrosis . The damage caused by inflammation and necrosis leads generally to proliferation of the remaining hepatocytes ,a characteristic of liver regeneration (Rehermann et al., 2005). Proliferative responses of hepatocytes to HCV infection are particularly important in subsequent pathogenesis as hepatocytes are the primary site of HCV replication and receive different cellular stresses from lymphocytes and kupffer cells. Several studies have measured proliferative activity in liver tissue from patients with chronic HCV infection using a variety of markers such as Ki-67 (Anzola et al., 2004)., (Arima et al., 2001)..

The molecular events during proliferation are related closely to cell cycle and its regulation. When stimulated to proliferate, hepatocytes first enter the G1 phase of the cell division cycle which is followed by DNA synthesis, or S phase. Progression through each phase of the cell cycle involves periodic activation of phase-specific protein kinase complexes. Compressing of cyclones and cyclin dependent kinases (CDKs) (Basu et al., 2002)., (Kao et al., 2004) .

Cyclin –CDK complexes are known to be regulated negatively by CDK inhibitors (CKIs), which are induced in response to

different stimuli including DNA damage and oxidative stress. One such inhibitor is the P21 (WAF/CIP1)p21 protien that binds to various cyclin –CDK complexes the activity of CDK in both P53-dependant and P53 independent fashion (Sato et al., 2006).,(Moriya et al., 1998). So P53 is of relevance while studying the HCV induced disease. Expression of the cell cycle regulator P53 in patients with HCV was observed in 52.4% of our cases. It was found to be associated with the fibrosis stage and not to the inflammation grade as was also moticed by (Abdel Fattah et al., 2009) and in contrary to (Siara et al., 2008) Who found P53 expression is weakly associated with inflammation grade and not with fibrosis stage.

As regards steatosis P53 Positivity increased with the increase of the percent of steatosis and this result was statistically significant, in contrast to (Siara et al.,2008) who found no significant association between this cell cycle regulator and the degree of steatosis.

Ki 67 protein was negative in 81% of cases and positive in 19% of cases and they were mostly of stage 6. We observed the relationship of Ki67 with fibrosis statistically insignificant as was also noticed by (Koskinas et al., 2005) .,(Aldora et al., 2007).

**Conclusion :** hepatic expression of the nuclear proliferative marker Ki-67 and the cell cycle marker p53 oncoprotein in chronic hepatitis C in relation to advanced stages of liver fibrosis in HCV positive patients are expressed in a considerable present of cases which should be candsidates for follow up for early detection of hepatocellular carcinoma.

## References

- Abdel Fattah M, Attallah, Gamal E, Shiha, Hisham Ismail et al (2009):** Expression of P53 protein in liver and sera of patients with liver fibrosis liver cirrhosis or hepatocellular carcinoma associated with chronic HCV infection. *Clinical Biochemistry* Vol. 42, (6),445-461.
- Aldora K, Agnieska A and Wieslawa B et al ., (2007):** Intracellular expression of the proliferative marker Ki 67 and viral proteins in

- chronic long lasting (HCV) infection. *Folia Histochemica*, Vol 45.(4.)337-336.
- Anthony PP, Ishak K, Nayak NC. Et al., (1978):** The morphology of cirrhosis. *J Clin Pathol*; 31:395-414.
- Anzola M, Saiz A, Cuevas N, et al (2004):** High levels of p53 protein expression do not correlate with p53 mutations in hepatocellular carcinoma. *J Viral Hepatitis* 2004;11:502.
- Anzola M. et al (2004):** Hepatocellular carcinoma: role of hepatitis B and hepatitis C virus proteins in hepatocarcinogenesis. *J. Viral Hepat.* 11:383-393.
- Arima N, Kao CY, Licht Padmanabham R, Sasaguri Y, Padmanabhan R et al (2001):** Modulation of cell growth by the hepatitis C nonstructural protein Ns5A. *J Biol Chem.* 276:12675-12684.
- Basu A, Meyer K, Ray R et al (2002):** Hepatitis C virus core protein is necessary for the maintenance of immortalized human hepatocytes. *Virology.*, 298:53-62.
- Bourdon JC, d'Errico A, Paterlini P et al., (1995):** P53 protein accumulation in European hepatocellular carcinoma is not analysis dependent on P53 gene mutation. *Gastroenterology*, 108:1176-1182.
- Cox LS, Lane DP(1995):** How P53 regulates the cell cycle in response to DNA damage *Biassays*; 1995;17:501-508.
- Farber E, (1992):** On cells of origin of liver cell cancer. In: Sirica AE, ed. *The Role of cell types in hepatocarcinogenesis*. Boca patients, FL: CRC, 1-28.
- Idilman R, De Maria N, Colantoni A, Van Thiel DH et al (1989):** Pathogenesis of hepatitis B and C Induced hepatocellular carcinoma. *J. Viral hepat*; 5:285-299.
- International Working Party et al., (1995):** Terminology of nodular hepatocellular lesions, *Hepatology*; 22:983-993.
- Ishak K, Baptitra A & Biachil (1995):** Histopathologic grading and staging of chronic hepatitis. *J Hepatology*; 22:696-699.
- Jacks T, Weinberg RA et al., (1996):** Cell cycle control and its watchman *Nature.*, 381:643-644.
- Jaskiewicz K, Banach L, Lzycka E. et al., (1995):** Hepatocellular carcinoma in young patients: histology, cellular differentiation, HBV infection and oncoprotein P53. *Anticancer Res*; 15:2723-2725.
- Kang YK, Kim CJ, Kim HO et al., (1998):** P53 mutation and overexpression in hepatocellular carcinoma and dysplastic nodules in the liver. *Virchows Arch*; 423: 27-32.
- Kao CF, Chen SY, Chen JY, Lee YHW et al (2004):** Modulation of P53 transcription regulatory activity and post-translational modification by hepatitis C virus core protein. *Oncogene* : Vol. 24:2472-2483.
- Keliner DE, Brunt EM & Van Natta M (2005):** Non-alcoholic steatohepatitis: Clinical research network design and validation of histopathological scoring system. *Hepatology.* 41:1313-1321.
- Koike , Transgenic et al (1999):** Mouse models of viral hepatitis : insight into viral hepatocarcinogenesis *Viral Hepato Rev.* 5:177-203.
- Konkinas J., Petraki N and Kavanatzas T et al., (2005):** Hepatic expression of the proliferative marker Ki67 and P53 protein in HBV or HCV cirrhosis in relation to dysplastic liver cell changes and hepatocellular carcinoma, *Journal of Viral Hepatitis*, 12(6): 635-641.
- Ledda-Columbano GM, Shinozuka H, Katyal SL et al., (1996):** Cells proliferation, cell death and hepatocarcinogenesis. *Cell death Dif*; 3:17-22.
- Livni N, Eid A, Ilan Y et al.,(1995):** P53 expression in patients with cirrhosis with and without hepatocellular carcinoma *Cancer*;75:2420-2426.
- Machida K, Cheng KT, Sung VM et al ., (2004):** Hepatitis C virus induces a mutator phenotype: enhanced mutative of immunoglobulin and protooncogenes. *Proc Nat.Sct (MSA)* 101(12):4262-4267.
- Matsubara K, Tokino T. et al (1990):** Integration of hepatitis B viral DNA and its implications hepatocarcinogenesis *Mol. Biology Med*; 7:243-260.
- Meara RS, Cangiarella J and Simsir A. (2007):** Prediction of aggressive gastrointestinal stromal tumors based on immunostaining with locl-2, Ki 67 and P53. *Cytopathology*; 18:283-9.
- Moriya K, Fujie H, Shintani Y et al (1998):** The core protein of hepatitis C virus induces hepatocellular carcinoma in transgenic mice. *Nature Med.*, 9:1065-1067.
- Moriya K, Fujie H, Shintani Y et al., (1998):** The core protein of hepatitis C virus induces hepatocellular carcinoma in transgenic mice. *Nat Med* .,4:1056-1067.
- Nakamoto Y, Guidotti LG, Kuhlen CV et al (1998):** immunopathogenesis of hepatocellular carcinoma. *J. Exp. Meol*; 188:341-350.
- Nakamura N, Yamamoto H & Yao T. (2005)** Prognostic significance of expressions of cell-cycle regulatory proteins in gastrointestinal stromal tumors relevance of the risk grade. *Human pathol*: 36:828-37.
- Porter PL, Gown A, Kramp SG et al., (1992):** Widespread P53 overexpression in

## Hepatic Expression....

human malignant tumors: an immunohistochemical study using methacarn-fixed, embedded tissue. *Am J Path*; 140:145-153.

**Qin G, Su J, Ning Y et al., (1997):** P53 expression in patients with hepatocellular carcinoma from the hyoh in cadence area of quangxi, southern China. *Cancer*; 121:203-210.

**Rehermann B, Nascimbeni M et al (2005):** Immunology of hepatitis B virus and hepatitis C virus infection. *Nature Rev*.5:215-229.

**Saira Sar FraZ, Saeed Hamid and Anwar Siddiqui et al., (2008):** Altered expression of cell cycle and apotitic proteins in chronic hepatitis C Virus Infections: 8-133, 1471-2180.

**Sato Y, Kato J, Takimoto R et al (2006):** Hepatitis C virus core protein promotes proliferation of human hepatoma cells through enhancement of transforming growth factor alpha expression via activation of nuclear factor-kappa B. *Gut*. 55:1801-1808.

**Skopelitou A, Hadjiyannakis M, Alexopoulou V et al., (1996):** P53 expression

in hepatocellular carcinoma in greace correlation with epidemiological and histopathological data. *Res Pract* ; 192:1100-1106.

**Tabor E. et al., (1997):** The role of tumor suppressor genes in the development of hepatocellular carcinoma. *Liver (Cancer. New Yourk): Churchill :Livingstone*, PP:In 89-95.

**Tannapfel A, Wasner M, Krause K et al., (1999):** Expression of P53 and its relation to histopathology and carcinogenesis hepatocellular carcinoma. *J. Natl Cancer Inst .*, 91: 1154-1158.

**Wong N, Lai P, Lee S-W et al., (1999):** Assessment of genetic changes in hepatocellular carcinoma by compared genomic hbridization analysis. Relationship to disease stage, tumor size and cirrhosis. *Am . J Pathol.*, 154:37-43.

**Xinwei., Tatsuo, Shuminw, et al (2006):** Cytoplasmic expression of P53 protien and its morphological features in salivary glands. *Journal of Oral pathology and Medicine . Vol. 24 (5):201-205.*

## الكشف عن Ki 67 و P53 فى كبد المرضى المصريين المصابين بالفيروس (سى)

عزه السيد حجازى<sup>1</sup> - نشوى أحمد زكى<sup>2</sup> - سامح محمد سيف - نجوى عبدالوهاب

المعهد القومى للأمراض المتوطنه الكبد

### المقدمه وهدف البحث:

تتطور الإلتهابات المزمنه فى الكبد الى مراحل تبدأ من ألتهايات عاديه الى ألتهايات مصحوبه بتكوين أنسجه ليفيه ثم الى مرحله متقدمه وهى تليف كامل بالكبد وقد تكون مصحوبه بأورام سرطانيه فى بعض الأحيان

يهدف هذا البحث الى دراسه التغيرات الباثولوجيه المصاحبه للفيروس سى فى كبد بعض المرضى المصريين المصابين بهذا الفيروس والذين تمت متابعتهم فى المعهد القومى للأمراض المتوطنه والكبد بالقاهره بأستخدام دلائل الأورام ( Ki 67 و P53 )

### المرضى وطرق البحث:

- تتضمن هذه الدراسه عدد 21 مريضاً تتراوح أعمارهم بين 31-59 عاماً منهم 16 رجل و 5 إمراه ثبتت أصابتهم جميعاً بفيروس سى من خلال الكشف عن الأجسام المضاده للفيروس وكذلك الكشف عن الفيروس نفسه عن طريق فحص عينات الدم (PCR) وتم أستبعاد أى سبب أخر للإلتهابات المزمنه فى كبد هؤلاء المرضى عن طريق الكشف الإكلينيكى والتحليل اللازمه.

- تم أخذ عينه كبديه من جميع المرضى وتم إرسالها لمعمل الباثولوجى لعمل قطاعات مناسبه على مستويات مختلفه وتم صبغها بالصبغات العاديه والصبغات الخاصه بالأنسجه الليفيه لتحديد درجه الإلتهابات ومرحله التليف فى هؤلاء المرضى. وتم صبغة الأنسجه بدلائل الأورام ( Ki 67 و P53 ) .

### النتائج:

أظهرت النتائج أن 52.4% من الحالات كانت إيجابيه لكاشف الأورام P53 وكانت له علاقة إيجابيه مع تقدم حالات التليف وليس حالة الإلتهاب كما كانت العلاقه أيضاً إيجابيه مع زيادة درجه تدهن الكبد أما بالنسبه لدلائل الأورام Ki 67 فكانت سلبيه فى 81% من الحالات إيجابيا فى 19% منها وكانت معظم الحالات الإيجابيه من المرطله السادسه من تليف الكبد وهذا يقودنا الى أنه ينصح بأستخدام هذان الكاشفان فى مراحل التليف المتقدمه للكشف عن الأستعداد المبكر للتحويل لسرطان الكبد.