

Assessment of vitreoretinal interface and clinically significant macular edema by OCT and fluorescein angiography

Hany Ali Yahia ⁽¹⁾, **Sawsan A Shalaby**⁽²⁾, **Elham A Hassan**⁽²⁾ ,
Wafaa A Madbouly ⁽²⁾, **Nihal Adel Hassan**⁽³⁾

Tanta Hospital of Ophthalmology ⁽¹⁾ Ophthalmology department, Faculty of medicine (for Girls), Al Azhar University. ⁽²⁾ Ophthalmology department, Faculty of medicine, Cairo University. ⁽³⁾

Abstract:

Objective: To assess the changes occurring at the vitreoretinal interface with clinically significant macular edema using optical coherent tomography (OCT) and fundus fluorescein angiography (FFA).

Patients and Methods: Ninety nine eyes of 84 patients suffering from macular edema of different etiologies were included in this study. They were divided according to the cause of macular edema into 6 groups. Treatment modalities were done to be evaluated in the follow up. All cases were followed up at regular visits one week, one month, and six months with routine ocular examinations. FFA and OCT changes were determined and evaluated at one month and 6 months after treatment.

Results: In diabetic group (40 eyes), there were 22 eyes with different stages of PVD seen by OCT in comparison to 5 eyes only demonstrated by FFA, ERM seen by OCT of different stages in 14 eyes while in FFA 10 eyes only, In the RVO group (15 eyes), there were 6 eyes with different stages of PVD seen by OCT in comparison to no eyes demonstrated by FFA, In the IGS group (10 eyes), there were 3 eyes with different stages of PVD seen by OCT in comparison to no eyes demonstrated by FFA, In the CNV group (17 eyes), there were 4 eyes with different stages of PVD seen by OCT in comparison to no eyes demonstrated by FFA, ERM seen by OCT of different stages in 3 eyes while in FFA one eye only, In the RP group (10 eyes), there were 2 eyes with different stages of PVD seen by OCT in comparison to no eyes demonstrated by FFA. In the TME group (7 eyes), there were 3 eyes with different stages of PVD seen by OCT in comparison to no eyes demonstrated by FFA, ERM seen by OCT and FFA of different stages in 4 eyes.

Conclusions: OCT provided us with valuable information on the retinal morphologic changes associated with ME of different etiologies and analyzing vitreomacular relationship and detecting macular SRD undetectable on biomicroscopy and FFA.

Keywords: PVD (posterior vitreous detachment), ERM (epiretinal membrane), RVO (retinal vein occlusion), IGS (Irvin gas syndrome), CNV (Choroidal neovascularization), SRD (serous retinal detachment), RP (retinitis pigmentosa), TME (tractional macular edema), ME (macular edema).

Introduction

The vitreoretinal interface assessment has been greatly aided by the development of the vitreoretinal interface in the development of macular edema. Intraretinal fluid can accumulate when there is loss of functional integrity in either of the blood retinal barriers and/or loss of an effective RPE pump⁽²⁾.

The causes of vision impairment in cases with macular edema may be mechanical, optical, or cellular in nature⁽³⁾.

Pathologic conditions causing macular edema may be, Inflammatory as IGS and uveitis, retinal vascular diseases as DR and RVO, Choroidal vascular disease as CNV, Drug reactions, Inherited retinal dystrophies as RP, Tractional maculopathies, Retinal detachment, Intraocular tumors, Optic nerve head abnormalities and Idiopathic⁽⁴⁾.

The fundus fluorescein angiogram is clinically the most widely available and useful test. It permits study of the circulation of the retina and choroid in normal and diseased states⁽⁵⁾.

Optical coherence tomography is a noninvasive, non-contact, trans-pupillary imaging technology (requires only a 3-mm pupil for adequate visualization), allows measurement of retinal thickness from the tomograms, Detection of vitreoretinal interface anomalies that couldn't be detected by biomicroscopy or FFA. It produces cross-sectional images (tomograms) of optical reflectivity in the retina in a way like the ultrasound B-scan^(6,7)

The Spectral Domain OCT has faster data acquisition time and hence improved resolution for the retinal images, with improvements in photoreceptors layer visualization that support more understanding of visual dysfunction in a variety of retinal pathologic features⁽⁸⁾.

The aim of this study was to assess the changes occurring at the vitreoretinal interface with clinically significant macular edema using OCT as diagnostic and follow

optical coherence tomography (OCT). Gaucher et al.,⁽¹⁾ supported the importance

up procedure with (FFA), and evaluating additive data taken by OCT over FFA.

Subjects and Methods

Eighty four patients (99 eyes) suffering from macular edema of different etiologies were included in this study. All cases underwent history taking, complete ophthalmic examination (best-corrected visual acuity (BCVA), slit lamp examination of the anterior segment, applanation tonometry, slit-lamp biomicroscopy for assessment of macular edema and the state of posterior hyaloid in relation to the macula, FFA, and spectral domain OCT).

Exclusion criteria included, ocular conditions in which visual acuity would not improve after resolution of macular edema (e.g., foveal atrophy, dense subfoveal hard exudates), cataract, history of treatment for macular edema, history of major ocular surgery, and systemic diseases as chronic renal failure, and myocardial infarction.

According to the cause of macular edema, the treatment was applied and, the cases were grouped into 6 groups:

Group I (Diabetic group): 40 eyes, who received intravitreal injection of 4 mg triamcinolone acetonide followed by laser photocoagulation after 2 weeks.

Group II (RVO group): 15 eyes (8 with BRVO and 7 with CRVO), received intravitreal injection of bevacizumab (Avastin) 1.25 mg in 0.05 mL followed by laser photocoagulation in cases with branch vein occlusion

Group III (Pseudophakic group): 10 eyes received intravitreal injection of 4 mg triamcinolone acetonide.

Group IV (CNV group): 17 eyes. received intravitreal bevacizumab (Avastin)

Group V (RP group): 10 eyes received oral acetazolamide 500 mg daily.

Group VI (Tractional ME): 7 eyes with macular edema secondary to vitreoretinal interface abnormalities that were referred to vitreoretinal surgeon.

All patients were followed up at regular visits one week, one month, and six months with routine ocular examinations. FFA and OCT changes were determined and evaluated at one month and 6 months after treatment.

Results

This study was carried out on (99) eyes with CSME of (84) patients and were classified into six groups according to the cause of macular edema (figure, 1).

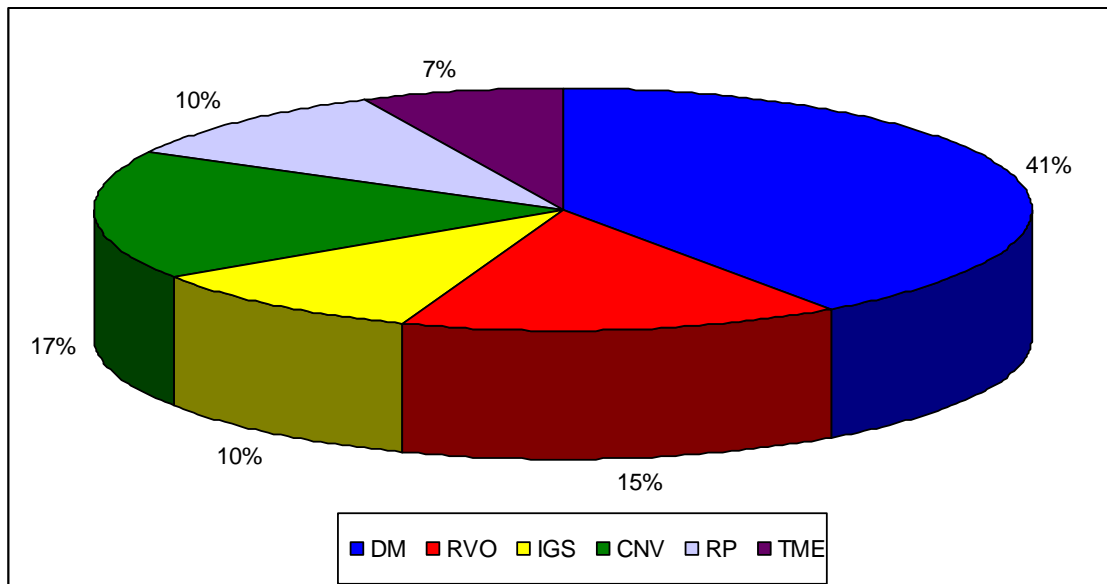


Figure (1): shows percent of eyes in different groups of treatment

All cases underwent complete ophthalmic examination (table, 1), slit-lamp biomicroscopy for assessment of macular edema and the state of posterior hyaloid in relation to the macula), FFA, and spectral domain OCT.

Statistical analysis was performed by the Statistical Package for the Social Sciences software (version 15; SPSS, Inc., Chicago, IL).

For descriptive purposes, qualitative variables were stated using percentage, and quantitative data were reported by mean \pm standard deviation.

Table (1): Demographic data of patients in different groups:

Characteristics	DM	RVO	IGS	CNV	RP	TME
No. of patients	34	15	10	14	5	6
No. of eyes	40	15	10	17	10	7
Sex of patients						
• Male	18	9	6	13	3	5
• Female	16	6	4	4	2	1
Age(mean+SD)	60.8± 8.169	50.2± 15.5	58.7± 15.585	72.35± 9.899	34.0± 5.963	63.87± 7.45
BCVA(eyes)						
• 6/12 or better	3	1	0	0	1	0
• 6/18 – 6/36	16	7	4	7	7	2
• 6/60	4	0	5	5	1	2
• Less than 6/60	17	5	1	5	1	3
IOP (mean +/-SD)	15.4± 3.1	14.8± 3.7	15.3± 2.8	15.9± 3.2	16.8± 2.1	14.7± 2.9

The following proportion was (V/A acuity value x 1000) used to describe the ratio of VA and CMT improvement in each group at baseline, one month, and 6 months.

For comparing VA and CMT with baseline values within each group, paired sample t test and mann whitney test were used (table, 2).

P values less than 0.05 were considered statistically significant to control the study.

Table (2):Pretreatment mean central macular thickness and mean visual acuity in all groups:

Etiology	Mean retinal thickness	Mean visual acuity
DM	462.60± 157.556	1.11± 0.536
RVO	627.615± 300.433	0.992± 0.403
IGS	439.4± 50.762	0.86± 0.241
CNV	412.529±162.336	0.941±0.376
RP	339.2± 47.345	0.730±0.279
TME	519.286±188.656	1.067±0.543
Mean	466.772± 98.602	0.950±0.140

Treatment of each group varies according to the etiology of macular edema (figures, 3, 4, 5). Patients were followed up at one month and 6 months after treatment for BCVA, FFA and OCT to detect macular thickening and vitreoretinal interface (table 3, 4, 5).

Table (3): Central macular thickness and FFA characteristics:

FA characteristics	Mean CRT by OCT±SD
Focal	317±103
Diffuse	389±127
Focal –diffuse	438±141
CME	442±98
No Ischemia	349±129
Ischemia	357±131

CRT: central retinal thickness, CME: cystoid macular edema, SD: standard deviation.

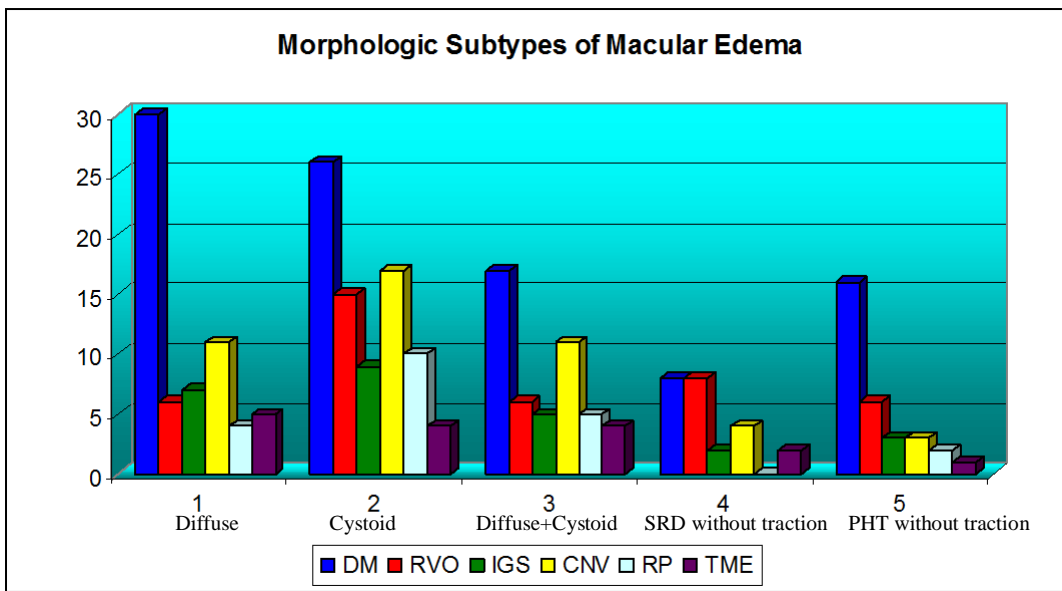


Table (4): Vitreomacular interface abnormalities among different groups seen by OCT in comparison to FFA:

	PVD		ERM		PVD + ERM		VMIA(total)	
	OCT	FFA	OCT	FFA	OCT	FFA	OCT	FFA
DM	22	5	14	10	6	1	36	16
RVO	6	-	1	-	-	-	7	-
IGS	3	-	-	-	-	-	3	-
CNV	4	-	3	1	-	-	7	1
RP	2	-	-	-	-	-	2	-
TME	3	-	4	4	2	-	7	4
Total	40	5	22	15	8	1	62	21

PVD: posterior vitreous detachment, ERM: epiretinal membrane, VMIA: vitreoretinal interface abnormalities.

Table (5): The standardized changes in macular thickening (SCMT):

Etiology	Macular thickening at baseline	Macular thickening at 6 months	The standardized change in macular thickening (SCMT):
DM	448.1	264.050	0.80
RVO	627.615	316.125	0.76
IGS	439.4	274.1	0.75
CNV	412.529	309.824	0.55
RP	339.20	222.30	0.92

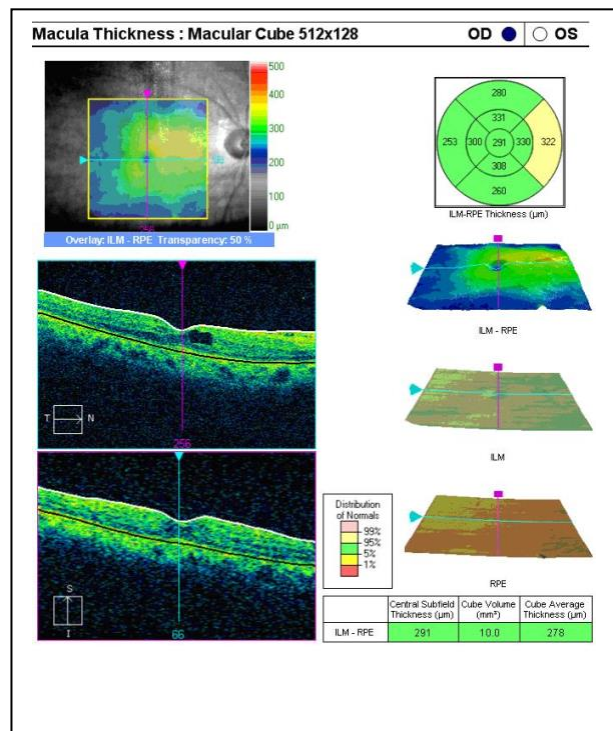
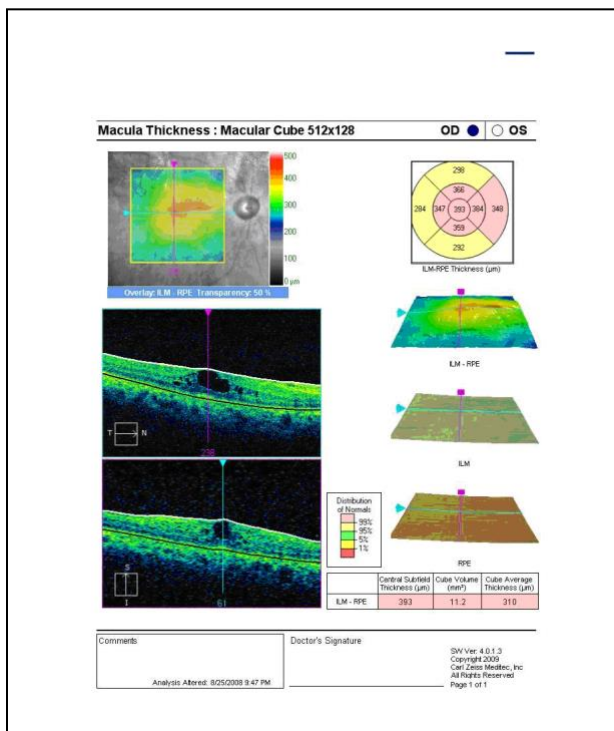
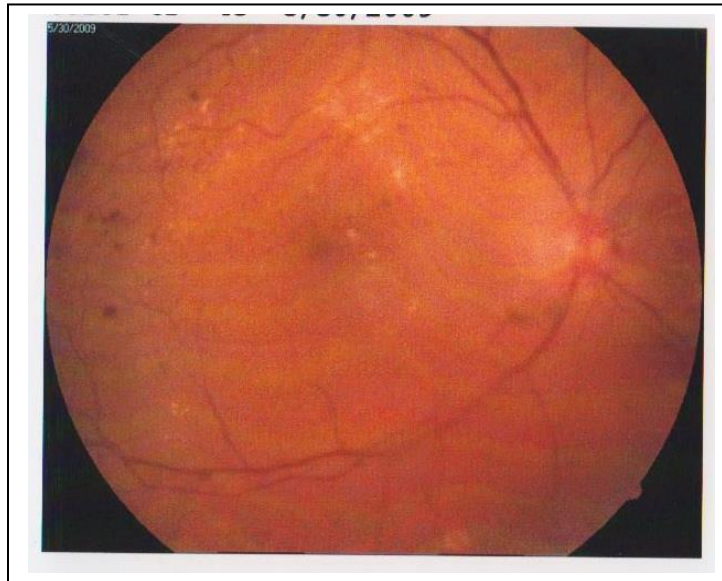The standardized change in macular thickening (SCMT):

SCMT= [actual change]/ [potential change]

= [initial thickness– final thickness] / [initial thickness–(X) μm]

(X) = normal retinal thickness by OCT

Assessment of...



significant diabetic macular edema: (top) fundus photography shows cystoid macular edema with exudates, (bottom left) OCT before treatment, and (bottom right) OCT after 6 months of treatment.

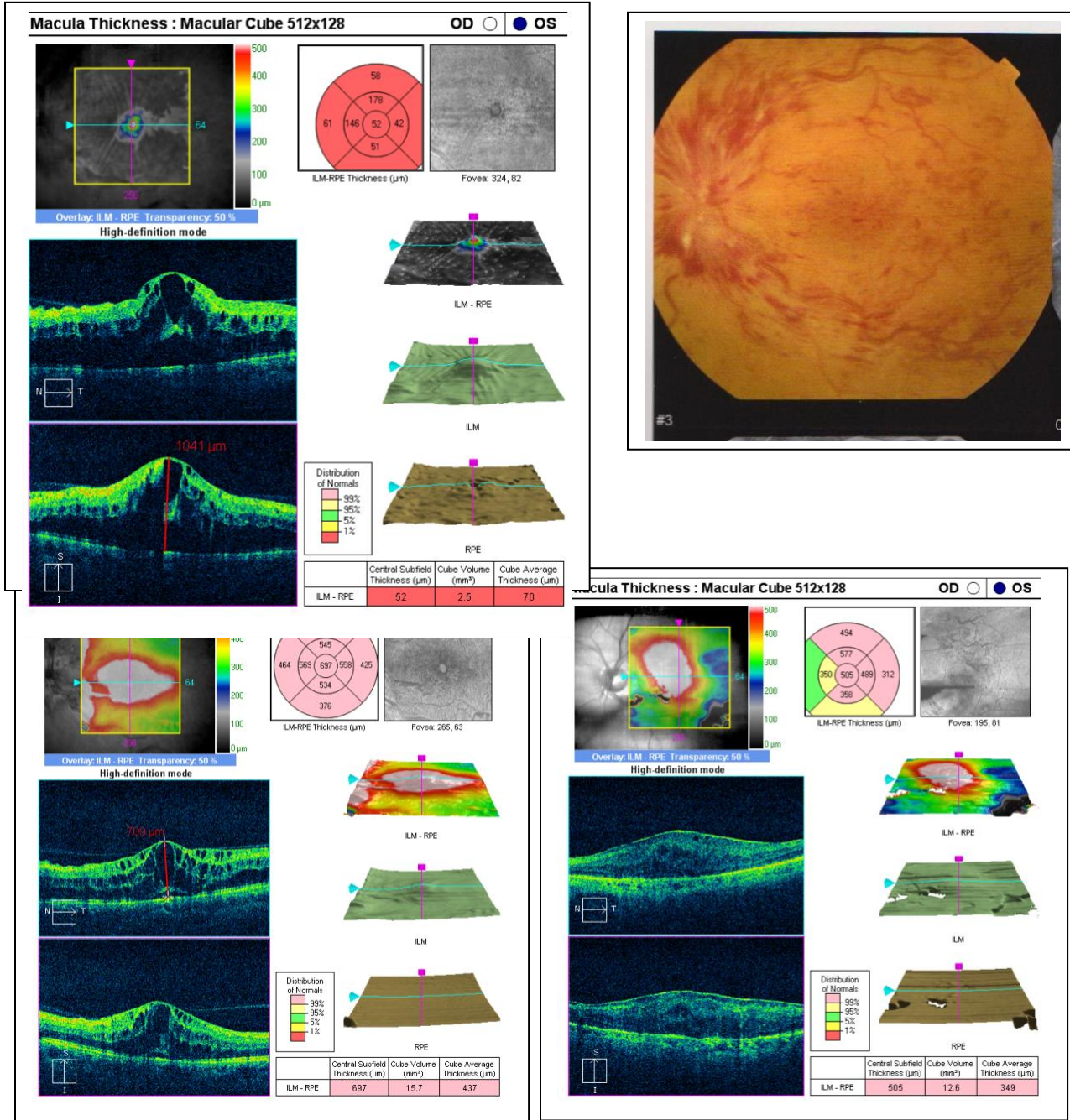


Figure (4): A case with nonischemic CRVO: (top left) OCT of Lt eye shows large cystic spaces with SRD, (top right) fundus photography shows CRVO with cystoid macular edema, (bottom left) OCT after 4 weeks of treatment, (bottom right) OCT image after 6 months of treatment.

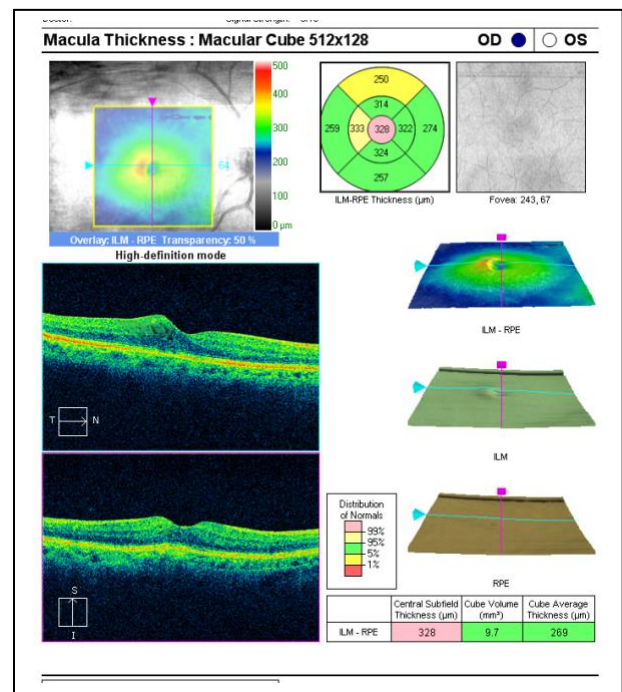
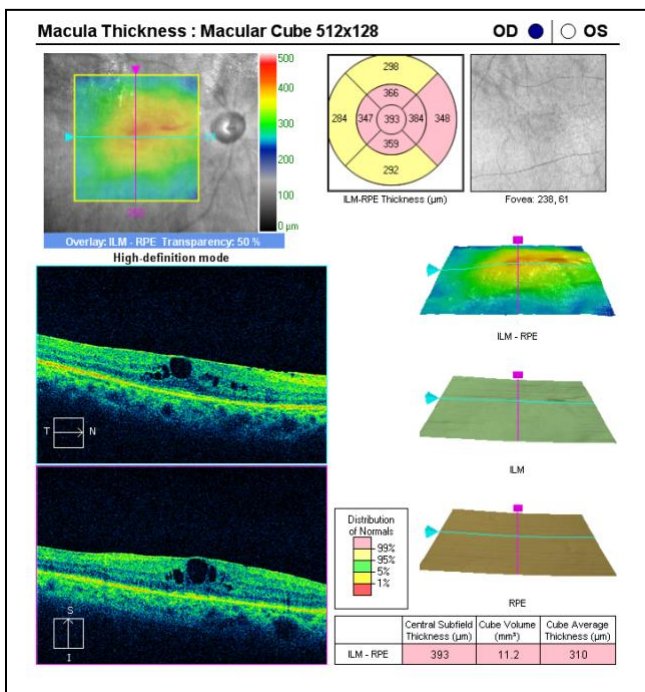
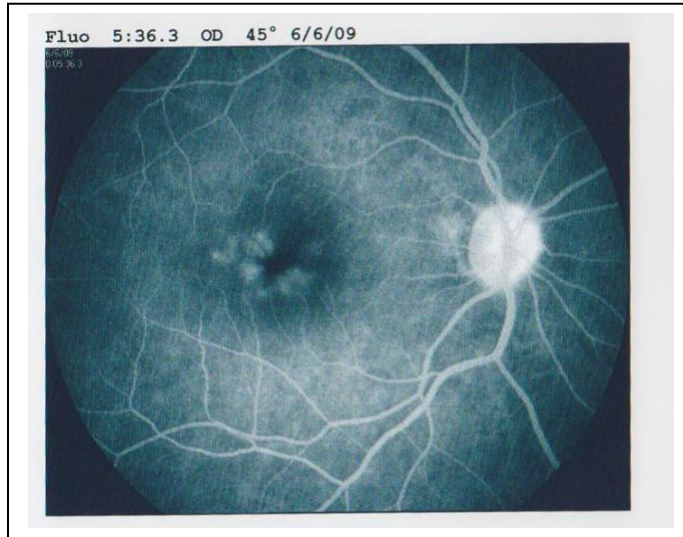


Figure (5): A case with clinically significant pseudophakic macular edema: (top) fundus photography shows clinically significant macular edema in pseudophakic patient, (bottom left) OCT image before treatment, (bottom right) OCT image after 6 months of treatment.

Discussion

OCT is particularly useful for analyzing vitreoretinal relationships and visualizing vitreoretinal adhesions ⁽⁹⁾. In this study, the posterior hyaloid was visible on OCT in 40% of the eyes; the role of the vitreous in the development of ME remains controversial.

The vitreous might indeed play a role in the pathogenesis of diabetic ME by exerting traction on the macula during perifoveolar posterior vitreous detachment: thus, this study found more cases of perifoveolar detachment among patients with diabetic ME than in ME of other etiologies and this is matching with the results by *Gaucher et al.* ⁽¹⁾.

FFA is known to be a sensitive method for the qualitative assessment of cases with macular edema. In this study SRD was more frequent in cases of ME associated with vein occlusion (46%) than in cases of diabetic ME (32%). In agree with **Spaide et al.** ⁽¹⁰⁾ reported a 43% prevalence of SRD in a series of ME because of vein occlusion, while **others** ^(11,12), reported a 15% and 21% prevalence, respectively, in cases of diffuse diabetic ME

We found a significant correlation between central macular thickness and VA in patients with pseudophakic, BRVO and diabetic ME, in agree with many authors ^(11, 13). However, others ^(14, 15) found a poor correlation in ME combined with uveitis or retinitis pigmentosa.

CME was detected with OCT in 80 eyes (80%) in the study, 30 eyes (30%) of which was not detected during slit-lamp biomicroscopy with a +90D lens and 35 eyes (35%) of which was not found during angiography. This is a striking finding, demonstrating the importance of OCT in the detection of foveal changes which are not evident clinically and angiographically. The great discrepancy between FA and OCT could also be the result of a masked cystoid staining pattern in eyes with severe focal and diffuse leakage.

We have demonstrated serous foveal detachment in 22 eyes of total 99 eyes (22% of cases) where it was not detected during clinical examination. This is a very important finding which may explain the cause of unexplained visual loss in patients with diabetic maculopathy. On the other hand, serous foveal detachment determined with OCT was reported in 15% of diabetic patients in other studies ^(5, 16).

Cystic spaces were more commonly found in the outer retina, as **Otani and Kishi** ⁽¹⁷⁾ studied 59 eyes with DME by OCT and stated that cystoid macular edema was located mainly in the outer retinal layers. This study stated that cystoid macular edema was located mainly in the outer retinal layers in 53 eyes of 80 eyes with CME.

OCT was significantly superior to biomicroscopy and FFA in detecting such vitreomacular interface abnormalities (VMIA) as OCT detected VMIA in 62 eyes in comparable to FFA in 21 eyes. This supports the finding of **Gallemore et al.** ⁽⁹⁾, who reported that OCT was on average three times more sensitive than biomicroscopy in detecting vitreoretinal adhesions associated with a variety of macular diseases.

OCT superiority in this study was more significant in eyes with NPDR as compared with those with PDR, perhaps because in PDR, ERMs and areas of vitreoretinal adhesions tend to be denser and generally easier to recognize clinically.

The OCT results described here may be important for several reasons such as eyes with DME are increasingly considered for pharmacologic or surgical therapies as alternatives to laser photocoagulation, the findings of this study underscore anatomic factors that may make patient selection more specific. For example, eyes with DME and evidence of vitreomacular traction in theory may benefit more from vitrectomy than eyes with DME without traction. Clinical support for this was given by a study where vitrectomy was found to be beneficial in eyes with diffuse DME and vitreomacular traction but not in edematous eyes without traction ⁽¹⁸⁾. So, OCT may be of value in the early diagnosis of traction in such eyes. In addition, OCT-guided identification of eyes with and without VMIA may help in understanding some reasons for response or lack of response to pharmacologic therapies for eyes with DME. Furthermore, OCT allows for detection of subclinical macular detachment associated with VMIA that may be missed otherwise.

OCT provided us with valuable information on the retinal morphologic changes associated with ME of different etiologies and analyzing vitreomacular relationship and detecting macular SRD undetectable on biomicroscopy and FFA.

However, FFA is still essential for the assessment of the foveal perfusion state which cannot be demonstrated with OCT.

After an initial FFA, OCT seems to be a useful tool in the follow-up of the effectiveness of treatment modalities of macular edema. In conclusion, the two imaging modalities, OCT and FFA provided a more comprehensive picture of the pathophysiologic mechanisms of macular edema.

References

Gaucher D, Tadayoni R, Erginay A, Haouchine B, Gaudric A and Massin P.: Optical coherence tomography assessment of the vitreoretal face in diabetic macular edema. *Am J Ophthalmol* 2005; 139:807–813?

Catier A, Tadayoni R, Paques M, Erginay A, Haouchine B, Gaudric A and Massin P. : Characterization of macular oedema from various aetiologies by optical coherence tomography. *Am J Ophthalmol* 2005; 140: 200–206.

Gardner TW. : Current strategies and challenges in the management of diabetic retinopathy. *Advanced studies in ophthalmology* 2005; 2: 14-19.

Johnson MW. : Etiology and treatment of macular edema. *Am J Ophthalmol* 2009; 147:11–21?

Hee MR, Puliafito CA and Wong C.: Quantitative assessment of macular edema with optical coherence tomography. *Arch Ophthalmol* 1995; 113: 1019–1029.

Drexler W.: Ultrahigh-resolution optical coherence tomography [review]. *J Biomed Opt* 2004; 9(1):47–74.

Van Velthoven MEJ, Faber DJ, Verbraak FD, Van Leeuwen TG and De Smet MD. : Recent developments in optical coherence tomography for imaging the retina. *Progress in Retinal and Eye Research* 2007; 26: 57–77.

Kiernan Df, William F. Mieler, And Seenu M. Hariprasad : Spectral-domain optical coherence tomography: a comparison of modern high-resolution retinal imaging systems. *Am J Ophthalmol* 2010; 149: 18-31

Gallemore RP, Jumper JM, McCuen BW, Jaffe GJ, Postel EA and Toth CA. : Diagnosis of vitreoretinal adhesions in macular disease with optical coherence tomography. *Retina* 2000; 20:115–120.

Spaide RF, Lee JK, Klancnick JM and Gross NE.: Optical coherence tomography of branch retinal vein occlusion. *Retina* 2003; 23:343–347.

Otani T, Kishi S and Maruyama Y.: Patterns of diabetic macular edema with optical coherence tomography. *Am J Ophthalmol* 1999; 127:688–693.

Kang SW, Park CY and Ham DI. : The correlation between fluorescein angiographic and optical coherence tomographic features in clinically significant diabetic macular edema. *Am J Ophthalmol* 2004;137:313–322-

Suzuma K, Kita M and Yamana T. : Quantitative assessment of macular edema with retinal vein occlusion. *Am J Ophthalmol* 1998;126:409–416.

Hirakawa H, Iijima H, Gohdo T and Tsukahara S.: Optical coherence tomography of cystoid macular edema associated with retinitis pigmentosa. *Am J Ophthalmol* 1999;128:185–191.

Antcliff RJ, Stanford MR and Chauhan DS.: Comparison between optical coherence tomography and fundus fluorescein angiography for the detection of cystoid macular edema in patients with uveitis. *Ophthalmology* 2000;107:593–599.

16- Toth CA, Narayan DG and Boppart SA. : A comparison of retinal morphology viewed by optical coherence tomography and by light microscopy. *Arch Ophthalmol* 1997;115(11):1425–1428.

Otani T and Kishi S.: Correlation between optical coherence tomography and fluorescein angiography findings in diabetic macular edema. *Ophthalmology* 2007;114:104 –107.

Massin P, Duguid G, Erginay A, Haouchine B and Gaudric A.: Optical coherence tomography for evaluating diabetic macular edema before and after vitrectomy. *Am J Ophthalmol* 2003;135:169 – 177

تقييم السطح البيني للشبكية والجسم الزجاجي لحالات ارتشاح ماقولة العين باستخدام تصوير قاع العين بصبغة الفلورسين والمسح المقطعي الضوئي المترابط للعين

هاني علي يحيى⁽¹⁾، سوسن عبدالصبور شلبي⁽²⁾، إهام عبد الواحد حسن⁽²⁾، وفاء أحمد مدبولي⁽²⁾، نهال عادل حسن⁽³⁾
مستشفى رمد طنطا⁽¹⁾، قسم طب وجراحة العيون - كلية الطب بنات - جامعة الأزهر⁽²⁾، قسم طب وجراحة العيون - جامعة القاهرة⁽³⁾

يعتبر ارتشاح ماقولة العين أحد أهم الأسباب لضعف الإبصار وقد وجد أنها تحدث مع كثير من الأحوال المرضية بالعين كما أنه يحدث نتيجة تأثر الحاجز الداخلي بين الدم والشبكية . وذكر بعض الباحثين أن هناك علاقة بين الجسم الزجاجي وحدوث ارتشاح ماقولة العين وبالتالي سوف يؤدي هذا إلى تغيير طرق العلاج.

الغرض من البحث:

تقييم السطح البيني للشبكية والجسم الزجاجي وارتشاح ماقولة العين بواسطة استخدام تصوير قاع العين بصبغة الفلورسين و المسح المقطعي الضوئي المترابط للعين.

مادة وطرق البحث:

تم اختيار تسعة وتسعون عينا لأربعة وثمانين مريضا يعانون من ارتشاح ماقولة العين المؤثرة اكلينيكيًا وقد تم تقسيمهم إلى ست مجموعات :

المجموعة الأولى:

المرضى المصابين بارتشاح سكري شبكية العين مع ارتشاح ماقولة العين المؤثر اكلينيكيًا وعددهم أربعون عينا و العلاج وهو حقن بالجسم الزجاجي لمادة تراي امسينولون اسيتونايد وعمل جلسات أرجون ليزر.

المجموعة الثانية:

المرضى المصابون بالانسداد الوريدي شبكية العين مصحوبا بارتشاح ماقولة العين المؤثر اكلينيكيًا وعددهم خمسة عشر عينا و العلاج هو حقن لمادة (أفاسيتين) بالجسم الزجاجي.

المجموعة الثالثة: المرضى المصابون بارتشاح ماقولة العين بعد عمليات إزالة البياض وعددهم عشرة عيون و العلاج هو حقن لمادة تراي امسينولون اسيتونايد بالجسم الزجاجي.

المجموعة الرابعة:

المرضى المصابون بارتشاح ماقولة العين المصاحب للأوعية الدموية الناشئة بمشيمة العين نتيجة ضمور ماقولة العين مع كبر السن وعددهم سبعة وعشرون عينة و العلاج هو حقن بالجسم الزجاجي لمادة (أفاسيتين).

المجموعة الخامسة:

المرضى المصابون بارتشاح ماقولة العين والذين يعانون من الالتهاب الشبكي التلوني بالشبكية وعددهم عشرة عيون و العلاج دوائي وهو استخدام أقراص مادة (اسيتازولاميد).

المجموعة السادسة:

المرضى المصابون بارتشاح ماقولة العين الناتج عن خلل بالسطح البيني بين الشبكية والجسم الزجاجي وعددهم سبعة عيون

قد تم استيفاء التاريخ المرضى والكشف الطبي الكامل للمعين على جميع المرضى مع عمل تصوير قاع العين بصبغة الفلوريسين و عمل المسح المقطعي الضوئي المترابط للمعين عند اول كشف للمريض وفي المتابعات عند شهر وستة أشهر.

النتائج:-

-- أظهرت الدراسة حدوث تحسن ملحوظ في سمك ماقولة العين بعد تلقي العلاج
-- أظهر استخدام المسح المقطعي الضوئي المترابط للمعين أشكال للارتشاح بشبكية العين لم تكن واضحة بواسطة استخدام تصوير قاع العين بالصبغة مما أدى الى تغيير طرق العلاج
-- أظهرت الدراسة وجود أشكال مرضية متنوعة بالسطح البيني للشبكية والجسم الزجاجي والتي تساعد في تحديد نوع العلاج لكل حالة.
-- يساعد تصوير قاع العين بالصبغة على التشخيص وتحديد موضع العلاج بواسطة جلسات أرجون ليزر ومعرفة حالة الدورة الدموية للشبكية.ولهذا فوجود تصوير قاع العين بصبغة الفلوريسين مع المسح المقطعي الضوئي المترابط للمعين يساعد على معرفة التشخيص السليم وطريقة العلاج ومتابعة المرضى ومدى استجابتهم للعلاج.