

<b>Original Article</b>	<b>The Inter-Epicondylar Distance as a Valid Method for Localization of the Radial Nerve in the Posterior Approach to the Humerus: Cadaveric and Surgical Study</b> <i>Ayman Ahmed Khanfour<sup>1</sup>, Marwa Mahmoud Mady<sup>2</sup> and Ahmed Fouad Abo Taleb<sup>3</sup></i> <i>Department of <sup>1,2</sup>Anatomy, <sup>3</sup>Orthopedic, Faculty of Medicine, Alexandria University, Egypt</i>
-------------------------	---

### ABSTRACT

**Background:** An ability to predict correctly the point where the radial nerve pierces the lateral intermuscular septum would be useful during arm surgery. Aim of the work: The present work aimed to create a simple bony guide to localize the radial nerve for the safe posterior approach to the humerus.

**Material and Methods:** The material of this work included forty upper limbs of formalin preserved specimens obtained from the dissecting room of anatomy department, and forty surgical cases undergoing posterior fixation of the humerus from the operative room of El Hadra hospital, Faculty of Medicine, Alexandria University.

The measurements involved the distance between the upper margin of the spiral groove to the tip of the medial epicondyle (medial measurement), the distance between the lower margin of the spiral groove to the tip of the lateral epicondyle (lateral measurement) and measurement of the inter-epicondylar distance in both cadaveric and surgical cases and compared with each other.

**Results:** The results revealed no statistically significant difference between measurements of both sides in the cadaveric study. In the same time, no statistically significant difference between measurements of cadaveric and surgical cases. From the previous measurements we obtained a formula from which we can predict the medial and lateral measurements of the radial nerve from the inter-epicondylar distance value.

**Conclusion:** The inter-epicondylar distance is a reliable method and reproducible measure to localize the radial nerve on the back of the humerus.

**Received:** 22 November 2019, **Accepted:** 6 January 2020

**Key Words:** Inter-epicondylar distance, posterior approach of humerus, radial nerve.

**Corresponding Author:** Ayman Ahmed Khanfour, Ph.D, Department of Anatomy, Faculty of Medicine, Alexandria University. **Tel.:** 021223815866, **E-mail:** ayman222@hotmail.com

**The Egyptian Journal of Anatomy, ISSN:** 0013-2446, Vol. 43 No. 2

### INTRODUCTION

The radial nerve (RN) is the continuation of the posterior cord of the brachial plexus. It originates from C5 to T1 spinal nerves. The nerve is situated behind the brachial artery and descends between the lateral and medial heads of triceps brachii muscle.<sup>[1,2]</sup> The radial nerve penetrates the lateral intermuscular septum of the arm and descends reaching the front of the lateral epicondyle where it divides into superficial and deep branches.<sup>[3]</sup> An ability to predict correctly the point where the nerve pierces the septum would be useful during arm surgery and promote the planning of posterior approach for exploring the radial nerve after distal humeral shaft fractures. In specific, it would minimize the risk of minimally invasive surgical methods.<sup>[4,5]</sup> During

the operative intervention posterior to the humerus, it is essential to identify the radial nerve while it passes through the spiral groove to preserve its integrity.<sup>[6]</sup> In humerus fractures, one of the most common (wounded/injured) nerves is the radial nerve.<sup>[7,8]</sup> Iatrogenic Radial nerve injury is a well-known complication during open humeral reduction and internal fixation. It would be of great value to prevent this sort of injury.<sup>[9, 10]</sup> Knowledge of radial nerve anatomy is a key element for security and effective arm and elbow surgery.<sup>[11]</sup>

### AIM OF THE WORK:

The present work aimed to create a simple bony guide to localize the radial nerve for the safe posterior approach to the humerus.

## MATERIAL AND METHODS

The material of this work included forty upper limb cadaveric specimens obtained from the Dissecting Room of Anatomy Department, Faculty of Medicine, Alexandria University and forty surgical cases undergoing posterior fixation of the humerus from the operative room of ElHadra hospital, Faculty of Medicine, Alexandria University. Arms having any gross malformation or deformity as well as patients with preoperative radial nerve palsy were discarded from the study.

In the cadaveric study, each cadaver was on the dissection table in a prone position. Both arms were held in an extended position. From the tip of the acromion process to the top aspect of the olecranon process, an incision was made (Fig. 1). The skin and subcutaneous tissues were dissected and removed. The lateral intramuscular septum was identified.<sup>[12]</sup>

Blunt dissection through the musculature of the triceps was performed at a rate of two finger widths proximal to its aponeurosis and the radial nerve lying on the posterior humerus periosteum was established.<sup>[13]</sup> Measurements were done on both sides using manual Smith Vernier caliper with the help of a graduated tape. The measurements involved the distance between the upper margin of the spiral groove (entry of the radial nerve through the spiral groove) to the tip of the medial epicondyle (medial measurement), the distance between the lower margin of the spiral groove (exit of radial nerve from the lateral intermuscular septum) to the tip of the lateral epicondyle (lateral measurement) and measurement of the inter-epicondylar distance (Fig. 2).

In the surgical study, patients with fracture humerus were in lateral decubitus position, with the affected arm bent at the elbow. Prophylactic antibiotics 2 gram ceftriaxone were given parenterally 60 min before induction. After routine disinfection and draping, standard posterior approach through the skin, subcutaneous fat, and aponeurosis of triceps muscle. Epicondylar distance was identified. Using values from the anatomical phase from this study, a prediction of the course of the radial nerve was projected. Then identification of the radial nerve by following the gap between lateral and long heads of triceps was followed by obtaining the same measurements

(medial measurement, and lateral measurement) as in the anatomical phase of this study and were statistically analyzed and compared with those of the cadaveric study.

Values were expressed as means, standard deviations. A level of statistical significance was established at  $P < .05\%$ . Statistical analysis was performed using SPSS version 19.



**Fig. 1:** A photograph of a right side arm (lateral view) showing the line of incision. (A) Tip of acromion process (O) Tip of olecranon process.

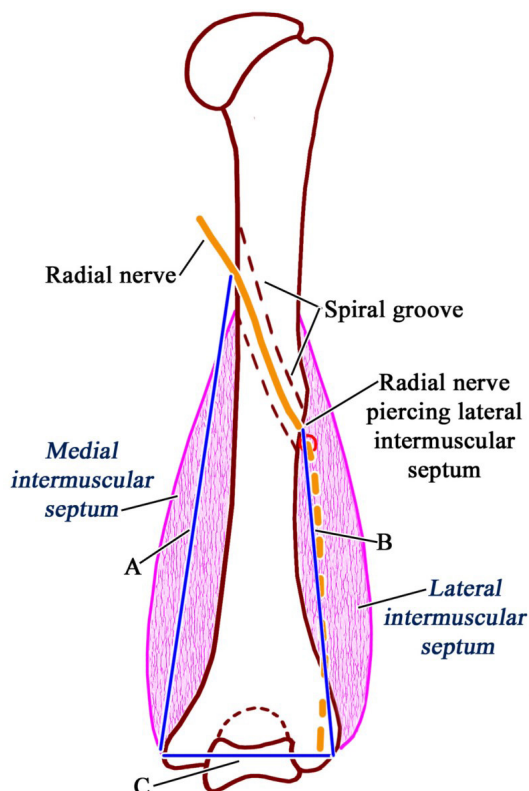


Fig. 2: A diagram of the back of the right humerus showing the medial measurement (A), lateral measurement (B) and the intercondylar distance (C).

## RESULTS

### I. Results of the cadaveric study:

The distance between the upper and lower margins of the spiral groove (entry and exit of the radial nerve through the spiral groove) to the tip of the medial and lateral epicondyles respectively (medial and lateral measurements respectively) were measured.

The medial measurement ranged from 12.80-19.76 cm with a mean value of  $14.94\text{cm} \pm 2.30$  on the right side, and ranged from 12.77-19.80 cm with a mean value of  $15.01\text{cm} \pm 2.44$  on the left side (Fig. 3). No significant statistical difference existed between measurements on both sides ( $P 0.888$ ). (Table 1)

The lateral measurement ranged from 5.50-11.40 cm with a mean value of  $8.41\text{cm} \pm 1.52$  on the right side, and ranged from 5.48-11.36 cm

with a mean value of  $8.58\text{cm} \pm 1.27$  on the left side (Fig. 4). There was no statistical significant difference between measurements on both sides ( $P 0.627$ ) (Table 1)

The intercondylar distance ranged from 6.11-7.19 cm with a mean value of  $6.53\text{cm} \pm 0.35$  on the right side, and ranged from 6.10-7.20 cm with a mean value of  $6.54\text{cm} \pm 0.37$  on the left side (Fig. 5). No significant statistical difference existed between measurements on both sides ( $P 0.900$ ) (Table 1)

### II. Results of the surgical study

The medial measurement ranged from 12.79-19.72cm with a mean value of  $15.96\text{cm} \pm 2.81$ . Compared to the cadaveric measurements, there was no significant statistical difference existed between measurements on both sides ( $P 0.154$ ). (Table 2)

The lateral measurement ranged from 5.49-11.41cm with a mean value of  $8.17\text{cm} \pm 2.04$  (Fig. 6). Compared to the cadaveric measurements, there was no significant statistical difference existed between measurements on both sides ( $P 0.493$ ). (Table 2)


The intercondylar distance ranged from 6.11-7.22cm with a mean value of  $6.66\text{cm} \pm 0.42$  (Fig. 7). Compared to the cadaveric measurements, there was no significant statistical difference existed between measurements on both sides ( $P 0.207$ ). (Table 2)

From the intercondylar distance, we created an equation to predict the point of entry and exit of the radial nerve through the spiral groove in relation to the medial and lateral epicondyles respectively:

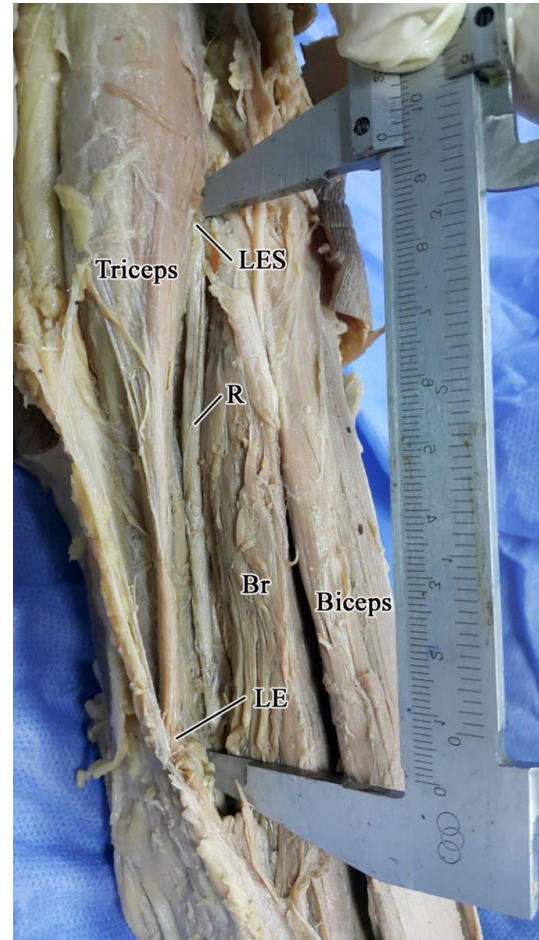
$$\text{Distance between the upper margin of the spiral groove to the tip of the medial epicondyle} = -24.84 + (6.102 * \text{Inter-Epicondylar Distance})$$

$$\text{Distance between the lower margin of the spiral groove to the tip of the lateral epicondyle} = 25.98 - (2.678 * \text{Inter-Epicondylar Distance}).$$


(Table 3).



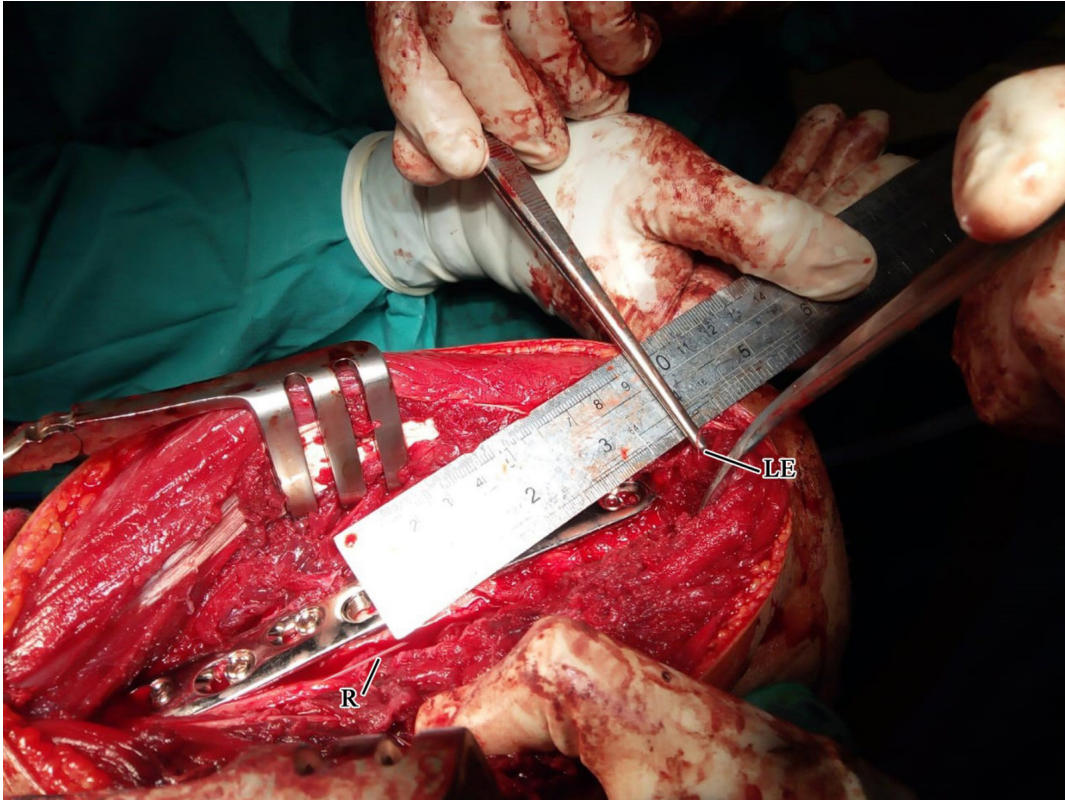
**Fig. 3:** A photograph of a right side arm showing the medial measurement of the radial nerve (R) (UES: upper edge of spiral groove - U: Ulnar nerve - Ba: Brachial artery - M: Median nerve – ME: Medial epicondyle)



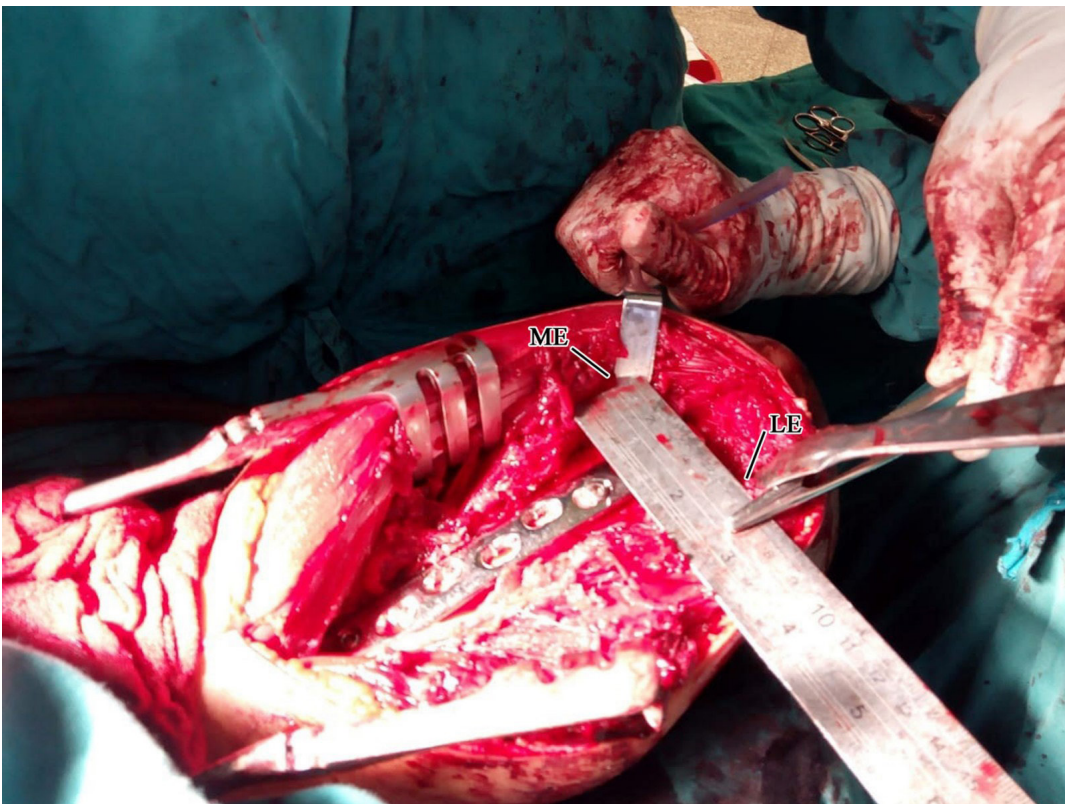
**Fig. 4:** A photograph of a right side arm showing the lateral measurement of the radial nerve (R) (LES: lower edge of spiral groove - Br: Brachialis - LE: Lateral epicondyle)



**Fig. 5:** A photograph of a left sided specimen showing the measurement of the intercondylar distance. (ME: Medial epicondyle - LE: Lateral epicondyle - M: Median nerve - Ba: Brachial artery - U: Ulnar nerve)



**Fig. 6:** A photograph of a right posterior surgical approach of the humerus showing the radial nerve (R) piercing the lateral intermuscular septum to reach the anterior compartment. (LE: Lateral epicondyle)



**Fig. 7:** A photograph of a left posterior surgical approach of the humerus showing the measurement of the intercondylar distance. (ME: Medial epicondyle - LE: Lateral epicondyle)

**Table 1:** Comparison between medial and lateral measurements and the intercondylar distance in the cadaveric group.

	Cadaver group		t-test	<i>P value</i>
	Right side	Left side		
Medial measurements				
Range	12.80-19.76	12.77-19.80		
Mean	14.94	15.01		
S.D.	2.30	2.44	0.020	0.888
Lateral measurements				
Range	5.50 -11.40	5.48-11.36		
Mean	8.41	8.58		
S.D.	1.52	1.72	0.238	0.627
Inter-epicondylar distance				
Range	6.11-7.19	6.10-7.20		
Mean	6.53	6.54		
S.D.	0.35	0.37	0.016	0.900

**Table 2:** Comparison between medial and lateral measurements and the intercondylar distance in the cadaveric and surgical groups.

	Cadaver group	Surgical group	t-test	<i>P value</i>
Medial measurement				
Range	12.80-19.80	12.79-19.72		
Mean	14.98	15.96		
S.D.	2.36	2.81	1.07	0.154
Lateral measurement				
Range	5.50-11.40	5.49-11.41		
Mean	8.49	8.17		
S.D.	1.62	2.04	0.474	0.493
Inter-epicondylar distance				
Range	6.10-7.20	6.11-7.22		
Mean	6.53	6.66		
S.D.	0.35	0.42	0.96	0.207

**Table 3:** Prediction medial and lateral measurements of the radial nerve from the intercondylar distance value.

Equation	Parameters	Accuracy of equation	The mean difference between equation and actual distance
$-24.84 + (6.102 * \text{Inter-Epicondylar Distance})$	= Distance between the upper margin of the spiral groove to the tip of the medial epicondyle	85.2	0.072
$25.98 - (2.678 * \text{Inter-Epicondylar Distance})$	= Distance between the lower margin of the spiral to the tip of the lateral epicondyle	87.0	0.044

## DISCUSSION

The posterior approach is widely used in arm surgery, although this approach puts the radial nerve at risk of iatrogenic injury. Therefore, a thorough evaluation of the radial nerve distribution in this region is required.<sup>[14,15]</sup>

A soft tissue guide was conducted by Arora *et al.* (2011)<sup>[7]</sup> using the triceps aponeurosis apex as a landmark to locate the radial nerve. They identified a soft tissue point in relation to triceps, it was 2.5 cm cranial to the apex of the aponeurosis of the triceps, along the longitudinal axis of the humerus, which can help to easily locate the radial nerve during the posterior approach to the arm.

Another cadaveric study was done by Mythraeyee Prasad *et al.* (2018)<sup>[16]</sup> where they found the mean distance of the radial nerve in relation to the point of confluence of the triceps heads was  $39.7 \pm 11.8$  mm. It was never found to be closer than  $4.6 \pm 2.54$  mm to the aponeurosis.

Compared with the present study, we used fixed bonny anatomical landmarks to obtain accurate measurements of the radial nerve, indeed, we established a correlation distance between the upper margin of the spiral groove to the tip of the medial epicondyle =  $-24.84 + (6.102 * \text{Inter-epicondylar distance})$  and the distance between the lower margin of the spiral groove to the tip of the lateral epicondyle =  $25.98 - (2.678 * \text{Inter-epicondylar distance})$ . Using soft tissue landmarks may be subjected to bias and may be affected by body built. So, it is not a reliable guide but it may be put into consideration.

A bonny guide for the radial nerve was studied by S. Kamineni *et al.* (2009).<sup>[17]</sup> The mean trans-epicondylar distance was  $62 \pm 6$  mm (range 52–78 mm), and the mean lateral radial nerve length was  $102 \pm 10$  mm (range 75–129 mm). The average ratio of the lateral radial nerve length to the trans-epicondylar distance was an average of  $1.7 \pm 0.2$  (range 1.4–2.0). The coefficient of comparison between the lateral length of the radial nerve and the trans-epicondylar length was  $r = 0.95$ .

The above study is in agreement with the present study. However, the present study entailed the relation between the radial nerve length on both the medial and lateral sides to the trans-epicondylar distance. This ensures accurate

localization of the main part of the radial nerve course in the posterior compartment of the arm.

Park *et al.* (2019)<sup>[18]</sup> used deltoid tuberosity and the origin of brachioradialis where the radial nerve can be easily reproducible. During fracture surgery, these two structures can serve as stationary landmarks to find the radial nerve that can be found in the distal 2/3 of the distance between deltoid tuberosity and brachioradialis origin. Another rough method of localization of the radial nerve was described by P. Fleming *et al.* (2004)<sup>[4]</sup> declaring that, in almost every case, the radial nerve penetrated the anterior compartment (through penetrating the lateral intermuscular septum) at a point within 5 mm from the junction of the middle and lower thirds of a line connecting the lateral point of the scapular acromion process to the lateral epicondyle of the humerus. The above two studies denied by Kim, J. G. *et al.* (2017)<sup>[19]</sup> where they concluded that multiple segmentation measurement methods better reflected the radial nerve path than a single linear measuring system.

Nasr A (2011)<sup>[11]</sup> concluded that in males the mean distance between the point of exit of the radial nerve and the middle of the lateral and medial epicondyles was  $104.7 \pm 13$  mm (33.8%) and in females was  $101.3 \pm 7$  mm (36%).

Another study was done by Jain, R. K. (2019)<sup>[8]</sup> to identify the danger zone of the radial nerve in the Indian population. The mean distance of medial epicondyle to the entry of the radial nerve into the spiral groove was  $18.5 \pm 0.79$  cm. The mean distance of the lateral epicondyle to the exit of the radial nerve into the spiral groove was  $11.34 \pm 0.41$  cm. The mean length of the radial nerve groove/spiral groove was  $4.3 \pm 0.75$  cm. However, this study lacks elaboration of a relationship (formula) between the length of the radial nerve on the lateral and medial sides to fixed bonny landmarks of the same person, indeed it neglected the personal variations in the body built of the same Indian population.

## CONCLUSIONS

The inter-epicondylar distance is a reliable method and reproducible measure to locate the radial nerve on the back of the humerus during subsequent posterior approach to the humerus that could be used to avoid radial nerve iatrogenic injury.

**CONFLICT OF INTERESTS**

There are no conflicts of interest.

**REFERENCES**

1. Demirkale I, Imamoglu H, Sik S, Ozturk O. Localisation of the radial nerve at the spiral groove: A new technique. *Journal of orthopaedic translation*. 2019;16:85-90.
2. Theeuwes HP, van der Ende B, Potters JW, Kerver AJ, Bessems J, Kleinrensink GJ. The course of the radial nerve in the distal humerus: A novel, anatomy based, radiographic assessment. *PLoS One*. 2017;12(10):e0186890.
3. Artico M, Telera S, Tiengo C, Stecco C, Macchi V, Porzionato A, *et al.* Surgical anatomy of the radial nerve at the elbow. *Surgical and radiologic anatomy : SRA*. 2008;31:101-6.
4. Fleming P, Lenehan B, Sankar R, Folan-Curran J, Curtin W. One-third, two-thirds: relationship of the radial nerve to the lateral intermuscular septum in the arm. *Clinical anatomy (New York, NY)*. 2004;17(1):26-9.
5. Cox CL, Rihard D, Tubbs RS, Bradley E, Lee DH. Predicting radial nerve location using palpable landmarks. *Clinical anatomy (New York, NY)*. 2010;23(4):420-6.
6. Seigerman D, W Choung E, Yoon R, Lu M, Frank M, C D R Robert J Gaines L, *et al.* Identification of the Radial Nerve During the Posterior Approach to the Humerus: A Cadaveric Study. *Journal of orthopaedic trauma*. 2011;26:226-8.
7. Arora S, Goel N, Cheema GS, Batra S, Maini L. A method to localize the radial nerve using the 'apex of triceps aponeurosis' as a landmark. *Clinical orthopaedics and related research*. 2011;469(9):2638-44.
8. Jain RK, Champawat VS, Mandlecha P. Danger zone of radial nerve in Indian population - A cadaveric study. *Journal of clinical orthopaedics and trauma*. 2019;10(3):531-4.
9. Fu MC, Hendel MD, Chen X, Warren RF, Dines DM, Gulotta LV. Surgical anatomy of the radial nerve in the deltopectoral approach for revision shoulder arthroplasty and periprosthetic fracture fixation: a cadaveric study. *Journal of shoulder and elbow surgery*. 2017;26(12):2173-6.
10. Theeuwes HP, van der Ende B, Potters JW, Kerver AJ, Bessems JHJM, Kleinrensink GJ. The course of the radial nerve in the distal humerus: A novel, anatomy based, radiographic assessment. *PLOS ONE*. 2017;12(10):e0186890.
11. Nasr A. The clinical significance of the arm bony landmarks in correlation to the radial nerve course: An anatomical study. *Zagazig University Medical Journal*. 2011;Vol. (17):115-31.
12. Wu ZZ, Wang JD, Ji XX, Ma ZJ, Wu JH, Wang QG. Surgical exposures of the distal humeral fractures: An anatomical study of the anterior, posterior, medial and lateral approaches. *Chinese journal of traumatology = Zhonghua chuang shang za zhi*. 2018;21(6):356-9.
13. Capo JT, Criner KT, Shamian B. Exposures of the humerus for fracture fixation. *Hand clinics*. 2014;30(4):401-14, v.
14. Latef TJ, Bilal M, Vetter M, Iwanaga J, Oskouian RJ, Tubbs RS. Injury of the Radial Nerve in the Arm: A Review. *Cureus*. 2018;10(2):e2199-e.
15. Simone JP, Streubel PN, Sanchez-Sotelo J, Steinmann SP, Adams JE. Fingerbreadths Rule in Determining the Safe Zone of the Radial Nerve and Posterior Interosseous Nerve for a Lateral Elbow Approach: An Anatomic Study. *Journal of the American Academy of Orthopaedic Surgeons Global research & reviews*. 2019;3(2):e005.
16. Mythraeyee Prasa d1 B1c, Prasa nna Samuel Premkumar3. Anatomic Landmarks to Identify the radial nerve during the Posterior Approach of the Humerus: A Cadaveric Study. *Journal of Clinical and Diagnostic Research*. 2018;12(11).



17. Kamineni S, Ankem H, Patten D. Anatomic Relationship of the Radial Nerve to the Elbow Joint: Clinical Implications of Safe Pin Placement. *Clinical anatomy* (New York, NY). 2009;22:684-8.
18. Park KJ, Romero BA, Ahmadi S. Identification of Radial Nerve in Relationship to Deltoid Tuberosity and Brachioradialis. *Arch Bone Jt Surg*. 2019;7(3):246-50.
19. Kim JG, Kim D, Seok HY, Kim Y, Yang KS, Rhyu IJ, *et al*. A Method of Radial Nerve Length Measurement Based on Cadaveric Investigation. *Archives of physical medicine and rehabilitation*. 2017;98(3):596-9.

## المسافة بين اللقيمتين كطريقه فعاله لتحديد مكان العصب الكعبري أثناء الفتح الخلفي لعظمة العضد: دراسة جثيه وجراحية

### ملخص البحث

#### الخلفية:

ان القدرة على التنبؤ بشكل صحيح للنقطة التي يخترق فيها العصب الكعبري للحاجز الوحشى أثناء المدخل الخلفى لجراحة الذراع مفيد لاستكشاف العصب الكعبري بعد كسور عظمة العضد البعيدة.

#### الهدف من العمل:

يهدف العمل الحالي إلى إنشاء دليل عظمى بسيط لتوطين العصب الكعبري للنهج الخلفي الآمن لعظم العضد .

#### المواد والطرق:

تضمنت مادة هذا العمل أربعين طرفاً علويًا من العينات المحفوظة من الفورمالين والتي تم الحصول عليها من غرفة التشريح في قسم التشريح ، كلية الطب ، جامعة الإسكندرية ، و أربعون حالة جراحية تمر بعملية تثبيت خلفي لعظم العضد من غرفة العمليات في مستشفى الحضرة ، كلية الطب ، جامعة الإسكندرية. تضمنت القياسات المسافة بين الهامش العلوي للأخدود الحلزوني إلى طرف الظهارة الإنسيّة (القياس الإنسي) ، والمسافة بين الهامش السفلي للأخدود الحلزوني إلى طرف الظهارة الوحشيّة (القياس الوحشى) وقياس المسافة بين اللقيمتين في كل من الحالات الجثيه والجراحية ومقارنة مع بعضها البعض.

#### النتائج:

كشفت النتائج عدم وجود فروق ذات دلالة إحصائية بين قياسات كلا الجانبين في الدراسة الجثيه. في الوقت نفسه ، لا يوجد فرق ذو دلالة إحصائية بين قياسات الحالات الجثيه والجراحية. من القياسات السابقة ، حصلنا على معادله يمكننا من خلالها التنبؤ بالقياسات الإنسي والوحشى للعصب الكعبري من قيمة المسافة بين اللقيمتين.

#### الإستنتاج:

إن المسافة بين اللقيمتين هي طريقة موثوق بها وإجراء استئساخ لتوطين العصب الكعبري على الجزء الخلفي من عظم العضد خلال المخل الخلفي لعظم العضد التي يمكن استخدامها لتجنب إصابة العصب الكعبري.

الكلمات الرئيسية: العصب الكعبري ، المسافة بين اللقيمتين، المدخل الخلفى لعظمة العضد.