

Original research

Changes in the microstructure of the small intestine of sheep infected naturally with *Paramphistomum cervi* after treatment with Antitrem

Oksana Bibik¹ and Mahmoud Abdelhamid^{2*}

¹Department of Parasitology and Biology, Kemerovo State Medical University, Ministry of Health of the Russian Federation, Kemerovo, 650029, Russia

²Department of Parasitology, Faculty of Veterinary Medicine, Aswan University, Aswan, 81528, Egypt

Received: 15/3/2021

Accepted: 29/4/2021

© Unit of Environmental Studies and Development, Aswan University

Abstract:

It is clear that the chemical structure of a drug and its process, which are the determinants of the degree of activity an anthelmintic have on the organs and tissues of trematodes, as well as their hosts. This study demonstrates changes in the microstructure of the small intestine of sheep with impulsive Paramphistomiasis after treatment with Antitrem. Seven days after giving “Antitrem (contain oxcyclosanide and pyrantela pamoate, OLKAR Release, Russia)” at a dose of 200 mg/kg once per orally, fixed in 70% alcohol and administered according to generally accepted histological methods, the small intestine of the sheep which it was administered to was impulsively attacked by *Paramphistomum cervi*. Partial atrophy of intestinal mucosa, common dystrophic changes in the epithelium, and destruction of individual goblet cells represented the microstructural changes in the small intestine of infected sheep with *Paramphistomum cervi* after treatment with Antitrem. Microstructural changes in the small intestine of the sheep are composed of proliferative procedures, a reduction in the content of carbohydrate compounds, and a change in the protein component in the tissues of the organ and stagnation of the secretory product in the cells.

Keywords: *Paramphistomiasis*; Trematodes; Anthelmintic; histological; Small intestine

1- INTRODUCTION

An unfavorable epizootic situation in the world for trematodes not only for ruminants, but also for humans were shown by an analysis of literary sources (Ooms *et al.*, 1995; Mas-Coma *et al.*, 2005; Samn, 2017; Bibik *et al.*, 2020). There is a robust effect of Trematodes on livestock production and consequent in substantial economic downturn, such as stunted growth and diminution, as well as low production of milk, meat and wool. The presence of fascioliasis, paramphistomiasis, dicroceliosis, opisthorchiasis, clonorchiasis and a number of other trematodes transmitted through fish and mollusks was shown by an analysis of epizootic situation of helminth infections in animals in the Russian Federation (Gorohov *et al.*, 2014; Puzanova, 2019).

Corresponding author*: E-mail address: Mahmoud.ahmed2509@aswu.edu.eg

Trematode parasites of ruminant livestock have a worldwide distribution and zoonotic importance amongst the helminths. In the provinces belonging to the Nile Delta of Egypt, there is a high prevalence of fascioliasis (El-Tahawy *et al.*, 2017). In Egypt, *Heterophyes heterophyes*, *Schistosoma mansoni*, and *Fasciola* species are recorded in humans. Trematode infection rates in rural areas are relatively higher than in urban areas (El-Shazly *et al.*, 2006). There is a high occurrence of fascioliasis in the population of Egypt (Soliman, 2008). Human Fascioliasis is registered in Scandinavia (Holm and Kristoffersen, 2002), Turkey (Kabaalioglu *et al.*, 2007), East Asia (Vietnam, Japan and Korea), and also Bolivia, Ecuador, Iran, Peru and Yemen (Ooms *et al.*, 1995).

It is of much relevance to scientist from different countries in the world, to study the microstructure of organs and tissues of trematodes, histochemical and pathomorphological studies in the host-parasite system with trematodes and the effect of anthelmintic drugs on the destruction of this system remain relevant for scientists from different countries (Periago *et al.*, 2008). A great deal of work is dedicated to the study of the morphology of *Paramphistomum spp.* (Nikander and Saari, 2007; Burdakova, 2012; Panyarachun *et al.*, 2013; Choudhary *et al.*, 2015). Paramphistomes are spreading worldwide, particularly in the warmer regions such as: Australia, Africa and India, and primarily, it infects cattle, goats and sheep. Additionally, there are certain species of paramphistomes with medical importance beside economic value, that infect human (Samn, 2017). *Paramphistomum cervi* is thought-out to be one of the most important species of Paramphistomes. Adult flukes are situated in the rumen of ruminants and immature flukes in the small intestine mainly in the duodenum. *Paramphistomum cervi* is one of sheep parasite that harmfully affects their health depending upon the number and developmental stages of the helminthes present (Sindičić *et al.*, 2017). Hexosaminoglycans, common proteins, and mucoproteins were discovered in the tegument, intestines, and parenchyma, which provide the basis for the functional morphology of helminths, according to histochemical methods (Bibik *et al.*, 2019; Bibik *et al.*, 2020). The effect of anthelmintic drugs during chemotherapy on the breakdown of this "parasite-host" system, as well as the effect of drugs from various chemical groups on the parasite and host, as components of this system, are of particular interest (Ooms *et al.* 1995).

Therefore, the study of the chemistry of cells and tissues, and consequently, the chemical basis of the deworming process, is of paramount importance in the development of effective measures to combat helminthiasis. The aim of the study was to study changes in the microstructure of the small intestine of sheep with spontaneous paramphistomiasis after treatment with anthelmintic "Antitrem".

2- MATERIALS AND METHODS

Animal and experimental design:

The experiment was carried out at Kemerovo State University, Faculty of Medicine, Kemerovo, Russia. The study used 10 intestines for slaughtered sheep diagnosed with *Paramphistomun carvi* infection in a slaughterhouse in Kemerovo, Russia.

Anthelmintic and Histopathological examination:

Antitrem, an anthelmintic, was used to treat the infected sheep seven days before slaughter. Antitrem, OLKAR Release, Russia, which contains oxcyclosanide and pyrantela pamoate, was given to infected sheep at a dose of 200 mg/kg by active substance once per orally in 70% alcohol and processed using widely accepted histological methods, 5-6 µm thick paraffin

sections were stained using histological and histochemical methods and examined under a light microscope. The experiment was conducted in accordance with animal welfare standards and was based on the EU directive (86/609/EEC) as well as the Helsinki Declaration.

3. RESULTS AND DISCUSSION

According to its detrimental effect on ruminant health and wellbeing, gastrointestinal parasitism is a global problem that is limiting ruminant efficiency (Dyab *et al.*, 2018; Paul *et al.*, 2020; Abdelhamid *et al.*, 2021). Infections of ruminant livestock with paramphistomes have become more common and are still widespread. Extreme enteritis with a large number of immature flukes is the most common clinical symptom of paramphistomosis in sheep. A characteristic and persistent foetid diarrhoea is accompanied by weakness, depression, dehydration and anorexia (Priya *et al.*, 2013). Domestic ruminant mortality due to immature paramphistomes is extremely high, ranging from 80 to 90% (Hassan *et al.*, 2005). The use of chemotherapeutic anthelmintic drugs is typically used to control paramphistome infection. Anthelmintic resistance has developed as a result of indiscriminate use of these medications (Verma *et al.*, 2006).

In the current, we discovered that partial atrophy of the intestinal mucosa, common dystrophic changes in the epithelium and destruction of individual goblet cells characterize microstructural changes in the small intestine of *Paramphistomum cervi* infected sheep after Antitrem treatment. Proliferative hyperplastic manifestations predominate in the small intestine tissues, manifested by an increase and proliferation of villus epithelial cells and mucous membrane crypt. The villi and crypt epithelium were high, with basophilic nuclei that were intensely stained and oxyphilic cytoplasm with large and numerous secretory inclusions in the apical sections of cells (Figure 1).

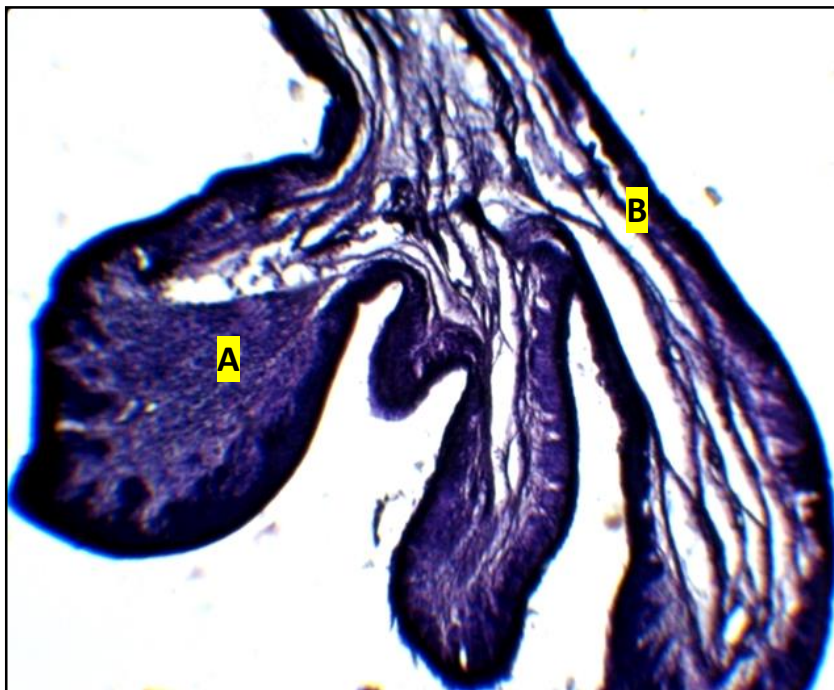

Figure 1. Hematoxylin-eosin-stained fragments of the sheep's small intestine; (A) Intestinal villi and (B) Lamina propria.

There are several massive and basophilic nuclei in the epithelium of Lieberkühn glands. The presence of the several nuclei, as well as a rise in size and basophilia, are signs of dysplasia in the intestinal epithelium (Kheirandish *et al.*, 2017). The presence of villi coated in massive layers of

degenerative proliferating epithelium confirms the presence of proliferation. Villi that have thickened have lateral outgrowth. Staining reactions with histochemical dyes show a poor manifestation of proliferative cellular elements' functional capacity, which indicates the degeneration of the intestinal epithelium layer caused by anthelmintic chemotherapy (Steuer *et al.*, 2018). For the first time, we present the progression of the stages of the pathogenesis processes in the small intestine of sheep with spontaneous paramphistomiasis after treatment with Antitrem in the form of a diagram using histological and histochemical methods (Figure 2).

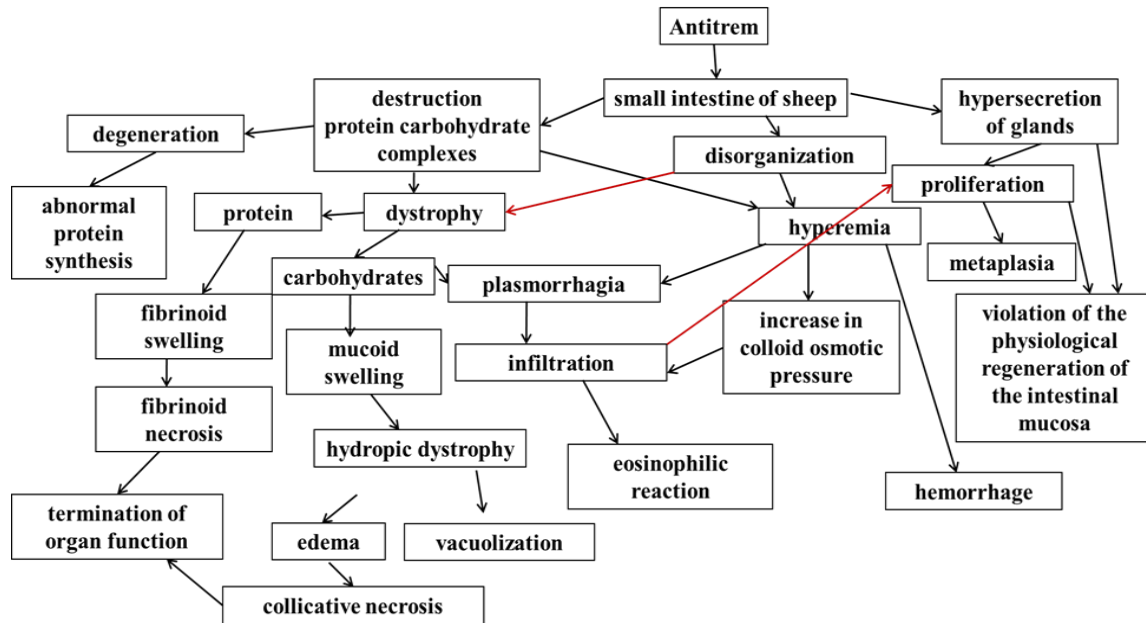


Figure 2. Pathogenesis processes in the small intestine of sheep with spontaneous paramphistomiasis after treatment with Antitrem are depicted in a diagram.

The parasitization of *Paramphistomum cervi* in the small intestine of spontaneously invaded sheep as an example of component adaptation during the formation of the "parasite-host" system revealed adhesion in the microstructure "tegument trematodes – epithelial tissue of the villi of the small intestine" with sheep paramphistomiasis at the level of contact between the two glycocalyx. The reciprocal relationships between the components of a single parasite-host system are confirmed by the adhesion formed by histological staining (Bibik *et al.*, 2019; Bibik *et al.*, 2020).

An aggregation of eosinophils was observed after chemotherapy with Antitrem in the intestinal villi, with the cell membrane preserved, the nuclei necrotic (pyknotic), the granular cell inclusions lysed under the influence of Antitrem, and the cytoplasm of the cells stained orange according to Mallory's triple stain (Samn, 2017). The anthelmintic drug is thought to block the eosinophilic effect on the surrounding host tissues, resulting in their death. This shows how important this drug is and how likely it is to be used in practice. In cattle and goats, oxcyclozanide is highly effective against both juvenile and adult paramphistomids (Paraud *et al.*, 2009).

The sensitizing effect of somatic antigens (allergens) of dead helminths can be linked to the negative effects of anthelmintic therapy on the health of an invading species. Antigens of helminths found in the intestine's lumen will infiltrate host tissue due to damage to the epithelial coating, allowing large molecular proteins-antigens to be absorbed, exacerbating allergic reactions (Geldhof *et al.*, 2007; King and Li, 2018; Bibik *et al.*, 2020). As a result, it is important

that the helminth is removed during deworming. Antitrem's intervention was responsible for this. The drug's single action has no discernible impact on the host. When the simultaneous action on the host and the parasite contributes to the detachment of trematodes from the host organ, the villi of the small intestine, and the parallel outflow of contents from the organ contributes to the independent removal of the fluke from the host organism, without decomposition of it and exerting additional action, thereby exacerbating the effect of the drug on the host or when the simultaneous action on the host and the parasite contributes to the independent removal of the fluke.

Conclusions

Proliferative processes, a decrease in the content of the carbohydrate compounds, a change in the protein portion in the tissues of the organ, and stagnation of the secretory substance in the cells are all microstructural changes in the small intestine of sheep during spontaneous paramphistomiasis after Antiterim treatment. Histological and histochemical tests provide useful information about the drug's effect on the host organism.

References

- Abdelhamid M., Vorobiev V.I., Lapteva M.L., Dyab A.K. (2021). Combined effect of monieziosis and hypomicroelementosis on some hematological, biochemical and hormonal parameters in Merino sheep. *Pakistan veterinary journal*.41(1) -107-111.
- Bibik O.I., Arkhipov I.A., Nacheva L.V., Boborykin M.S. (2020). Adaptation of the Relationship in the "Parasite-Host" System with Parasitism *Paramphistomum cervi* in the Small Intestine of sheep. *Russian Journal of Parasitology*.14(1) -46-52.
- Bibik O.I., Nacheva L.V. (2019). Morphofunctional Peculiarities of *Fasciola Hepatica* Organs Changes After Treatment of Sheep with Triclabendazole in Case of Fasciolosis. *Russian Journal of Parasitology*.13(2) -64-72.
- Burdakova E.N. (2012). Acetabulum of some members of the order Paramphistomatida (Plathelminthes, Trematoda). *Yaroslavl Pedagogical Bulletin*.4(3) -103-111.
- Choudhary V., Hasnani J.J., Khyalia M.K., Pandey S., Chauhan V.D. (2015). Morphological and histological identification of *Paramphistomum cervi* (Trematoda: *Paramiphistoma*) in rumen of infected sheep. *Vetrinary World*.8(1) -125-129.
- Dyab A.K., Marghany M.E., Othman R.A., Ahmed M.A., Abd-Ella O.H. (2018). Hydatidosis of Camels and Sheep Slaughtered in Aswan Governorate, Southern Egypt. *Russian Journal of Parasitology*.12(3) -33-41.
- El-Shazly A.M., El-Nahas H.A., Soliman M., Sultan D.M., Abedl Tawab A.H. (2006). The reflection of control programs of parasitic diseases upon gastrointestinal helminthiasis in Dakahlia Governorate, Egypt. *Journal of the Egyptian Society of Parasitology*.36(2) -467-480.
- El-Tahawy A.S., Bazh E.K., Khalafalla R.E.(2017). Epidemiology of bovine fascioliasis in the Nile Delta region of Egypt: Its prevalence, evaluation of risk factors, and its economic significance. *Veterinary World*.10(10) -1241-1249.
- Geldhof P., De Maere V., Vercruyse J., Claerebout, E. (2007). Recombinant expression systems: the obstacle to helminth vaccines. *Trends in Parasitology*.23(11) -527-532.
- Gorohov V.V., Samoylovskaya N.A., Peshkov R.A. (2014). Forecast of epizootic situation on main helminthosis in Russian Federation for the year 2014. *Russian Journal of Parasitology*. (2) -32-33. (In Russian)

- Haseeb A.N., El-Shazly A.M., Arafa M.A., Morsy A.T. (2002). A review on fascioliasis in Egypt. *Journal of the Egyptian Society of Parasitology*.32(1) -317-354.
- Hassan S.S., Kaur K., Joshi K., Juyal P.D. (2005). Epidemiology of paramphistomosis in domestic ruminants in different districts of Punjab and other adjoining areas. *Journal of Veterinary Parasitology*.19(1) -43-46.
- Holm P.I., Kristoffersen E.K. (2002). A Scandinavian case of domestically acquired human fascioliasis. *Scandinavian Journal of Infectious Diseases*.34(7) -548-550.
- Kabaalioglu A., Ceken K., Alimoglu E., Saba R., Cubuk M. (2007). Hepatobiliary Fascioliasis: Sonographic and CT Findings in 87 Patients during the Initial Phase and Long-Term Follow-Up. *American Journal of Roentgenology*.189(4) -824-828.
- Kheirandish R., Nourollahi-Fard S.R.,Yadegari Z.(2014). Prevalence and pathology of coccidiosis in goats in southeastern Iran. *Journal of parasitic diseases*.38(1) -27-31.
- King I.L., Li Y. (2018). Host–parasite interactions promote disease tolerance to intestinal helminth infection. *Frontiers in immunology*.9 -2128.
- Mas-Coma S., Bargues M.D., Valero M.A. (2005). Fascioliasis and other plant-borne trematode zoonoses. *International Journal for Parasitology*.35(11-12) -1255-1278.
- Nikander S., Saari S. (2007). Notable seasonal variation observed in the morphology of the reindeer rumen fluke (*Paramphistomum leydeni*) in Finland. *Rangifer*.27(1) -47-57.
- Ooms H.W., Puylaert J.B., Van der Werf S.D. (1995). Biliary fascioliasis: US and endoscopic retrograde cholangiopancreatography findings. *European Radiology*.5 -196-199.
- Panyarachun B., Ngamniyom A., Sobhon P., Anuracpreeda P. (2013). Morphology and histology of the adult *Paramphistomum gracile* Fischoeder, 1901. *Journal of Veterinary Science*.14(4) -425-432.
- Paraud C., Gaudin C., Pors I., Chartier C. (2009). Efficacy of oxclozanide against the rumen fluke *Calicophoron daubneyi* in experimentally infected goats. *Veterinary Journal*.180(2009) -265–267.
- Paul B.T., Jesse F.F.A., Chung E.L.T., Che’Amat A., Mohd Lila M.A. (2020). Risk Factors and Severity of Gastrointestinal Parasites in Selected Small Ruminants from Malaysia. *Veterinary Sciences*.7(4) -208.
- Periago M.V., Valero M.A., Sayed M.E., Ashrafi K., Wakeel A.E. (2008). First phenotypic description of *Fasciola hepatica/Fasciola gigantica* intermediate forms from the human endemic area of the Nile Delta, Egypt. *Infection, Genetics and Evolution Journal*.8(1) - 51-58.
- Priya P., Veerakumari L., Raman M. (2013). Anthelmintic efficacy of *Acacia concinna* against paramphistomes in naturally infected sheep. *Journal of Applied Animal Research*.41(2) - 183-188.
- Puzanova E.V.(2019). Forecast of epizootic situation in main helminthosis of farm livestock in the Russian Federation for 2019. *Russian Journal of Parasitology*.13(2) -28-35.
- Samn A.A. (2017). A Molecular and Microscopically Studies of *Calicophoron Microbothrium* (Paramphistomatidae). *The Egyptian Journal of Hospital Medicine*. 66 -28- 39.
- Sindičić M., Martinković F., Strišković T., Špehar M., Štimac I. (2017). Molecular identification of the rumen flukes *Paramphistomum leydeni* and *Paramphistomum cervi* in a

concurrent infection of the red deer *Cervus elaphus*. *Journal of Helminthology*.91(5) - 637-641.

Soliman M.F. (2008). Epidemiological review of human and animal fascioliasis in Egypt. *Journal of Infection in Developing Countries*.2(3) -182-189.

Steuer A.E., Loynachan AT., Nielsen MK. (2018). Evaluation of the mucosal inflammatory responses to equine cyathostomins in response to anthelmintic treatment. *Veterinary immunology and immunopathology*.199(3) -1-7.

Verma S.K., Gupta M.P., Juyal P.D. (2006). Efficacy of oxclozanide and triclabendazole in buffaloes infected with paramphistomosis. *Journal of Veterinary Parasitology*.20(1) -61-64.