

Young adult with liver cirrhosis, portal vein thrombosis, a reported case of α -1anti-trypsin deficiency.

Sameh Seif¹, Mohamed A. Ezzel Arab², Mohammad A.Hassanein¹ Mohamed El Kassas¹, Selim Wadie³, Khalid Zalata⁴, Helmy El Gazzar⁵, Mohamed Hassany¹, Amin Abdel Baki¹

1- Tropical Medicine Department National Hepatology and Tropical Medicine Research Institute (NHTMRI), Cairo, Egypt.

2-Internal Medicine Department, National Hepatology and Tropical Medicine Research Institute, Cairo, Egypt.

3- Radiology Department, National Hepatology And Tropical Medicine Research Institute, Cairo, Egypt.

4- Pathology Department, Faculty of Medicine, Mansoura University, Egypt.

5- Clinical Pathology Department, Hearing and Speech Institute, Egypt

Introduction

Alpha-1 antitrypsin is a protein with inhibitory capability over the proteolytic enzyme elastase. Since its first description in 1963, over 100 different α 1 AT alleles have been described (*Folch E., et al, 2007*). The major clinical manifestations of α 1 AT deficiency relate to the function of α 1 AT and where it is made. α 1 AT serves as an inhibitor of neutrophil elastase (NE), a powerful, destructive proteolytic enzyme stored in neutrophils (*Carrell R. W, et al., 1982*) (*Janoff A, .1985*). The liver is the major site of α 1 AT gene expression, releasing 2 g of α 1 AT into the circulation daily. α 1 AT diffuses into most organs, where it protects extracellular structures from attack by NE released by activated or disintegrating neutrophils. The lower respiratory tract is particularly vulnerable to deficiency of α 1 AT, which normally represents > 90% of the anti-NE protective screen of the alveolar walls (*Gadek J. E., et al., 1981*) (*Wewers, M. D., et al., 1987*). When serum α 1 AT levels are < 11 μ m, there is insufficient α 1 AT to protect the lower respiratory tract from its burden of NE, permitting progressive destruction of the alveoli, which culminates in emphysema (*Wewers, M. D., et al., 1987*). The pathogenesis of the liver disease is less well understood, but relates to the fact that hepatocytes are the major site of α 1 AT synthesis, and that certain mutations of the

α 1 AT gene cause derangements in the intracellular processing of α 1 AT, culminating in hepatocyte injury (*Errickson S.,1986*). The most severe form of deficiency is the homozygous expression of the Z allele or PI*ZZ, when this expression occurs, it accounts for 95% of cases of severe α 1 AT deficiency. The three organs most commonly affected by α 1 AT are the lungs, liver and skin. α 1 AT deficiency is the most frequently recognized genetic risk factor for chronic obstructive pulmonary disease (COPD). Even though it remains under diagnosed, its importance continues to grow in the field of solid organ transplantation, accounting for 8-9% of all lung transplants. α 1 AT is the most common metabolic liver disease requiring liver transplantation in children.

The presence of cirrhosis in alpha-1-antitrypsin deficiency is low, approximately 2.2/100,000 for ZZ homozygotes. The male-to-female ratio was 2 to 1. In one-third of the patients alcohol could have been a co-adjuvant or aggravating factor in the liver disease (*Folch E.,et al,2007*).

We describe a unique case of a 27 year-old man with α 1 AT, presented with liver cirrhosis portal vein thrombosis & multiple bony deformities.

Case presentation:

male patient 27 years old was admitted to tropical medicine department at (NHTMRI). works as a manual worker in printing factory ,he lives and born in Manawat,Giza, Egypt, married 5 years ago and he is father of 1 daughter 2 years old ,he used to smoke 20 cigarettes/day for 12 years with history of Hashish and alcohol intake. Positive contact to canal water and received anti-bilharzial treatment in the form of tablets 3 doses the last one is 10 years ago.

The main complaint of the patient is swelling of both lower limbs one year before admission.The condition started by gradual onset ,slowly progressive course ,the patient noticed swelling of both lower limbs up to knees ,the condition is associated with fever ,yellowish discoloration of the sclera and dark colored urine ,the patient sought medical advice & was admitted to fever hospital, stay for 2 weeks then discharged after fever disappeared & jaundice subsided . Few months later the patient noticed increase of the lower limb oedema and was referred to NHTMRI, during hospital stay the patient developed an attack of haematemesis, about 1 cup of fresh blood not followed by melena and stopped spontaneously.The patient gives past history of 2 orthopedic operations (correction of deformity).Another operation to repair tendon cut. There is positive consanguinity for his parents. His grandfather was diabetic.

By examination the followings are noticed:
The vital signs of the patient are normal. There is tinge of jaundice. Congenital small bony swelling in the right mandible. Congenital maldeformity in the hands (the fingers of the left hand are thinner and taller than that of the right hand).1st degree clumping of fingers.Fine tremors of both hands Scar in the left index finger (tendon repair operation). Congenital maldeformity in both lower limbs (knock knees).scar of the orthopedic operation in the right thigh (correction of deformity).Both feet show marked pitting oedema.Right leg shows moderate pitting oedema up to knee. Left leg shows mild pitting oedema up to knee. Chest and heart are clinically free.

The upper border of the liver is encountered in the 5th intercostal space MCL, and the lower border is not felt. The lower border of the left lobe is felt 1 finger below xiphisternum with sharp border and firm consistency. The spleen & both kidneys are not felt; the Traub's area is resonant. No ascites is felt clinically.

The laboratory and imaging studies reveal the followings:

Urine analysis: Alkaline,Protein:(+),Blood:(+),Bilirubin(+),Pus cells (3-4),R.B.Cs:(6-8). AST: 109 U/L (0-40), ALT: 59 U/L (0-40).T.BIL :2.65 mg/dl, D.BIL :1 mg/dl,Albumin :2.3 g/dl .FBS: 96 mg/dl, Urea: 24 mg/dl, Creat. : 0.75 mg/dl .Uric acid: 3.5 mg/dl.CBC:HB: 12.5 g/dl, MCV: 87.6 fl, MCH: 29 pg, MCHC: 33.2 g/dl WBCs: 3900,Gran. :54%,Lymph.:39 %,Platelets :116,000 Comment: mild normocytic normochromic anemia, pancytopenia.E.S.R: 1ST hour 25,INR: 1.39,AFP: 1.2 IU/ml, HBsAg: negative,HCV Ab: negative,ANA : negative, AMA: negative,ASMA: negative.S.Iron:90 ug/dl (60 – 160) µg/dL. S.ferritin:80 ug/L (20-300) µg/L.S.copper:100ug/dl(70-40)ug/dl.ceruloplasmin:62.9mg/dl (17.1-65.1)mg/dl.S.Homocysteine:13.3umol/l(5-15)umol/l,decreased activity of protein C activity:50%(70-140)% .borderline protein S activity:71%(70-140)% .Quantitative serum Alpha-1 Antitrypsin:1.37 g/l(0.9-2.09)g/l Slit-lamp examination of the eyes shows no kayser Flischer ring. abdominal ultrasonography reveals Heterogenous liver with portal vein thrombosis. Splenomegaly with dilated lienorenal collaterals.No ascites. venous duplex on both lower limbs is normal. Chest x ray shows slight obliteration of the right costo-phrenic angle,cardiac shadow is normal. Spiral CT scan of the abdomen with contrast shows cirrhotic liver with no focal lesions, main portal vein thrombosis.Lienorenal collaterals, right sided pleural effusion, CT Chest shows bilateral apical emphysematous bullae & mild right sided pleural effusion.

Young adult

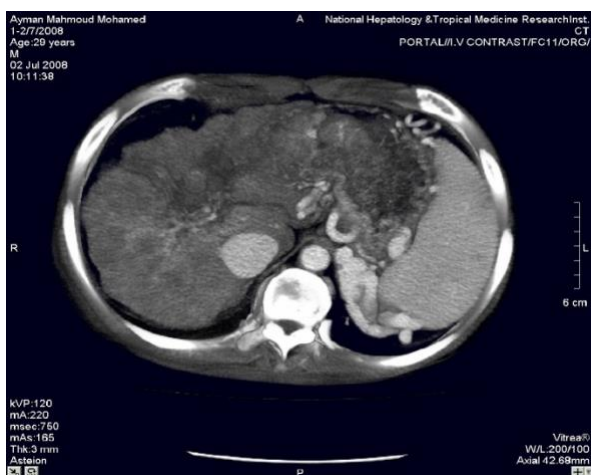


Fig 1) CT scan of the abdomen showing cirrhotic liver, portal vein thrombosis.

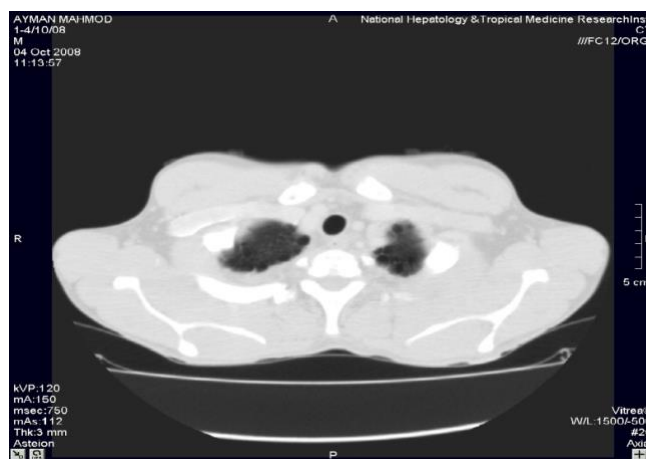


Fig 2) CT chest showing apical emphysematous bullae.

Upper GI endoscopy reveals esophageal varices grade I-II Incompetent cardia, then liver biopsy revealed a picture consistent with alpha-1-antitrypsin deficiency with early cirrhotic changes associated mild chronic cholestasis. Pulmonary function tests reveal mild restrictive lung disease. We start treatment with warfarin in small increasing dose aiming for portal recanalization and to prevent further thrombosis in other vessels.

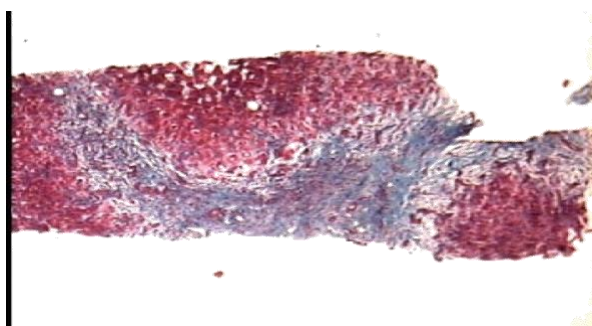


Fig 3) prominent bridging fibrosis & occasional nodules-surrounded by fibrous septa

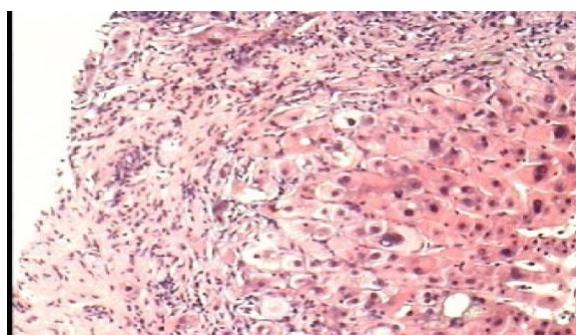


Fig 4) Interface hepatitis "piece meal necrosis"

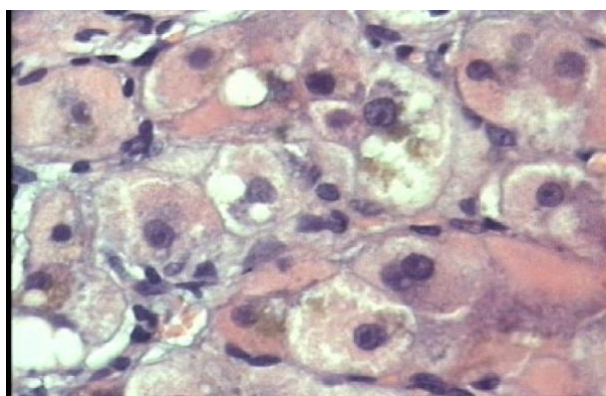


Fig 5) mild cholestasis. Globules

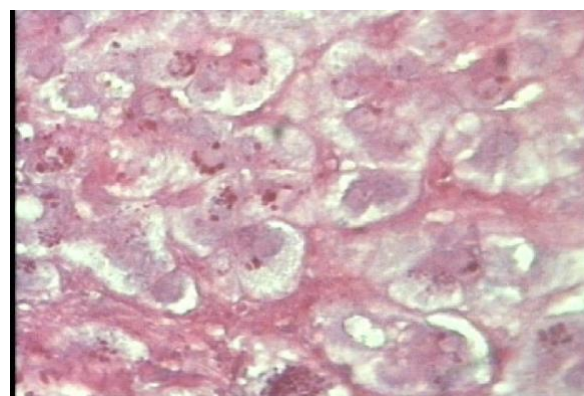


Fig 6) PAS positive-diastase resistant In periportal hepatocytes.

Discussion

Cases of alpha1-Antitrypsin deficiency may be sporadic cases but it should be in our differential diagnosis for screening of cases of liver cirrhosis with negative viral markers especially if it is associated with unexplained chest problems. This case is presented with portal vein thrombosis as a 1 AT is one of the major inhibitors of the intrinsic pathway of coagulation, concomitant decrease of protein C activity and low normal activity of protein S may pave the way for PV thrombosis in this case, on contrary there are published cases of a 1 AT deficiency associated with Henoch-Schönlein purpura (HSP) (*Patterson CC, et al ,2005*)(*Meier P ,et al ,2001*) Replacement therapy may not be of value in such a case as it will not lead to reversal of hepatic fibrosis, cessation of smoking is the first line management of this case, oral warfarin should be adjusted to obtain portal patency then liver transplantation should be considered, it is not only the curative treatment of the hepatic condition but also it will lead to stoppage of progression for the pulmonary complication like emphysema, the 5 year survival rate in these cases is excellent and may reach up to 95 %, also screening of the family members is mandatory for early diagnosis and management .

References

- 1- Folch E , Shenoy R , Atul C , Pettersson G, Winnans C , Marie M., Liver transplantation in a lung transplant recipient for alpha 1 antitrypsin deficiency .Chest / 132 / 4 / October, 2007 Supplement.
- 2- Carrell, R. W., J. Jeppson, C. Laurell, S. O. Brennan, M. C. Owen, L. Vaughan, and D. R. Boswell. 1982. Structure and variation of human al-antitrypsin. *Nature (Lond.)*. 298:329-333.
- 3-Janoff, A. 1985. Elastases and emphysema: current assessment of the protease-antiprotease hypothesis. *Am. Rev. Respir. Dis.* 132:417-433.
- 4-Gadek, J. E., R. L. Zimmerman, G. A. Fells, S. I. Rennard, and R. G. Crystal. 1981. Antielastases of the human alveolar structures: implications for the protease-antiprotease theory of emphysema. *J. Clin. Invest.* 68:889-898.
5. Wewers, M. D., M. A. Casolaro, S. Sellers, S. C. Swayze, K. M. McPhaul, and R. G. Crystal. 1987. Replacement therapy for alpha I-antitrypsin deficiency associated with emphysema. *N. Engl. J. Med.* 316:1055-1062.
6. Erickson, S., J. Carlson, and R. Velez. 1986. Risk of cirrhosis and primary liver cancer in alpha,-antitrypsin deficiency. *N. Engl. J. Med.* 314:736-739.
7. Patterson CC, Ross P Jr, Pope-Harman AL, Knight DA, Magro CM. 2005. Alpha-1 antitrypsin deficiency and Henoch-Schönlein purpura associated with anti-neutrophil cytoplasmic and anti-endothelial cell antibodies of immunoglobulin-A isotype. *J Cutan Pathol.* Apr;32(4):300-6.
8. Meier P, Dayer E, Lemoine R, Blanc E. 2001. Henoch-Schönlein purpura with IgG PR3-ANCA in a PiZZ alpha 1-antitrypsin deficient patient. *Nephrol Dial Transplant.* Sep;16(9):1932-5.

حالة مسجلة لنقص إنزيم ألفا وان المضاد للتريبسين وتسببه في حدوث جلطة بالوريد البابي وتليف بالكبد

سامح سيف¹, محمد علي عز العرب², محمد أحمد حسنين¹, محمد القصاص¹, سليم وديع³, خالد
زلطة⁴, حلمي الجزار⁵, محمد حساني¹, أمين محمد عبد الباقي¹
قسم طب المناطق الحارة¹, قسم الأمراض الباطنة², قسم الأشعة³
المعهد القومي للأمراض المتوطنة و الكبد
قسم الباثولوجي, كلية الطب, جامعة المنصورة⁴
قسم الباثولوجيا الإكلينيكية, معهد السمع والكلام⁵

مقدمة:

منذ إكتشاف المرض عام 1963 ظهرت العديد من الطرازات الجينية للمرض وصلت
حوالي 100 طراز. وحيث أن الأعراض المرضية لنقص أنزيم ألفا وان المضاد
للتريبسين مرتبطة بشكل وثيق مع الأعضاء التي يعمل بها هذا الأنزيم لذا فإننا غالباً
ما نشاهد أعراضه المرضية في الكبد والرئتين .

الحالة:

تم رصد حالة شاب في العقد العشريني وهو يعاني من جلطة مزمنة بالوريد البابي
الكبدية وبعد إجراء التحاليل وعمل أشعات عادية ومقطعية على البطن والصدر وعمل
وظائف تنفس وعينة كبدية للمريض, ثبتت إصابة هذا الشاب بمرض نقص أنزيم ألفا
وان المضاد للتريبسين.

التوصيات:

ينبغي وضع مرض نقص أنزيم ألفا وان المضاد للتريبسين في الحسبان أثناء البحث
عن أسباب اعتلال الكبد بالتليف عل الرغم من عدم شيوع المرض. تعتبر زراعة الكبد
هي الحل الأمثل لهذا المريض من أجل إيقاف تدهور حالة الكبد والرئتين أيضاً .