

Management of Calcific Supraspinatus Tendinitis A Systematic Review

H.A.Elattar¹, A.M.Halawa¹ and T.A.Zayed²

¹Orthopedic Surgery, Dept., Faculty of Medicine, Benha Univ., Benha, Egypt

²Kafr Elsheikh General Hospital Add: Kutour, Gharbia, Egypt

Email: zayed_tarek@yahoo.com

Abstract

Background: The objectives of this comprehensive quantitative review of the treatment of calcific supraspinatus tendinitis were to investigate if there is a sustainable positive effect on outcomes after treatment with extracorporeal shockwave therapy (ESWT) or ultrasound (US)-guided needling and to compare these results with those of treatment with arthroscopic surgery. **Method:** The PRISMA (Preferred Reporting Items for Systematic Reviews and Meta-Analyses) guidelines were followed to conduct this review. A systematic literature search was conducted in December 2019 to identify relevant clinical articles in peer-reviewed journals with at least 3 months' follow-up. Each article was scored using the Coleman Methodology Score. The primary endpoints were functional outcome and radiologic change in the size of the calcific deposit. **Results:** Twenty-four studies were included (1,509 shoulders). The mean Coleman Methodology Score for the included studies was 77.1 ± 9.1 . Overall, good to excellent clinical outcomes were achieved after treatment with either ESWT, US-guided needling, or arthroscopic surgery, with an improvement in the Constant-Murley score ranging between 26.3 and 41.5 points after 1 year. No severe side effects or long-term complications were encountered. **Conclusions:** Patients can achieve good to excellent clinical outcomes after ESWT, US-guided needling, and arthroscopy for calcific tendinopathy of the shoulder. Side effects and posttreatment complications should be taken into account when a decision is being made for each individual patient. Physicians should consider ESWT and US-guided needling as minimally invasive treatment options when primary conservative treatment fails. Arthroscopy can safely be used as a very effective but more invasive secondary option, although the extent of deposit removal and the additional benefit of subacromial decompression remain unclear. **Keywords:** Calcific Tendinitis, Treatment, ESWT, US-PICT, Arthroscopy, supraspinatus Management UGN.

Keywords: Calcific, Supraspinatus, Tendinitis.

1. Introduction

Supraspinatus calcific tendinopathy is the most common cause of shoulder pain, with the prevalence in the general population found to range between 5 and 39%, and the prevalence of the condition is highest among the third and fifth decade of life. The etiopathogeny of calcific tendinopathy is still not clear, although its origin may be multifactorial, the result of a combination of extrinsic factors (anatomical or biomechanical) and intrinsic factors (changes related to age, vascularity, overloading, genetic, hormonal factors, etc.). [1]

The natural history of the disease can be divided into three distinct clinical stages: acute, subacute and chronic. The main clinical manifestation is pain, which may or may not be associated with acute or gradual restriction of movements. [2]

X-ray shows a focus of calcification within the supraspinatus. This may be well-defined, but can be ill-defined if there is extravasation into the overlying subacromial bursa. The presence of calcification is readily identified on ultrasound scanning, which is more sensitive than X-ray. [3]

Numerous treatments have been advocated for calcific tendinitis. The initial treatment is usually conservative. In patients with severe or persisting symptoms, more invasive therapy is indicated. Numerous types of conservative treatments have been described. These include calcium deposit needling and lavage (barbotage), subacromial corticosteroid injections (SAI)

and extracorporeal shock wave therapy (ESWT). Nevertheless, failure of these methods may necessitate the need for surgical management. [4]

2. Materials and Methods

This review was performed and reported following the principles of the PRISMA (Preferred Reporting Items for Systematic Reviews and Meta-Analyses) guidelines. [5] The literature search conducted for this systematic review was limited to clinical studies concerning the minimally invasive and arthroscopic treatment of chronic calcific supraspinatus tendinitis with at least 3 months' follow-up. Three interventions were included: ESWT, US-guided needling, and arthroscopic surgery.

2.1. Inclusion criteria

- Trials involving patients aged 18 years or older with symptoms of subacromial pain syndrome in combination with radiographically or sonographically proven calcific tendinitis .
- Trials focusing on outcome measures for pain, shoulder function and change in radiologic size of the calcific deposit.

2.2. Exclusion criteria

- Studies involving patients with evidence of a full-thickness rotator cuff tear (physical examination, sonography, or magnetic resonance imaging).
- Systemic inflammatory disorders.
- Previous surgery on the shoulder.
- Instability of the shoulder .

- Dysfunction of the upper limb .
- ESWT/needling within the past year .
- Acute bursitis, osteoarthritis of the glenohumeral or acromioclavicular joint.

3. Results

The search of the Medline, Scopus, PubMed databases provided a total of 942 citations (fig. 1). After adjustment for duplicates, 393 studies remained. Of these studies, 369 were discarded for not meeting the inclusion criteria after review of the abstracts. 24 studies met the inclusion criteria and were included in the systematic review.

We categorize papers according to used treatment techniques. We will focus on the three main treatment techniques: ESWT, US-guided needling and arthroscopic surgery.

3.1. Patient Characteristics

The total number of the patients in this study is 1,509 patients. In ESWT group is 484 patients. In US-guided needling group is 648 patients. In arthroscopic surgery is 377 patients. The longest mean follow-up time was 4 years for the ESWT studies, 10 years for the US-guided needling studies, and 8 years for the arthroscopy studies .

The mean age for the three group studies is 49.82 yr. The mean age for ESWT group is 52.81, for US-

guided needling group is 49.02, for arthroscopic surgery is 47.64.

The mean number of females related to male (F/M) for the three group studies is 41.3/27.8. The mean number F/M for ESWT group is 44.5/30.2, for US-guided needling group is 55.3/31.3, for arthroscopic surgery is 24/22.

The mean duration of symptoms(mo.) for the three group studies is 31.18. The mean duration of symptoms for ESWT group is 34.4, for US-guided needling group is 28.6, for arthroscopic surgery is 27.54.

The mean follow-up(mo.) for the three group studies is 18.51. The mean follow-up for ESWT group is 7.13, for US-guided needling group is 8.97, for arthroscopic surgery is 39.45 .

3.2. Outcome Measures (Type and Timing)

Assessments of pain, shoulder function, and the radiologic appearance of calcific resorption after treatment were the most frequently reported outcome measures for ESWT (table.1), for US-guided needling (table.2) and for arthroscopic surgery (table.3). All studies reported on shoulder function. The Constant-Murley Scale (CMS) and visual analogue score (VAS) were the most commonly reported shoulder function outcome measure.

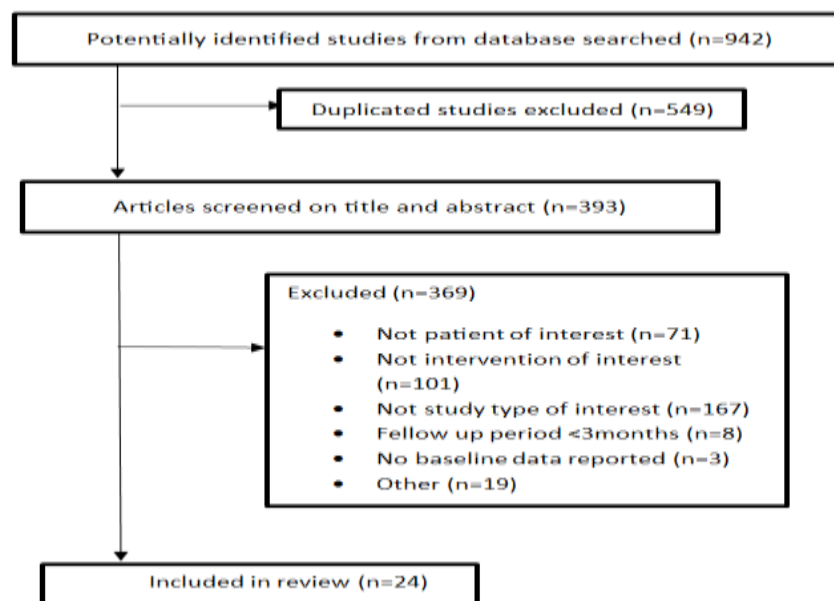


Fig. (1) flow diagram of the search process.

3.3. Complications

Adverse events were reported by all studies but one. [27] The most commonly reported complications after surgery were prolonged postoperative pain and stiffness (Table .4). All cases of shoulder stiffness could be treated with subacromial or intra-articular infiltrations of corticosteroids and/or nonsteroidal anti-inflammatory drugs, with no reported long-lasting disability. No serious adverse events such as infection or hyperesthesia and no secondary operations were reported

3.4. Rehabilitation protocol used includes

- An immediate passive and active exercise. [22,25,26,27]
- Passive training of 3 weeks before adding active exercises. [27]
- Immobilization the shoulder with a sling for 2 weeks in combination with passive motion exercise. [23]
- Immobilization the shoulder with an abduction brace for 3 weeks. [24]

Table (1) Assessments of Outcome Measures (pain, shoulder function, and the resorption/change in size of calcific deposit) for ESWT.

Author (Year)	Baseline	3 mo.	6 mo.	1 yr.	2 yr.	>2 yr.	>5 yr.	Resorption/ Change in Size of calcific deposit
Jan Louwerens et al, 2020 [6]	VAS: 6.0±1.5 CMS:66.4±12.7 DASH: 35.2±15.8	VAS:4.9 CMS: 73.4 DASH: 28.8	VAS: 3.1 CMS:78.8 DASH: 21.6	VAS:2.1 CMS:87.3 DASH: 15.1				Full,68□ Pre 15.8± 4.5mm Post: 1.8 ±3.4 mm
Del Castillo-Gonzalez, 2016 [7]	VAS: 7.43±.99	VAS: 3.25	VAS:2.35	VAS:1.46				Full,86.78% Pre:12.07±4.8mm Post:1.95±2.3mm
Kim et al, 2014 [8]	VAS:6.8 ASES: 41.5 SST: 38.2□	VAS:3.3 ASES: 68.6 SST:59□	VAS:1.8 ASES: 85.2 SST: 74.1□	VAS:1.4 ASES: 90.1 SST: 83.3□	VAS: 1.1 ASES: 91.1 SST: 91.7□			Partial, 11.1%; full,72.2%; none,16.7% Pre:14.8 ± 1.7mm Post: 0.45 ± 0.3mm
De Witte et al, 2013 [16]	CMS: 71.6 ±12.3 DASH: 32.6 ±18.5 WORC: 49.6 ±20.3		CMS: 78.6 ±16.7 DASH: 24.6 ±20.7 WORC: 63.5 ±26.2	CMS:86.0 (80.3-91.6) DASH: 19.6 (9.5-29.8) WORC: 69.7 (57.6-81.8)				Partial, 39%; full, 56%; none, 5% Pre:11.6 ± 6.4mm Post:5.1 ± 5.7mm
Yoo et al, 2010 [17]	CMS: 53.7 ±16.3 ASES: 48.0± 14.5		CMS: 87.9 ± 8.7 ASES: 84.6± 12.8					Pre: 13.6 ± 5 mm Post: 5.6 ± 6.5 mm
Group I	CMS: 55.4 ± 7.4		CMS: 92 ± 16.9					Pre:13.1 ± 4.8mm Post: 12.7 ± 7.1mm
Group II	ASES: 48.6 ± 9.4		ASES: 47.5 ±17.5 CMS:81.4					
De Conti et al, 2010 [18]	CMS:28.6		CMS:71.1					
Group I	CMS:34.1							
Group II								
Serafini et al, 2009 [19]	VAS: 9.3 ± 0.4 CMS: 57.3 ± 3.4	VAS: 3.3 ±0.4 CMS: 90.2±2.6		VAS:2.7±0.5 CMS: 91.7 ± 3.1		VAS: 2.6 ± 0.5 CMS: 90.9±3.6	VAS: 2.5 ±0.6 CMS: 91.8± 5.0	
Del Cura et al, 2007 [20]	SPADI: 50.2 (10-90.1)			SPADI: 14.7 (0-62.8)				Partial, 18.8%; full, 78.1%; none, 3.1%

Note; DASH, Disabilities of the Arm, Shoulder and Hand; SPADI, Shoulder Pain and Disability Index; WORC, Western Ontario Rotator Cuff index; Post, postoperative; Pre, preoperative.

Table (3) Assessments of Outcome Measures (pain, shoulder function, and the resorption/change in size of calcific deposit) for arthroscopic surgery.

Author (Year)	Baseline	3mo	6mo	1 yr.	2 yr.	>2 yr.	>5 yr.	Resorption/ Change in Size of calcific deposit
---------------	----------	-----	-----	-------	-------	--------	--------	--

Chul-Hyun Cho et al, 2020 [21]	VAS: 6.7±1.9 ASES: 34.8±13.8 UCLA: 14.8±4.8	VAS: 4.0±2.3 ASES: 58.9±18.4 UCLA: 23.0±5.2	VAS: 2.3±1.7 ASES: 75.8±15.0 UCLA: 27.1±4.4	VAS: 1.1±1.3 ASES: 88.1±10.5 UCLA: 30.8±3.7	VAS: 1.0±1.8 ASES: 92.3±13.0 UCLA: 32.4±5.5	Full, 26□; Partial, 74□ Pre: 17.4 ± 9.6 mm2
Sabeti et al, 2014 [22]	VAS: 7.7±1.75 CMS: 44.9±14.4			VAS: 1.94±2.07 CMS: 90.33±14.7		Partial, 6%; full, 94%
Balke et al, 2012 [23]	ASES: 38.3				ASES: 81.5 CMS: 76.2	
El Shewy, 2011 [24]	CMS: 63.3 ASES: 57.2 UCLA: 52.8				CMS: 97.8 ASES: 95 UCLA: 95	Partial, 26%; full, 74%
Yoo et al, 2010 [25]	CMS: 63.2 ± 20 ASES: 39 ± 17				CMS: 87 ± 15 ASES: 89 ± 13	Full, 83%; partial, 19% Pre: 15±7.1mm post; < 5mm
Seyahi and Demirhan, 2009 [26]	VAS: 6.5 ± 1.36 CMS: 42				VAS: 0.2 ± 0.5 CMS: 100	Partial, 3%; full, 97%
Seil et al, 2006 [27]	CMS: 32.8			CMS: 90.9		Partial, 4%; full, 96% Pre: 2.2 ± 1.1cm ²
Porcellini et al, 2004 [28]	CMS: 55.1±12.3				CMS: 86.4 ± 7.2	Full resorption in 21%, microcalcifications in 71%, deposits <10 mm in size in 8%
Rubenthaler et al, 2003 [29]	VAS: 8.4 CMS: 64.1			VAS: 1.6 CMS: 97.6 Patte: 84.39		Partial, 42%; full, 58%

Table (4) Treatment Side Effects and Post-Treatment Complications.

Treatment Modality	Peri-Treatment Side Effects	Post-Treatment Complications
ESWT	Frequent: pain, erythema, local petechial bleeding, subcutaneous hematomas	None reported
US-guided needling	Frequent: pain, discomfort Rare: vagal reactions, fainting	Rare: frozen shoulder (2.4%), subacromial bursitis (5%)
Arthroscopy	Frequent: pain, RC defects due to extensive debridement requiring intraoperative RC repair	Frequent: postoperative pain Rare: frozen shoulder (3.7%), partial RC tears (3.5%), subacromial bursitis (<1%), secondary surgical RC repair (<1%)

Note; ESWT, extracorporeal shockwave therapy; RC, rotator cuff; US, ultrasound.

4. Discussion

The main goal for treating calcific tendinitis is to reduce pain, improve function, and decrease calcific deposition. The results of treatment with ESWT, US-guided needling, and arthroscopy in patients with calcific tendinitis of the shoulder were evaluated. Good results concerning improvement of shoulder function and resorption of the calcific deposit at final follow-up were achieved by all 3 treatment modalities, with an improvement in the Constant- Murley score ranging between 26.3 and 41.5 points after 1 year.

Ogon et al examined the outcome of conservative treatment that included physical therapy (i.e., Application of cold and heat), manual therapy, electrotherapy, iontophoresis, systemic use of analgesic and NSAIDs, and up to three subacromial injections of corticosteroids. They defined the failure of nonoperative therapy as persistent symptoms for at least 6 months, including 3 months of standardized nonoperative treatments at their institution. The overall failure rate was 27%. They identified bilateral calcific deposits' occurrence, localization near the anterior portion of the acromion, medial (subacromial) extension, and high volume of calcific deposits as negative prognostic factors. Positive prognostic factors were identified as Gartner type III calcific deposits and lack of sonographic sound extinction. [30]

The advantage of high-energy ESWT is that it is widely applicable in out-of hospital settings and is relatively inexpensive. Good clinical results can be achieved, and treatment is administered without any severe side effects or long-term complications. However, in general, patients have to undergo multiple ESWT sessions to achieve these results, which makes this treatment more time-consuming than US-guided needling. [31]

Jan Louwerens et al. [6] found when comparing ESWT with UGN that both treatment techniques show clinically relevant improvements in terms of shoulder function and pain (CMS:24□-19□; DASH: 57□- 51□; VAS:65□- 45□) for UGN and ESWT respectively after 1-year follow-up. UGN was more effective in eradicating the calcific deposit than ESWT (89□ vs 45□ for UGN).

Kim et al. [8] found when comparing ESWT with UGN significant improvement in shoulder pain (VAS) 84□ vs 62□ for UGN, function (ASES 54□ vs 36□ and) for UGN and resorption of calcific deposit 72.2□ vs 42.6□ for UGN after long term follow up 2 years, though both treatments led to improvement relative to initial findings.

Del Castillo-Gonzalez. [7] also found when comparing ESWT with UGN significant improvement in shoulder pain (VAS) 80□ vs 56□ for UGN and resorption of calcific deposit full;86.87□ vs 55.6□ for UGN after medium follow up 1year. though both treatments led to improvement relative to initial findings .

Farin et al. [32] were the first to describe the outcomes of UGN, reporting 73% of excellent results correlated with the reduction in calcifications' size .

Different approaches have been reported in recent studies and all include the use of a fluid (local anesthetic or saline solution) to dissolve calcium deposits; one needle or two needles are used to inject and retrieve the fluid to dissolve calcium deposits. Recent evidence showed that a double-needle approach might be more appropriate to treat harder deposits, while one needle may be more useful in treating fluid calcifications. [33]

It is preferable to use warm saline solution to reduce procedure duration and improve calcium deposit dissolution, particularly in cases of hard calcifications. There is also evidence that the use of warm saline could be also associated with a reduction in postprocedural bursitis incidence. [33]

A recent review by Gatt and Charalambous. [34] showed no difference in outcome when comparing a 1-needle technique versus a 2-needle technique. Two studies reported re-needling rates of 28% and 45%. The most reported side effects were discomfort during treatment and shoulder pain after treatment, which resolved with nonoperative treatment.

Surgical removal of the calcific deposit has been the preferred treatment for chronic calcific rotator cuff tendinopathy for several years. Open and endoscopic techniques are available for this purpose, but arthroscopy is currently favored because it is minimally invasive and provides clinical results equivalent to open techniques. [29]

In this review according to arthroscopy follow up of shoulder pain and function. Sabeti et al. [22] found an improvement in CMS 50□ and VAS 75□ in 20 patients after 1 year. Five trials reported data after 1.5 to 3 years' follow-up, with improvements in CMS 44□. Balke et al. [32] reported a significant improvement in the ASES score 53□ at 6 years' follow-up. At 7 years' follow-up, El Shewy. [24] reported significant improvements in the ASES 40□ and in the University of California, Los Angeles score 44.□

Chul-Hyun Cho et al. [21] reported overall satisfactory radiological and clinical outcomes. However, recovery of shoulder function and pain relief required up to six months. Therefore, it is necessary to inform patients that pain and discomfort around the shoulder may persist up to six months following treatment. Significant improvement in shoulder pain and function (VAS:85□, ASES:62□, ULCA:54□) after long term follow up was reported. Rotator cuff repair and subacromial decompression were poor prognostic factors of clinical outcomes after treatment. Porcellini et al. [28] studying 58 patients followed up for three years, highlighted the importance of removing all the calcific deposit, finding better shoulder function at follow-up in patients in whom complete removal of the calcifications had been achieved .

Maier et al. [35] studied 93 patients with mean follow-up of 37.3 months. They showed that it is not important to remove all the calcific deposit; residual calcification was resorbed within 6-12 months of the surgical treatment and there were no significant

differences in outcomes between patients with and those without complete removal of calcific deposits.

Seyahi and Demirhan. [29] used side-to-side sutures in all cases after removal of the deposit. Yoo et al. [25] and Porcellini et al. [28] used side-to-side sutures or suture anchors depending on the size of the rotator cuff lesion. Three studies reported no additional use of sutures.

The importance of acromioplasty is also debated. Jacobs and Debeer. [36] did not find statistical differences between patients treated only with removal of calcific deposits, and those treated with removal of calcification in association with acromioplasty. Balke et al. [23] studied the acromial index in a group of patients with calcific tendinitis and a group with subacromial impingement and the results were similar in the two groups.

5. Conclusion

Patients can achieve good to excellent clinical outcomes after ESWT, US-guided needling, and arthroscopy for calcific tendinopathy of the shoulder. Side effects and post-treatment complications should be taken into account when a decision is being made for each individual patient. Physicians should consider ESWT and US-guided needling as minimally invasive treatment options when primary conservative treatment fails.

Arthroscopy can safely be used as a very effective but more invasive secondary option, although the extent of deposit removal and the additional benefit of subacromial decompression remain unclear.

References

- [1] F.D.González, J.J.Álvarez, G.R.Fabián, and et al. Treatment of the calcific tendinopathy of the rotator cuff by ultrasound-guided percutaneous needle lavage, Two years prospective study. *Muscles Ligaments Tendons J.* vol.4(4), pp.407–412, 2014 .
- [2] G.Merolla, S.Singh, P.Paladini, and G.Porcellini. Calcific tendinitis of the rotator cuff: state of the art in diagnosis and treatment. *J Orthop Traumatol.* Vol.17(1), pp. 7–14, 2016.
- [3] S.Basu and D.Temperley. Radiological Investigations. Diagnostic Clusters in Shoulder Conditions. pp.37-53, 2017.
- [4] A.Arirachakaran, M.Boonard, S.Yamaphai, and et al. Extracorporeal shock wave therapy, ultrasound-guided percutaneous lavage, corticosteroid injection and combined treatment for the treatment of rotator cuff calcific tendinopathy: a network meta-analysis of RCTs. *European Journal of Orthopaedic Surgery & Traumatology.* Vol 27. (3), pp.381–390, 2017.
- [5] D. Moher, A. Liberati, J. Tetzlaff, and D.G. Altman. Preferred reporting items for systematic reviews and meta-analyses: The PRISMA statement. *BMJ*; 339: b2535, 2009.
- [6] J.K. G. Louwerens, I.N. Siervelt, E.T. Kramer, and et al. Comparing Ultrasound-Guided Needling Combined with a Subacromial Corticosteroid Injection Versus High-Energy Extracorporeal Shockwave Therapy for Calcific Tendinitis of the Rotator Cuff. *Arthroscopy.* Vol.36(7), pp.1823-1833, 2020.
- [7] F.D.González, J.J.Álvarez, G.R.Fabián, and et al. Extracorporeal shockwaves versus ultrasound-guided percutaneous lavage for the treatment of rotator cuff calcific tendinopathy: a randomized controlled trial. *Eur J Phys Rehabil Med.* vol.52, pp.145-51, 2016.
- [8] Y.S.IP, H.J .Lee, Y.V. Kim, and C.G.Kong. Which method is more effective in treatment of calcific tendinitis in the shoulder? Prospective randomized comparison between ultrasound-guided needling and extracorporeal shock wave therapy. *J Shoulder Elbow Surg.* vol.23, pp.1640-6, 2014.
- [9] F. Ioppolo, M. Tattoli, L. D.Sante, and et al. Extracorporeal shock-wave therapy for supraspinatus calcifying tendinitis: a randomized clinical trial comparing two different energy levels. *Phys Ther.* vol.92(11). pp.1376–1385, 2012.
- [10] C.J.Hsu, D.Y.Wang, K.F.Tseng, and et al. Extracorporeal shock wave therapy for calcifying tendinitis of the shoulder. *J Shoulder Elbow Surg.* vol.17(1), pp.55–59,2008.
- [11] J.D.Albert, J. Meadeb, P.Guggenbuhl, and et al. High-energy extracorporeal shock-wave therapy for calcifying tendinitis of the rotator cuff: a randomised trial. *J Bone Joint Surg Br.* vol.89, pp.335-4,2007.
- [12] A.Cacchio, M.Paoloni, A.Barile, and et al. Effectiveness of radial shockwave therapy for calcific tendinitis of the shoulder: single-blind, randomized clinical study. *Phys Ther.*vol.86, pp.672-82,2006.
- [13] J.Pleiner, R.Crevenna, H.Langenberger, and et al. Extracorporeal shockwave treatment is effective in calcific tendonitis of the shoulder. A randomized controlled trial. *Wien Klin Wochenschr.* vol.116, pp.536-541,2004.
- [14] L.Gerdesmeyer, S.Wagenpfeil, M.Haake, and et al. Extracorporeal shock wave therapy for the treatment of chronic calcifying tendonitis of the rotator cuff: A randomized controlled trial. *JAMA.* vol.290, pp.2573-2580,2003.
- [15] W.Daecke, D.Kusnierczak, and M.Loew. Long-term effects of extracorporeal shockwave therapy in chronic calcific tendinitis of the shoulder. *J Shoulder Elbow Surg.* vol.11(5), pp.476–480,2002.
- [16] P.B.de Witte, J.W.Selten, A.Navas, and et al. Calcific tendinitis of the rotator cuff: A randomized controlled trial of ultrasound-guided needling and lavage versus subacromial corticosteroids. *Am J Sports Med.* Vol.41, pp.1665-1673, 2013.
- [17] J.C.Yoo, K.H.Koh, W.H.Park, and et al . The outcome of ultrasound-guided needle decompression and steroid injection in calcific tendinitis. *J Shoulder Elbow Surg.* vol.19, pp.596-600,2010.

- [18] G.D.Conti, U.Marchioro, A.Dorigo, and et al. Percutaneous ultrasound-guided treatment of shoulder tendon calcifications: Clinical and radiological follow-up at 6 months. *J Ultrasound*. vol.13, pp.188-198,2010.
- [19] G.Serafini, L.M.Sconfienza, F.Lacelli, and et al. Rotator cuff calcific tendonitis: short-term and 10-year outcomes after two-needle us-guided percutaneous treatment--nonrandomized controlled trial. *Radiology*. vol.252, pp. 157-164,2009.
- [20] J.L.D.Cura, I.Torre I, R.Zabala, and A.Legorburu. Sonographically guided percutaneous needle lavage in calcific tendinitis of the shoulder: Short- and long-term results. *AJR Am J Roentgenol*. vol.189, pp.128-134,2007.
- [21] C.H.Cho, K.C.Bae, B.S.Kim, and et al. Recovery pattern after arthroscopic treatment for calcific tendinitis of the shoulder. *Orthopaedic & Traumatology: Surgery & Research*. vol.106(4), pp. 687–691, 2020.
- [22] M.Sabeti, M.Schmidt, P.Ziai, and et al. The intraoperative use of ultrasound facilitates significantly the arthroscopic debridement of calcific rotator cuff tendinitis. *Arch Orthop Trauma Surg*. vol.134, pp.651-656,2014.
- [23] M.Balke, R.Bielefeld, C.Schmidt, and et al. Calcifying tendinitis of the shoulder: Midterm results after arthroscopic treatment. *Am J Sports Med*. vol.40, pp.657-661,2012.
- [24] M.T.El Shewy. Arthroscopic removal of calcium deposits of the rotator cuff: A 7-year follow-up. *Am J Sports Med*. vol.39, pp.1302-1305,2011.
- [25] J.C.Yoo, W.H.Park, K.H.Koh, and S.M.Kim. Arthroscopic treatment of chronic calcific tendinitis with complete removal and rotator cuff tendon repair. *Knee Surg Sports Traumatol Arthrosc*. vol.18, pp.1694-1699, 2010.
- [26] A.Seyahi, and M.Demirhan. Arthroscopic removal of intraosseous and intratendinous deposits in calcifying tendinitis of the rotator cuff. *Arthroscopy*. vol.25, pp.590-596,2009.
- [27] R.Seil, H.Litzenburger, D.Kohn, and S.Rupp. Arthroscopic treatment of chronically painful calcifying tendinitis of the supraspinatus tendon. *Arthroscopy*. vol.22(5), pp.521–527,2006.
- [28] G.Porcellini, P.Paladini, F.Campi, and M.Paganelli. Arthroscopic treatment of calcifying tendinitis of the shoulder: clinical and ultrasonographic follow- up findings at two to five years. *J Shoulder Elbow Surg*. vol.13(5), pp. 503–508,2004.
- [29] F.Rubenthaler, J.Ludwig, M.Wiese, and R.H.Wittenberg. Prospective randomized surgical treatments for calcifying tendinopathy. *Clin Orthop*. vol. 410, pp.278–284,2003.
- [30] P.Ogon, N.P.Suedkamp, M.Jaeger, and et al. Prognostic factors in nonoperative therapy for chronic symptomatic calcific tendinitis of the shoulder. *Arthritis Rheum*. vol.60(10), pp.2978–2984,2009.
- [31] J.K. G. Louwerens, E. S. Veltman, A.V. Noort, and et al. The Effectiveness of High-Energy Extracorporeal Shockwave Therapy Versus Ultrasound-Guided Needling Versus Arthroscopic Surgery in the Management of Chronic Calcific Rotator Cuff Tendinopathy: A Systematic Review: Arthroscopy: The Journal of Arthroscopic & Related Surgery. vol. 32, 1, P. 165-175,2016.
- [32] P.U.Farin, H.Räsänen, H.Jaroma, A.Harju. Rotator cuff calcifications: treatment with ultrasound-guided percutaneous needle aspiration and lavage. *Skeletal Radiol*. vol.25(6), pp.551–554,1996.
- [33] D.Orlandi, G.Mauri, F.Lacelli, and et al. Rotator Cuff Calcific Tendinopathy: Randomized Comparison of US-guided Percutaneous Treatments by Using One or Two Needles. *Radiology*. vol.285, pp.518-527,2017.
- [34] D.L.Gatt, and C.P.Charalambous. Ultrasound-guided barbotage for calcific tendonitis of the shoulder: A systematic review including 908 patients. *Arthroscopy*. vol.30, pp.1166-1172,2014.
- [35] D.Maier, M. Jaeger, K.Izadpanah, and et al. Rotator cuff preservation in arthroscopic treatment of calcific tendinitis. *Arthroscopy*. vol.29, pp.824-831,2013.
- [36] R.Jacobs, and P.Debeer. Calcifying tendinitis of the rotator cuff: functional outcome after arthroscopic treatment. *Acta Orthop Belg*. vol.72, pp.276-281,2006.