

## **UNUSUAL PATHWAY OF SHARP FOREIGN BODY IN A COW FIRST RECORDED ADDED TO SEQUELLAE OF TRUMATIC PERFORATION**

With

### **Clinical Pictures (Case report)**

El-Sebaie, A. and Ali, M.A.

Dept. of Animal Medicine and Veterinary Surgery, Faculty of Veterinary Medicine, Assiut University

#### **Case History:**

A native breed cow admitted to the clinic during the activities of veterinary surface conveys. Case history taken from the owner indicated that the cow suddenly stop to take the ration unable to intake the ration or drink water and marked restlessness. Since 3-days, further more drop in milk production.

#### **Clinical Examination:**

Clinical examination revealed marked swelling on the right at the region of upper part of cervical oesophagus further findings revealed, that there was marked decrease in rate and quality of ruminal motility with the presence of cape of gases. Palpation of the swelling revealed sever pain and restlessness, examination of the oral cavity indicated pain and the cow unable to tolerate the manipulation of oral cavity, on site, it was very difficult to reach a final diagnosis and recommended the owner to transmit the cow to the veterinary clinic for further clinical examination. The second step was directed for further investigations, including careful examination of the oral cavity and visualized it carefully, which indicated the presence end of pice of metal wire (Fig.2). Further step of investigation revealed that this part of wire penetratrated deeply the upper of oesophagus. Manipulation of this pice of wire accompanied by severe pain and restlessness. Trials have been made to with dwal this pice of wire by hand, the pice of wire was about 10 cm of length (Fig.3). Extraction of these pice of wire was fallowed by immediate relief and drink water and start to prehense ration.

#### **Differential diagnosis:**

This ease was confused clinically with inflammation of mouth cavity and or pharyngitis.

#### **Conclusion:**

It is will known that the swallowing of shap foreign bodies pass to directly to Reticulum and rumen and then takes the its usual pathway to its know liliated syndrome (Traumatic Reticulate) or Pericarditis or adjacent organs. But and on the other hand, there no previous evidence that the shap foreign bodies-get penetrate the oral cavity. Based in the clinical findings in this case report was considered as first case report and should be added as an unusual pathway of penetrating foreign body listed by blood and herderson (1968).

#### **Conclusion**

It is well known, that swallowing a sharp foreign bodies in bovine pass directly to the reticulum and rumen and then takes its pathway to toward the known allied syndrome traumatic reticulo peritonitis and extend its pathway to the heart causing traumatic pericarditis or other adjacent organs, according to the illustration presented by (Blood and Henderson 1968). Therefore the present case report should added to illustration of (Blood and Henderson) as new pathway for sharp foreign bodies.

#### **Reference:**

*Blood, D.C. and Henderson, J.A. (1968):  
Veterinary Medicine 3<sup>rd</sup> Ed.*

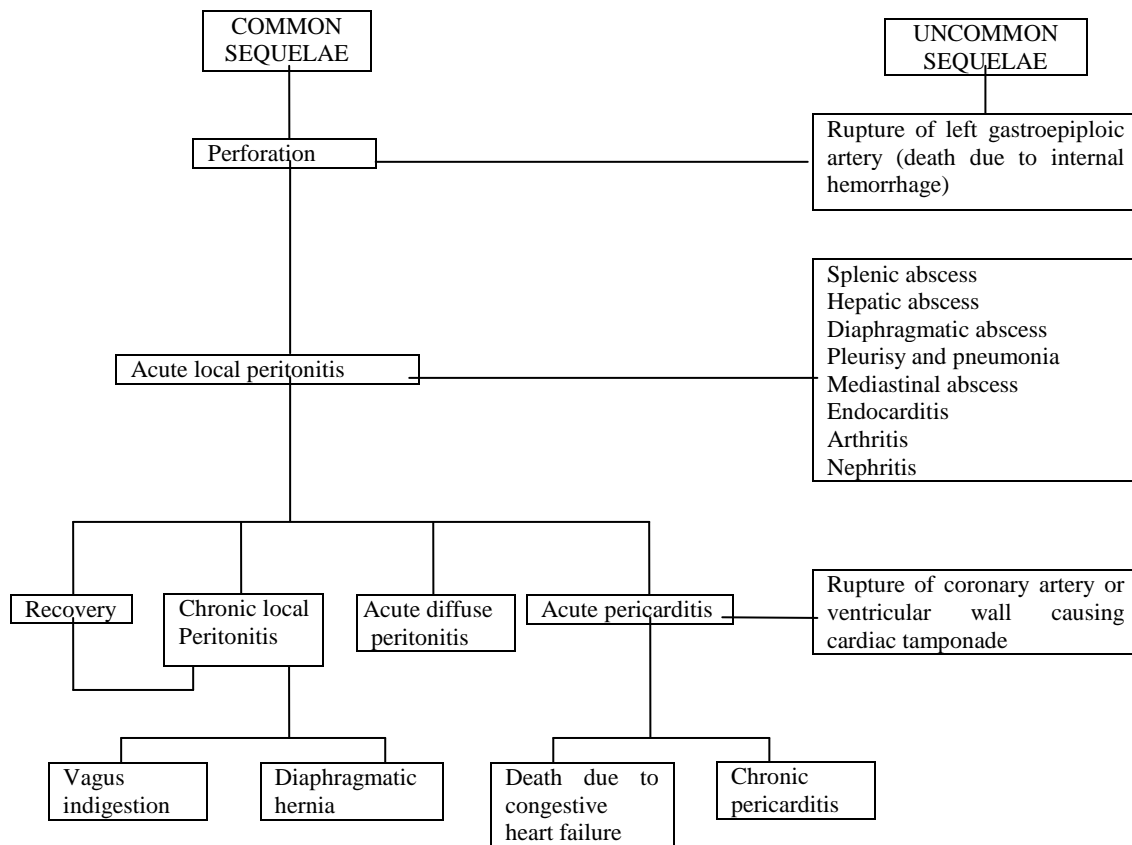


Fig. 1: Sequelae of traumatic perforation of the reticular wall

