

The in vivo ameliorative effect of silymarin on cisplatin-associated ovarian and testicular histopathological and biochemical alterations



Sohaila Abd El- Hameed, Hebatallah A. Mahgoub[†], Walaa F. Awadin, Ahmed F. El- Shaieb

Pathology department, Faculty of Veterinary Medicine, Mansoura University, Egypt.

ARTICLE HISTORY

Received: 06.01.2021

Revised: 17.05.2021

Accepted: 17.05.2021

Address correspondence to **Hebatallah A. Mahgoub**; Tel. +201112316644, E-mail: hebamahgoub@mans.edu.eg

ABSTRACT

Objective: To investigate the protective effect of silymarin against *in vivo* cisplatin-induced ovarian, testicular and epididymal histopathological alterations in female and male albino rats, respectively.

Design: Randomized controlled study.

Animals: Eighty adult male and female albino rats (160 ± 20 g in body weight and 4-6 weeks in age).

Procedures: animals were randomly allocated to four treatments groups. Animals were treated with either mock treatment, cisplatin, silymarin or cisplatin and silymarin simultaneously for 20 successive days. Blood and tissue samples (ovary, testis and epididymis) were collected. Animal sera were tested for sex hormones and ovary, testis and epididymis were examined histopathologically.

Results: Our study demonstrated the ability of silymarin to ameliorate the cisplatin-associated tissue damage in all studied organs. Silymarin treatment also had a minor effect on resorting the serum level of estrogen in cisplatin-treated female rats.

Conclusion and clinical relevance: Silymarin may be an alternative nutritional supplement to counteract the side effects of cisplatin during anti-cancer chemotherapy.

Keywords: Silymarin; cisplatin; ovarian toxicity; testicular toxicity; chemotherapy

1. INTRODUCTION

Cisplatin (cis-diamminedichloroplatinum II, CDDP), is a commonly used chemotherapeutic drug [1]. It is regarded as one of the most potent, effective, and powerful anti-neoplastic drugs used in the treatment of many cancers, e.g. the solid tumors of testis, head, neck, urinary bladder, and uterine cervix. In addition, it is effective in the treatment of lymphomas, sarcomas, and germ cell tumors, but its usage caused numerous side effects, e.g. hepatotoxicity, nephrotoxicity, and ototoxicity [2-4]. Furthermore, CDDP induced biochemical and histological alterations in female and male gonads [5, 6]. It was reported that CDDP treatments caused ovarian injury, increase in follicular apoptosis, disturbance of estrous cycle and reduction in the number of ovarian follicles in both human and animals [7]. CDDP treatments also caused a significant decrease in the daily sperm production, associated with a decrease in the sperm head length and reduction in the DNA percentage of the head [8]. Similarly, it caused diminished testicular tubular diameter, reduction of the epithelial cell height and decrease in the number of spermatogonia [9]. Alteration in Leydig cell

function and chromosomal abnormalities in the sperm with temporary or permanent azoospermia were also associated with CDDP treatment [10]. Such CDDP-induced alterations were attributed to redox imbalance and lipid peroxidation of the ovarian and testicular tissues [10, 11].

Silymarin is an ancient herbal cure, a mixture of flavonoids extracted from *Silybum marianum Gaertneri*, also known as (milk thistle) [12]. It has antibacterial, anti-inflammatory, antiviral, and antineoplastic pharmacological activities, and it is reported to scavenge free radicals, chelate metal ions and inhibit lipid peroxidation [13]. Silymarin exerts its antioxidant activity through preventing the formation of free radicals, where it suppresses reactive oxygen species producing enzymes, and chelating iron and copper in the intestine [14]. It is also related with superoxide dismutase activation [15].

This study aimed towards investigating the protective effect of silymarin against CDDP-associated ovarian and testicular damage in male and female albino rats through serum biochemical analyses of sex hormones and

histopathological examinations of ovarian and testicular tissues.

2. MATERIALS AND METHODS

2.1. Animals

This experiment was conducted on 80 adult albino rats of both sexes (160 ± 20 g in body weight and 4-6 weeks in age). The animals were housed in plastic cages (10 rats per cage) and supplied *ad libitum* with standard pellet rat diet and water. Animals were maintained under standard hygienic conditions of temperature, humidity and light with 12 h light/dark cycle, in the laboratory of Pathology Department, Faculty of Veterinary Medicine, Mansoura University. Following animals arrival, animals were acclimatized to the new environment for one week before the start of the experiment, where they were monitored for clinical signs until the end of the experiments. The experiments were conducted following the 'Guide for the Care and Use of Laboratory Animals' approved by the Ethics Committee of the Faculty of Veterinary Medicine, Mansoura University.

2.2. Chemicals

CDDP (Cisplatin) was purchased from Mylan Company (United States) in the form of injectable aqueous solution vial (50 mL). Each 50 mL of the vial contains 50 mg of CDDP, dissolved in 0.9 % NaCl. Silymarin (legalon) was purchased from Meda Company (Sweden) in the form of capsules (140 mg).

2.3. Design

Animals were randomly allocated to four treatments groups. The first group represented the negative control group, where animals received a daily intraperitoneal injection of sterile physiological saline (0.9% NaCl, 1 mL per kilogram of body weight) and a daily oral dose of distilled water at (100 mL per kilogram of body weight) for 20 successive days. The second group represented the positive control group, cisplatin-treated group, where animals received a daily intraperitoneal injection of cisplatin (1mg per kilogram of body weight) for 20 successive days [17]. The third

group represented the experimental control group, silymarin-treated group, where animals received a daily oral dose of silymarin (100 mg per kilogram of body weight) for 20 successive days [18]. The fourth group represented the experimental group, silymarin-treated group, where animals received a daily oral dose of silymarin (100 mg per kilogram of body weight) together with intraperitoneal injection of cisplatin (1 mg per kilogram of body weight) for 20 successive days.

2.4. Collection

At the end of the experiment, light ether anesthesia was administered. Blood samples were collected from the orbital sinus of the eye, and the blood was kept at 4°C to separate for 24 h. Blood samples were then centrifuged for 10 minutes at 4000 revolution per minute, and the supernatant was collected. Serum samples were stored at -20°C until assessment of sex hormones. Ovarian and testicular tissues were collected from all experimental groups and preserved in 10% formaldehyde for histopathological examination.

2.5. Processing and examination

Samples were processed for hematoxylin and eosin (H&E) staining [19]. Tissue sections (three microns in thickness each) were examined, using 4x, 10x, and 40x magnification lenses (XSZ-107BN biological microscope, China).

2.6. Serum sex hormones

The levels of serum testosterone and estrogen levels were estimated using kits purchased from Siemens Health care diagnostic products (United Kingdom), and the manufacturer's instructions were followed.

2.7. Statistical analysis

Statistical analysis of the biochemical data was executed using Prism 9 for macOS (GraphPad Software, LLC), where one-way analysis of variance (ANOVA) was used, followed by Turkey's post hoc test for group comparison, with a *P* value of ≤ 0.05 indicating statistical significance [20].

3. RESULTS

3.1 Hormonal analysis

The female rats treated with silymarin showed a significant increase in the serum levels of estrogen, when compared with the negative control group (Figure 1). In contrast, CDDP-treated group showed a significant reduction in serum estrogen levels, when compared with the negative control group. Meanwhile, CDDP and silymarin concurrent application showed a mild restoration of serum estrogen, when compared with the CDDP-treated group. However, it was still significantly lower than the negative control.

The male rats treated with silymarin showed a significant increase in the serum levels of testosterone, when compared with the negative control group (Figure 2). On the other hand, CDDP treatment, either alone or with the application of silymarin, caused a significant decrease in serum testosterone levels, when compared with the negative control group.

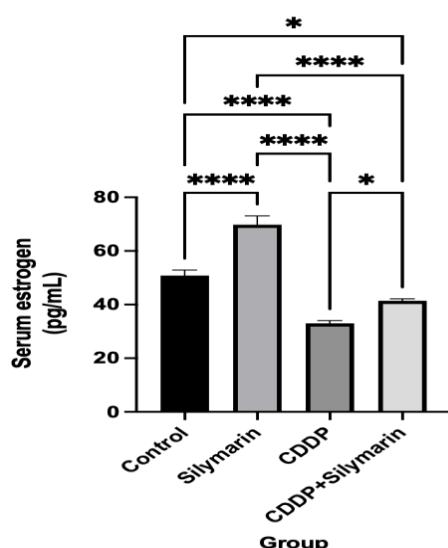


Figure 1. Effect of oral silymarin on serum estrogen level (mean \pm standard error of the mean (SE)) in female rats treated with intraperitoneal cisplatin (CDDP) for 20 days. Asterisks represent significant variation between treatment groups, where *: P value ≤ 0.05 ; ****: P value ≤ 0.0001 .

1.2. Histopathological examination

3.2.1 ovary

Microscopical examination of the ovarian sections from the female negative control rats showed normal ovarian morphology with regular cuboidal epithelium on the surface with the presence of primordial, primary, secondary, and tertiary follicles in the cortex, and capillary vessels in the

medulla (Figure 3: A-I). Only CDDP-treated groups showed altered ovarian histology, where a marked reduction in the follicular numbers was observed, together with absence of mature follicles and marked vascular dilation. No other group showed any recorded alteration in the ovarian histological picture. Overall, CDDP and silymarin concurrent treatment improved the microscopical picture of the ovary.

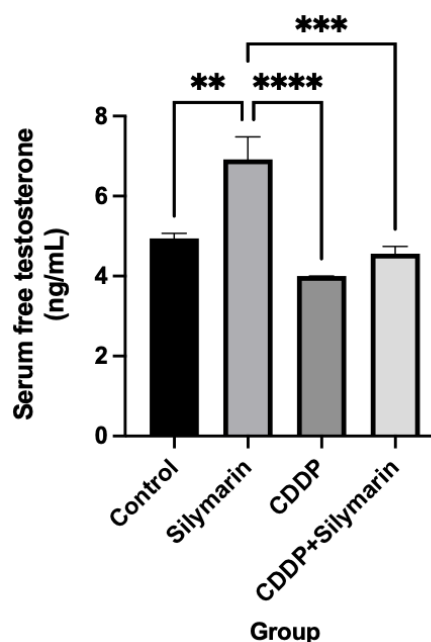


Figure 2. Effect of oral silymarin on serum testosterone level (mean \pm SE) in male rats treated with intraperitoneal cisplatin (CDDP) for 20 days. Asterisks represent significant variation between treatment groups, where **: P value ≤ 0.01 ; ***: P value ≤ 0.001 ; ****: P value ≤ 0.0001 .

3.2.2. Testis

Microscopical examinations of the testicular sections the male negative control rats showed normal seminiferous tubules, where their lumen was filled with spermatids and spermatozoa and lined by spermatogonia, several layers of spermatocytes and Sertoli cells (Figure 4: A-E). An interstitial space was seen between the tubules, where it contained cells of Leydig. CDDP treatment caused enlargement of the interstitial space, massive degeneration and vacuolation of the germinal epithelial lining of the seminiferous tubules and reduction in the numbers of germ cells. No other group showed any recorded alteration in the testicular histological picture, except mild vacuolations that were observed in the

germinal epithelium of CDDP and silymarin treated rats. In general, CDDP and silymarin simultaneous treatment improved the microscopical picture of the testis.

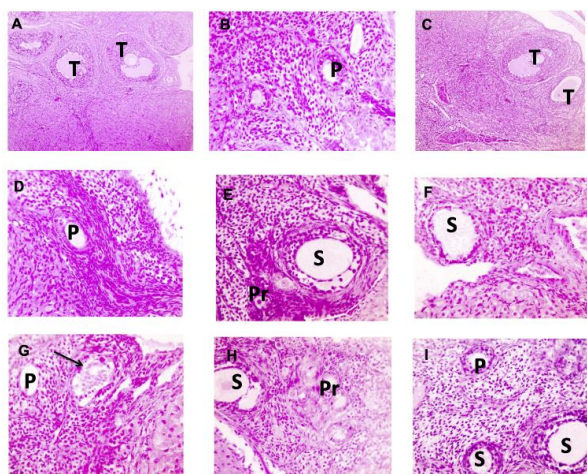


Figure 3. Microscopical examination of the ovarian tissues collected from female rats treated with CDDP and Silymarin. A-B and C-E represent the control group and silymarin-treated group, respectively, showing normal ovarian morphology with regular cuboidal epithelium on the surface, together with the presence of primordial, primary, secondary and tertiary follicles in the cortex and capillary vessels in the medulla. F-G) The micrographs represent CDDP-treated female rats showing marked reduction of follicular numbers and absence of mature follicles, together with marked vascular dilation (arrow). H-I) The micrographs represent CDDP and silymarin-treated female rats showing normal ovarian structure. Magnification = 100 (A; C) and 400 (B; D-I). Pr: Primordial follicle, P: Primary follicle, S: Secondary follicle, T: Tertiary follicle.

3.2.3 Epididymis

Microscopical examination of epididymis tissue sections from normal (negative control) male rats showed normal epididymal ducts lined by low cuboidal epithelium and their lumina were with filled sperms (**Figure 5: A-D**). CDDP treatment caused a marked reduction in sperm numbers. No other group showed any recorded alteration in the epididymis histological picture. Overall, CDDP and silymarin coincident treatment enhanced the microscopical picture of the epididymis.

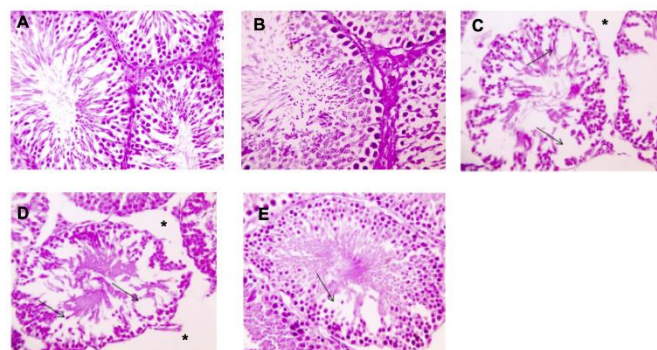


Figure 4. Microscopical examination of the testicular tissues collected from male rats treated with CDDP and silymarin. A and B represent the control group and silymarin-treated group, respectively. Normal seminiferous tubules are seen, where the lumina are filled with spermatids and spermatozoa and lined by spermatogonia, several layers of spermatocytes and Sertoli cells, together with the presence of an interstitial space between the tubules containing cells of Leydig in the negative control and silymarin groups, respectively. C-D) The micrographs represent CDDP-treated male rats showing wide interstitial space (asterisk), fewer numbers of germ cells and massive degeneration and vacuolation in the germinal epithelium (arrows). E) The micrograph represents CDDP and silymarin-treated male rats showing restoration of normal testicular histology and mild vacuolation in germinal epithelium (arrow). Magnification = 400.

4. DISCUSSION

CDDP is a potent chemotherapeutic drug with multiple adverse side effects [9, 11, 21, 22]. Silymarin is a widely known antioxidant that can be used as a dietary supplement [23]. Owing to its anti-bacterial, anti-inflammatory, antiviral, and antineoplastic activities, it is the drug of choice in the treatment of liver disorders [13]. Due to its antioxidant properties [24], it was used in different experimental models and was safe for administration in human studies [16].

Several animal and human studies showed the side effects of CDDP, including the ovarian damage [25, 26]. CDDP induced apoptosis in the granulosa cells and damage of the primordial follicles [11]. Our study showed that CDDP caused significant reduction in the serum estrogen levels and severe deterioration of the ovarian histology. Previous reports showed similar deteriorating effect [27-29]. Our study also

showed a significant increase in the levels of serum estrogen hormone and an enhancement of ovarian histology following simultaneous application of silymarin. In previous reports, silymarin showed an anti-inflammatory effect against ovarian inflammations [30]. Silymarin also reduced the apoptosis of granulosa cells [31]. However, this is the first report of the tissue-damage protective effect of silymarin against CDDP-associated ovarian damage.

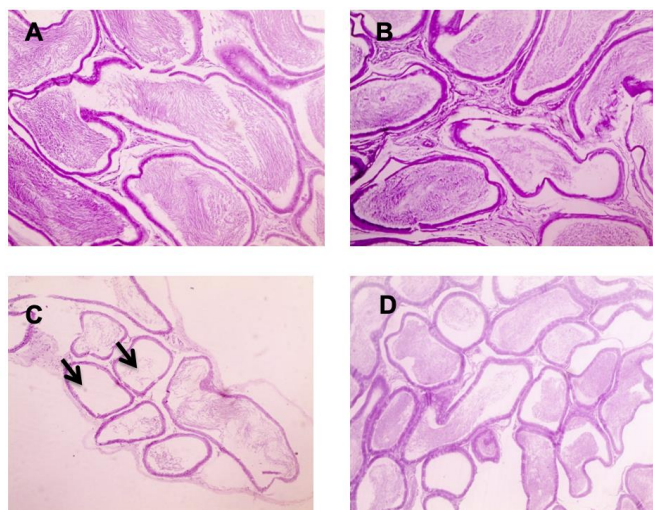


Figure 5. Microscopical examination of the epididymal tissues collected from male rats treated with CDDP and silymarin. A and B represent the control group and silymarin-treated group, respectively. Epididymal ducts are lined by low cuboidal epithelium and the lumina contain sperms in the negative control and silymarin groups, respectively. C) The micrograph represents CDDP-treated male rats showing marked reduction in the numbers of sperms in the epididymal lumina (arrows). D) The micrograph represents CDDP and silymarin-treated male rats showing normal epididymal histology. Magnification = 100.

In previous literature, CDDP induced testicular damage, sperm dysfunction, apoptosis of germ cells, and Leydig cell abnormalities [10] that were attributed to redox imbalance and lipid peroxidation [32]. The present study elucidated a marked reduction testosterone hormone serum levels and a marked testicular and epididymis damage following CDDP application that was reversed following the simultaneous application of silymarin. Silymarin, in previous reports, showed a protective, antioxidant effect against testicular oxidative damage [33]. Overall, our study elucidated the role

of silymarin in protection against CDDP-associated ovarian, testicular and epididymal tissue damage.

3. Conclusion

In this work, the simultaneous use of silymarin and cisplatin in our mammalian model showed enhanced tissue pathology in the ovary, testis and the epididymis of male rats. Therefore, our study recommends the usage of silymarin as nutritional supplement to counteract the side effects of cisplatin during anti-cancer chemotherapy.

Acknowledgment

The authors wish to thank Dr Azza Abd El-baky El-baiomy, Professor of Clinical Pathology, Faculty of Medicine, Mansoura University, for her help in the biochemical analysis.

Conflict of interest statement

The authors declare no conflict of interest.

Research Ethics Committee Permission

The current research work is permitted to be executed according to standards of Research Ethics committee, Faculty of Veterinary Medicine, Mansoura University.

Authors' contribution

The study is part of a Master thesis presented to the Department of Pathology, Faculty of Veterinary Medicine, Mansoura University by SA, where HAM, WFA and AFE acted as thesis supervisors.

5. REFERENCES

- [1] Dasari S, Tchounwou PB. Cisplatin in cancer therapy: molecular mechanisms of action. *European journal of pharmacology*. 2014;740:364-78. <https://doi.org/10.1016/j.ejphar.2014.07.025>
- [2] Al-Malki AL, Sayed AAR. Thymoquinone attenuates cisplatin-induced hepatotoxicity via nuclear factor kappa- β . *BMC complementary and alternative medicine*. 2014;14:1-8. <https://doi.org/10.1186/1472-6882-14-282>
- [3] Rathinam R, Ghosh S, Neumann WL, Jamesdaniel S. Cisplatin-induced apoptosis in auditory, renal, and neuronal cells is associated with nitration and downregulation of LMO4. *Cell death discovery*. 2015;1:1-8. <https://doi.org/10.1038/cddiscovery.2015.52>
- [4] Talach T, Rottenberg J, Gál B, Kostrica R, Jurajda M, Kocak I, et al. Genetic

- risk factors of cisplatin induced ototoxicity in adult patients. *Neoplasma*. 2016;63:263-8. https://doi.org/10.4149/212_140820N391
- [5] Lee SJ, Schover LR, Partridge AH, Patrizio P, Wallace WH, Hagerty K, et al. American Society of Clinical Oncology recommendations on fertility preservation in cancer patients. *Journal of clinical oncology*. 2006;24:2917-31. <https://doi.org/10.1200/JCO.2006.06.5888>
- [6] Ilbey YO, Ozbek E, Cekmen M, Simsek A, Otuntemur A, Somay A. Protective effect of curcumin in cisplatin-induced oxidative injury in rat testis: mitogen-activated protein kinase and nuclear factor-kappa B signaling pathways. *Human reproduction*. 2009;24:1717-25. <https://doi.org/10.1093/humrep/dep058>
- [7] Boulikas T, Vougiouka M. Recent clinical trials using cisplatin, carboplatin and their combination chemotherapy drugs. *Oncology reports*. 2004;11:559-95. <https://doi.org/10.3892/or.11.3.559>
- [8] Cherry SM, Hunt PA, Hassold TJ. Cisplatin disrupts mammalian spermatogenesis, but does not affect recombination or chromosome segregation. *Mutation Research/Genetic Toxicology and Environmental Mutagenesis*. 2004;564:115-28. <https://doi.org/10.1016/j.mrgentox.2004.08.010>
- [9] Jahan S, Munawar A, Razak S, Anam S, Ain QU, Ullah H, et al. Ameliorative effects of rutin against cisplatin-induced reproductive toxicity in male rats. *BMC urology*. 2018;18:107. <https://doi.org/10.1186/s12894-018-0421-9>
- [10] Afsar T, Razak S, Almajwal A. Acacia hydasypica ethyl acetate extract protects against cisplatin-induced DNA damage, oxidative stress and testicular injuries in adult male rats. *BMC cancer*. 2017;17:883. <https://doi.org/10.1186/s12885-017-3898-9>
- [11] Erbaş O, Akman L, Yavaşoğlu A, Terek MC, Akman T, Taskiran D. Oxytocin improves follicular reserve in a cisplatin-induced gonadotoxicity model in rats. *BioMed Research International*. 2014;2014. <https://doi.org/10.1155/2014/703691>
- [12] Ferenci P. Silymarin in the treatment of liver diseases: what is the clinical evidence? *Clinical Liver Disease*. 2016;7:8. <https://doi.org/10.1002/cld.522>
- [13] Di Costanzo A, Angelico R. Formulation strategies for enhancing the bioavailability of silymarin: The state of the art. *Molecules*. 2019;24:2155. <https://doi.org/10.3390/molecules24112155>
- [14] Surai PF. Silymarin as a natural antioxidant: an overview of the current evidence and perspectives. *Antioxidants*. 2015;4:204-47. <https://doi.org/10.3390/antiox4010204>
- [15] Milosevic N, Milanovic M, Abenavoli L, Milic N. Phytotherapy and NAFLD—from goals and challenges to clinical practice. *Reviews on recent clinical trials*. 2014;9:195-203. <https://doi.org/10.2174/1574887109666141216110337>
- [16] Hogan F, Krishnegowda N, Mikhailova M, Kahlenberg M. 46: Flavonoid, silibinin, inhibits proliferation and promotes cell-cycle arrest of human colon cancer cell lines: Fet, Geo, HCT116. *Journal of Surgical Research*. 2007;137:169-70. <https://doi.org/10.1016/j.jss.2006.12.055>
- [17] El-Sayyad HI, Ismail MF, Shalaby F, Abou-El-Magd R, Gaur RL, Fernando A, et al. Histopathological effects of cisplatin, doxorubicin and 5-fluorouracil (5-FU) on the liver of male albino rats. *International journal of biological sciences*. 2009;5:466. <https://doi.org/10.7150/ijbs.5.466>
- [18] Salem S, AA AE-B, Mohammed F. Cytoprotective effect of silymarin on cisplatin induced hepatotoxicity and bone marrow toxicity in rats. *Asian J Anim Sci*. 2017;11:140-52. <https://doi.org/10.3923/ajas.2017.140.152>
- [19] Bancroft JD, Gamble M. *Theory and practice of histological techniques: Elsevier health sciences*; 2008.
- [20] Toothaker LE, Newman D. Nonparametric competitors to the two-way ANOVA. *Journal of Educational Statistics*. 1994;19:237-73. <https://doi.org/10.3102/10769986019003237>
- [21] Wang Y, Lv J, Ma X, Wang D, Ma H, Chang Y, et al. Specific hemosiderin deposition in spleen induced by a low dose of cisplatin: altered iron metabolism and its implication as an acute hemosiderin formation model. *Current drug metabolism*. 2010;11:507-15. <https://doi.org/10.2174/138920010791636149>
- [22] Pezeshki Z, Khosravi A, Nekuei M, Khoshnood S, Zandi E, Eslamian M, et al. Time course of cisplatin-induced nephrotoxicity and hepatotoxicity. *Journal of nephropathology*. 2017;6:163. <https://doi.org/10.15171/jnp.2017.28>
- [23] Hellerbrand C, Schattenberg JM, Peterburs P, Lechner A, Brignoli R. The potential of silymarin for the treatment of hepatic disorders. *Clinical Phytoscience*. 2017;2:7. <https://doi.org/10.1186/s40816-016-0019-2>
- [24] Federico A, Dallio M, Di Fabio G, Zarrelli A, Zappavigna S, Stiuso P, et al. Silybin–phosphatidylcholine complex protects human gastric and liver cells from oxidative stress. *in vivo*. 2015;29:569-75.
- [25] Meirou D. Reproduction post-chemotherapy in young cancer patients. *Molecular and cellular endocrinology*. 2000;169:123-31. [https://doi.org/10.1016/S0303-7207\(00\)00365-8](https://doi.org/10.1016/S0303-7207(00)00365-8)
- [26] Perez GI, Maravei DV, Trbovich AM, Cidlowski JA, Tilly JL, Hughes Jr FM.

Identification of potassium-dependent and-independent components of the apoptotic machinery in mouse ovarian germ cells and granulosa cells. *Biology of reproduction*. 2000;63:1358-69.

<https://doi.org/10.1095/biolreprod63.5.1358>

[27] Yucebilgin MS, Terek MC, Ozsaran A, Akercan F, Zekioglu O, Isik E, et al. Effect of chemotherapy on primordial follicular reserve of rat: an animal model of premature ovarian failure and infertility. *Australian and New Zealand Journal of Obstetrics and Gynaecology*. 2004;44:6-9.

<https://doi.org/10.1111/j.1479-828X.2004.00143.x>

[28] Yeh J, Kim B, Liang YJ, Peresie J. Müllerian inhibiting substance as a novel biomarker of cisplatin-induced ovarian damage. *Biochemical and biophysical research communications*. 2006;348:337-44.

<https://doi.org/10.1016/j.bbrc.2006.06.195>

[29] Ozcelik B, Turkyilmaz C, Ozgun MT, Serin IS, Batukan C, Ozdamar S, et al. Prevention of paclitaxel and cisplatin induced ovarian damage in rats by a gonadotropin-releasing hormone agonist. *Fertility and sterility*. 2010;93:1609-14.

<https://doi.org/10.1016/j.fertnstert.2009.02.054>

[30] Kayedpoor P, Mohamadi S, Karimzadeh-Bardei L, Nabiuni M. Anti-inflammatory Effect of Silymarin on Ovarian Immunohistochemical Localization of TNF- α Associated with Systemic Inflammation in Polycystic Ovarian Syndrome. *International Journal of Morphology*. 2017;35.

[31] Moosavifar N, Mohammadpour A, Jallali M, Karimi G, Saberi H. Evaluation of effect of silymarin on granulosa cell apoptosis and follicular development in patients undergoing in vitro fertilization. *EMHJ-Eastern Mediterranean Health Journal*, 16 (6), 642-645, 2010.

<https://doi.org/10.26719/2010.16.6.642>

[32] Moretti E, Mazzi L, Terzuoli G, Bonechi C, Iacoponi F, Martini S, et al. Effect of quercetin, rutin, naringenin and epicatechin on lipid peroxidation induced in human sperm. *Reproductive Toxicology*. 2012;34:651-7.

<https://doi.org/10.1016/j.reprotox.2012.10.002>

[33] Moshtaghion S-M, Malekinejad H, Razi M, Shafie-Irannejad V. Silymarin protects from varicocele-induced damages in testis and improves sperm quality: evidence for E2f1 involvement. *Systems biology in reproductive medicine*. 2013;59:270-80.

<https://doi.org/10.3109/19396368.2013.794253>