



Manuscript ID ZUMJ-2104-2199 (R1)

DOI 10.21608/zumj.2021.72982.2199

ORIGINAL ARTICLE

Lateral Mass Screw Fixation in Sub-Axial Cervical Spine Combined with Decompression Laminectomy in Multi-Level Cervical Spondylotic Myelopathy Safety and Clinical Outcome

Ashraf El-Desouky*, Ahmed A. Arab, Mohammed Hammad Eltantawy, Moataz A. Elawady
Neurosurgery Department, Faculty of Medicine, Benha University, Benha city, Egypt.

Corresponding author:

Ashraf El-Desouky,
Neurosurgery Department,
Faculty of Medicine, Benha
University, Benha city, Egypt.

Email:

ashrafeldesouky73@gmail.com

Submit Date 2021-04-18

Revise Date 2021-05-14

Accept Date 2021-05-19

ABSTRACT

Background: Since Roy-Camille introduced lateral mass fixation in 1979, it has been widely used to fixate cervical spine after posterior decompression. this study is to evaluate safety and clinical outcome, using lateral mass screw fixation in sub-axial cervical spine combined with laminectomy in patients with multi-level cervical spondylotic myelopathy (CSM).

Methods: A prospective clinical study, selected patients operated on for multi-level CSM from C3-C7 using laminectomy and lateral mass screw fixation (LMS) with 6 months follow up. The patients had preoperative cervical spine A-P, lateral, flexion and extension radiographs, CT scan and MRI and postoperative radiographs as preoperative views obtained at 1, 3 and 6 months after surgery. Myelopathy severity evaluated preoperative, 3-months and 6-months postoperative using Nurick myelopathy score. Functional status evaluated by Neck Disability Index (NDI) recorded preoperative, 3-months, and 6-months postoperative.

Results: 25 patients included, aging from 52 to 68 years. 164 screws inserted. At the end of follow up good bone fusion and cervical stability in flexion and extension views achieved in all patients. There were significant improvements in both Nurick scores and NDI at 6-months post-operative compared to pre-operative scores ($P < 0.001$). we had no nerve root or vertebral artery injury.

Conclusions: In sub-axial cervical spine, LMS fixation combined with multilevel laminectomy in patients when they had CSM with cervical spine instability, straight or kyphotic curve is a safe and easy technique. It has a good clinical outcome, good bone fusion, a low rate of hardware failure and a low rate of complications.

Keywords: Lateral mass fixation, Nurick score, Cervical spondylotic myelopathy



INTRODUCTION

Degenerative disease, trauma, neoplasms, and congenital anomalies are commonly seen in the cervical spine and the needed surgical decompression is obtained by cervical laminectomy and fixation obtained either anteriorly or posteriorly.^[1] Iatrogenic cervical kyphosis is caused by treating a common pathology such as spondylotic myelopathy with posterior decompression alone changing the normal cervical alignment.^[2] Anterior cervical decompression and fusion is the standard procedure used for treating many patients with such cervical pathologies. However, these procedures are associated with complications such as pseudarthrosis, and neurological complications.^[3,4] Roy-Camille introduced lateral mass fixation in 1979, since when this has been widely used after posterior cervical

decompression to fixate cervical spine.^[5] We aimed in this study to evaluate the safety and the clinical outcome when using lateral mass screw fixation in sub-axial cervical spine combined with cervical decompression laminectomy in patients with multi-level cervical spondylotic myelopathy.

METHODS

This is a prospective clinical study, conducted from the 1st of January 2015 to the end of December 2019, where selected patients operated on for multi-level cervical spondylotic myelopathy (CSM) from C3-C7 using decompression laminectomy and lateral mass screw fixation where 3 or more levels were fixated with 6 months follow up. The included patients showed either preoperative cervical instability evident on preoperative dynamic X-ray (flexion and extension views) or straight or kyphotic cervical curve on

lateral standing X-ray as those patients known to be at high risk of post laminectomy kyphosis. For those patients, we did pre-operative general examination, and full neurological examination.

For radiological evaluation, preoperative cervical spine imaging including plain x-ray (Antero-posterior, lateral, maximum flexion and extension), CT scan and MRI to show radiological evident of cervical cord compression at 3 or more levels and postoperative radiographs (Antero-posterior, lateral and maximum flexion and extension) were obtained at 1, 3 and 6 months after surgery to check the presence of hardware failure (screw loosening or breakage) and also to evaluate the stability and bone fusion at end of follow up. CT scan with bone window was done within a week after surgery to evaluate the screw trajectory and tip position. In order to evaluate the clinical outcome, the myelopathy severity was evaluated preoperative, 3-months and 6-months postoperative using the Nurick myelopathy Scoring System which has 6 grades from 0 to 5, a higher Nurick score corresponds with more severe myelopathy. [6] (see table;1) Functional status was evaluated by the Neck Disability Index (NDI) [7], which is designed to measure neck-specific disability and this questionnaire has 10 items concerning pain and activities of daily living including personal care, lifting, reading, headaches, concentration, work status, driving, sleeping and recreation. Patients were asked to rate each item on a scaling system ranging between "0" and "5", where "0" corresponds to no effect and "5" corresponds to complete disability. The sum of responses to all items formed the total raw score. Percentage score was then calculated by dividing the raw score by the total possible score (if all ten items were completed, the total possible score=50; if one section is missing or not applicable the total possible score=45) and multiplied by 100. [7] NDI scores were recorded preoperative, 3-months, and 6-months postoperative. Exclusionary criteria from this study included; cervical spine neoplasms, spinal traumatic fracture, cervical infection, patients underwent previous ACDF and patients with radiculomyelopathy.

Surgical technique Under general anesthesia where fiberoptic Intubation was used by the anesthesia team, we put the patient in prone position with the head held on slightly flexed by using three-pins skull fixation. Standard- midline incision was performed. All cervical lateral masses of interest were exposed bilaterally to facilitate fusion and allow for accurate screw trajectory. We used Magerl technique of lateral mass screw fixation where the entry point from C3 to C7 was 1mm medial and 1mm superior to the mid-portion of the lateral mass, and the screws directed 25°

lateral and 30° cephalic^[8] (see fig.;1). to open posterior cortex of the lateral mass at the entry point we used a sharp awl perpendicularly, then tapping into lateral mass superolateral quadrant according to aforementioned angles under lateral fluoroscopic guidance parallel to superior articular facet for cephalic trajectory while lateral trajectory needed was guided by resting the tap and then the screw driver on the tip of the spinous process of the vertebra during screw insertion process. before screw insertion a blunt probe was used to check integrity of bony walls of lateral mass all around and to measure appropriate length of the screw to be inserted. The same process was repeated at each targeted level on one side then repeated on the other one. After that we did cervical decompression laminectomy and for fusion, we did burr of the exposed bone surfaces of the lateral masses and placing bone graft harvested from the cervical laminectomy on them. The rods by then were secured to the screws. Closure was done after good hemostasis, over a drain which was removed within 48 hours after surgery. All included patients used hard neck collars for 6 to 8 weeks after the operation for neck protection and motion limitation to promote the bone fusion.

Informed consent and ethics committee approval: This research has given approval by Research Ethics Committee (REC) of Benha faculty of medicine, Benha University. A written informed consent was obtained from each patient after explaining all steps of this study. All procedures performed involving human participants were in accordance with the ethical standards of the institutional and/or national research committee and with the 1964 Helsinki declaration and its later amendments or comparable ethical standards.

STATISTIC METHODS

All statistical analyses were done using STATA/SE version 11.2 for Windows (STATA corporation, College Station, Texas). The mean \pm Standard Deviation (SD) and range were used to describe numerical data, while categorical data were described as frequency and percentage. Comparisons in the Nurick myelopathy index and the neck disability index scores obtained pre-operative, 3-months and 6-months post-operative were carried out using the Wilcoxon signed-rank test to detect differences in pairs. Changes in the degree of neck disability at 3-months and 6-months post-operative compared to pre-operative were examined using the Cochran's Q test. All statistical tests were conducted tow-sided, where a p-value<0.05 was considered statistically significant.

RESULTS

A total of 25 patients were included in this study, of them 19 patients are males (76%) and 6 patients

are females (24%). The age of those patients at the time of operation ranged from 52 to 68 years with a mean 58 ± 7.8 years. All included patients underwent cervical decompression laminectomy and lateral mass screw fixation, where 164 screws were inserted included 6 screws placed in C7 lateral mass in 3 patients. At the end of follow up good bone fusion and also confirmed cervical Stability in postoperative X-ray in flexion and extension views achieved in all the patients.

According to Nurick myelopathy score at the end of follow up, 21 patients (84%) showed improved score of at least one grade higher, 4 patients (16%) showed the same pre-operative score with no change and no patients showed deterioration of their pre-operative scores.

Table (2) shows comparisons between Nurick scores recorded pre-operative, 3-months, and 6-months post-operative. There was a significant reduction in the Nurick myelopathy scores obtained 3-months and 6-months post-operative compared to pre-operative scores (3.2 ± 1.1 , 2 ± 1.1 , and 1.7 ± 1.1 for pre-operative, 3-months, and 6-months post-operative, respectively; $P < 0.001$). In addition, scores recorded 6-months post-operative were significantly lower than those recorded at 3-months post-operative ($P = 0.003$).

The Neck Disability Index (NDI) percentage scores recorded pre-operative, 3- and 6-months post-operative are shown in Table (3). There was a significant improvement in the NDI 3- and 6-

months post-operative compared to pre-operative (54.7 ± 17.9 , 37.0 ± 20.5 , and 31.4 ± 21.3 for pre-operative, 3-, and 6-months post-operative, respectively; $P < 0.001$). Moreover, the NDI scores reported at 6-months post-operative were significantly lower than those reported at 3-months post-operative ($P = 0.004$).

Figure (2) demonstrates changes in the NDI degrees at 3- and 6-months post-operative to pre-operative. Pre-operatively, three (12%) patients had complete disability, 12 (48%) patients had severe disability, 7 (28%) patients had moderate disability, and three (12%) patients had mild disability. At the end of follow up 4 patients (16%) had no disability, 10 patients (40%) had mild disability, 6 patients (24%) had moderate disability, 3 patients (12%) had severe disability and 2 patients (8%) remained with complete disability as preoperative. Statistical analysis proved that there was significant improvement of the NDI degrees postoperatively ($P = 0.04$).

The complications we found were respiratory tract infection in three patients (12%), superficial wound infection in two patients (8%), and they were managed by high doses of antibiotics & daily dressing and none of them required revision. There was no root or vertebral artery injury in our study although perforation into transverse foramen was noted in one Screw. There were no procedural related deaths.

Table 1: NURICK SCORING SYSTEM [6]

Grade	Definition
0	Symptoms and signs of root involvement without spinal cord compression
1	Signs of spinal cord compression without difficulty in walking
2	Slight difficulty in walking that does not prevent full time employment
3	difficulty in walking that prevents full time employment but requires no help with walking
4	Ability to walk only with help
5	Chair bound or bedridden

Table 2: Comparisons of pre- and postoperative Nurick myelopathy scores at 3 and 6 months

Time	Nurick myelopathy score		Z1	P1	Z2	P2	Z3	P3
	Range	Mean \pm SD						
Pre-operative	1-5	3.2 ± 1.1	4.35	<0.001	4.32	<0.001	3.00	0.003
3-months post-operative	1-5	2.0 ± 1.1						
6-months post-operative	1-5	1.7 ± 1.1						

SD: Standard Deviation; P: Probability; Z: Wilcoxon signed-rank test; Z1 and P1: preop to 3 months post-operative; Z2 and P2: preop to 6 months post-operative; Z3 and P3: 3 months to 6 months post-operative.

Table 3: Comparison of pre- and postoperative Neck disability index scores at 3 and 6 months

Time	Neck disability index*		Z1	P1	Z2	P2	Z3	P3
	Range	Mean ± SD						
Pre-operative	24.4-88.9	54.7±17.9	4.29	<0.001	4.34	<0.001	3.56	0.004
3-months post-operative	6.7-82.2	37.0±20.5						
6-months post-operative	2.2-82.2	31.4±21.3						

*Percentage of the total possible score

SD: Standard Deviation; P: Probability; Z: Wilcoxon signed-rank test; Z1 and P1: preop to 3 months post-operative; Z2 and P2: preop to 6 months post-operative; Z3 and P3: 3 months to 6 months post-operative

Table (4): Changes in the Neck Disability Index (NDI) scores post-operative compared to pre-operative

Degree of NDI	Pre-operative		3-months post-operative		6-months post-operative		Cochran's Q test	P test
	No.	%	No.	%	No.	%		
No disability (NDI= 0-8%)	0	0.0	3	12.0	4	16.0	6.5	0.04
Mild disability (NDI= >8-28%)	3	12.0	6	24.0	10	40.0		
Moderate disability (NDI= >28-48%)	7	28.0	10	40.0	6	24.0		
Severe disability (NDI= >48-68%)	12	48.0	4	16.0	3	12.0		
Complete disability (NDI=>68-100%)	3	12.0	2	8.0	2	8.0		

NDI: Neck Disability Index in percentage of the total possible score

P: Probability

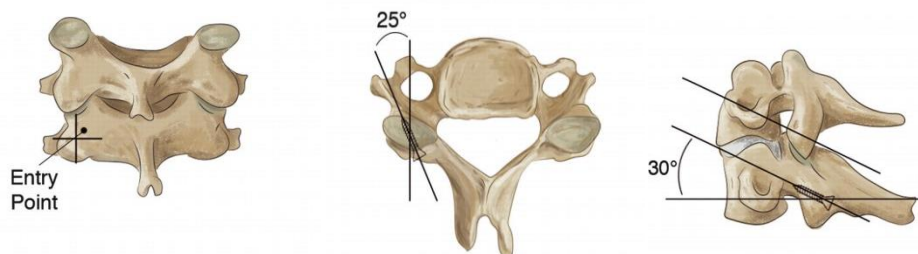


Fig. (1): Magerl technique of lateral mass screw fixation [8]

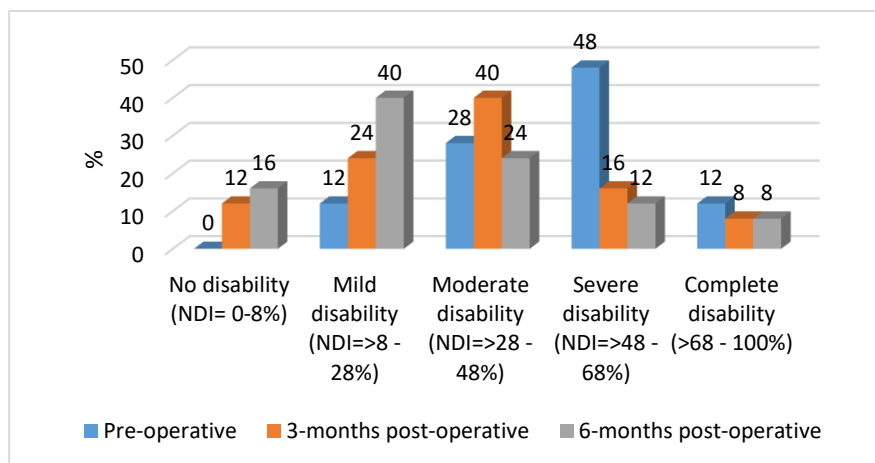
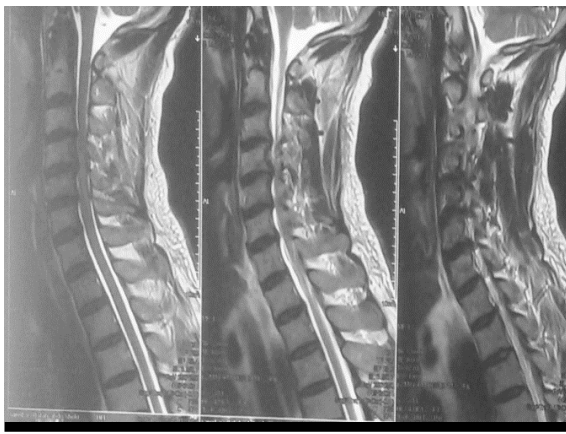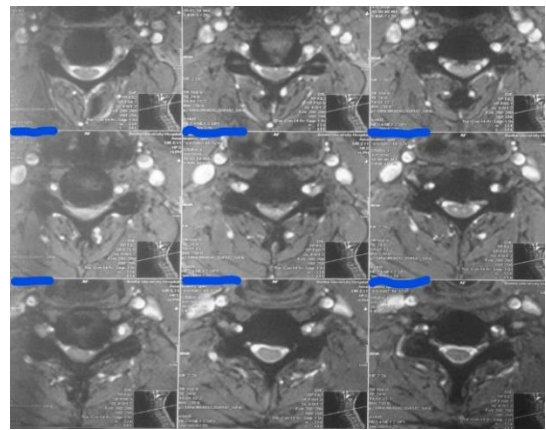


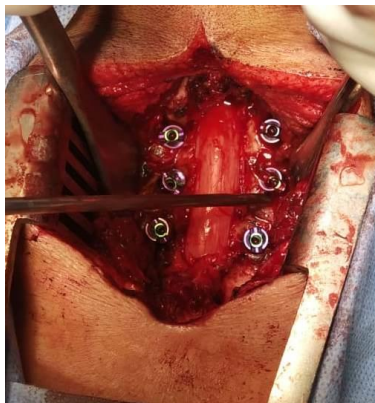
Fig. (2): Changes in the Neck Disability Index (NDI) scores post-operative compared to pre-operative
The Cochran's Q test= 6.5, and P=0.04



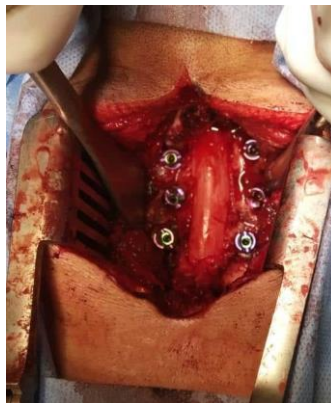
(a)



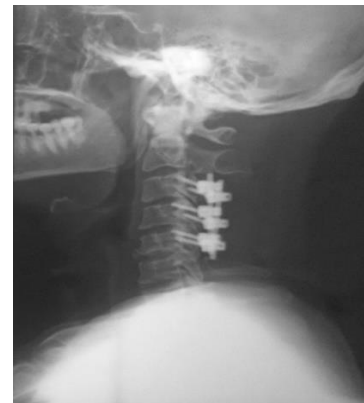(b)



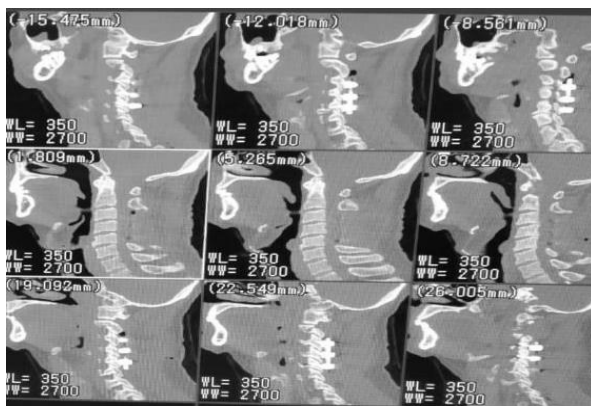
(c)



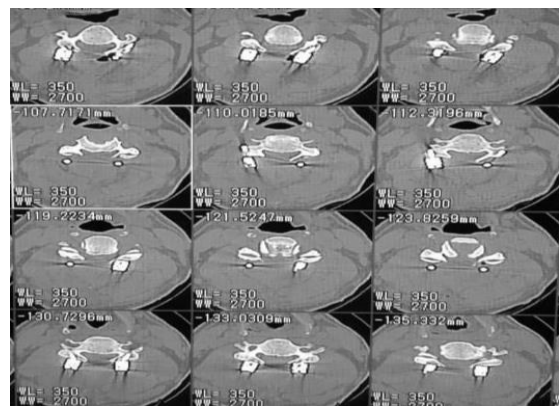
(d)



(e)



(f)



(g)

Fig.(3): showing male patient aged 52 years with cervical spondylotic myelopathy. (a & b) preoperative magnetic resonance imaging T2WI sagittal and axial views (c & d) intraoperative view showing decompression laminectomy C3,4 and 5 and lateral mass screw insertion. (e) postoperative lateral X-ray view showing C3,4 and 5 lateral mass fixations. (f & g) postoperative CT sagittal and axial cuts showing laminectomy and the screws trajectory.

DISCUSSION

In this study, all selected patients had CSM with either preoperative cervical instability evident on preoperative dynamic X-ray or had straight or kyphotic cervical curve on lateral standing X-ray underwent posterior cervical laminectomy and lateral mass screw fixation and fusion as those

patients known to be at high risk of post laminectomy kyphosis. [see fig.; 3] the presence and extent of cervical instability depends on careful evaluation of static and dynamic radiographs and on the presence of clinical signs of instability also as suggested by Olson and Joder^[9] e.g., paraspinal muscle spasm,

loss of cervical lordosis and neck pain with sustained posture.

Many techniques are now utilized for posterior sub-axial cervical stabilization such as posterior cervical wires, clamps, and screws and now the most used of them is posterior cervical screws which are inserted either in the lateral mass, pedicle, lamina, or facet joint. Lateral mass screw fixation has become the method of choice in stabilizing sub-axial cervical spine whenever the posterior elements (lamina, spinous process, or pedicle) are absent or compromised.^[9-11] Anatomically, the lateral mass is the bony junction between the superior and inferior articular processes, separated medially from the lamina by the medial facet line (a sulcus at the junction of the lamina and facet).^[10,11]

Posterior stabilization utilizing the lateral mass offers exceptionally high fusion rates, with ranges between 85-100% as reported in the literature.^[11,12]

In our study, at the end of follow up all the patients got benefit of lateral mass screw fixation, where statistically significant improvements were found in both the Nuric score for assessment of myelopathy severity and Neck disability index score for assessment of functional status when compared to patients' preoperative scores and we found our results comparable to the results of Yehya study in 2014.^[13] Huang RC et al.,^[14] and Chang V. et al.,^[15] used lateral mass fixation to treat patients with cervical myelopathy and both had similar results: the neurological status improved significantly in 85.5%, while 14.5% of patients showed no improvement. None of the patients had deterioration in their study and we found our results regarding improvement in myelopathy severity are in accordance with theirs. Some studies also showed lateral mass screw fixation followed by fusion as a promising and effective method of treatment in properly selected cervical injury patients.^[16]

Singrakhia et al., found that multilevel cervical laminectomy with lateral mass screw fixation for multilevel cervical myelopathy is a safe technique that provides decompression of the spinal cord, prevents the development of kyphotic deformity.^[17]

Du et al., concluded that multilevel cervical laminectomy with lateral mass screw fixation technique provides immediate stability, so it prevents the development of kyphotic deformity and adjacent segment degeneration by the prevention of osteophyte formation.^[18]

El rahmany et al., reported that, the main advantages of the lateral mass screw insertion over other posterior cervical screws are that it does not depend on the integrity of the laminae, or pedicle, to achieve fixation. It provides superior rotational stability at the facet joints, as it does not penetrate

them as in case of trans-facet screws. It is safer compared to the transpedicular screws, which has a high risk of injury to spinal cord. It can be applied easily without continuous intraoperative imaging. While the main limitations of LMF are relative risk of injury to the adjacent nerve roots, vertebral arteries, or facet joint; weak grip of the screw because of less cortical bone in the lateral mass; and small area for bone fusion left after plate insertion.^[19] Controversy remains regarding the use of LMS or pedicle screw at C7. LMS have good clinical outcomes, a low rate of complications, a high rate of fusion, and a low rate of screw loosening and breakage.^[20]

We used intraoperative C-arm fluoroscopy to guide the LMS insertion while Other studies reported that intra-operative spinal navigation increased the accuracy of screw insertion.^[21,22]

The common complications of lateral mass screw fixation are injury to the vertebral artery, nerve roots, and/or the cervical cord.^[23,24] There were no such complications in our study.

CONCLUSION

In sub-axial cervical spine, lateral mass screw fixation combined with multilevel cervical laminectomy in patients when they had CSM with cervical spine instability, straight or kyphotic curve is a safe and easy technique. It has a good clinical outcome, good bone fusion, a low rate of hardware failure and a low rate of complications.

Conflict of Interest: The authors report they have no conflict of interest.

Financial Disclosures: Nil.

Authors' contributions: All authors have participated in the research and article preparation and all of them read and approved the final version of the study

Authorship All authors have made contributions to the following: (1) the conception and design of the study, acquisition of data, analysis and interpretation of data, (2) drafting the article and revising it for important intellectual content, (3) final approval of the version to be submitted.

Acknowledgment: We would like to thank Dr. Hanaa El-Sayed Bayomy, Associate Professor of Public Health and Community Medicine, Benha Faculty of Medicine, Benha University for great effort in accomplishing the statistical analysis of this study

www.bu.edu.eg & www.fac.bu.edu.eg

REFERENCES

1. Al Barbarawi MM , Audat ZA, Obeidat MM, Qudsieh TM, Dabbas WF, Obaidat MH et al. Decompressive cervical laminectomy and lateral mass screw-rod arthrodesis Surgical analysis and outcome. Scoliosis and spinal disorder 2011;6 (10). Published online 19 May 2011

2. Emery SE. Cervical spondylotic myelopathy: Diagnosis and treatment. *J Am Acad Orthop Surg* 2001; 9 (3):76-88.
3. Blizzard DJ, Gallizzi MA, Sheets C, Klement,MR, Kleeman LT, Caputo AM et al. The role of iatrogenic foraminal stenosis from lordotic correction in the development of C5 palsy after posterior laminectomy and fusion. *Journal of Orthopaedic Surgery and Research* 2015; 10(160).
4. Shriver MF, Lewis DJ, Kshetry VR, Rosenbaum BP, Benzel EC, Mroz TE. Pseudarthrosis rates in anterior cervical discectomy and fusion: A meta-analysis. *Spine J*. 2015; 15(9):2016-27.
5. Roy-Camille R, Gailliant G, Bertreaux D. In: *Recent Advances Orthopedics*. McKibben B, editor. Edinburgh: Churchill-Livingstone; Early management of spinal injuries; pp. 57–87.
6. Nurick S. The natural history and the results of surgical treatment of the spinal cord disorders associated with cervical spondylosis. *Brain* 1972; 95:101–8.
7. Cleland JA, Childs JD, Whitman JM. Psychometric Properties of the Neck Disability Index and Numeric Pain Rating Scale in patients With Mechanical Neck Pain. *Arch Phys Med Rehabil*. 2008; 89(1):69-74
8. Baek JW, Park DM, Kim DH. Comparative analysis of three different cervical lateral mass screw fixation techniques by complications and bicortical purchase: cadaveric study. *J Korean Neurosurg Soc* 2010;48(3):193–8.
9. Olson KA, Joder D. Diagnosis and treatment of cervical spine clinical instability. *J Orthop Sports Phys Ther* 2001; 31:194-206.
10. Pelton MA, Schwartz J, Singh K. Subaxial cervical and cervicothoracic fixation techniques-indications, techniques, and outcomes. *Orthop Clin North Am*. 2012; 43:19–28.
11. Wu JC, Huang WC, Chen YC, Shih YH, Cheng H. Stabilization of subaxial cervical spines by lateral mass screw fixation with modified Magerl's technique. *Surg Neurol*. 2008;70: S1:25–33.
12. Abdullah KG, Steinmetz MP, Mroz TE. Morphometric and volumetric analysis of the lateral masses of the lower cervical spine. *Spine* 2009; 34:1476–9.
13. Yehya A. The clinical outcome of lateral mass fixation after decompressive laminectomy in cervical spondylotic myelopathy. *AJM*. 2014; 51:153–9.
14. Huang RC, Girardi FP, Poynton AR, Cammisa FP, Jr. Treatment of multilevel cervical spondylotic myeloradiculopathy with posterior decompression and fusion with lateral mass plate fixation and local bone graft. *J Spinal Disord Tech*. 2003;16: 123–9.
15. Chang V, Lu DC, Hoffman H, Buchanan C, Holly LT. Clinical results of cervical laminectomy and fusion for the treatment of cervical spondylotic myelopathy in 58 consecutive patients. *Surg Neurol Int*. 2014;5(3): S133–7.
16. Chowdhury FH, Haque MR. C1-C3 Lateral Mass Screw-Rod Fixation and Fusion for C2 Pathologies and Hangman's Fractures. *Asian Spine J*. 2014; 8:735–746.
17. Singrakhia MD, Malewar NR, Singrakhia SM, Deshmukh SS. Cervical Laminectomy with Lateral Mass Screw Fixation in Cervical Spondylotic Myelopathy: Neurological and Sagittal Alignment Outcome: Do We Need Lateral Mass Screws at each Segment? *Indian J Orthop*. 2017; 51(6): 658–665.
18. Du W, Zhang P, Shen Y. Enlarged laminectomy and lateral mass screw fixation for multilevel cervical degenerative myelopathy associated with kyphosis. *Spine J*. 2014; 14:57–64.
19. Elrahmany M, Zidan I, Anwar M, Nabawi A, Haitham A. Lateral Mass Fixation in Subaxial Cervical Spine: Anatomic Review. *Global Spine J*. 2012; 2(1): 39–46.
20. Coe JD, Vaccaro AR, Dailey AT, Ludwig SC, Brodt ED, Dettori JR et al. Lateral mass screw fixation in the cervical spine: A systematic literature review. *J Bone Joint Surg Am*. 2013; 95:2136–43
21. Theologis AA, Burch S. Safety and Efficacy of Reconstruction of Complex Cervical Spine Pathology Using Pedicle Screws Inserted with Stealth Navigation and 3D Image-Guided (O-Arm) Technology. *Spine (Phila Pa 1976)* 2015; 40 (18):1397–406.
22. Uehara M, Takahashi J, Mukaiyama K, Kuraishi S. Mid-term results of computer-assisted cervical pedicle screw fixation. *Asian Spine J*. 2014; 8 (6):759–67.
23. Katonis P, Papadakis S A, Galanakis S, Paskou D, Bano A, Sapkas G, et al. Lateral mass screw complications: analysis of 1662 screws. *J Spinal Disord Tech*. 2011;24(7):415–20.
24. Song M, Zhang Z, Lu M, Zong J, Dong C, Ma K et al. Four lateral mass screw fixation techniques in lower cervical spine following laminectomy: A finite element analysis study of stress distribution. *Biomed Eng Online* 2014; 13(1):115.

To Cite:

Desouky, A., Arab, A., Eltantawy, M., Elawady, M., Lateral Mass Screw Fixation in Sub-Axial Cervical Spine Combined with Decompression Laminectomy in Multi-Level Cervical Spondylotic Myelopathy Safety and Clinical Outcome. *Zagazig University Medical Journal*, 2023; (505-511): -.doi: 10.21608/zumj.2021.72982.2199.