



Potential Effect of Alendronate on Tooth Eruption and Molar Root Formation in Young Growing and Osteoporotic Albino Rats (A Histological and Histochemical Study)

Somaya M. Salwat⁽¹⁾, Mona H. M. Farid⁽²⁾ and Heba M. Hakam⁽³⁾

Codex : 28/1807

azhardentj@azhar.edu.eg

http://adjg.journals.ekb.eg

ABSTRACT

Aim: The aim of the present study to evaluate the potential effect of Sodium Alendronate on tooth eruption and root formation in young growing and osteoporotic albino rats. **Materials and Methods** Sixty newborn wister albino rats with their average weight 6 grams, each were used in the study. Rats were divided into 4 groups (group I, group II, group III & group IV) : GI negative control, GII positive control, GIII Alendronat treated group, GIV (alendronate + dexamethasone) then each group was divided into 3 subgroups according to the date of scarification at 7, 14, 30 days. Rats were subjected to subcutaneous injection of sodium alendronate and dexamethasone in their dorsal back. The specimens were processed for histological and histochemical analysis. **Results:** alendronate prevented tooth eruption and root formation but dexamethasone caused resorption of bone over developing molar but didn't affect molar eruption and root formation. **Conclusion:** sodium alendronate caused increase in bone formation and obstructed eruption pathway. Sodium alendronate prevented maturation of alveolar bone while dexamethasone caused destruction of alveolar bone but didn't affect normal tooth eruption.

INTRODUCTION

Tooth eruption is a developmental process by which teeth move from their bony crypt in which they begin their formation to their final position in the oral cavity which is divided into three stages: pre-eruptive, eruptive and post-eruptive stages. It was also described as five stages: pre-eruptive movements, intra-osseous eruption, mucosal penetration, pre occlusal eruption, and post-occlusal eruption. ⁽¹⁾

KEYWORDS

Sodium alendronate,
dexamethasone,
tooth eruption,
root formation.

- Extracted from master thesis entitled “ Potential Effect of Alendronate on Tooth Eruption and Molar Root Formation in Young Growing and Osteoporotic Albino Rats (A Histological Study and histochemical)”
- 1. Demonstrator of Oral and Dental Biology, Faculty of Dental Medicine for Girls , Al- Azhar University.
- 2. Professor and Head of Oral and Dental Biology Department, the Former Dean of Faculty of Dental Medicine for Girls, Al- Azhar University.
- 3. Assistant Professor of Oral and Dental Biology, Faculty of Dental Medicine for Girls, Al- Cairo University.

Several systemic conditions can affect the eruption process include renal malformation, bone diseases, tumors, syndromes as Gapo syndrome (it is probably an autosomal-recessive condition of growth retardation, alopecia, pseudo anodontia and optic atrophy) and osteoporosis (OP) which characterized by decrease bone strength that predisposes to an increased risk of fracture.⁽²⁾

Knowledge of the principles of the antiinflammatory action of corticosteroids has shown that these agents are capable of controlling the development of inflammatory processes from the irritation phase by inhibiting the production of arachidonic acid and consequently the production of prostaglandins, which have an important role in inducing vasodilatation and increasing vascular permeability. Thus, the vascular inflammatory events tend to diminish.⁽³⁾

Dexamethasone (DEX), an artificial glucocorticoid (GC), is used to treat inflammatory diseases and one of its side effect it can cause OP ; bone resorption . In vitro, DEX stimulates bone resorption in neonatal mouse calvariae . Both the incisors and molars were examined to determine if they responded in a similar manner to this GC. and, to determine the potential role of DEX on osteoclast formation.⁽⁴⁾

Bisphosphonate (Bps) are a class of the drug analogs of pyrophosphate which have high affinity to hydroxyapatite they have the ability to suppress osteoclast mediated bone resorption, and are widely used in the prevention and treatment OP and other bone disorders such as osteogenesis imperfecta, fibrous dysplasia, malignancy associated hypercalcaemia and idiopathic juvenile OP.⁽⁵⁾

DEX is known to induce osteoporotic changes in bone and consequently affects the eruption process on the other hand alendronate is a drug that suppress the osteoclastic function.⁽⁶⁾

MATERIALS AND METHODS

Dexamethazone 21-phosphate to induce osteoporosis : it is a glucocorticoid in the form of ready made ampoule preparation to be injected subcutaneous in dorsal back of newly born albino rats with average dose (100 ng/g body wt/day) in 100 mL of water for days(1–30) after birth

Sodium alendronate it is a bisphosphonate obtained from (sigma_ Aldrich company) as powder and prepared as follows : It is diluted with distilled water with percentage 1:1 to be injected subcutaneously in new born albino rats with average dose 2.5 mg/kg/day⁽⁷⁾

Sixty newborn wister albino rats with their average weight 6 grams were delivered from ten mother where each mother deliver six new born .The rats were obtained from the experimental animal house of faculty of pharmacy ,al-azhar university .All animals were caged and maintained under relative humidity 55 and thermostatically regulated room temperature at 23 . Meticulus care was taken to maintain cage hygiene providnce good ventilation. Along the experimental period ,the animals were fed breast milk from their mother.

Animals will follow the rules and regulation of the animal experimental studies approved by Ethical Committee including their facilities diet and method of scarification.

Rats were divided into 4 groups (groupI, groupII, group III &group IV) : GI negative control, GII positive control, GIII Alendronat treated group, GIV (alendronate + dexamethasone) then each group was divided into 3 subgroups according to the date of scarification at 7,14,30 days.

Animals will be observed daily. For scarification ,the animals in all groups were euthanized by intra-cardiac overdoses of sodium thiopental, and then separate the head from the body. Then mandibles were dissected carefully. the specimens were collected at days (7,14,30) from each experimental group, The specimens were obtained from the molar region by sagittal section then the sets of serial sag-

ittal sections were proceeding for light microscopy (L.M) and Histochemical examination (HC).

Histology and Histochemical

The specimens were fixed in 10% neutral formalin solution for 24 hours. The specimens were washed properly under running water to remove excess of the fixative formalin solution . Decalcification was carried out in 5% nitric acid and EDTA(ethylenediamine-tetra-acidic acid) at PH 7.

After decalcification, the specimens were washed under running water to remove the remaining acid, then were dehydrated in ascending grades of ethyl alcohol 50%, 70%, 90% and absolute ,cleared into two changes of xylene and embedded in paraffin wax. The embedded specimens were sectioned by rotaty microtome to 5 micron thickness. Then specimens were carried to histological examination via (H&E) stain and Collagen and osteoid localization using Masson’s Trichrome stain.^(8,9)

RESULTS

At day 14, eruption pathway couldn’t be detected and relatively thicker bone at occlusal portion in

both (GIII, GIV) when compared with the control group (Fig.1:D,G). There was more invasion of Hertwig’s Epithelial Root Sheath as well as the epithelial diaphragm by bone trabeculae at the cervical portion, in both (GIII, GIV) when compared with the control group (Fig.1:E,H) and increase in distribution of collagen fibers appeared as blue colour by using Masson trichrom stain (Fig.1:F,I)

At day 30, At the occlusal portion : The tooth was at advanced stage of development but showed failure of eruption, REE appeared discontinuous due to more invasion of bone trabeculae that reached enamel organ, No eruption pathway could be detected. in GIII, GIV(Fig.2:d, g). At the cervical portion: the root dentin didn’t form uniformly due to more invasion of primary bone trabeculae to Hertwig Epithelial Root Sheath which was disrupted by the invasion of bone trabeculae in GIII, GIV(Fig.2: e, h) while tooth appeared fully erupted and most of root is completely formed in control group (Fig.2: a,b,c). Marked reduction in calcified areas of bone appeared as red colour and collagen fibers is abundant appeared blue colour by using Masson trichrom stain in GIII, GIV(Fig.2: f,i).

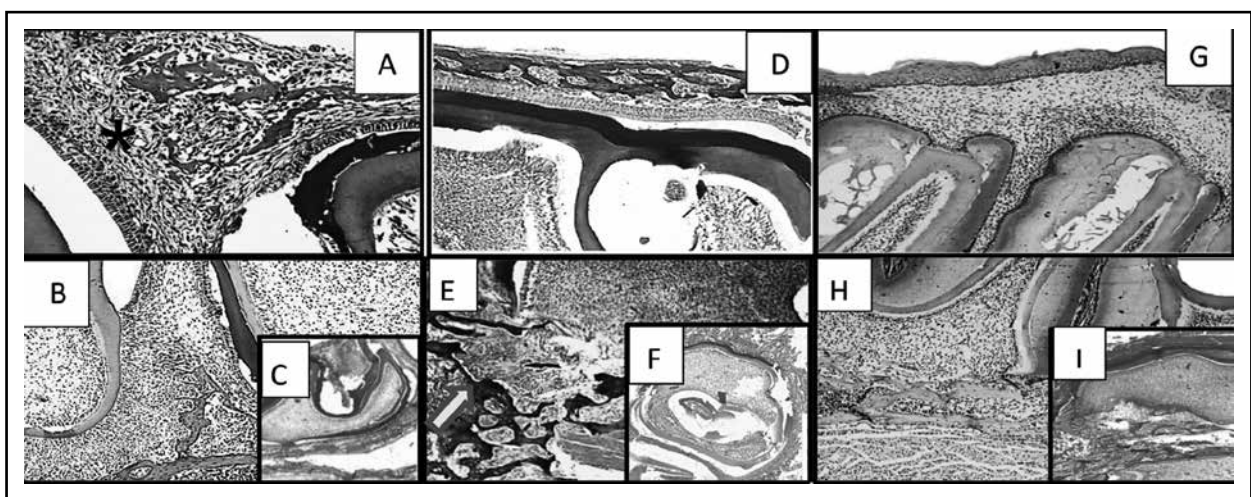


Fig. (1) Photomicrographs of of lower molar rat at day 14. A) control group (occlusal)H.&E., B) control group (cervical) H.&E., C) control group Masson trichrom stain, D) GIII (occlusal)H.&E., E) GIII (cervical) H.&E. , F) GIII Masson trichrom stain, G) GIV (occlusal) H.&E. , H) GIV (cervical) H.&E. , I) GIV, Masson trichrom stain Arrow: primary bone trabeculae, star: eruption pathway

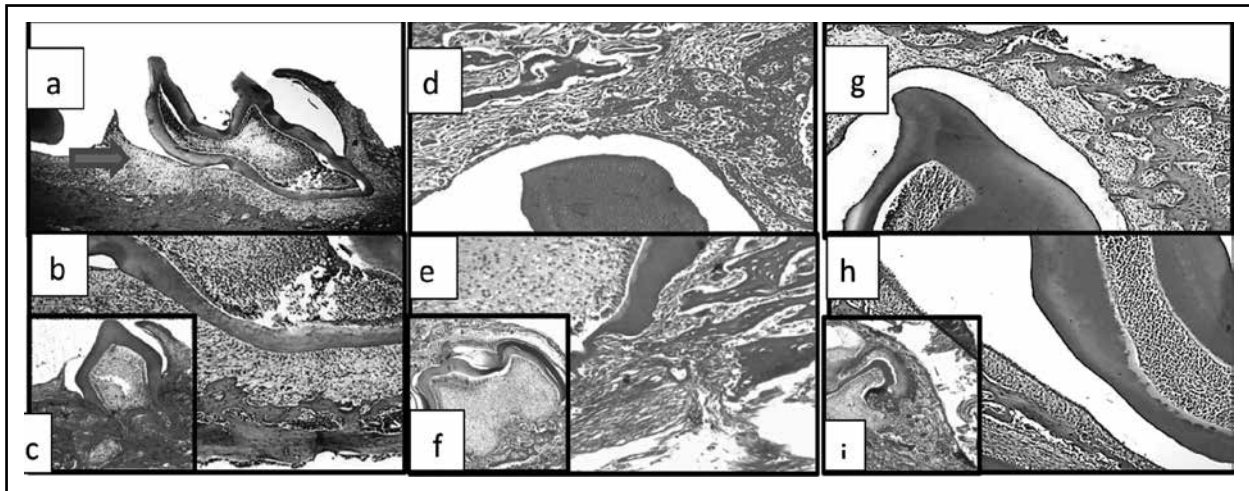


Fig. (2) Photomicrographs at day 30 :a) control group (occlusal) H.&E., b) control group (cervical) H.&E., c) control group Masson trichrom stain d) GIII (occlusal) H.&E., e) GIII (cervical) H.&E., f) GIII Masson, g) GIV (occlusal) H.&E., h) GIV (cervical) H.&E., i) GIV Masson, arrow: failure of tooth eruption.

DISCUSSION

In the current study, glucocorticoid (DEX) was used to induce OP and Bps (sodium alendronate) also was injected to counteract OP and the effect of both drugs on tooth eruption was utilized. These drugs were chosen because of their solubility in water which in turn facilitate their injection and transport to teeth and their widespread availability, non toxicity, ease of administration, more economical, absence of unwanted side effects and their effectiveness as crude preparations.⁽¹⁰⁾

The rats were scarificed at 7, 14 days to show physiologic development of tooth and physiologic changes before tooth eruption. Further more to show the eruption of the tooth and compare this control group with changes that occurred in the experimental groups, the rats were sacrificed at 30 day.

The ongoing study showed that sodium alendronate administered to rats from birth to 30 days of age (group III) impaired tooth eruption and root formation. The occlusal portion of the alveolar bony crypt showed no signs of resorption, instead areas of ankylosis were evident between the alveolar bone and the developing hard dental tissues

in the alendronate-treated specimens. This might be explained on the basis that sodium alendronate obtains an anti-resorptive effect, and therefore, the eruption pathway was obstructed.⁽¹¹⁾

Furthermore, Bps including sodium alendronate, are the backbone of treatment of adult bone diseases such as postmenopausal osteoporosis, cancer chemotherapy, in the prevention of malignant tumor bone metastasis , and alleviating bone pain caused by radiotherapy . Since this drug is also indicated in the therapy of several pediatric bone disorders. It is possible that alendronate administration to children or adolescents, in which odontogenesis and/or tooth eruption are taking place, might induce the structural alteration of teeth or even the failure of tooth eruption.⁽¹²⁾

The revealed results demonstrated that there was failure of tooth eruption in groups (III & IV) which may be explained by other investigators that alendronate is a more potent resorption inhibitor when compared to other Bps such as pamidronate when used on albino rats.⁽¹³⁾ Indeed, some investigators have detected delayed eruption of molars attributable to a low resorptive activity of osteoclasts, despite the finding that they exhibited

a ruffled border and a clear zone apposite to the bone surface. In this context, the administration of a more effective inhibitor of bone resorption improves the analysis of osteoclast activity in proportioning spatial conditions for tooth eruption.⁽¹⁴⁾

Concomitant with the lack of bony crypt resorption, no root formation has been observed during the entire periods of the present study of alendronate-treated rats and (DEX + alendronate) treated rats (group III & IV) respectively. The contact of bone trabeculae with the Hertwig's epithelial root sheath and the epithelial diaphragm might have arrested root development, since these epithelial cells are believed to induce the differentiation of root odontoblasts by secreting specific molecules or factors. The presence of many ankylosis sites prevented bone resorption at this region which hindered the process of root formation, as the latter occurs simultaneously with the displacement of tooth germ toward the oral cavity and bone resorption is necessary to complete the sequence of events.⁽¹⁵⁾

The results of the present study also allow the discussion of some aspects regarding the role of the dental follicle in tooth eruption. Previous experiments have shown the absence of tooth eruption in dogs after removal of their dental follicle indicating that it plays a key role in initiating tooth eruption. The invasion of bone trabeculae toward the tooth germ in groups (III&IV) certainly disrupts dental follicle homeostasis and might interfere with the releasing of factors responsible for triggering bone resorption at the occlusal portion of the crypt wall.⁽¹⁶⁾

The Bone trabeculae gradually thickened at (7,14,30) days in alendronate-treated specimens (group III) and also in (group IV). This bone trabeculae appeared highly cellular resemble the structure of primary (woven) bone, interconnected and have no lamellar structure because alendronate treatment prevents bone remodeling of the primary bone into secondary or lamellar bone. Although

osteogenesis in rat maxilla and mandible begins on the 17th week intrauterine day, the first osteoclasts only appear at the day of birth, i.e., when we start alendronate treatment. The lack of bone remodeling continue until 30-day-old animals in which alveolar processes are formed by trabeculae that still exhibit features of primary bone. Furthermore, the lack of bone remodeling might promote a number of abnormalities during skeletal growth. In general, the alveolar bone of alendronate-treated rats resembled osteopetrotic bone.⁽¹⁷⁾

Masson trichrome Stain in this study the mature alveolar bone in normal control group exhibited two main reaction: a blue reaction which is mainly localized to the osteoid tissue and collagen fibers distribution and a red reaction detected in calcified bone. An image which was nearly constant all over the experimental periods. In this control group, the collagen fibers were abundant in the newly formed bony specules and reflected by their intense bluish colour. In group II, III & IV there is marked decrease of calcified part which was appeared as a red colour, Obvious increase in collagen fiber distribution was evident by increase the distribution and intensity of the blue colour.

CONCLUSIONS

It was concluded that dexamethasone caused more bone resorption over developing molars but didn't affect eruption rate. Sodium alendronate treatment caused increase in bone formation and obstructed eruption pathway. Sodium alendronate prevented tooth eruption and root formation and prevented maturation of alveolar bone.

REFERENCES

1. Marks SC Jr and Schroeder HE, Tooth eruption: theories and facts. *Anat Rec* 1996; 374-393
2. G. Sandgren, "GAPO syndrome: a new case," *American Journal of Medical Genetics* 1995; 87-90
3. Rhen T and Cidlowski JA. Anti inflammatory action of glucocorticoids--new mechanisms for old drugs. *The New England journal of medicine* 2005; 1711-23

4. Chrousos GP and Kino T. Intracellular glucocorticoid signaling: a formerly simple system turns stochastic. *Science's STKE: signal transduction knowledge environment* 2005; 48-66
5. Harris ST, Watts NB, Jackson RD et al. Four-year study of intermittent cyclic etidronate treatment of postmenopausal osteoporosis: three years of blinded therapy followed by one year of open therapy. *Am J Med* 1993; 557-567
6. Asikaran S. Bisphosphonates: an overview with special reference to alendronate. *Ann ClinBiochem*, 2001; 608-23
7. Massa LF, Bradaschia-Correa V, Arana-Chavez VE. Immunocytochemical study of amelogenin deposition during the early odontogenesis of molars in alendronate-treated newborn rats. *J Histochem Cytochem* 2006; 713-725
8. Brown & Richard. *Histologic Preparations: Common Problems and Their Solutions*. College of American Pathologists, 2009; 95-101
9. Carson, Freida L., and Christa Hladik. *Histotechnology: A Self Instructional Text*. 3rd ed.: American Society of Clinical Pathologists, 2009; 162-165
10. Gary E. Wise, Robert L. Grier IV, Steven J. Lumpkin, Qiyang Zhang. Effects of Dexamethasone on Tooth Eruption in Rats: Differences in Incisor and Molar Eruption. *Clin. Anat.* 2001; 204-209
11. McClung M. Use of highly potent bisphosphonates in the treatment of osteoporosis. *Curr Osteoporos* 2003;116-122
12. Maasalu K, Haviko T, Martson A. Treatment of children with osteogenesis imperfecta in Estonia. *Acta Paediatr* 2003; 452-455
13. van Beek ER, Cohen LH, Leroy IM, Ebetino FH, Löwik CWGM, Papapoulos SE. Differentiating the mechanisms of resorptive action of nitrogen containing bisphosphonates. *Bone*, 2003; 805-811
14. Grier RL & Wise GE. Inhibition of tooth eruption in the rat by a bisphosphonate. *J Dent Res* 1998; 8-15
15. Marks SC Jr & Schroeder HE. Tooth eruption: theories and facts. *Anat Rec* 1996; 374-393
16. Wise GE, Frazier-Bowers S, D'Souza RN. Cellular, molecular and genetic determinants of tooth eruption. *Crit Rev Oral Biol Med* 2002; 323-334
17. (105) Marks SC Jr. Pathogenesis of osteopetrosis in the IA rat: reduced bone resorption due to reduced osteoclast function. *Am J Anat* 1973; 165-189