



## COMPARISON BETWEEN MTA AND BIODENTINE ON TREATMENT OF ACCIDENTLY RECENT FURCAL PERFORATION IN PRIMARY MOLARS: A PROSPECTIVE CLINICAL TRIAL

Hamdy M Badreldin <sup>1\*</sup>, Alaaeldin A. Ismail <sup>2</sup>, Samy Y. Elbayomy <sup>3</sup>

### ABSTRACT

**Objective:** Pulpotomy and pulpectomy usually are the most common techniques for pulp therapy in primary teeth. Despite the relative ease of performing these techniques, iatrogenic errors such as furcal perforation may occur. MTA and Biodentine were selected to test their ability to repair the furcal perforation in primary molars. **Subjects and Methods:** thirty patients with thirty accidentally furcally-perforated primary molars discovered and sealed immediately on the same visit with either Biodentine or MTA, then completed by conventional pulp therapy treatment either by pulpotomy or pulpectomy. The treated primary molars were then followed up clinically and radiographically for 12 months. **Result:** both materials showed high success rates, the first group of MTA showed 100% success, while the second group of Biodentine showed (93.3%) success with no significant difference ( $p=1.000$ ). **Conclusion:** MTA and Biodentine can successfully be used in treatment of iatrogenic recent furcal perforations that may occur during pulpotomy in primary molars.

**KEY WORDS:** primary molars, accidental perforation, Biodentine, MTA

### INTRODUCTION

Errors such as accidental perforation of pulpal floor is considered one of the most common errors during access cavity or orifice canal detection <sup>(1)</sup>. Such an error may affect the prognosis of treatment as it can lead to inflammatory response in periodontium that may cause irreversible destruction of the periodontal ligaments or even tooth loss <sup>(2)</sup>. Management of these iatrogenic accidents can pose a significant clinical challenge, mainly when they occur in primary teeth as it's considered

more complicated than the permanent ones due to anatomical variations in primary teeth, resorptive features, complex root canal system, and the child's behavior challenge <sup>(3,4)</sup>. That is why success rates can be different in primary teeth than permanent teeth. Treatment of cases with such iatrogenic errors was limited, and usually the affected teeth were immediately extracted, with or without later space maintainer, or may be left without treatment, leading to an inflammatory response and periodontal abscess, which may lead to the early loss of these teeth.

1. Assistant Lecturer, Department of Pedodontics and Oral health, Faculty of Dental Medicine Al-Azhar University, Boys, Cairo.
2. Assistant Professor, Department of Pedodontics and Oral Health. , Faculty of Dental Medicine Al-Azhar University, Boys, Cairo.
3. Professor, Department of Pedodontics and Oral Health, Faculty of Dental Medicine Al-Azhar University, Boys, Cairo.

• **Corresponding author:** badreldin\_h.209@azhar.edu.eg

Current developments in the techniques and materials utilized for root perforation repair have enhanced this procedure's prognosis<sup>(5)</sup>. Ideally, the material used for sealing root perforations should be non-toxic, non-resorbable, radiopaque and bacteriostatic with good sealing ability<sup>(6,7)</sup>. In addition, that material should present an osteogenic inductive capacity and biocompatibility<sup>(8)</sup>. A Lot of materials had been suggested to repair perforations such as: Amalgam, calcium hydroxide, calcium hydroxide with iodoform, IRM, Super EBA, light-cured glass ionomer, gutta percha, calcium phosphate, Cavite, composite resin, Portland cement, and MTA. However, there was no material which have the all desired ideal properties<sup>(9)</sup>.

Since the development of Mineral Tri-Oxide Aggregate (MTA) in 1993 by Mahmoud Torabinejad at Loma Linda University, the perforation repair turned to regenerative work that mostly fulfilled the ideal requirement of repair materials. Many recent researches were directed to use MTA and other like regenerative materials in such procedures<sup>(6)</sup>. Biodentine is a relatively new calcium silicate-based material which was introduced as a dentine substitute material; it is mainly composed of tricacium silicate, calcium carbonate, zirconium dioxide and calcium chloride as an accelerator to reduce its setting time<sup>(10)</sup>. Biodentine and MTA were chosen in this study to evaluate their effect when used to seal the recent accidental bifurcation perforation in primary molars.

## SUBJECTS AND METHODS

Thirty primary molars from 30 patients were selected from outpatient clinic at the department of Pedodontics and Oral Health, Faculty of Dental Medicine, Al-Azhar University in Cairo, Egypt. Teeth which were accidently perforated during pulpotomy or pulpectomy procedures by undergraduate students at the same clinic were selected for the study. Reassessment was done on spot, and after talking with the parents about the possibility

of the new treatment, a consent form was taken. The number on cases based on previous sample size calculation with effect size 0.5 and level of 95% confidence, and power of 80% they were divide into two equal group (15 to each group), group I for MTA, and group II for Biodentine.

Primary molars with iatrogenic recent furcal perforations were recruited to this study. Selected teeth had to have sufficient coronal tooth structure for restoration, and the perforation must have been discovered and treated immediately on the same visit. The exclusion criteria were:

- a. Teeth with insufficient coronal structure or with insufficient periodontal support.
- b. Molars with large periapical lesion including the succedenous tooth germ or with root resorption exceeding one third of the root length.
- c. Very large perforations extending more than 2/3 of pulpal floor area.

When the tooth was selected to be included in the study, cleaning the field within the cavity was done, and proper isolation using rubber dam was ensured. Then, irrigation and flushing the pulp chamber and perforation site with copious saline solution was done. A moist cotton pellet of 2.5% Sodium Hypochlorite was placed in the perforation site to control bleeding and disinfect the perforation site, then re-assessment for the tooth was done regarding the pulp condition. A series of large, sterile cotton pellets were placed into the chamber with pressure to obtain temporary hemostasis. Two materials were used for perforation repair, MTA (Neo MTA, NuSmile Ltd, Houston, USA) and Biodentine (Biodentine™, Septodont Ltd., Saint Maur des Fausse's, France). The MTA powder was mixed with sterile water in a ratio of 3:1 (powder to liquid) with a metal spatula on a glass slab to form the consistency of putty like paste, then material was transferred to the cavity by MTA carrier and condensed slightly to the site of perforation until

complete covering of the perforation. Biodentine comes in the form of a powder and liquid, the powder was mixed with the liquid (5 drops) in a capsule in the triturator for 30 seconds, which results in a gel-like structure. Biodentin was transferred to the perforation site by plastic applicator and condensed slightly to the wanted place.

Final pulp therapy, either by pulpotomy or pulpectomy, was performed according to the condition of the tooth treated. In teeth treated by pulptomy, after treatment of perforation, the rest of the pulpal floor covered by the same material of perforation treatment, in 3mm thickness by a cotton pellet damped with sterile water and squeezed well. The rest of the cavity filled with glass ionomer filling material (Fuji equia, GC Corporation, japan). The tooth directed to preparation of stainless steel crown (3M ESPE USA). Pulpectomy procedure involved determining the working length by placing initial files in the canals after treatment of the perforation then taking radiograph. The working length is 1-3 mm from the radiographic apex. Complete debridement of the pulpal tissue in the canal was done by suitable headstrom file. Rotary endodontic files (AF Baby Rotary, fanta, China) system were used to complete the preparation. Irrigation was done by sodium hypochlorite 2.5%. Calcium hydroxide with iodoform (Metapex, Meta Biomed. Korea) was used to obturate the prepared canals. Treatment success was evaluated based on the following clinical and radiographic criteria:

1. Tenderness to palpation.
2. Presences of swelling or fistula.
3. Mobility.
4. Radiographic evaluation: all the patient scheduled for radiographic examination every month for 12 months for presence of new periapical or inter-radicular radiolucency, pathologic root resorption and any existing lesion under the bifurcation area and increase in size.

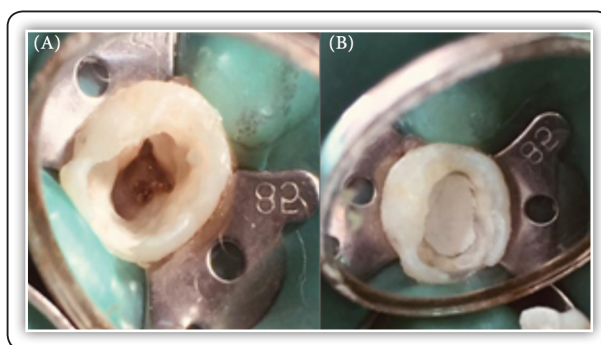


FIG (1) Sealing furcal perforation in lower 2<sup>nd</sup> primary molar with MTA. A) Perforation after blood hemostasis b) placement of MTA in cavity floor.

**Statistical Analysis:**

Differences were analyzed with chi square (c<sup>2</sup>) test and Fisher’s exact test when appropriate. Adjustments of p value were done using the Bonferroni method for multiple testing. All p-values are two-sided. P-values ≤0.05 were considered significant

**RESULTS**

The overall success rate was not statistically significant between the two groups, meaning that no difference in the effect between the two tested materials at the end of 12 months follow up (p=1.000). For Group I 100% of patients showed success, while 14 patients (93.3%) showed success in group II, (Table 1).

**TABLE (1):** Percentages and results of Chi-square (x2) for comparison of success rate between the two groups (Group I & Group II).

		Group I (MTA)		Group II (Biodentine)		
Period		Count	%	Count	%	P value
12m	Failure	0	0.0	1	6.7	1.000
	Success	15	100.0	14	93.3	

## DISCUSSION

This study was directed to evaluate the effect of Mineral Trioxid Aggregate (MTA) and Biodentin materials in the treatment of furcal perforation repair of primary molars. These materials are highly recognized and recommended for treatment of perforations in permanent teeth.

The results of the current study showed no significance difference between the two materials along the follow up period. The highest success rate was in the first 6 months for both groups, which showed 100% success, followed by the second period at 12 months and showed 100% for MTA group and 93.3%. Many trials come in favor with this current result in which they test the perforation treatment in relation to time such as studies done by Lantz & Persson<sup>(11-13)</sup> which they produced root perforations in dogs that were treated either immediately or after some delay, and the best results was most when perforations were sealed immediately. Moreover Seltzer et al.<sup>(14)</sup> treated 22 perforations in monkeys at intervals from immediately to 10 months post-perforation. While the periodontium was damaged in all teeth, the most severe tissue destruction was in the untreated perforations and in teeth where treatment was delayed while teeth with immediate sealing showed highly success rate. Moreover, Beavers et al.<sup>(15)</sup> observed consistent periodontal healing following immediate treatment of experimentally produced root perforations in a monkey model.

The high success rate was best attributed due to the lesser possibility of contamination of perforation site after exposure, as the perforation site is sealed immediately, so surrounding tissue inflammation is reduced, also the antibacterial effect of both materials can overcome any possible slight bacterial contamination during the procedures. Also the factor of higher sealing ability of both materials prevent further effect and leakage from the surrounding environment. Both materials pose high mechanical properties, rendering them able to withstand heavy

occlusal forces, hence increasing their stability and longevity till the time of exfoliation<sup>(4)</sup>.

Within the limitations of the current study it can be concluded that MTA and Biodentine can be efficiently used to seal accidental recent furcal perforations in primary molars.

## REFERENCES

1. Keine KC, Kuga MC, Pereira KF, Diniz AC, Tonetto MR, Galoza MO, Magro MG, de Barros YB, Bandeca MC, de Andrade MF. Differential Diagnosis and Treatment Proposal for Acute Endodontic Infection. *J Contemp Dent Pract.* 2015;16(12):977-83.
2. Silveira CMM, Sánchez-Ayala A, Lagravère MO, Pilatti GL, Comes OMM. Repair of furcal perforation with mineral trioxide aggregate: long-term follow-up of 2 cases. *J Can Dent Assoc.* 2008;74(8):729.
3. Haghgoo, R, Niyakan A M, Nazari Moghaddam B M , Asgary C S, and Mostafaloo N. An In vitro Comparison of Furcal Perforation Repaired with Pro-root MTA and New Endodontic Cement in Primary Molar Teeth- A Microleakage Study. *J Dent (Shiraz).* 2014 ; 15(1): 28-32.
4. Farhin A. Katge, Pooja Ravindra Shivasharan, and Devendra Patil .Sealing ability of mineral trioxide aggregate Plus™ and Biodentine™ for repair of furcal perforation in primary molars: An in vitro study. *Contemp Clin Dent.* 2016 ; 7(4): 487-92.
5. Holland R, Bisco Ferreira L, de Souza V, Otoboni Filho JA, Murata SS, Dezan E, Jr. Reaction of the lateral periodontium of dogs' teeth to contaminated and non contaminated perforations filled with mineral trioxide aggregate. *J Endod.* 2007;33(10):1192-7.
6. Weldon Jr K, Pashley DH, Loushine RJ, Norman Weller R, Frank Kimbrough W. Sealing ability of mineral trioxide aggregate and super-EBA when used as furcation repair materials: a longitudinal study. *J Endod.* 2002;28(6): 467-70.
7. Vajrabhaya L, Korsuwannawong S, Jantarat J, Korre S. Biocompatibility of furcal perforation repair material using cell culture technique: Ketac Molar versus ProRoot MTA. *Oral Surg Oral Med Oral Pathol Oral Radiol Endod.* 2006;102(6):e48-e50.

8. Han L., Kodama S, Okii T. Evaluation of calcium-releasing and apatite-forming abilities of fast-setting calcium silicate-based endodontic materials. *Inter endod J* 2015;28 (2): 124–130.
9. De-Deus G, Petrucci V, Gurgel-Filho E, Coutinho-Filho T. MTA versus Portland cement as repair material for furcal perforations: a laboratory study using a polymicrobial leakage model. *Int Endod J*. 2006;39(4):293-8.
10. Katge FA, Shivasharan PR, Patil D. Sealing ability of mineral trioxide aggregate Plus™ and Biodentine™ for repair of furcal perforation in primary molars: An in vitro study. *Contemp Clin Dent*. 2016; 7: 487-92.
11. Lantz B, Persson PA. Experimental root perforation in dogs' teeth. A roentgen study. *Odontol Revy*. 1965: 1657–238 .
12. Lantz B, Persson PA. Periodontal tissue reactions after root perforations in dogs' teeth. A histologic study. *Odontol Tidskr*. 1967: 75: 209–37.
13. Lantz B, Persson PA. Periodontal tissue reactions after surgical treatment of root perforations in dogs' teeth. A histologic study. *Odontol Revy*. 1970: 21: 51–62.
14. Seltzer S, Sinai I, August D. Periodontal effects of root perforations before and during endodontic procedures. *J Dent Res*. 1970: 49: 332–39.
15. Beavers RA, Bergenholtz G, Cox CF. Periodontal wound healing following intentional root perforations in permanent teeth of *Macaca mulatta*. *Int Endod J*. 1986: 19: 36–44.