

## Comparative study between Bupivacaine with Magnesium sulphate v.s. Bupivacaine with Dexmedetomidine in ultrasound guided Transversus Abdominus Plane (TAP) block as postoperative analgesia for pain in Cesarean section

Obstetrics and  
Gynecology

Monzer M. El-Saqqa<sup>1\*</sup>, M.B.B.Ch, Farid A. Kassab<sup>1</sup> MD, Mostafa M. El-Laban<sup>1</sup> MD, and Nasr A. M. Saad<sup>2</sup> MD.

**\* Corresponding Author:**

Monzer M. El-Saqqa  
[drmonzerelsaqqa@gmail.com](mailto:drmonzerelsaqqa@gmail.com)

Received for publication May 03, 2021; Accepted May 28, 2021; Published online May 28, 2021.

**Copyright** The Authors published by Al-Azhar University, Faculty of Medicine, Cairo, Egypt. Users have the right to read, download, copy, distribute, print, search, or link to the full texts of articles under the following conditions: Creative Commons Attribution-Share Alike 4.0 International Public License (CC BY-SA 4.0).

doi: 10.21608/aimj.2021.68189.1438

<sup>1</sup>Obstetrics and Gynecology Department, Faculty of Medicine, Al-Azhar University Cairo, Egypt.

<sup>2</sup>Anesthesia and intensive care Department, Faculty of Medicine, Al-Azhar University Cairo, Egypt.

**Disclosure:** The authors have no financial interest to declare in relation to the content of this article. The Article Processing Charge was paid for by the authors.

**Authorship:** All authors have a substantial contribution to the article.

### ABSTRACT

**Background:** Most of anesthesiologists use Magnesium sulfate and Dexmedetomidine as adjuvants to local anesthesia for improving the quality of regional anesthesia.

**Aim of the work:** To compare the effects and side effects of Magnesium sulfate and Dexmedetomidine when added to Bupivacaine on the quality of transversus abdominus plane block (TAPB).

**Patients and methods:** The study was done at the department of Obstetrics and Gynecology, Faculty of Medicine, Al-Azhar University, Cairo, Egypt from November 2019 to October 2020. A total of 50 female patients undergoing elective Cesarean section using post operative transversus abdominus plane (TAP) block were randomly assigned into two groups; Ultrasound-guided transversus abdominus plane (TAP) block was performed using 20 ml 0.25% Bupivacaine. Magnesium sulfate 150 mg (1.5 ml) and dexmedetomidine 0.5 mcg/kg were added in the ( Magnesium sulfate + Bupivacaine ) group and ( Dexmedetomidine + Bupivacaine ) group, respectively. Time to first analgesic call, pain scores at 2/6/12/24/48 hours, hemodynamic data and side effects were recorded.

**Results:** Dexmedetomidine group provided the longest duration of analgesia and the least consumption of postoperative rescue analgesia versus Magnesium sulfate group (P = 0.001). Dexmedetomidine group had higher incidences of post operative hypotension and bradycardia.

**Conclusion:** Magnesium sulfate and Dexmedetomidine was a useful adjuvant to Bupivacaine for transversus abdominus plane (TAP) block in improving the duration of postoperative analgesia. Dexmedetomidine provided longer duration and quicker onset of analgesia with lesser consumption of postoperative rescue analgesia, but the incidence of postoperative hypotension and bradycardia was higher than Magnesium sulfate.

**Keywords:** Caesarean Delivery; Dexmedetomidine; Bupivacaine; Magnesium Sulfate; Transversus Abdominus Plane Block.

### INTRODUCTION

Caesarean section (CS) is one of the most operations in the world. Effective postoperative analgesia after it is very important because it encourages breast feeding and facilitates early ambulation and recovery.<sup>1</sup> Postoperative analgesia is too important to prevent unwanted side effects such as venous thromboembolism, respiratory complications and increased hospital stay.<sup>2</sup> Post Caesarean discomfort and pain is expected; so, the analgesic regimen should assure safe and efficient sedative. Commonly, opioids and NSAIDs are used for post caesarean pain relief. While dose dependent respiratory depression is the most discomforting side effect, other insignificant side effects such as gastrointestinal upset, pruritus and urinary retention can be annoying during the first hours of puerperium. The transversus abdominus plane (TAP) block has been used for postoperative pain relief in different abdominal surgeries as part of the multimodal anesthetic

approach.<sup>3</sup> It creates satisfactory somatic anesthesia with no visceral blockade.<sup>4</sup>

Dexmedetomidine is a new generation highly selective  $\alpha_2$ -adrenergic receptor ( $\alpha_2$ -AR) agonist that is associated with sedative and analgesic sparing effects, perioperative sympatholysis, reduced commotion and delirium, maintenance of respiratory function and cardiovascular stabilizing effects. Recently, Dexmedetomidine as a local anesthetic adjuvant has been the subject of increasing attention as the possibility to prolong the block duration.<sup>5-7</sup> The combined use of a local anesthetic agent and dexmedetomidine, applied in TAP block, which targets peripheral nociceptive receptors may be an ideal protocol for pain control after Cesarean section (CS). Local anesthetics like bupivacaine act in different pathway as they bind to intracellular portion of voltage-gated sodium channels.

**The present study** aimed to compare magnesium sulphate and dexmedetomidine as adjuvants to bupivacaine in TAP block for LSCS patients using ultrasound guiding.

## PATIENTS AND METHODS

This study was conducted between November 2019 and October 2020, on total of 50 female patients attending to Sayed Galal University hospital and Nasser Institute for Research and Treatment hospital during the time of the study.

### INCLUSION CRITERIA:

18 - 35 years.

Elective LSCS under LSAB.

Normal bleeding profile.

No history of relevant drug allergy.

### EXCLUSION CRITERIA:

<18 , >35 years.

Patient refusal.

Bleeding disorder.

After getting the institutional ethics committee permissiveness, and the informed consent of the patient, the patient was kept nil per oral for 6 hours. An intravenous access was secured using an 18 gauge cannula. Standard monitors were attached and heart rate, BP and oxygen saturation were monitored. Patients underwent LSCS under LSAB through a pfannenstiell incision. At the time of wound closure, following skin closure, drugs were given into bilateral Transversus Abdominus Plane under ultrasound guiding.

Patients were divided into two groups (25 female in each) by randomisation.

Group BM – 20 ml 0.25% Bupivacaine + 150 mg (1.5 ml) Magnesium sulphate given

Group BD – 20 ml 0.25% Bupivacaine + 0.5 mcg/kg Dexmedetomidine given

Time to first analgesia, pain scores at 2/6/12/24/48 hours, hemodynamic data, side effects were noted. Time to first analgesia is the time after which first dose of rescue analgesia is given. Pain scores at 2/6/12/24/48 hours were noted on the basis of visual analog scale (VAS). Hemodynamic data: HR, BP and RR were noted after 2/6/12/24/48 hours.

Side effects: Sedation was assessed using inverted observer assessment of alertness scale. PONV was assessed using PONV assessment scale.

**Statistical method:** Calculation of the sample size was based on the effect of adding magnesium sulfate or dexmedetomidine to local anesthetic solutions on the duration of analgesia. Based on the results of previous studies,<sup>8</sup> 25 patients were required to detect a 20% change in QoR-11 (Quality of Recovery) score at  $\alpha$  error of 0.05 and study power of 80%. The sample size was calculated using the SPSS statistical software package (V. 20, Echsoft Corp., USA). Quantitative data were described as mean  $\pm$  standard deviation in parametric data and as median (IQR) in non parametric data and were analyzed using independent t-test with Mann Whitney test. Categorical data were presented as number (n) or percentage (%) and were analyzed by Chi-square test. Comparison of the continuous data within each group was performed using repeated measures analysis of variance. We used SPSS 20 (SPSS Inc., Echsoft Corp., USA) for statistical analysis.  $P < 0.05$  was considered statistically significant

## RESULTS

Age, weight, height, frequency of pregnancy and duration of surgery were similar in both groups with no significant statistical difference (Table 1).

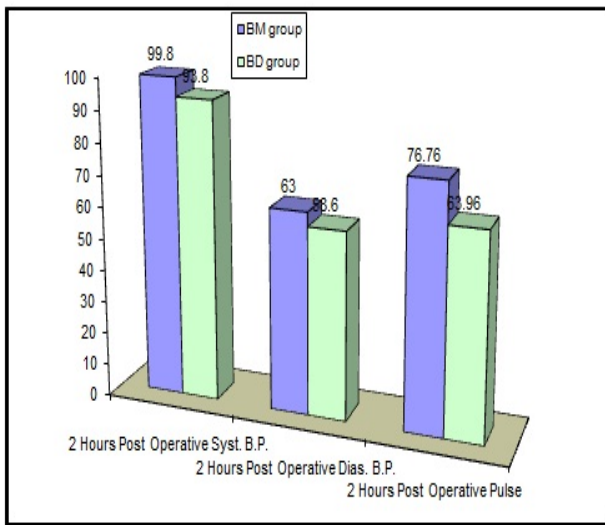
Parameters	Groups	BM group	BD group	P- value
		No.= 25	No.= 25	
Age(years)	Mean $\pm$ SD	24.88 $\pm$ 4.28	24.96 $\pm$ 4.10	0.946
	Range	18 – 34	18 – 33	
Parity(N)	Median(IQR)	1 (0 – 2)	1 (0 – 2)	0.886
	Range	0 – 3	0 – 3	
Syst.B.P.(mmHg)	Mean $\pm$ SD	102.80 $\pm$ 10.61	103.20 $\pm$ 11.45	0.899
	Range	90 – 120	90 – 120	
Dias.B.P.(mmHg)	Mean $\pm$ SD	65.60 $\pm$ 6.51	67.60 $\pm$ 7.79	0.329
	Range	60 – 80	60 – 80	
Temp.( $^{\circ}$ C)	Mean $\pm$ SD	37.02 $\pm$ 0.12	37.00 $\pm$ 0.11	0.711
	Range	36.8 – 37.2	36.8 – 37.2	
respiratory rate (c/m)	Mean $\pm$ SD	14.12 $\pm$ 1.30	13.76 $\pm$ 1.30	0.333
	Range	12 – 16	12 – 16	
Pulse(b/m)	Mean $\pm$ SD	79.76 $\pm$ 4.94	80.16 $\pm$ 6.80	0.813
	Range	70 – 90	70 – 90	
Height(cm)	Mean $\pm$ SD	159.12 $\pm$ 3.53	158.84 $\pm$ 4.26	0.801
	Range	153 – 165	152 – 167	
Weight(kg)	Mean $\pm$ SD	62.96 $\pm$ 1.99	62.20 $\pm$ 1.80	0.163
	Range	60 – 65	60 – 65	
Duration of surgery(min.)	Mean $\pm$ SD	54.92 $\pm$ 5.49	55.76 $\pm$ 4.99	0.574
	Range	45 – 65	45 – 65	

**Table 1:** Patient's characteristics and hemodynamic data in the studied groups.

Statistically significant difference in heart rate and blood pressure were observed at 2 hours and 6 hours for which no interventions were required. (Table 2) and (Figure 1)

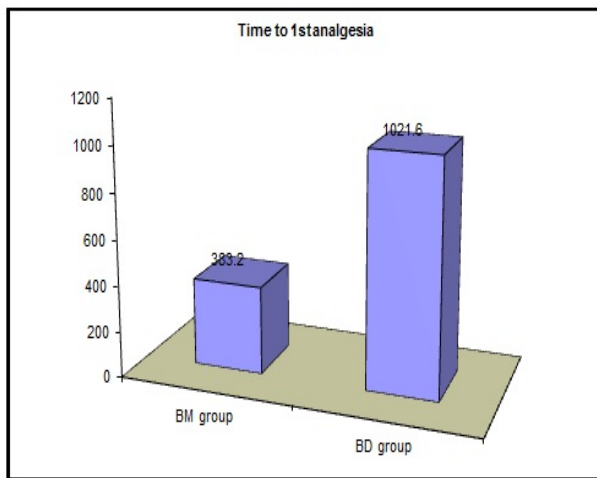
2 Hours Post Operative		BM group	BD group	P- value
		No.= 25	No.= 25	
Syst. B.P.	Mean $\pm$ SD	99.80 $\pm$ 10.36	93.80 $\pm$ 6.96	0.020
	Range	85 – 115	85 – 100	
Dias. B.P.	Mean $\pm$ SD	63.00 $\pm$ 6.77	58.60 $\pm$ 3.69	0.006
	Range	55 – 75	55 – 65	
Pulse	Mean $\pm$ SD	76.76 $\pm$ 4.75	63.96 $\pm$ 4.07	0.001
	Range	65 – 85	58 – 70	
Time to 1st analgesia	Mean $\pm$ SD	383.20 $\pm$ 15.20	1021.60 $\pm$ 107.23	0.001
	Range	360 – 420	900 – 1200	
24 Hours Analgesia consumption	50 mg	0 (0.0%)	25 (100.0%)	0.001
	100 mg	25 (100.0%)	0 (0.0%)	

**Table 2:** 2 hours post operative syst. BP, dias. BP and pulse differences between the studied groups.



**Fig. 1:** 2 hours post operative pulse, syst. and diast. BP between the studied groups.

In group BD, mean of time to 1st analgesia was  $1021.60 \pm 107.23$  minutes and in group BM, it was  $383.20 \pm 15.20$  minutes which was comparable in two groups with highly significant difference as shown in (Table 2) and (Figure 2).



**Figure (2):** Time to 1st analgesia in minutes between the studied groups.

In group BD, 24 hours analgesia consumption was 50 mg of tramadol while in group BM, it was 100 mg of tramadol which was comparable in both groups with highly significant difference as shown in (Table 2).

Statistically significant difference in pain scores were observed at 6 hours and 12 hours. Pain scores were statistically insignificant at 2 hours and 24 hours. Pain scores were statistically significant at 48 hours. (Table 3)

Parameters	Groups	BM group	BD group	P- value
		No.= 25	No.= 25	
VAS 2	Median (IQR) Range	0 (0 – 0) 0 – 2	0 (0 – 0) 0 – 1	0.815
VAS 6	Median (IQR) Range	3 (3 – 4) 3 – 4	0 (0 – 1) 0 – 1	0.001
VAS 12	Median (IQR) Range	3 (2 – 3) 2 – 3	1 (1 – 1) 0 – 2	0.001
VAS 24	Median (IQR) Range	2 (1 – 2) 1 – 4	2 (1 – 3) 0 – 4	0.662
VAS 48	Median (IQR) Range	1 (1 – 1) 0 – 2	0 (0 – 1) 0 – 2	0.015

**Table 3:** Visual analog score changes in the studied groups at 2,6,12,24 and 48 hours.

**DISCUSSION**

There are different ways to control post caesarean pain and discomfort.<sup>2</sup> Most commonly used way includes epidural, intrathecal and intravenous administration of opioids which are associated with modification of the normal hepatic, renal and gastrointestinal systems.<sup>9</sup> But, none of these techniques can be considered ideal due to lack of ease of technique and due to systemic side effects associated with them. So, in order to search for an ideal option for post operative pain relief in terms of efficacy, safety and simplicity, regional anaesthesia techniques come into respect.<sup>10,11</sup>

One of these techniques is transversus abdominus plane (TAP) block which has been used successfully in Caesarian delivery as a component of the multimodal analgesic approach. It blocks the thoracolumbar nerves T10 to L1 and provides adequate somatic analgesia with no visceral blockade.<sup>4</sup>

TAP block involves injection of local analgesic between the internal oblique and transversus abdominus muscle layers, with the aim of anaesthetising the intercostal nerves (T6-T11), subcostal nerve (T12) and ilioinguinal and iliohypogastric nerves (L1) which supply the anterolateral abdominal wall. We use surface landmarks of the triangle of Petit located along the mid axillary line bounded posteriorly by latissimus dorsi, superiorly by external oblique and inferiorly by iliac crest and a double fascial ‘pop’ to guide placement of the local analgesic. Ultrasonography has been used to improve the accuracy of TAP block.<sup>12</sup>

Dexmedetomidine is an alpha 2 adrenergic agonist which acts on alpha 2c and alpha 2a receptors in the dorsal horn thereby decreasing release of substance P and glutamate and hyperpolarisation of neurons. It prolongs the action of local anaesthetic when given as an adjuvant. Sensory block is more via the unmyelinated C fibres. It also has an opioid sparing effect. Common adverse effects include hypotension

and bradycardia.<sup>13</sup> Magnesium sulphate is an NMDA receptor antagonist. It regulates calcium influx into cells thereby increasing analgesic effects of opioids.<sup>14</sup>

In agreement with our results, Ammar and Mahmoud<sup>15</sup> concluded that the addition of dexmedetomidine (0.75 µg/kg) to bupivacaine (0.33%) for infraclavicular BPB in 60 patients undergoing upper extremity surgery hastened the onset of SB and MB, prolonged the duration of postoperative analgesia, and decreased opioid requirements with lower pain assessment scale, but there were no side effects documented in their study. Esmaglu *et al.*<sup>16</sup> reported that the addition of dexmedetomidine (100 µg) to levobupivacaine 0.5% for axillary BPB in 60 patients undergoing hand and forearm surgery resulted in fast onset time with long duration of the axillary block with prolonged duration of analgesia. Bradycardia was reported as a side effect in their study. Das *et al.*<sup>17</sup> concluded that the use of dexmedetomidine (100 µg) as an adjuvant to ropivacaine 0.5% for supraclavicular BPB prolonged the SB and MB duration and the duration of postoperative analgesia and decreased total analgesic need with no adverse effects.

As regards the effect of dexmedetomidine on the onset of the block, Gandhi *et al.*<sup>18</sup> found that the onset time of the SB and MB was faster in the control group than dexmedetomidine. Dexmedetomidine did not affect SB and MB onset time in some studies.<sup>17,19</sup> It shortened the SB onset time without affecting the MB onset time in another study.<sup>20</sup>

Mirkheshti *et al.*<sup>21</sup> and Marhofer *et al.*<sup>22</sup> noticed that dexmedetomidine shortened the MB onset time. Our study showed that dexmedetomidine induced bradycardia and hypotension in some patients during the procedures, which was evident in other studies as well.<sup>16,19,23</sup>

They concluded that addition of dexmedetomidine to bupivacaine in TAP block achieves better local anesthesia and provides better pain control post-operatively without any major side-effects which corresponds with our results.

In this study, statistically significant difference was noted in the time to first analgesia and also in the pain scores at 6 hours, 12 hours and 48 hours. First dose of rescue analgesia was given after 17 hours and 1 minute +/- 107 minutes, when dexmedetomidine was added as an adjuvant to bupivacaine for TAP block, whereas the first dose of rescue analgesia had to be given at 6 hours and 20 minutes +/- 15 minutes when magnesium sulphate was used as an adjuvant. Total opioid requirement during the first 24 hours was 50 mg of tramadol, when dexmedetomidine was used as an adjuvant, whereas 100mg of tramadol had to be used when magnesium sulphate was used as an adjuvant.<sup>24</sup> Statistically significant difference was noted in the heart rate and BP at 2 hours and 6 hours, but no interventions were needed for the same. No side effects were noted with both drugs during the study period except 2 patients developed allergy with magnesium sulphate. Hence Dexmedetomidine produces a longer duration of post operative

analgesia with no deleterious effects on haemodynamic status and no side effects compared to magnesium sulphate, when added to bupivacaine for TAP block.

## CONCLUSION

Magnesium sulfate or dexmedetomidine was a useful adjuvant to bupivacaine for transversus abdominis plane (TAP) block in improving the duration of postoperative analgesia. Dexmedetomidine provided longer duration and quicker onset of analgesia with lesser consumption of postoperative rescue analgesia, but the incidence of postoperative hypotension and bradycardia was higher than magnesium sulfate. 2 patients developed allergy to magnesium sulphate after injection.

## REFERENCES

1. Verma K, Malawat A, Jethava D and Jethava DD. Comparison of transversus abdominis plane block and quadratus lumborum block for post-caesarean section analgesia: A randomised clinical trial. *Indian J Anaesth.* 2019; 63:820-6.
2. Kerai S, Saxena KN and Taneja B. Post-caesarean analgesia: What is new?. *Indian J Anaesth.* 2017; 61:200-14.
3. Nair A. Bilateral quadratus lumborum block for post-caesarean analgesia. *Indian J Anaesth.* 2017; 61:362-3.
4. Abrahams MS, Horn JL, Noles LM and Aziz MF. Evidence-based medicine: Ultrasound guidance for truncal blocks. *Reg Anaesth Pain Med.* 2010; 35(2):S36-S42.
5. Brummett CM, Hong EK and Janda AM. Perineural dexmedetomidine added to ropivacaine for sciatic nerve block in rats prolongs the duration of analgesia by blocking the hyperpolarization-activated cation current. *Anesthesiology.* 2011; 115:836-43.
6. Marhofer D, Kettner SC and Marhofer. Dexmedetomidine as an adjuvant to ropivacaine prolongs peripheral nerve block: a volunteer study. *Br J Anaesth.* 2013; 110:438-42.
7. El-Boghdady K, Brull R and Sehmbi H. Perineural dexmedetomidine is more effective than clonidine when added to local anesthetic for supraclavicular brachial plexus block: a systematic review and meta-analysis. *Anesth Analg.* 2017; 124:2008-20.
8. Sakamoto B, Harker G, Eppstein AC and Gwartz K. Efficacy of local anesthetic with dexamethasone on the quality of recovery following total extraperitoneal bilateral inguinal hernia repair: a randomized clinical trial. *JAMA Surg.* 2016; 151(12):1108-15.
9. Ismail S, Afshan G, Monem A and Ahmed A. Postoperative analgesia following cesarean section: Intravenous patient controlled analgesia versus conventional continuous infusion. *Open J Anaesthesiol.* 2012; 2:120-6.

10. Shin HJ, Oh AY, Baik JS, Kim JH, Han SH and Hwang JW. Ultrasound-guided oblique subcostal transversus abdominis plane block for analgesia after laparoscopic cholecystectomy: A randomized, controlled, observer-blinded study. *Minerva Anesthesiol.* 2014; 80:185-93.
11. Ozmen S. Analgesia and respiratory function after laparoscopic cholecystectomy in patients receiving ultrasound-guided bilateral oblique subcostal transversus abdominis plane block: A randomized double-blind study. *Med Sci Monit.* 2015; 21:1304-12.
12. Shelly R, Ravinder KV and Jai S. Magnesium sulphate as an adjuvant to bupivacaine in ultrasound guided TAP block in patients scheduled for total abdominal hysterectomy under subarachnoid block. *Indian journal of Anaesthesia.* 2016; 60(3): 174-9.
13. Sandhya A, Ritu A and Praveen G. Dexmedetomidine prolongs the effect of bupivacaine in supraclavicular brachial plexus block. *Journal of Anaesthesiology Clinical Pharmacology.* 2014; 30(1): 36-40.
14. Mridu PN, Rakesh G, Tapan T, Dipika C and Anulekha C. To evaluate the efficacy of intrathecal magnesium sulphate for hysterectomy under subarachnoid block with bupivacaine and fentanyl: A prospective randomized double blind clinical trial. *Saudi Journal of Anaesthesiology.* 2012; 6(3): 254-8.
15. Ammar AS and Mahmoud KM. Ultrasound-guided single injection infraclavicular brachial plexus block using bupivacaine alone or combined with dexmedetomidine for pain control in upper limb surgery: A prospective randomized controlled trial. *Saudi J Anaesth.* 2012; 6:109-14.
16. Esmaoglu A, Yegenoglu F, Akin A and Turk CY. Dexmedetomidine added to levobupivacaine prolongs axillary brachial plexus block. *Anesth Analg.* 2010; 111:1548-51.
17. Das A, Majumdar S, Halder S, Chattopadhyay S, Pal S and Kundu R. Effect of dexmedetomidine as adjuvant in ropivacaine-induced supraclavicular brachial plexus block: A prospective, double-blinded and randomized controlled study. *Saudi J Anaesth.* 2014; 8:S72-S7.
18. Gandhi R, Shah A and Patel I. Use of dexmedetomidine along with bupivacaine for brachial plexus block. *Natl J Med Res.* 2012; 2:67-9.
19. Song JH, Shim HY, Lee TJ, Jung JK, Cha YD and Lee DL. Comparison of dexmedetomidine and epinephrine as an adjuvant to 1% mepivacaine in brachial plexus block. *Korean J Anesthesiol.* 2014; 66:283-9.
20. Kaygusuz K, Kol IO, Duger C, Gursoy S, Ozturk H and Kayacan U. Effects of adding dexmedetomidine to levobupivacaine in axillary brachial plexus block. *Curr Ther Res Clin Exp.* 2012; 73:103-11.
21. Mirkheshti A, Saadatniaki A, Salimi A, Manafi Rasi A, Memary E and Yahyaei H. Effects of dexmedetomidine versus ketorolac as local anesthetic adjuvants on the onset and duration of infraclavicular brachial plexus block. *Anesth Pain Med.* 2014; 4:e17620.
22. Marhofer D, Kettner SC, Marhofer P, Pils S, Weber M and Zeitlinger M. Dexmedetomidine as an adjuvant to ropivacaine prolongs peripheral nerve block: A volunteer study. *Br J Anaesth.* 2013;110:438-42.
23. Zhang Y, Wang CS, Shi JH, Sun B, Liu SJ and Li P. Perineural administration of dexmedetomidine in combination with ropivacaine prolongs axillary brachial plexus block. *Int J Clin Exp Med.* 2014;7:680-5.
24. Vinit KS, Abhishek M, Sanjay A, Sanjay K, Sunil S & Raj K. Comparative Evaluation of Dexmedetomidine and Magnesium Sulphate on Propofol Consumption, Haemodynamics and Postoperative Recovery in Spine Surgery: A Prospective, Randomized, Placebo Controlled, Double-blind Study. *Advanced pharmaceutical bulletin.* 2016; 6(1):75-81.