

Possible Protective Effect of Anisum Oil on Aspartame Induced Changes in Cerebellum of Albino Rats (Light and Electron Microscopic Study)

Mohammed Younis Sobhey^{1*}, MSc ; Mahmoud Ibrahim Al-Naggar¹, MD; Abd-Elmaboud Emara El-Sayed¹, MD and Mohamed Abdel Haye Autifi¹, MD

* Corresponding Author:

Mohammed Younis Sobhey
mys442233@gmail.com

Received for publication April 14, 2021; accepted May 28, 2021; published online May 28, 2021

Copyright The Authors published by Al-Azhar University, Faculty of Medicine, Cairo, Egypt. Users have the right to read, download, copy, distribute, print, search, or link to the full texts of articles under the following conditions: Creative Commons Attribution-Share Alike 4.0 International Public License (CC BY-SA 4.0).

doi: 10.21608/aimj.2021.68328.144

¹Department of Anatomy and Embryology, Faculty of Medicine Al-Azhar University.

ABSTRACT

Background: Aspartame (ASP) is an artificial sweetener which might cause changes in the cerebellum.

Objective: To evaluate the histological changes in the cerebellar cortex of albino rats treated by aspartame and the impact of co-treatment with anisum oil.

Material and methods: The study was done at Pharmacology Department Lab., Faculty of Medicine, Al-Azhar University, between January and March 2020. Sixty rats divided into four equal groups: Group 1 (control group): served as control animals. Group 2 (anisum oil): received 0.5 ml/kg/d/b wt. of anisum oil once daily. Group 3 (ASP group): received daily 250 mg/kg. body wt. of ASP dissolved in distilled water and given orally to animals through intra-gastric tube for 2 months. Group 4: received 0.5 mL/kg/b wt. of anisum oil once daily as prophylaxis, followed by ASP after 2 hours for 2 months. Then the rats were anesthetized and their cerebella were investigated.

Results: The histopathological results revealed changes in the myelinated nerve fibers, granular cells, and Purkinje cells of ASP-treated animals. The cytoplasm of some of these cells appeared deeply stained. Ultrastructural evaluation showed dilated rough endoplasmic reticulum of Purkinje cells and degenerated mitochondria. Nuclei of the granular cells appeared less condensed. There were thickening of the myelinated sheath of most of myelinated nerve fibers and myelin sheath of the others appeared splitted. The changes were less found in co-administration of anisum oil with ASP.

Conclusion: ASP neurotoxicity could affect cerebellar cortex as a target area. Meanwhile uses of oil of anisum with ASP might alleviate the toxic effect induced by ASP on brain tissue.

Keywords: anisum oil; aspartame; ultrastructure; histopathology; cerebellum.

Authorship: All authors have a substantial contribution to the article.

Disclosure: The authors have no financial interest to declare in relation to the content of this article. The Article Processing Charge was paid for by the authors.

INTRODUCTION

Aspartame (ASP) is an artificial diet sweetener, is widely distributed. ASP structure is a methyl ester¹. It is distributed in more than 6000 components, like carbonated drinks and low calories chocolate². ASP passes to circulation and to all parts of the body. It also might reach the brain tissues, because it could pass through blood-brain barrier. It might be one of reasons of neurological toxicity³. It has been metabolized to form many derivatives such as aspartic acid, yield phenylalanine, and methanol.

Then, it under oxidation gives another component which are formic acid and formaldehyde in the substance of tissues. Presence of one of these oxidative components like formic acid was the reason for dangerous effects of intoxication caused by methanol in the tissues of humans and animals⁴. Therefore, some authors said that process of metabolism of ASP occurring in the cell mitochondria, is the reason for the nuclear and mitochondrial DNA damage affecting its power to

give adequate energy, so results in high amounts of damaging free radicals⁵.

There is a suggestion that continuous use of products containing ASP is accompanied with occurrence of so many neurological symptoms like seizures⁴, memory loss⁶, headache⁷. Plant's derivatives give us a very good chance to decrease these harm symptoms that occur since plants and their healthy extracts defined traditionally as the cure for multiple diseases for a far time⁸. Aniseed is one of the widely distributed aromatic plants; it has been distributed over many countries like Iran, India and Turkey⁹. Multiple and different studies revealed that component of aniseed contains mainly anethole (85%) as an active component, as well as anisaldehyde, methylchavicol, eugenol and estragole¹⁰. Anisum oil has various medical and therapeutic indications in diseases like neurologic, digestive, and respiratory disorders¹¹. The aim here in our study was to highlight the protective role of anisum oil on the cerebellar changes caused by ASP, through observing histopathological and ultrastructural alterations.

MATERIAL AND METHODS

Animals:

The study was done at Pharmacology Department Laboratory of Al-Azhar Faculty of Medicine, Cairo, between January and March 2020.

Experimental design:

Sixty adult male albino rats, in four groups (15 rats in each one):

RESULTS

Light microscopic results:

H&E-stained sections:

Group I (control group), revealed that the cerebellar cortex appeared normal and formed of an outer molecular layer, an inner granular layer and one row of classic regular Purkinje cell layer found in between molecular and granular cell layers. The molecular layer formed of a clear area with few basket cells widely separated from each other. Purkinje cell layer formed of a single row of cells which are flask—shaped containing vesicular, rounded, large nuclei. The granular layer formed of small granular cells which are deeply stained (Fig.1 a, b).

Group II (anisum oil treated rats), showed three layers of cerebellar cortex. Molecular layer was seen to be formed of basket cells multiple in number and scattered. Purkinje cells are flask-shaped, with basophilic cytoplasm and nucleus appeared clear, darkly stained nucleolus and whole layer appeared in a monolayer arrangement. Granular layer showed multiple small cells which darkly stained (Fig.1 c, d).

Group III (ASP-treated rats), revealed the molecular layer shrunken and showed also congested blood capillaries resulted in hemorrhage which also found in this layer. There were disorganized Purkinje cells with clear cytoplasm and marked pyknotic alterations. There were intermingling with other cells

Group I: (control group) received distilled water daily.

Group II: (anisum oil group) given 0.5 mL/kg body wt. anisum oil daily for 2 months¹².

Group III: (ASP group) received 250 mg/kg body wt. ASP as a daily oral dose for 2 months dissolved in distilled water¹³.

Group IV: (anisum oil + ASP group) received 0.5 mL/kg body wt/d. Anisum oil is given once daily as prophylaxis¹², then 250 mg/kg body wt. ASP after 2 hours as a daily dose for 2 months¹³.

Chemicals:

ASP was purchased from Al-Ameriya Company (Alexandria, Egypt). ASP present in tablet form, each containing 20 mg. The tablets were dissolved in distilled water and administered to rats. Dose correspond human, 40–50 mg/kg/b wt. species factor, need 5–6 times increase than human dose, as metabolism of rat to ASP more fast than human metabolism¹⁴.

Anisum oil was taken from an aromatic shop in Cairo (Egypt). The required daily dose of anisum oil was 0.5 mL/kg body wt. daily¹².

At the selected time, the rats were anesthetized through inhalation of ether. The cerebellum gently dissected. Specimens were prepared, then stained with hematoxylin and eosin (H&E) for light microscopic examination.¹⁵ Other specimens were prepared then stained with double staining technique of uranyl acetate, then followed by lead citrate solutions for an electron microscopic examination.¹⁶

of both granular and molecular layers. Purkinje cells severely shrunken, degenerated, scattered, and shape was irregular with hard defined boundaries of cell. The Purkinje cells also were few in number and surrounded with clear halos. The granular cells were deeply stained in granular layer with large spaces separated these cells. The basket cells in the molecular layer appeared deeply stained with scattered pyknotic and clear spaces also vacuolated cytoplasm also found. (Fig. 2 a, b).

Group IV (anisum oil and ASP-treated rats), revealed a wider molecular layer which contained numerous scattered basket cells with clear haloes. The Purkinje cells were flask in shape with rounded, vesicular, and large nuclei. They were distributed in single layer present at region between both molecular and granular layers. There were many granule cells which appeared normal in shape present at the granular layer which formed of well-defined boundaries and separated by narrow spaces (Fig. 2 c, d).

Toluidine blue-stained sections:

Group I (control rats), revealed pyriform shape of Purkinje cells with vesicular, rounded, large nuclei and they distributed in a single layer with prominent Nissl granules and nucleolus in cytoplasm (Figure 3a).

Group II (anisum oil treated rats), revealed the Purkinje cells with flask-shaped, and with rounded, large and vesicular nuclei. They were distributed in mono layer like control. Cytoplasm contained prominent Nissl granules and nucleolus (Fig. 3b).

Group III (ASP-treated rats), showed degenerated Purkinje cells which also was irregular, shrunken and with hardly noticed nucleus (Fig. 3c).

Group IV (anisum oil and ASP-treated rats), revealed flask shaped Purkinje cells with nucleus centrally located. There were also obvious nucleolus and Nissl granules found in cytoplasm (Fig. 3d).

Electron Microscopic Findings:

Group I (control rats), showed normal Purkinje cell, with cell membrane appeared well-defined. The nucleus appeared normal with prominent nucleolus. There were large number of mitochondria in cytoplasm. Many axons were present, some myelinated and some unmyelinated (Fig. 4a).

Granular cells revealed intact nuclear membranes with normal nuclei (Fig. 4b).

Group II (anisum oil treated rats), showed Purkinje cell like control as cell membrane well-defined. The

Nucleus also normal and nucleolus was prominent. Also, numerous mitochondria were found in cytoplasm (Fig. 4c).

Granular cells were intact and nuclei seemed also normal like that in control animals (Fig. 4d).

Group III (ASP-treated rats) showed Purkinje cells with shrunken outlines and cell membrane appeared irregular. Also, abnormal shrunken nucleus was noticed with irregular and deformed nuclear envelope. There were many vacuolations in cytoplasm; and rough endoplasmic reticulum appeared dilated. There were many lysosomes and degenerated mitochondria in cytoplasm. Purkinje cells were surrounded by many degenerated axons (Fig. 5a).

Granular cells were degenerated in shape with deformed nucleus and vacuolated cytoplasm (Fig. 5b).

Group IV (anisum oil and ASP-treated group) revealed Purkinje cell which appeared nearly normal with intact nucleus and normal nuclear envelope. There were numerous intact mitochondria and rough endoplasmic reticulum (Figure 5c). Granular cells appeared with intact cytoplasm and nuclei (Fig. 5d).

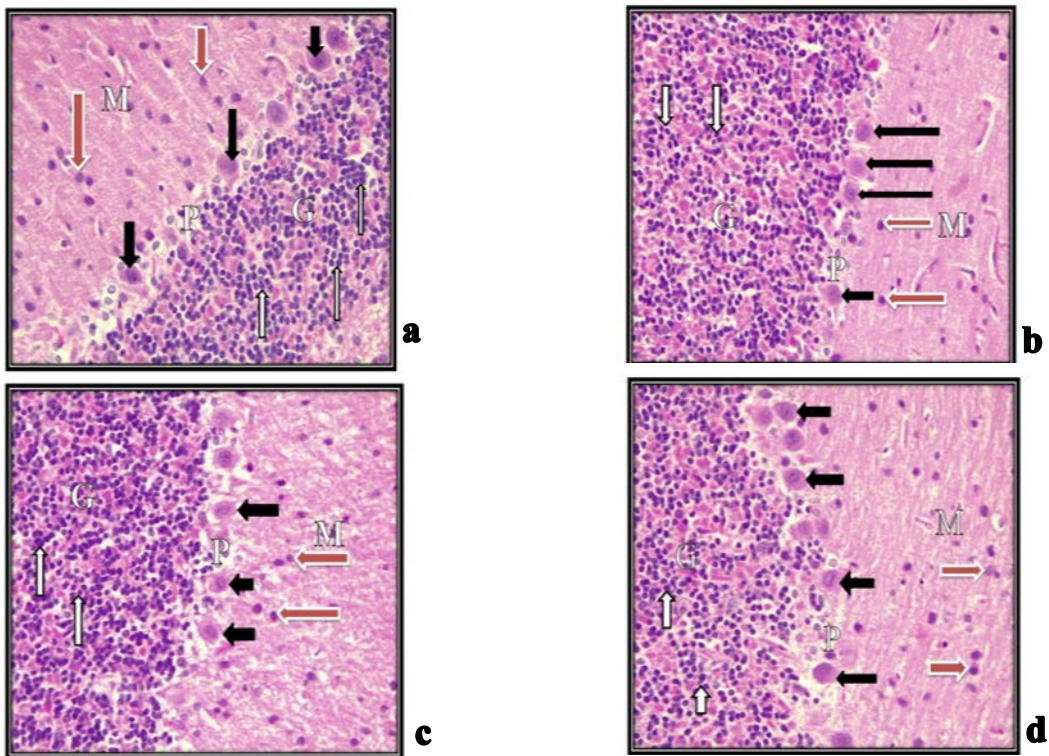


Fig.1: A photomicrograph of cerebellar cortex: (a) Control rat showing molecular layer (M) with a few widely separated basket cells (red arrows). The Purkinje cell layer (P) one row of flask-shaped cells with vesicular nuclei (black arrows). In the granular layer (G) deeply stained small granular cells (white arrows). (b) Control rat showing normal layers; molecular (M) with scattered basket cells (red arrow), Purkinje (P) with monolayer of Purkinje cells; pyramidal in shape, pale cytoplasm and intact nuclei with a prominent nucleolus (black arrows). Granular layer (G) formed of small granular cells; with nuclei deeply stained (white arrows). (c) Anisum oil rat showing cortical layers, molecular (M) with few basket cells widely separated (red arrows). Purkinje (P) with single row of flask-shaped cells with rounded, vesicular, and large nuclei (black arrows). Granular (G) with deeply stained small granular cells (white arrows). (d) Anisum oil rat showing layers of cerebellar cortex, molecular (M) with few separated basket cells (red arrows). Purkinje (P) with one row of flask-shaped Purkinje cells (black arrows). Granular (G) with small, granular cells (white arrows) (H& E, X400).

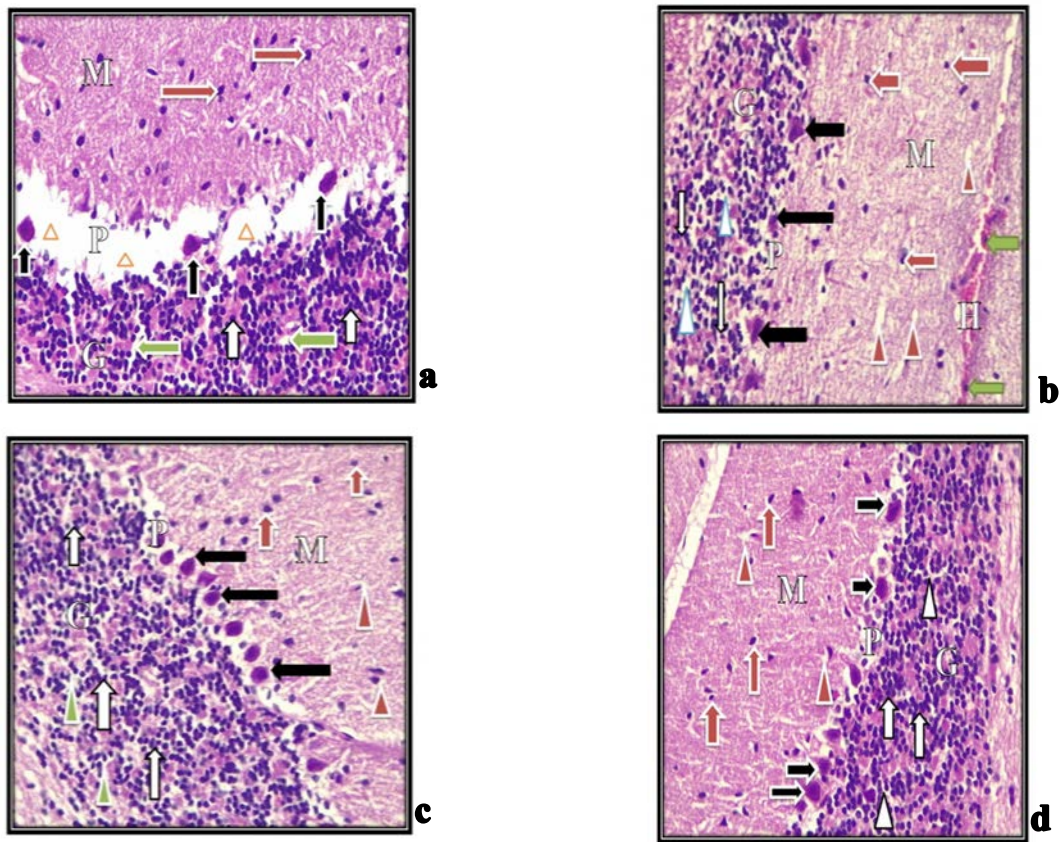
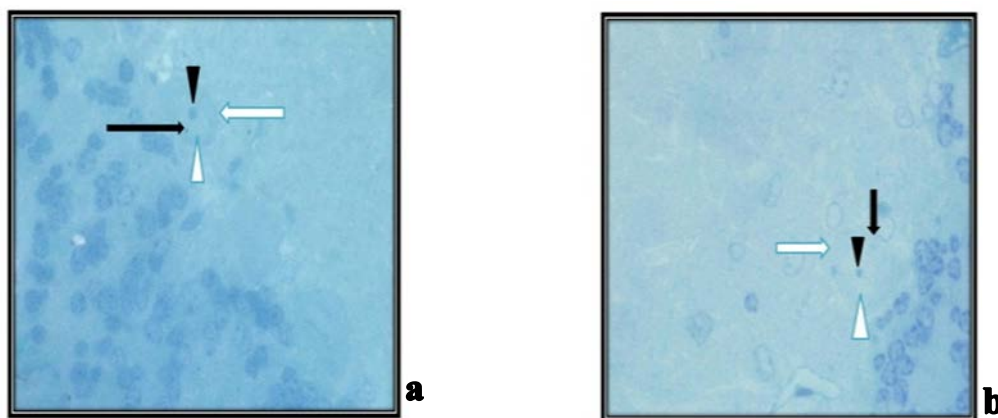


Fig.2: A photomicrograph of cerebellar cortex: (a) ASP-treated rats showing Molecular layer (M) with basket cells increased in numbers (red arrows). Purkinje cells (black arrows) disorganized, lose their pyriform appearance pyknotic changes and with large space in between (arrows heads). Granular (G) with small deeply stained granule cells (white arrows) with large spaces (green arrows). (b) ASP-treated rat showing molecular layer (M) basket cells appeared scattered with nuclei deeply stained (red arrows) also spaces (red arrow heads) Marked hemorrhage (H) and mononuclear cell (green arrows) infiltration were noticed. Purkinje cells (black arrows) few, severely degenerated, deeply stained with pyknotic nuclei. Granular (G) contains degenerated small granular cells deeply stained (white arrows) with abnormal intercellular spaces (blue arrow heads). (c) Anisum oil + ASP rat showing molecular layer (M) wider with many scattered basket cells (red arrows) with clear haloes (red arrow heads). Purkinje cells (black arrows) one layer of nearly normal oval in shape and central vesicular nuclei. Granular layer (G) normal thickness with many deeply stained granule cells (white arrows) fine spaces in between (green arrow heads). (d) Anisum oil + ASP rat showing improvement of the cerebellar layers. Molecular (M) with scattered basket cells (red arrows) and vacuolations (red arrow heads). Purkinje cells (black arrows) one layer of normal cells which oval in shape. Granular (G) with numerous apparently normal granular cells (white arrows) with fine spaces (white arrow heads) (H&E, X400).



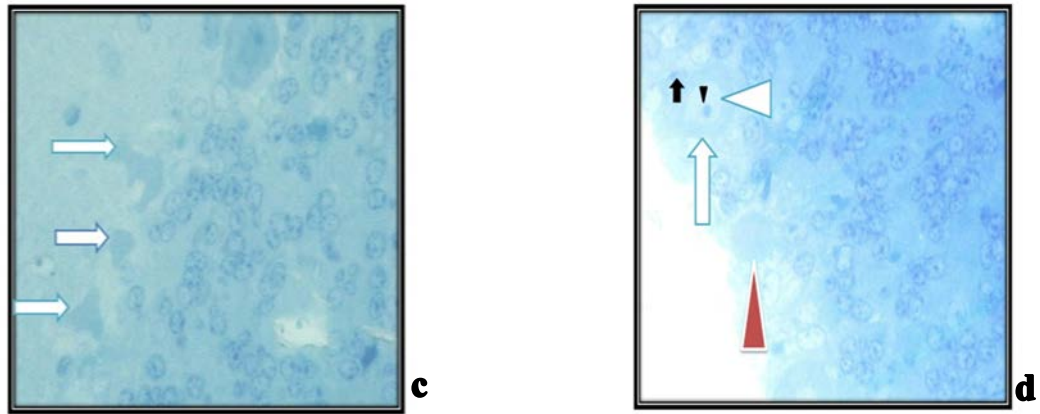


Fig.3: Photomicrograph of semithin section in the cerebellar cortex: (a) Control rat showing Purkinje cell (white arrow) pyriform in shape with nucleus large, vesicular and central (arrow head) prominent nucleolus (black arrow head) and Nissl granules (black arrow). (b) Anisum oil treated rat showing flask shape Purkinje cells with defined nucleus like control (arrow head) with prominent nucleolus (black arrow head) and Nissl granules (black arrow). (c) ASP-treated rat showing shrunken irregular Purkinje cells (arrows) with hardly identified nuclei and darkly stained cytoplasm. (d) Anisum oil + ASP-treated rat showing return of normal appearance of Purkinje cells (arrow) with central nucleus (white arrow head) and prominent nucleolus (black arrow head) and Nissl granules (black arrow). Few Purkinje cells with hardly identified nucleus and darkly stained cytoplasm were noticed (red arrow head) (Toluidine blue, X 1000).

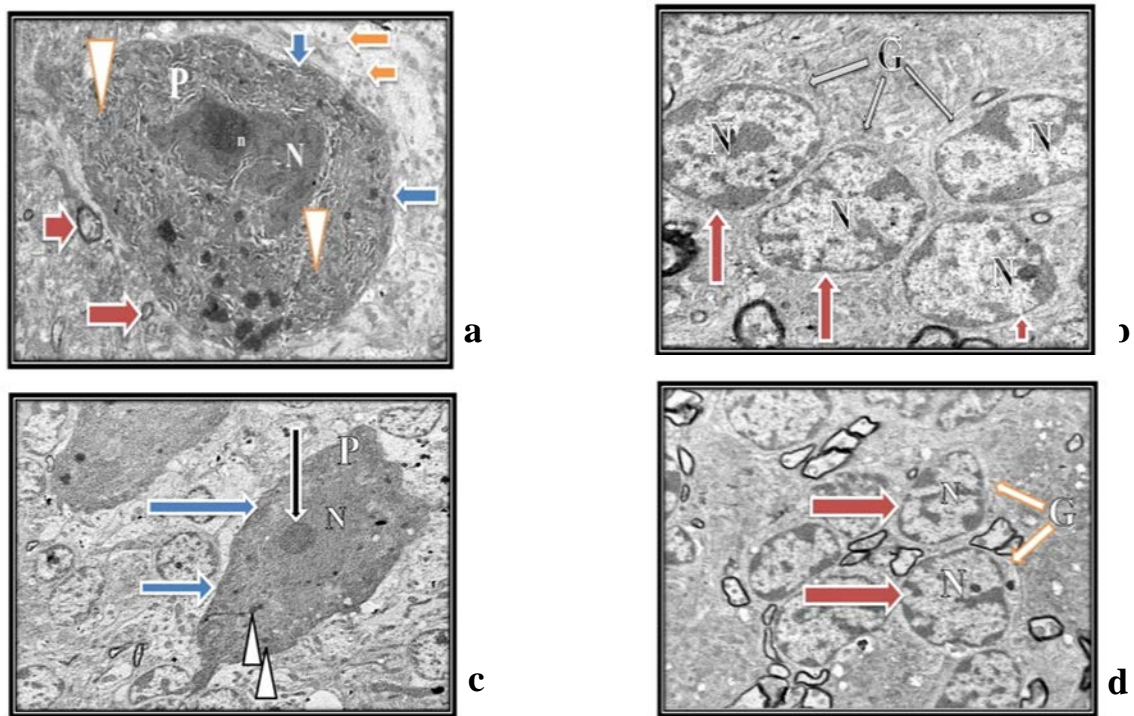


Fig.4: An electron micrograph of the cerebellar cortex: (a) Control rat showing normal Purkinje cell (P), well-defined cell membrane (blue arrows). The nucleus (N) appeared normal, well defined nucleolus (nu). Number of mitochondria in cytoplasm (arrow heads). The cell surrounded by large number of axons, myelinated (red arrows) and unmyelinated (orange arrows) (TEM, X4000). (b) Control rat showing granular cells (G), intact nuclear membranes (red arrows) and normal nuclei (N) (TEM, X6000). (c) Anisum oil treated rat showing normal Purkinje cell (P), with well-defined cell membrane (blue arrows). Normal nucleus (N) well defined nucleolus (black arrow). Number of mitochondria in cytoplasm (arrow heads) (TEM, X4000). (d) Anisum oil treated rat showing many granular cells (G) intact nuclear membranes (red arrows) normal nuclei (N) (TEM, X6000).

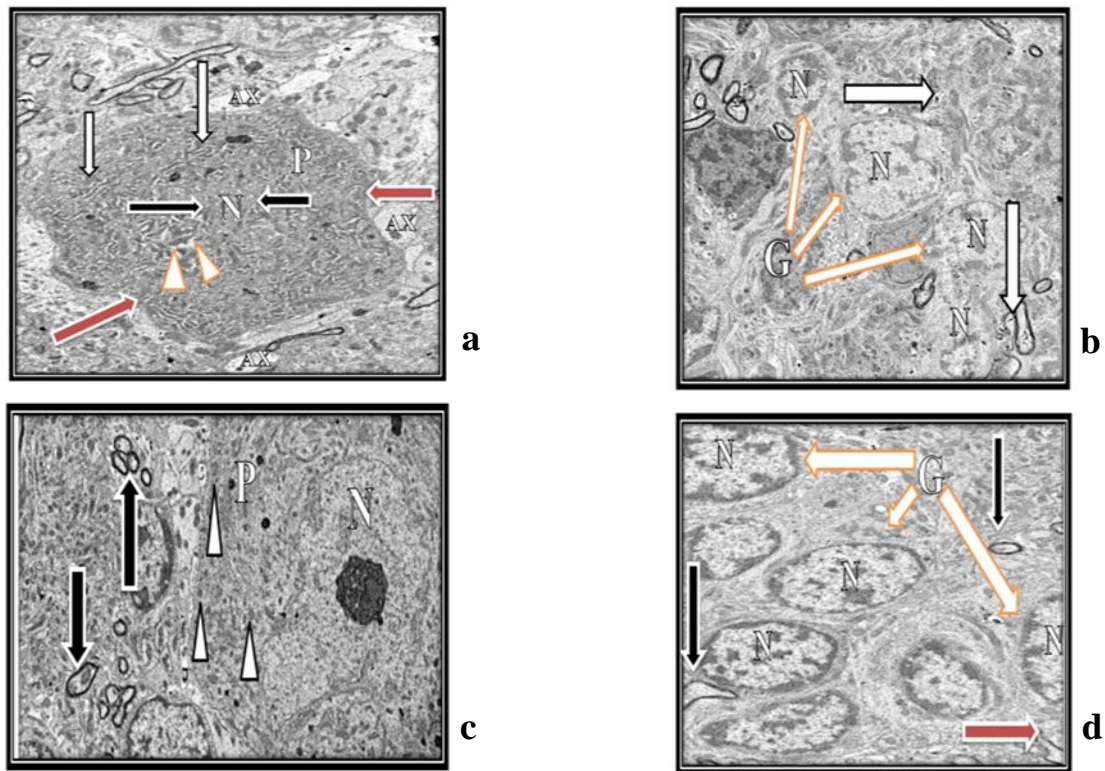


Fig.5: An electron micrograph of the cerebellar cortex: (a) ASP-treated rat showing shrunken Purkinje cell (P), irregular cell membrane (red arrows) and shrunken nucleus (N) with irregular nuclear envelope (black arrows). Dilated rough endoplasmic reticulum in cytoplasm (white arrows), many degenerated mitochondria (arrow heads). Degenerated axons (AX) are noticed (TEM, X4000). (b) ASP-treated rat showing degenerated axons (white arrows). Granule cells (G) degenerated and shrunken with abnormal nucleus (N) (TEM, X6000). (c) Anisum oil + ASP treated rat showing apparently normal Purkinje cell (P) nearly normal nucleus (N). Many normal mitochondria in cytoplasm (arrow heads). Normal myelinated axons (arrows) (TEM, X4000). (d) Anisum and ASP revealed normal cells (G) normal nuclei (N). Numerous normal axons (black arrows) few degenerated axons (red arrow) (TEM, X6000).

DISCUSSION

Numerous reports revealed that ASP toxic effects increased 20 years after FDA approved ASP¹⁷. Therefore, the aim of the current study was to detect the long treatment of ASP for 2 months could lead to different pathological effects to the cortex. In our study, the cortex of ASP group revealed abnormalities in the layer of Purkinje. Abnormal, degenerated margin of perikarya of it, frequently observed nuclei, cytoplasm deeply stained and loss pyriform shape of Purkinje cells. Histopathological alterations in the tissue of the cerebellum. The present study is enforced by Abd El-Samad¹⁸. Similar alterations in the treatment of cerebellum by cisplatin were reported, histological evaluation showed degenerative changes in Purkinje cells such as pyknosis which may reach up to cell death¹⁹. Alterations in the cells of Purkinje mean that involving of the single cells can send information outside the cerebellum²⁰. Recently found, ASP enhances the cell toxicity, tubule generation and oxygen reactive species²¹. In the present ultrastructure results of ASP-treated animals, revealed damaged and degenerated mitochondria in

the granular cell layer, rough endoplasmic reticulum showed dilated, Purkinje cells nuclei were condensed and thickening myelinated fibers were seen. These findings were similarly reported by Abd El-Samad¹⁸. Some reports discussed when increase stimulus to ASP that may cause formation of large numbers of nitrogen and oxygen species. Radicals resulted as destroy of proteins of cells and breakdown of DNA belong to mitochondria²². This is because the importance of mitochondria in energy production inside the neuron, so the change in its role cause possible cell damage. Also, chronic changes in the mitochondria of the cerebellum may be the main cause in the depression that occur to the rats²³. Generation of myelin is crucial for neurological health. So, if any harm occurs to it that could cause harm effect on speed of neuronal signal, conduction and time. This is very important for normal function of intact neuronal circuits²⁴. In our study anisum oil + ASP treated group done to determine the role of treatment with anisum oil on cerebellar cortex structure. In this group the Purkinje cells and nuclei required their normal architecture. The ultrastructure of the cells of these group showed normal nuclei, the mitochondria slightly normal and rER also nearly normal. These findings considered landmark about restoration of normal architecture of Purkinje cells

following treatment by anisum oil. This enhancement caused by the great antioxidant effect of anisum oil in destroying reactive oxygen species so equalize their harm effects on the target tissues. The anisum oil have a great radical chelating role through inhibiting Fe²⁺-chelating and H₂O₂- chelating activity up to 70%²⁵. These results were observed also by El Haliem²⁶ who decided that long term use of ASP made alterations in the axis between pituitary and thyroid glands, but anisum oil lower bad effect that caused by long term use of ASP.

CONCLUSION

In conclusion, the cerebellar cortex could be a target for ASP histopathological structural induced alterations that might form several diseases affecting nervous tissue. Fortunately, Anisum oil is suggested to play protective effect against such ASP-induced changes.

Conflict of interest: The authors declared that there are no conflicts of interest.

REFERENCES

1. Trocho C, Rafecas I, Pardo R, et al. Formaldehyde which derived from aspartame binds to the tissue components in vivo. *Life Sci* 1998; 63: 337–49.
2. Soffritti M, Degli Esposti D, Belpoggi F, et al. The first experimental exploration of the carcinogenic multipotential effects of aspartame use in the feed to the Sprague-Dawley rats. *Environ Health Perspect* 2006;114: 379–85.
3. Olney JW, Spitznagel E, Farber NB, et al. Brain tumor increasing in rates: Is there a link to use of aspartame? *J Neuropathol Exp Neurol* 1996;55: 1115–23.
4. Camfield PR, Camfield CS, Dooley JM, et al. Aspartame increase EEG spike wave in children complaining from generalized absence epilepsy: A double-blind controlled study. *Neurology* 1992;42: 1000–3.
5. El-Haliem NGA, Mohamed DS. Effect of aspartame on histological structure of liver and renal cortex of male albino rat and possible protective role of Anisum oil. *Egypt J Histol* 2011;34: 715–26.
6. Moser RH. Aspartame and loss of memory. *JAMA* 1994;272: 1543.
7. Van Eeden SK, Koepsell TD, et al. Aspartame intake and headaches: A randomized trial. *Neurology* 1994;44: 1787–93.
8. Benchaar C, Calsamiglia S, Chaves AV, et al. A review of the plant-derived essential oils in the ruminant production and nutrition. *Anim Feed Sci Technol* 2008;145: 209–28.
9. Kucukkurt G, Eryavuz I, Avci A, et al. Uyarlar role of supplementation of the aniseed (Anisum L.) in various amounts lipid to diets on antioxidant, peroxidation activity and also some parameters in laying quails (*Coturnix coturnix japonica*) Kocatepe. *Vet J* 2009;2: 1–5.
10. Gulcin U, Kirecci E, Oktay M, Kufrevioglu U. Screening of antimicrobial and antioxidant activities of anise (Anisum oil) extracts. *Food Chem* 2003;83: 371–82.
11. Aboabراهيم Z. and Zakhirah kharazmshahi, vol. 2. Tehran: National Works Publications, 1970; p141.
12. Lershin BI. Experimental therapy of hepatitis. *Patol Fiziol Eksp Ter* 1972;16: 66–7.
13. Fernstrom JD. Plasma phenylalanine and Oral aspartame: Pharmacokinetic difference between man and rodents and relevance to CNS effects of the phenylalanine. Short note. *J Neural Transm* 1989;75: 159–64.
14. Hjelle JJ, Marietta MP, Dudley RE, et al. pharmacokinetics and Plasma concentrations of phenylalanine in rats and mice under aspartame administered. *Pharmacology* 1992;44: 48–60.
15. Hegazy R and Hegazy A. Hegazy' Method of Tissue Processing (Consuming Less Time and Chemicals). *Annals of International Medical and Dental Research*. 2015; 1(2):57- 61”.
16. Hayat MR. Techniques for transmission electron microscopy. Academic Press Inc., Florida. 2000; p31.
17. Christian B, Bethea E, McConnaughey K, et al. Chronic aspartame affects T-maze performance, cholinergic receptors and Na⁺, K⁺-ATPase in rats. *Pharmacol Biochem Behav* 2004;78: 121–7
18. Abd El-Samad AA. Light and electron microscopic study on the effect of aspartame on the cerebellar cortex of male albino rat. *Egypt J Histol* 2010;33: 419–30.
19. Magnuson BA, Doull J, Burdock GA, et al. Aspartame: Evaluation based on use levels, regulations, toxicological and epidemiological studies. *Crit Rev Toxicol* 2007;37: 629–727.
20. Gartner LP, Hiatt JL. Textbook of histology, 2nd ed. Baltimore: Lippincott Williams & Wilkins; 2001.
21. Alleva R, Santarelli L, Borghi B, et al. In vitro effect of aspartame in the angiogenesis induction. *Toxicol In Vitro* 2011; 25: 286–93.
22. Beal MF, Koroshetz W, Hyman BT. Do defects of mitochondrial energy metabolism underlie the pathology of neurodegenerative diseases? *Trends Neurosci* 1993;16: 125–31.
23. Rezin GT, Goncalves CL, Cardoso MR, et al. Inhibition of respiratory chain of mitochondria in brain of rats subjected to depression. *Neurochem Int* 2008;53: 395–400.
24. Felts PA, Smith, KJ, Baker TA. Conduction in demyelinated mammalian central axons. *J Neurosci* 1997;17: 7267–77.
25. Elsn KS. Radical scavenging and chelating activities of some greens used traditional dishes in Mediterranean diet. *Int J Food Sci Nutr* 2004;55: 67–74.
26. El-Haliem NGA. Effect of aspartame on pituitary thyroid axis of adult male albino rat and possible protective role of Anisum oil: Histological study. *Egypt J Histol* 2013;36: 195–205.