

Role of ABER Positioning in Evaluation of Antero-inferior Labro-ligamentous Lesions in Shoulder MR Arthrograms

Ahmed A. Wahdan^{1*}, Mohamed Refaat¹, Laila El Kady¹, and Sherif Sokar²

¹Radiology Department, and ²Orthopedics Surgery Department, Suez Canal University Hospital, Faculty of Medicine, Suez Canal University, Egypt

Abstract

Background: MR arthrography in the abduction and external rotation (ABER) position has been demonstrated to enhance the diagnostic ratio of anterior labro-ligamentous complex tears. Meanwhile, the diagnostic and discriminatory rates of MR arthrography in this position in various types of the antero-inferior labro-ligamentous lesions have not been completely discovered. **Aim:** This study aimed to perform comparison between ABER MR and the conventional MR arthrography considering the diagnostic rate and discriminatory precision of various antero-inferior labro-ligamentous lesions. **Methods:** We studied 38 patients who suffered from shoulder conditions and evaluated the results of both conventional MR and ABER MR arthrography. An antero-inferior labro-ligamentous lesion was diagnosed with the detection of absence, fray, detachment, displacement of the antero-inferior labrum or detection of the contrast material inside the labrum, or avulsion, rupture of the inferior glenohumeral ligament at the humeral or labral attachment. All study subjects have undergone shoulder arthroscopy after MR technique. **Results:** ABER MR arthrography was associated with significant increased accuracy and diagnostic sensitivity than that of conventional MR regarding the diagnostic rate of various types of the antero-inferior labro-ligamentous lesions ($p < 0.05$). **Conclusion:** Based on our results, ABER MR arthrography would add more value to the diagnosis if the conventional MR were doubtful in suspected antero-inferior labro-ligamentous complex injuries.

Keywords: MR arthrography; ABER position; Neutral position; antero-inferior labroligamentous lesions; anterior shoulder dislocation.

Introduction

Magnetic resonance imaging (MRI) is the gold standard diagnostic technique of most of the pathologic articular conditions of the shoulder. Especially, magnetic resonance arthrography (MRA) gives more accurate information than standard non-arthrographic MRI regarding the diagnosis of shoulder cartilaginous injury or labral tears⁽¹⁻⁴⁾. Anterior shoulder dislocation

usually causes injury of the antero-inferior labroligamentous complex as it is considered the most important preservative of the shoulder joint. In fact, many types of antero-inferior labro-ligamentous lesions (Bankart and Bankart modified) were demonstrated^(5,6). The proper diagnosis and categorization of these variants is necessary in the preoperative phase in order to determine the most suitable surgical treatment in addition to assessment of the

*Corresponding Author: drawahdan@gmail.com

post-operative scenario⁽⁷⁻⁹⁾. Neutral position MR arthrography has been described as the best technique for anteroinferior labro-ligamentous lesions diagnosis and has been broadly recognized clinically^(2,10,11). Nevertheless, it has been associated with missing some information regarding the diagnosis of certain mild or nondisplaced torn labrums. Therefore, ABER position added more valuable analytical information to the neutral position MR arthrography^(5,6,12). In particular, ABER MR arthrography applies stretchy strength to the anterior labro-ligamentous complex, thus augmenting its possibility to recognize mild injured labrums, hence it has been more capable of rising the diagnostic percentage of anteroinferior labro-ligamentous tears, particularly the specific subtype of Perthes lesion⁽¹³⁾. Nevertheless, the analytical and discriminative rates of ABER MR in other types of the antero-inferior labro-ligamentous injuries were not fully explored until now. We hypothesized that ABER MR would add more diagnostic rate regarding the detection and discrimination of all subtypes of the antero-inferior labro-ligamentous injuries. We aimed, therefore, to perform a retrospective comparison between ABER MR and conventional MR arthrography considering the detection ratio and discriminatory exactitude of different antero-inferior labro-ligamentous lesions.

Patients and Methodology

The study is a comparative type. We examined Patients with shoulder disorders who have been requested to perform MR-Arthrography and have been referred to MR-Unit of radiology department-Suez Canal University Hospital. This study was approved by Faculty of Medicine Suez Canal University ethics evaluation panel. Consents were obtained from study subjects.

Thirty-eight study subjects were subjected to retrospective evaluation by conventional MR and ABER MR arthrography. Shoulder arthroscopy was performed for all study subjects after MR technique.

Image evaluation

MR arthrography images were individually reviewed through Synapse PACS, FUJIFILM station, Japan) by one radiologist with 10 years of concentrated practice of musculoskeletal imaging and who was blinded to patients' data and arthroscopic findings. Conventional MR arthrography that was obtained in neutral position were assessed at the beginning. ABER results have been assessed after 14 days. The antero-inferior labro-ligamentous injury has been diagnosed with the detection of absence, fray, detachment, displacement of the antero-inferior labrum or detection of the contrast material inside the labrum, or avulsion, rupture of the inferior glenohumeral ligament at the humeral or labral attachment.

Statistical analysis

Statistical significance was assumed if P value was below 0.05. Comparison between both arthrography methods has not been adjusted for patient gender, age, or side of shoulder injury. The distribution of qualitative data was shown in frequencies and tested for statistical significance by chi square analysis. SPSS, version 14.0.2 for Windows was used.

Results

There was male predilection among our study population as male patients represented about 74% of our study population in comparison to female patients (26%) as detailed in Figure (1). The mean age of our study population was 32.5 years.

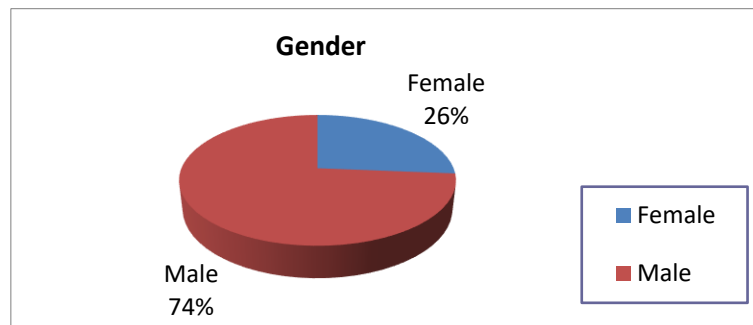


Figure 1: Gender Distribution among the Study Population

Regarding the examined site, there was much more right Sided patients rather than left sided (21/17), and more male patients than females (28/10). The frequency

of labral lesions by arthroscopy, it shows that 47% of our patients had soft tissue Bankart while 29% of them have osseous Bankart in the second position. Figure (2).

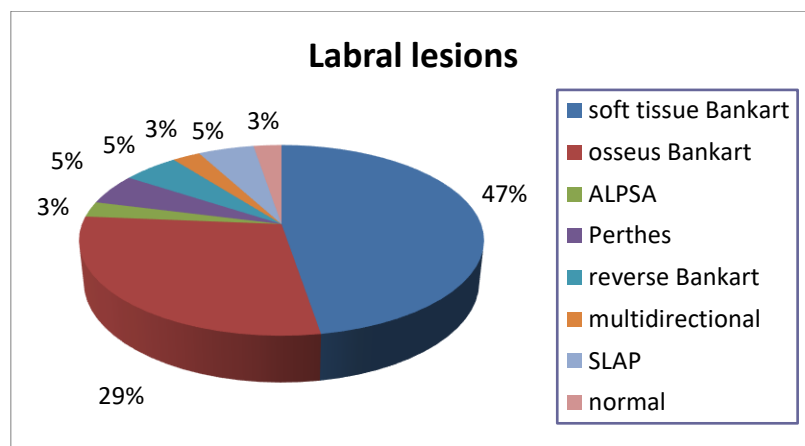


Figure 2: Frequency of Labral Lesions by Arthroscopy.

The results of ABER and conventional MR arthrography regarding the detection of antero-inferior labro-ligamentous injuries are shown in Tables (1 & 2). ABER MR arthrography has significantly increased accuracy (with 100% as combined technique to the neutral MRA), compared to that of conventional MR arthrography which showed 89.5% accuracy. The sensitivity of ABER and conventional MR arthrography in the detection of types of antero-inferior labro-ligamentous lesions are listed in Tables 1 & 2.

Discussion

In the present study, we performed a retrospective comparison between the diagnostic rate of ABER MR arthrography and the conventional neutral arthrography for antero-inferior labro-ligamentous injuries. We showed that ABER MR arthrography may significantly enhance the accuracy of antero-inferior labro-ligamentous lesions’ detection. In comparison to conventional MR arthrography, ABER MR arthrography may considerably increase the diagnostic accuracy of antero-inferior labro-ligamentous injuries with equivalent specificity in this study.

Table 1. Neutral MR Arthrogram findings in Diagnosis of Labral Lesions as Compared to Arthroscopic Findings.

Arthroscopy	Neutral MR arthrogram								
	Soft Bankart	Osseous Bankart	Reversed Bankart	Perthes	ALPSA	SLAP	Multi directional	N	Total
Soft Bankart	16	0	0	0	0	0	0	2	18
Osseous Bankart	1	10	0	0	0	0	0	0	11
Reversed Bankart	0	0	2	0	0	0	0	0	2
Perthes	0	0	0	2	0	0	0	0	2
ALPSA	0	0	0	0	0	0	0	1	1
SLAP	0	0	0	0	0	2	0	0	2
Multi directional	0	0	0	0	0	0	1	0	1
Normal	0	0	0	0	0	0	0	1	1
Total	17	10	2	2	0	2	1	4	38

Chi-square = 201.65; - P-value = 0.000 (highly significant); - Accuracy= 89.5% Sensitivity = 91.9%, Specificity = 100 %; Positive predictive value 100%; Negative predictive value 25%

In agreement with our results, It was reported that ABER arthrography revealed a diagnostic sensitivity of 96% and a specificity of 97% in comparison to neutral position MR arthrography which showed 48% sensitivity and 91% specificity ($P \sim 0.005$)⁽¹²⁾. Though, in another study, it was shown that there was a non-significant variation between ABER and conventional MR arthrography in terms of sensitivity and specificity⁽⁶⁾. This discrepancy could be due to distinct proportions of Perthes lesions (5.3% [2/38] in this study versus 7.6% [7/92]), as the most important advantage of ABER position is enhancing the diagnostic ratio of Perthes lesions⁽⁶⁾. ABER MR arthrography is able to strengthen the pressure of inferior glenohumeral ligament and may detect slight and non-displaced labral tears, that represents the base of successful diagnosis of Perthes lesions⁽¹³⁻¹⁵⁾. As far as we know, information about precision of MR arthrography for categorizing the

antero-inferior labro-ligamentous injuries was uncommon. A research that has been conducted on 104 confirmed patients, neutral MR arthrography was precise in detecting Bankart (80%, 35/44) and ALPSA injuries (77%, 17/22), though less precise in detecting Perthes lesions (50%, 6/12)⁽¹⁶⁾. Another 2 similar studies which included relatively small sampling size and involved patients with confirmed antero-inferior labro-ligamentous injuries (44 and 23 patients), ABER MR has been shown to be mildly inferior than neutral position concerning Bankart and ALPSA lesions, nonetheless somewhat more accurate regarding Perthes lesions^(6,17). Though, this study demonstrated sufficient precision of ABER MR in differentiation between different types of injuries. This position accuracy has reached 100%. This showed that the ability of MR arthrograms for categorizing the antero-inferior labro-ligamentous injuries could be trustworthy.

Table 1. ABER MR Arthrogram findings in Diagnosis of Labral Lesions as Compared to Arthroscop-ic Findings

Arthroscopy	Combined neutral & ABER MR arthrogram								
	Soft Bankart	Osseous Bankart	Reversed Bankart	Perthes	ALPSA	SLAP	Multi directional	N	Total
Soft Bankart	18	0	0	0	0	0	0	0	18
Osseous Bankart	0	11	0	0	0	0	0	0	11
Reversed Bankart	0	0	2	0	0	0	0	0	2
Perthes	0	0	0	2	0	0	0	0	2
ALPSA	0	0	0	0	1	0	0	0	1
SLAP	0	0	0	0	0	2	0	0	2
Multi directional	0	0	0	0	0	0	1	0	1
Normal	0	0	0	0	0	0	0	1	1
Total	18	11	2	2	1	2	1	1	38

Chi-square = 266; - P-value = 0.000 (highly significant), Accuracy= 100%

Conclusion

MR arthrography in ABER position, in comparison to arthroscopy, can significantly improve the diagnostic sensitivity of antero-inferior labro-ligamentous complex tears. Thus, we recommend that ABER MR is preferred to be included in case of doubtful conventional MR especially in suspected antero-inferior labro-ligamentous complex injuries.

References

1. Wagner SC, Schweitzer ME, Morrison WB, Fenlin Jr JM, Bartolozzi AR. Shoulder instability: accuracy of MR imaging performed after surgery in depicting recurrent injury—initial findings. *Radiology*. 2002;222(1):196–203.
2. Magee T, Williams D, Mani N. Shoulder MR arthrography: which patient group benefits most? *Am J Roentgenol*. 2004;183(4):969–74.
3. Major NM, Browne J, Domzalski T, Cothran RL, Helms CA. Evaluation of the glenoid labrum with 3-T MRI: is intraarticular contrast necessary? *Am J Roentgenol*. 2011;196(5):1139–44.
4. Flannigan B, Kursunoglu-Brahme S, Snyder S, Karzel R, Del Pizzo W, Resnick D. MR arthrography of the shoulder: comparison with conventional MR imaging. *AJR Am J Roentgenol*. 1990; 155(4):829–32.
5. Steinbach LS. MRI of shoulder instability. *Eur J Radiol*. 2008;68(1):57–71.
6. Schreinemachers SA, van der Hulst VPM, Willems WJ, Bipat S, van der Woude H-J. Is a single direct MR arthrography series in ABER position as accurate in detecting anteroinferior labroligamentous lesions as conventional MR arthrography? *Skeletal Radiol*. 2009;38(7):675–83.
7. Farber JM, Buckwalter KA. Sports-related injuries of the shoulder: instability. *Radiol Clin*. 2002;40(2):235–49.
8. Neviasser TJ. The anterior labroligamentous periosteal sleeve avulsion lesion: a cause of anterior instability of the shoulder. *Arthrosc J Arthrosc Relat Surg*. 1993;9(1):17–21.
9. Antonio GE, Griffith JF, Yu AB, Yung PSH, Chan KM, Ahuja AT. First-time shoulder dislocation: High prevalence

- of labral injury and age-related differences revealed by MR arthrography. *J Magn Reson Imaging An Off J Int Soc Magn Reson Med.* 2007;26(4):983–91.
10. Roger B, Skaf A, Hooper AW, Lektrakul N, Yeh L, Resnick D. Imaging findings in the dominant shoulder of throwing athletes: comparison of radiography, arthrography, CT arthrography, and MR arthrography with arthroscopic correlation. *AJR Am J Roentgenol.* 1999;172(5):1371–80.
 11. Chandnani VP, Yeager TD, DeBerardino T, Christensen K, Gagliardi JA, Heitz DR, et al. Glenoid labral tears: prospective evaluation with MRI imaging, MR arthrography, and CT arthrography. *AJR Am J Roentgenol.* 1993; 161(6): 1229–35.
 12. Cvitanic O, Tirman PF, Feller JF, Bost FW, Minter J, Carroll KW. Using abduction and external rotation of the shoulder to increase the sensitivity of MR arthrography in revealing tears of the anterior glenoid labrum. *AJR Am J Roentgenol.* 1997;169(3):837–44.
 13. Wischer TK, Bredella MA, Genant HK, Stoller DW, Bost FW, Tirman PFJ. Perthes lesion (a variant of the Bankart lesion) MR imaging and MR arthrographic findings with surgical correlation. *Am J Roentgenol.* 2002;178(1):233–7.
 14. Saleem AM, Lee JK, Novak LM. Usefulness of the abduction and external rotation views in shoulder MR arthrography. *Am J Roentgenol.* 2008;191(4):1024–30.
 15. Choi J-A, Suh S, Kim BH, Cha SH, Kim MG, Lee KY, et al. Comparison between conventional MR arthrography and abduction and external rotation MR arthrography in revealing tears of the antero-inferior glenoid labrum. *Korean J Radiol.* 2001;2(4):216.
 16. Waldt S, Burkart A, Imhoff AB, Bruegel M, Rummeny EJ, Woertler K. Anterior shoulder instability: accuracy of MR arthrography in the classification of anteroinferior labroligamentous injuries. *Radiology.* 2005;237(2):578–83.
 17. Song H, Huh Y, Kim S, Lee SA, Kim S, Shin K, et al. Anterior–inferior labral lesions of recurrent shoulder dislocation evaluated by MR arthrography in an adduction internal rotation (ADIR) position. *J Magn Reson Imaging An Off J Int Soc Magn Reson Med.* 2006; 23(1):29–35.