

IJMA

INTERNATIONAL JOURNAL OF MEDICAL ARTS



Volume 3, Issue 3 [Summer (July-September) 2021]



J-Gate
INDEX

<http://ijma.journals.ekb.eg/>

Print ISSN: 2636-4174

Online ISSN: 2682-3780

About IJMA [last updated July, 1st, 2021]

- ✓ International Journal of Medical Arts is the Official Journal of the Damietta Faculty of Medicine, Al-Azhar University, Egypt
- ✓ It is an International, Open Access, Double-blind, Peer-reviewed Journal
- ✓ Published four times a year
- ✓ The First Issue was published in July 2019
- ✓ Published under the following license: Creative Commons Attribution-ShareAlike 4.0 International Public License (CC BY-SA 4.0). It had updated from the Creative Commons license [CC BY] in volume 2, Issue 4, October 2020 About IJMA
- ✓ The Egyptian Knowledge Bank hosts the web site of IJMA
- ✓ The Egyptian Knowledge Bank supports IJMA
- ✓ IJMA follows the regulations of the International Committee of Medical Journal Editors
- ✓ IJMA is indexed in the "Directory of Open Access Journals" [15 January 2021].
- ✓ IJMA is indexed in JGate [29-6-2021]
- ✓ IJMA is a member of the International Society of Managing and Technical Editors
- ✓ Listed in "Index Copernicus", "Publons", "Academic resource index [ResearchBib]", "Electronics journal library", "Eurasian Scientific Journal Index", and "Citefactor"
- ✓ IJMA introduced to the search engine [BASE] through DOAJ

Click image to reach the page



Egyptian Knowledge Bank

DOAJ



INDEX COPERNICUS
INTERNATIONAL



ESJI Eurasian Scientific Journal Index
www.ESJIndex.org





Available online at Journal Website
<https://ijma.journals.ekb.eg/>
Main subject [Cardiothoracic Surgery]*



Original Article

Role for Video-Assisted Thoracoscopy in Undiagnosed Pleural Effusion: An Audit to Represent our Clinical Experience?

Zakaria Mostafa Almashtouly, Ismail Nasr El-Sokkary, Ibrahim Zaki

Department of Cardiothoracic Surgery, Faculty of Medicine, Al-Azhar University, Egypt.

Corresponding author: Ibrahim Zaki

Email: IZ.cardiothoracic@gmail.com

Submission date: February 10, 2021; Revision date: May 20, 2021; Acceptance date: May 31, 2021



DOAJ

DOI: [10.21608/ijma.2021.174079](https://doi.org/10.21608/ijma.2021.174079)

ABSTRACT

Background: Undiagnosed pleural effusion represents a health challenge. To discover possible causes, there were a number of invasive and non-invasive modalities. Each modality had its own accuracy.

The aim of the work: The current work aimed to evaluate the role of video-assisted thoracoscopy [VATS] in the undiagnosed indeterminate pleural effusion.

Materials and Methods: The current work included forty patients with undiagnosed indeterminate pleural effusion. All underwent preoperative assessment [history, physical examination, laboratory and radiological investigation]. Then, all submitted to VATS, pleurocentesis had been completed, and pleural aspirates were sent for culture and sensitivity. Also, the aspirate was subjected to biochemical investigation]. Operative data related to VATS included time of the whole procedure, intraoperative complications, amount of drained pleural fluid, the ability to obtain multiple biopsies, field exposure and degree of lung expansion. The visual analogue scale [VAS] was used to assess postoperative pain. Any postoperative complications were documented.

Results: The mean operative time was 54.37 ± 7.63 minutes, and no intraoperative complications had been recorded. The field exposure was adequate among the majority [77.5%]. The VATS was able to provide a diagnosis for all studied patients. The mean duration of hospital stay was 5.90 ± 1.53 days; the mean chest tube duration was 5.65 ± 1.27 days. Finally, recurrent effusion was reported in 7 patients [17.5%] [5 males and two females]. All patients need postoperative analgesia with great variability and postoperative pain showed significant variance across time [during the first 24 hours]. 60% need no further intervention, while 32.5% need pleurodesis, and 7.5% need decortication. Malignant effusion was reported in 9 patients [22.5%].

Conclusions: VATS as a diagnostic and therapeutic tool for undiagnosed pleural effusions, is an effective and safe intervention. Thus, it is advocated to be used as the standard and first intervention in such patients.

Keywords: Video Assisted; Effusion; Pleura; Exudate; Thoracoscopy.

This is an open-access article registered under the Creative Commons, ShareAlike 4.0 International license [CC BY-SA 4.0] [<https://creativecommons.org/licenses/by-sa/4.0/legalcode>].

Citation: Almashtouly ZM, El-Sokkary IN, Zaki I. Role for Video-Assisted Thoracoscopy in Undiagnosed Pleural Effusion; An Audit to Represent our Clinical Experience. IJMA 2021; 3 [3] July-September: 1516-1524. [DOI: [10.21608/ijma.2021.174079](https://doi.org/10.21608/ijma.2021.174079)].

* Main subject and any subcategories have been classified according to the research topic.

INTRODUCTION

Pleural effusion is a ubiquitous medical presentation for a range of potentially underlying severe diseases [1,2]. Pleural effusion represented a worldwide common etiology of morbidity; its incidence varies depending on the studied population, with diverse etiologies. Pleural effusions can arise from the pleura or extrapleural diseases. More than 90.0% of all effusions in the developed countries are caused by congestive heart failure [CHF], malignancy, pneumonia, and pulmonary embolism [3].

Also, tuberculosis [TB] is a common cause of pleural effusions in endemic areas. The wide diversity of potential causes and different clinical manifestations of benign pleural effusion makes the challenge for its diagnosis [4].

The approach to diagnose pleural effusions' etiology mainly based on clinical evaluation, imaging studies, pleural fluid analysis, and applicable pleural biopsy [5]. However, 30 to 40% of pleural effusions remain undiagnosed, even after extensive investigations [6].

Diagnosis of an unexplained pleural effusion is one of the critical challenges in pleural disease. The particular concern is of underlying malignancy, which is essential to diagnose as it will impact survival time and treatment options [7]. Pleural biopsy is indicated when the less invasive diagnostic methods have not yielded a diagnosis. The pleural biopsy may be blinded, image-guided, or thoracoscopic. The latter two have largely replaced blind biopsy owing to their greater sensitivity and safety profile. Blind needle parietal pleural is positive for malignancy in around 45%, lower than pleural fluid cytology. This low sensitivity is due to most of the malignant pleural deposits being scattered and occurring primarily along the diaphragmatic pleura and midline, locations that are inaccessible by the needle. Conversely, tuberculous granulomata are much more homogeneously distributed over the pleura, resulting in the higher sensitivity [$>80.0\%$] of this biopsy modality for tuberculosis [8].

CT-guided cutting needle biopsy is the preferred diagnostic method whenever pleural thickening and/or

nodule, particularly if $>1\text{cm}$, exist and malignancy is suspected [sensitivity $> 85.0\%$] [9, 10].

Thoracoscopy permits direct visualization of the pleural surface. It permits biopsy of areas that appear abnormal and therapeutic maneuvers such as complete fluid drainage and talc pleurodesis during the same procedure [5]. Thoracoscopy is able to establish the diagnosis of either malignancy or tuberculosis in nearly 100% of cases [11]. Thoraco-scopy should be performed when less invasive procedures are non-diagnostic. If thoracoscopy is performed for an undiagnosed pleural effusion, a procedure should be performed to create pleurodesis at the time of the thoracoscopy [therapeutic intervention] [1, 12].

AIM OF THE STUDY

This study aimed to evaluate the role of video-assisted thoracoscopy [VATS] in undiagnosed indeterminate pleural effusion regarding diagnosis and management.

PATIENTS AND METHODS

Forty patients with undiagnosed indeterminate pleural effusion were included. They were selected from Al-Azhar University Hospitals. The study duration extended between 2015 and 2019. The exclusion criteria were: patient refusal, patient younger than 18 years of age, bad general condition or any contraindications for general anesthesia, and any contraindications for VATS, for example, frozen chest or severe chronic obstructive pulmonary disease.

Ethical considerations: The study protocol had been investigated and approved by the local research and ethics committee [Institutional Review Board] of Damietta Faculty of Medicine. Besides, informed consent had been signed by each participant. The research and dealing with data were completed according to ethics code of conduct, Declaration of Helsinki.

All patients were submitted to preoperative assessment. It included history taking, physical examination, laboratory investigations, radiological examinations, and pleural fluid aspiration and analysis. Then, all underwent VATS. In more detail, the preoperative history taking included personal data, any

associated medical comorbid conditions, past and family history. Clinically, patients were examined systematically for their general condition, vital data, review of all body systems, and detailed local examination of the chest as described in the literature. The Laboratory work included complete blood picture, kidney function tests, liver functions tests, serum lactate dehydrogenase, and serum proteins. All these Lab investigations were completed as a part of routine preoperative work in the university hospital. Radiologically, all patients had a plain chest X-ray [two views; posteroanterior and lateral views] and computed tomography of the chest. Finally, electrocardiography had been performed for all participants. Yet, pleurocentesis had been completed, and pleural aspirate was submitted to culture and sensitivity, biochemistry, cholesterol, triglycerides, and cytology]

The technique of VATS:

The procedure had been explained for each participant before he/she signed the informed consent. Any potential complications were explained, and the final decision had been achieved by the patient independently. When they arrived to the operation theatre, all patients were instructed to lie in the supine position at first. A multi-channel monitor [Trakmon kontron limited - England] was attached to the patient to monitor the following data in a continuous manner [ECG, heart rate [HR], mean arterial blood pressure [MAP], and arterial oxygen saturation [SaO₂]. All patients completed the procedure under general anesthesia. Then, a single lumen endo-tracheal tube was inserted with the use of low tidal volumes and jet mechanical ventilation throughout the surgery. Then, patients were placed in the lateral decubitus position with the involved side upwards. The chest was prepared and draped as for thoracotomy.

After skin disinfection, the fourth-sixth intercostal spaces in the midaxillary line were marked as the standard entry points, as they provided an optimum overview of the pleural cavity. Other ports were designed according to each patient and pathology discovered in CT-Chest. Then, careful entry of the chest was achieved through a two-centimeter stab incision in the fifth intercostal space at the midaxillary line for the camera; digital palpation had determined the presence of adhesions and bleeders from the

wound were investigated, discovered, and controlled. An 11 mms' trocar was inserted through the incision, through which the 10 mm rigid telescope was inserted carefully to avoid uncontrolled deep penetration. Another one cm stab incision was made in the fifth intercostal space at the anterior axillary line for the instrument used to take the biopsy. Then evacuation of the entire fluid collection was done, and ipsilateral pneumothorax was created. The introduction of the telescope was done to explore the whole pleural cavity by a video camera that was attached to the rigid telescope through the eyepiece. Images were projected on a video monitor and were documented in the patient's files. Biopsies were generally taken from the suspicious areas; copious and multiple biopsies were taken for histopathological examination with an optional blunt dissection instrument for breaking impeding adhesions, septae, and membranes. The ipsilateral chest tube was then inserted, and closure of the incision was performed.

Postoperative assessment:

At the post-operative period, the pain was assessed by the use of the visual analogue scale [VAS], a subjective method to evaluate the severity of pain. It is a scale from 0 [no pain] and 10 [the worst even pain]. All patients had preoperative instructions on the evaluation of their pain by VAS. All patients had received fixed schedule analgesia in the form of ibuprofen 400 mg tablets/4 times a day. The assessment of pain severity had been carried out each hour till the score become ≥ 4 . Then, rescue analgesic medication was given in the form of intravenous ketorolac 0.75 mg/kg and/or IV Nalbuphin 10 mg according to the severity of pain.

Collected data: The collected operative data included: ability of VATS to reach a diagnosis, the time for the whole VATS, any intraoperative complications, amount of drained pleural fluid, the ability to obtain multiple biopsies, field exposure and degree of lung expansion. The postoperative data included postoperative pain score, need for analgesia, duration of hospital stay, amount of fluid in drain and its rate, the duration of intercostal chest tube, recurrence rate of pleural effusion, need for further intervention, and final diagnosis.

Statistical analysis of data: The collected data was represented in suitable formats [mean, standard deviation, minimum and maximum for numerical variables, frequency, and percent distribution for categorical variables]. To compare between groups, appropriate statistical tests were used [for example, Chi-square, Fisher exact test and, independent samples t-test for categorical and numerical variables]. Besides, a repeated ANOVA test was used for the postoperative pain. P-value < 0.05 was considered statistically significant.

RESULTS

In the current study, forty subjects with pleural effusion were included. They were 23 males [57.5%] and 17 females [42.5%]. Their age ranged between 35 to 67 years; the mean age was 52.90±7.24 years. The subject's weight ranged between 67 to 87 kilograms, while their height ranged between 163 to 177 cm. In addition, smoking was reported among 12 patients [30.0%]; all were males. Thirty-three patients [57.3%] complained of dyspnea, and 15 patients [37.5%] complained of chest pain. There was no significant difference between males and females as regards patient characteristics or their complaint. However, smoking was confined to male subjects with a significant increase in males compared to females [52.2% vs. 0.0% respectively] [Table 1].

Operative time ranged between 43 and 75 minutes; the mean operative time was 54.37±7.63 minutes, and there was no significant difference between males and females [53.69±6.86 vs. 55.29±8.70, respectively, p = 0.52]. There were no intraoperative complications either for males or females. The amount of drained fluid intra-operatively ranged from 750 to 2500 ml. The mean value was 1611.25±443.83, and there was no significant difference between males and females [p =0.94]. The number of biopsies obtained from each patient ranged between 2 and 4, with a mean value of 2.67±0.65; there was no significant difference between males and females [p=0.09]. The field exposure was extensively limited among one patient [2.5%], while it was partially limited among eight patients [20.0%], and it was adequate [not limited] among the majority of our patients [31 patients; 77.5%]. There was no relation between patient gender and field exposure [p=0.32].

The VATS was able to provide a diagnosis for all studied patients [Data not tabulated].

There was a significant increase of leucocytes and lactate dehydrogenase in males in the current work compared to females. Otherwise, there was no significant difference regarding other fluid characteristics as pH, glucose, and proteins. The duration of hospital stays [days] ranged between 3 and 9 days; the mean duration was 5.90±1.53 days; while the mean drainage/day ranged between 200 and 900 ml, the mean value was 483.75±174.60 ml; the chest tube duration ranged between 3 to 8 days, the mean duration was 5.65±1.27 days. Finally, recurrent effusion was reported in 7 patients [17.5%] [5 males and two females], and the time at which recurrence occur was between the second and sixth weeks postoperatively. No significant difference was found between males and females [Table 2].

Regarding the need for postoperative analgesia, all patients need it. However, nine patients [22.5%] need only single oral analgesic drug; while 20 patients [50.0%] need two drugs [one oral and one intravenous] and 11 patients [27.5%] need three drugs [one oral and two intravenous drugs]; no significant difference was reported between males and females [p = 0.24].

In the current work, postoperative pain showed significant variance across time [during the first 24 hours], where basal values were lower than increased at the fourth postoperative hour, then decreased slightly with the administration of analgesia on request, showed a slight increase [its maximum values] at 16 hours, then dropped progressively till the end of the first day. However, no significant difference was observed between males and females at any time [Figure 1].

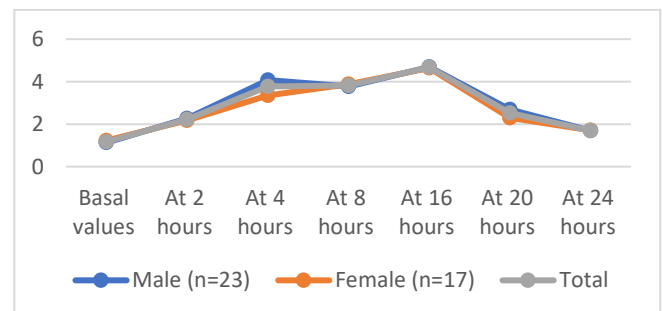


Figure [1]: Postoperative VAS among studied populations

Regarding final diagnosis, it was metastatic effusion in 7 patients [17.5%], chronic non-specific inflammation among the majority of patients [21 subject; 52.5%], suppurative effusion in 5 patients [12.5%], tuberculous effusion among other 5 patients [12.5%] and effusion due to primary malignant tumor in 2 patients [5.0%]. There was a significant increase of metastatic and tuberculous effusion in males when compared to females [30.4%, 17.4% vs. 0.0% and 5.9%, respectively]; while chronic nonspecific inflammation, suppurative effusion, and effusion due to the primary malignant tumor were significantly lower in males when compared to females [table 3].

Regarding the need for further intervention, 60.0% of our patients need no intervention, while 32.5% need

pleurodesis, and 7.5% need decortication. There was significant increase of those needed pleurodesis and decortication [further intervention] among males than females [43.5% and 13.0% vs 17.6% and 0.0% respectively] [p= 0.035]. Malignant effusion, either due to the primary or metastatic tumor, was reported in 9 patients [22.5%], and there was no significant difference between males and females [30.4% vs. 11.8% respectively, p= 0.16]. Patients with malignant effusion had significantly higher lactate dehydrogenase values than patients with non-malignant effusion [519.55±33.49 vs. 311.64±54.73, respectively]. Otherwise, no difference was reported between both groups regards other variables [Table 4]

Table [1]: Patient’s characteristics and complaints among studied populations

	Male [n=23; 57.5%]	Female [n=17; 42.5%]	Total	Test	P
Age [years]	53.47±8.28	52.11±5.67	52.90±7.24	0.58	0.56
Weight [kg]	76.65±4.73	75.41±4.24	76.12±4.51	0.85	0.39
Height [m]	1.7117±0.0279	1.669±0.0156	1.706±0.024	1.63	0.11
BMI[kg/m ²]	26.14±1.19	26.10±1.22	26.12±1.9	0.11	0.99
Smoking	12[52.2%]	0[0.0%]	12[30.0%]	12.67	<0.001*
Dyspnea	12[52.2%]	11[64.7%]	23[57.3%]	0.62	0.42
Chest pain	8[34.8%]	7[41.2%]	15[37.5%]	0.17	0.68

Table [2]: Analysis of fluid and postoperative data among studied populations

	Male		Female		Total		Test	p
	Mean	S. D	Mean	S. D	Mean	S. D		
pH	7.409	.012	7.412	.016	7.410	.014	0.347	0.559
Glucose [mg/dl]	117.783	4.317	117.235	4.590	117.550	4.385	0.149	0.702
Proteins [g/L]	45.130	4.362	44.824	3.468	45.000	3.961	0.057	0.812
Leucocytesx10 ⁹ /L	1607.043	119.951	1716.882	167.116	1653.725	150.326	5.870	0.020*
LDH [IU/L]	387.913	91.332	318.529	103.012	358.425	101.318	5.061	0.030*
Hospital stay	5.91	1.75	5.88	1.21	5.90	1.53	0.06	0.95
Drainage/day [ml]	483.47	180.29	484.11	172.08	483.75	174.60	0.001	0.99
CT duration [days]	5.65	1.49	5.64	0.93	5.65	1.27	0.001	0.99
Recurrence	5[21.7%]		2[11.8%]		7[17.5%]		0.67	0.41
Time to recurrence [week]	3.80	0.83	4.00	2.82	3.85	1.34	0.16	0.87

Table [3]: Final diagnosis among studied populations

		Sex				Total	
		Male		Female			
		n	%	n	%	n	%
Final diagnosis	Metastatic effusion	7	30.4%	0	0.0%	7	17.5%
	Chronic non-specific inflammatory	10	43.5%	11	64.7%	21	52.5%
	suppurative	2	8.7%	3	17.6%	5	12.5%
	Tuberculous	4	17.4%	1	5.9%	5	12.5%
	Malignant Primary tumor	0	0.0%	2	11.8%	2	5.0%
Statistics		X ² = 10.38, p = 0.034*					

Table [4]: Comparison between malignant and non-malignant effusion regarding chemical analysis

	Malignant		Non-Malignant		Test	p
	Mean	SD	Mean	SD		
pH	7.40	0.015	7.41	0.013	2.093	0.156
Glucose [mg/dl]	115.77	3.59	118.06	4.50	1.943	0.171
Proteins [g/L]	47.00	4.58	44.41	3.64	3.121	0.085
Leucocytes x 10 ⁹ /L	1670.00	203.28	1649.00	135.11	0.133	0.717
Lactate dehydrogenase [IU/L]	519.55	33.49	311.64	54.73	115.911	<0.001*

DISCUSSION

History, clinical examination, and pleural fluid analysis will reveal the diagnosis in most cases with pleural effusion. However, an estimated 26% of pleural effusions remain undiagnosed and warrant further work-up. Many of these undiagnosed effusions are exudative and are especially problematic in TB prevalence areas, more than half of these will be malignant [13,14]. Numerous invasive and non-invasive methods have been introduced for the diagnosis of thoracic diseases [15]. Video-assisted thoracoscopy is a minimally invasive technique with a minor morbidity and mortality risk for evaluating the pleural space by direct vision through small incisions. Direct visual inspection of the pleural space, drainage of pleural fluid, and taking a sufficient biopsy for pathologic evaluation is the commonly performed procedures during video-assisted thoracoscopy, which may be performed under general or even local anesthesia in particular situations. At the same time, pleurodesis and decortications may be done during this procedure to prevent recurrence of the effusion and resolution of dyspnea [1].

This study aimed to evaluate the efficacy of Video-Assisted Thoracoscopy [VATS] in the diagnosis of undiagnosed pleural effusion. It included forty patients, and results revealed VATS's ability to reach a diagnosis in all included patients. The final diagnosis was metastatic effusion in 7 patients [17.5%], chronic non-specific inflammation among the majority of patients [21 subject; 52.5%], suppurative effusion in 5 patients [12.5%], tuberculous effusion among other 5 patients [12.5%] and effusion due to primary malignant tumor in 2 patients [5.0%]. There was a significant increase of metastatic and tuberculous effusion in males when compared to females [30.4%, 17.4% vs. 0.0% and 5.9%, respectively]; while chronic nonspecific inflammation, suppurative effusion, and effusion due to the primary malignant tumor were

significantly lower in males when compared to females. Also, no complications were reported either in intra-operative or postoperative durations. Our results are comparable to results obtained by Arkin *et al.* [16] who reported that their results showed that VATS was a highly sensitive and accurate method in the diagnosis of exudative pleural effusion undiagnosed by other methods, as it had a diagnostic accuracy of over 98%. In addition, many previous studies reported that VATS achieved a diagnostic rate of above 95% in pleural effusion [7,17]. The high success rate of VATS in the diagnosis of PE may be attributed to its ability to examine the entire pleural cavity and to allow multiple tissue sampling in large numbers under visual inspection [18]. However, some patients with PE are diagnosed as nonspecific pleuritis, and the etiology remains unclear even after a thoracoscopic biopsy [19]. The main diagnostic significance of thoracoscopy in this patient group is the exclusion of malignancy and TB [16].

As VATS is performed under general anesthesia in a lateral decubitus position, single-lung ventilation with the collapse of the ipsilateral lung is performed and provides an exploration of the thoracic cavity during the maneuver and permits surgical instruments to move easily within the cavity. As such, adhesions can be handled easily [20]. This is another advantage of VATS and could be added to the explanation of its high success rate and diagnostic accuracy. Medford *et al.* [7] reported on the safety of VATS and stated that major complications had been reported in just 1.2% of patients, and no mortalities were recorded in an audit of one UK center. In the current work, no major complications were reported, nor mortality has occurred. Also, in patients with tuberculous pleural effusion, Wang *et al.* [21] concluded that thoracoscopy is a simple procedure with high diagnostic yield and excellent safety for the diagnosis of tuberculous pleural effusion. Also, Wan *et al.* [22] concluded that

thoracoscopy is generally a safe and effective method in the diagnosis of undiagnosed pleural effusions and the management of pleural diseases. Eldaboosy *et al.*^[23] reported that thoracoscopy gives the final diagnosis in 62 cases [87.3%] from a total of 71 patients [the current work gives a higher percentage]. The previous work reported lower diagnostic accuracy than the present study. This could be explained by different samples and continuous and progressive advancement of technology used in VATS over time.

Mootha *et al.*^[24] had evaluated the yield of thoracoscopic pleural biopsy for achieving a diagnosis in undiagnosed pleural effusions in 35 patients. The overall diagnostic yield of the thoracoscopic pleural biopsy was 74.3%. Pleural malignancy was reported in 48.6% of patients. There was only one case of mesothelioma, and the rest were due to pleural metastasis. Lung and breast cancer were the most common sites of the primary malignancy. TB was diagnosed with pleural biopsy in 22.8% of patients, and only two cases of empyema were observed. Patil *et al.*^[25] performed thoracoscopy in 129 cases of undiagnosed exudative pleural effusions. The overall diagnostic yield of the thoracoscopic biopsy was 110/129 [85.2%] in patients with undiagnosed pleural effusion, and 19/129 [14.8%] remained unexplained. Histopathological diagnosis confirmed malignancy in 66.4% of patients [both primary and metastatic pleural carcinoma], TB in 28.2%, others including parapneumonic effusion in 4 cases followed by multiple myeloma, lupus pleuritis, and pulmonary Langerhans cell histiocytosis in one case each. They had allocated 18 cases that had chronic nonspecific inflammation on pleural biopsy to the undiagnosed group since they could not initiate any specific treatment except keeping these patients under observation. On the other side and in agreement with the current study, Blanc *et al.*^[26] reported that the diagnostic efficiency of medical thoracoscopy was [93.3%].

In the current work, the most common diagnosis was chronic nonspecific inflammation, and these results do not agree with Eldaboosy *et al.*^[23], who reported that the most common diagnosis was malignancy in 52 cases [83.8%] then TB pleurisy in 10 patients [16.2%]. Malignant mesothelioma reported in 39 cases [54.9%], malignant adenocarcinoma, and TB pleurisy in 10 cases [14.1%] for each, non-Hodgkin's

lymphoma in 2 cases [2.8%], and lastly, malignant melanoma in one case [1.4%]. Thoracoscopy is much more important in such situations where malignancy is more probable than in the developed countries. Indeed, in developed countries where the incidence of tuberculosis is low, more than 50% of the cases of undiagnosed pleural effusion are due to carcinomas, the second most common [10%] being tuberculosis. In developing countries [as Egypt], the incidence of TB [and TB pleurisy] is still high^[23].

Furthermore, and in line with the current study, Dadaş *et al.*^[27] concluded that VATS is not only a rapid and effective diagnostic method but also a palliative therapeutic method. We think that VATS should be used right after the diagnostic work conducted with initial thoracentesis in undiagnosed exudative PE in the less experienced centers so that a diagnosis can be obtained faster, and diagnostic delay can be avoided in malignant PE. Also, Wan *et al.*^[22] concluded that thoracoscopy is usually a safe and effective technique, not only in the diagnosis of undiagnosed pleural effusions but also in the management of pleural diseases.

Prabhu and Narasimhan^[28] had performed a study evaluating the role of pleuroscopy on 68 patients with undiagnosed pleural effusion and reported diagnostic accuracy of 97%. Malignancy was recognized in 24 patients, 22 patients had nonspecific inflammation, tuberculosis was found in 16 patients, empyema was found in 2 patients, one patient had sarcoidosis, one patient had normal pleura it was non-diagnostic in 2 patients. The possible causes for the variation in diagnostic accuracy obtained by VATS in different studies have been analyzed, and the important factors that contribute to this variation include para-malignant effusions, experience and skill of the surgeon, inadequate sampling [under looking of costovertebral gutter and diaphragm], pathological errors [not taking deeper cuts], the fibrinous necrotic layer covering the actual pathological area, and the presence of dense adhesions. Lastly, and to report on the efficacy of VATS against other diagnostic and therapeutic modalities, Janssen^[29] reviewed the efficacy of three different methods of pleural biopsy [an old technique using Abrams needle closed pleural biopsy, thoracoscopic biopsy, computed tomography-guided biopsy, and ultrasound-guided biopsy], showed that

thoracoscopy was of a sensitivity of 90-95% compared with other methods [40% to 85%]. He commented that although thoracoscopy is a more invasive procedure compared with image-guided pleural biopsy, the major advantage of thoracoscopy is its possibility to perform a simultaneous therapeutic intervention.

In the present study, thoracoscopy had allowed adequate pleural fluid drainage, generous multiple biopsies recruitment in 100% of patients, and adequate field exposure of patients, and these results are comparable to that reported by Mootha *et al.* [24], and Patil *et al.* [25]. No intraoperative procedure-related complications had been reported in all patients in the current study. However, Mootha *et al.* [24] also reported two cases of empyema as a complication of the procedure. In the research done by Prabhu and Narasimhan [28] only four patients had minor complications like subcutaneous emphysema [three patients] and prolonged air leak [one patient]. Patil *et al.* [25] reported minor complications [prolonged air leak [4.6%], self-limiting subcutaneous emphysema [3.9%], empyema [2.3%], tract malignancy [1.5%], and cardiac arrhythmia and hypotension in one case each [0.7%]].

In the present study, all patients had received postoperative analgesics for pain control. However, nine patients [22.5%] need only a single oral analgesic drug; while 20 patients [50.0%] need two medications [one oral and one intravenous], and 11 patients [27.5%] need three drugs [one oral and two intravenous drugs]; no significant difference was reported between males and females. Similarly, in the study done by Nagahiro *et al.* [30], Twenty-two patients underwent either a VATS approach or a posterolateral thoracotomy approach to carry out pulmonary lobectomy for peripheral lung cancers in clinical stage I. It was found that postoperative pain was significantly less in the VATS group on postoperative days 0, 1, 7, and 14 in comparison to the thoracotomy group. More recently, Kwon *et al.* [31] had also performed a study on 498 patients who underwent Robotic-Assisted Thoracoscopic Surgery [74], VATS [227], and reported that, there was a significant reduction in acute pain for patients with minimally invasive surgery.

Regarding the need for further intervention, 60.0% of our patients need no intervention, while 32.5% need pleurodesis, and 7.5% need decortication. There was

a significant increase in those needed pleurodesis and decortication [further intervention] among males than females [43.5% and 13.0% vs. 17.6% and 0.0% respectively]. However, Beheshtirouy *et al.* [32] performed additional procedures simultaneously in the same setting of thoracoscopy in all patients [as indicated], including removal of loculated pleural effusion [58%], decortication [54%], and chemical pleurodesis [42%] getting the advantage of doing therapeutic procedures through VATS.

In short, the current study provided additional proof of the safety and efficacy of VATS as a diagnostic and therapeutic tool for undiagnosed pleural effusions. Thus, it is encouraged to be adopted as the standard and first intervention in such patients. Also, mastering VATS well leads to improved patient management after the procedure and reduces potential post-procedural complications.

Financial and Non-Financial Relationships and Activities of Interest

None

REFERENCES

1. Jany B, Welte T. Pleural Effusion in Adults-Etiology, Diagnosis, and Treatment. *Dtsch Arztebl Int.* 2019 May 24; 116 [21]: 377-386. [DOI: 10.3238/arztebl.2019.0377].
2. Walker S, Bibby AC, Maskell NA. Current best practice in the evaluation and management of malignant pleural effusions. *Ther Adv Respir Dis.* 2017; 11[2]:105-114. [DOI: 10.1177/1753465816671697].
3. Skok K, Hladnik G, Grm A, Crnjac A. Malignant Pleural Effusion and Its Current Management: A Review. *Medicina [Kaunas].* 2019 Aug 15; 55[8]:490. [DOI: 10.3390/medicina55080490].
4. Antonangelo L, Faria CS, Sales RK. Tuberculous pleural effusion: diagnosis & management. *Expert Rev Respir Med.* 2019 Aug; 13[8]:747-759. [DOI: 10.1080/17476348.2019.1637737].
5. Beaudoin S, Gonzalez AV. Evaluation of the patient with pleural effusion. *CMAJ.* 2018 Mar 12; 190 [10]: E291-E295. [DOI: 10.1503/cmaj.170420].
6. Dixon G, de Fonseca D, Maskell N. Pleural controversies: image-guided biopsy vs. thoracoscopy for undiagnosed pleural effusions? *J Thorac Dis.* 2015 Jun; 7[6]:1041-51. [DOI: 10.3978/j.issn.2072-1439.2015.01.36].
7. Medford AR, Awan YM, Marchbank A, Rahamim J, Unsworth-White J, Pearson PJ. Diagnostic and therapeutic performance of video-assisted thoracoscopic surgery [VATS] in the investigation and management of pleural exudates. *Ann R Coll Surg Engl.* 2008 Oct; 90[7]:597-600. [DOI: 10.1308/003588408X318246].

8. Porcel JM. Chest Tube Drainage of the Pleural Space: A Concise Review for Pulmonologists. *Tuberc Respir Dis* [Seoul]. 2018; 81[2]:106-115. [DOI: 10.4046/trd.2017.0107].
9. Zhang Y, Tang J, Zhou X, Zhou D, Wang J, Tang Q. Ultrasound-guided pleural cutting needle biopsy: accuracy and factors influencing diagnostic yield. *J Thorac Dis*. 2018 Jun; 10[6]: 3244-3252. [DOI: 10.21037/jtd.2018.05.94].
10. Lin Z, Wu D, Wang J, Wang C, Huang M. Diagnostic value of ultrasound-guided needle biopsy in undiagnosed pleural effusions: A systematic review and meta-analysis. *Medicine* [Baltimore]. 2020 Jul 2; 99[27]: e21076. [DOI: 10.1097/MD.00000000000021076].
11. Casalini AG, Mori PA, Majori M, Anghinolfi M, Silini EM, Gnetti L, Motta F, Larini S, Montecchini S, Pisi R, Calderaro A. Pleural tuberculosis: medical thoracoscopy greatly increases the diagnostic accuracy. *ERJ Open Res*. 2018; 4[1]: 00046-2017. [DOI: 10.1183/23120541.00046-2017].
12. Shrestha BK, Adhikari S, Thakur BK, Kadaria D, Tamrakar KK, Devkota M. Medical Thoracoscopy for Undiagnosed Exudative Pleural Effusion: Experience from Two Tertiary Care Hospitals of Nepal. *JNMA J Nepal Med Assoc*. 2020 Mar; 58[223]:158-164. [DOI: 10.31729/jnma.4873].
13. Ali MS, Light RW, Maldonado F. Pleuroscopy or video-assisted thoracoscopic surgery for exudative pleural effusion: a comparative overview. *J Thorac Dis*. 2019 Jul; 11[7]: 3207-3216. [DOI: 10.21037/jtd.2019.03.86].
14. Kocatürk C, Kutluk AC, Usluer O, Onat S, Çınar HU, Yanık F, Cesur E, Ülkü R, Karamustafaoglu A, Çelik B, Demirhan R, Kalafat CE, Özpolat B. Comparison of awake and intubated video-assisted thoracoscopic surgery in the diagnosis of pleural diseases: A prospective multicenter randomized trial. *Turk Gogus Kalp Damar Cerrahisi Derg*. 2019; 27[4]: 550-556. [DOI: 10.5606/tgkdc.dergisi.2019.18214].
15. Alemán C, Sanchez L, Alegre J, Ruiz E, Vázquez A, Soriano T, Sarrapio J, Teixidor J, Andreu J, Felip E, Armadans L, Fernández De Sevilla T. Differentiating between malignant and idiopathic pleural effusions: the value of diagnostic procedures. *QJM*. 2007 Jun; 100[6]:351-9. [DOI: 10.1093/qjmed/hcm032].
16. Arkin FS, Kutluk AC, Gorgun D, Cansever L, Kocaturk C, Yildiz P, Bedirhan MA. The diagnostic role of video-assisted thoracoscopic surgery in exudative pleural effusion and follow-up results in patients with nonspecific pleuritis. *J Pak Med Assoc*. 2019 Aug; 69[8]:1103-1107. [PMID: 31431761].
17. Shah RD, D'Amico TA. Modern impact of video assisted thoracic surgery. *J Thorac Dis*. 2014 Oct; 6[Suppl 6]: S631-6. [DOI: 10.3978/j.issn.2072-1439.2014.08.02].
18. Murthy V, Bessich JL. Medical thoracoscopy and its evolving role in the diagnosis and treatment of pleural disease. *J Thorac Dis*. 2017 Sep; 9[Suppl 10]: S1011-S1021. [DOI: 10.21037/jtd.2017.06.37].
19. Vakili E, Ost D, Vial MR, Stewart J, Sarkiss MG, Morice RC, Casal RF, Eapen GA, Grosu HB. Nonspecific pleuritis in patients with active malignancy. *Respirology*. 2018 Feb; 23 [2]: 213-219. [DOI: 10.1111/resp.13187].
20. Perikleous P, Rathinam S, Waller DA. VATS and open chest surgery in diagnosis and treatment of benign pleural diseases. *J Vis Surg*. 2017 Jun 16; 3:84. [DOI: 10.21037/jovs.2017.05.03].
21. Wang Z, Xu LL, Wu YB, Wang XJ, Yang Y, Zhang J, Tong ZH, Shi HZ. Diagnostic value and safety of medical thoracoscopy in tuberculous pleural effusion. *Respir Med*. 2015 Sep; 109[9]:1188-92. [DOI: 10.1016/j.rmed.2015.06.008].
22. Wan YY, Zhai CC, Lin XS, Yao ZH, Liu QH, Zhu L, Li DZ, Li XL, Wang N, Lin DJ. Safety and complications of medical thoracoscopy in the management of pleural diseases. *BMC Pulm Med*. 2019 Jul 10; 19[1]:125. [DOI: 10.1186/s12890-019-0888-5].
23. Eldaboosy SA, El-shamly M, Halima KM, Shaarawy AT, Alwakil I, Osama M. Medical video-assisted thoracoscopy – minimally invasive diagnostic tool for diagnosis of undiagnosed pleural effusion. *Egy J Chest Dis Tuberculosis* 2013; 62[1]: 121-126. [DOI: 10.1016/j.ejcdt.2013.02.008].
24. Mootha VK, Agarwal R, Singh N, Aggarwal AN, Gupta D, Jindal SK. Medical thoracoscopy for undiagnosed pleural effusions: experience from a tertiary care hospital in north India. *Indian J Chest Dis Allied Sci*. 2011 Jan-Mar; 53[1]:21-4. [PMID: 21446220].
25. Patil CB, Dixit R, Gupta R, Gupta N, Indushekar V. Thoracoscopic evaluation of 129 cases having undiagnosed exudative pleural effusions. *Lung India*. 2016 Sep-Oct; 33[5]:502-6. [DOI: 10.4103/0970-2113.188969].
26. Blanc FX, Atassi K, Bignon J, Housset B. Diagnostic value of medical thoracoscopy in pleural disease: a 6-year retrospective study. *Chest*. 2002 May; 121[5]:1677-83. [DOI: 10.1378/chest.121.5.1677].
27. Dadaş E, Erdoğan E, Tokar A, Ersöz M, Okay T. Effectiveness of Video-Assisted Thoracoscopic Surgery in Undiagnosed Exudative Pleural Effusions. *Turk Thorac J*. 2019 Apr 9; 20[3]:188-191. [DOI: 10.5152/TurkThoracJ.2018.18133].
28. Prabhu VG, Narasimhan R. The role of pleuroscopy in undiagnosed exudative pleural effusion. *Lung India*. 2012 Apr; 29[2]:128-30. [DOI: 10.4103/0970-2113.95304].
29. Janssen JP. Why you do or do not need thoracoscopy. *Eur Respir Rev*. 2010 Sep; 19[117]:213-6. [DOI: 10.1183/09059180.00005410].
30. Nagahiro I, Andou A, Aoe M, Sano Y, Date H, Shimizu N. Pulmonary function, postoperative pain, and serum cytokine level after lobectomy: a comparison of VATS and conventional procedure. *Ann Thorac Surg*. 2001 Aug; 72 [2]:362-5. [DOI: 10.1016/s0003-4975[01]02804-1].
31. Kwon ST, Zhao L, Reddy RM, Chang AC, Orringer MB, Brummett CM, Lin J. Evaluation of acute and chronic pain outcomes after robotic, video-assisted thoracoscopic surgery, or open anatomic pulmonary resection. *J Thorac Cardiovasc Surg*. 2017 Aug; 154[2]:652-659.e1. [DOI: 10.1016/j.jtcvs.2017.02.008].
32. Beheshtirouy S, Kakaie F, Mirzaaghazadeh M. Video-assisted rigid thoracoscopy in the diagnosis of unexplained exudative pleural effusion. *J Cardiovasc Thorac Res*. 2013; 5[3]:87-90. [DOI: 10.5681/jcvtr.2013.019].

International Journal

The background of the cover is a light blue gradient. It features a faint, stylized ECG (heart rate) line running across the top and bottom. In the center, there is a semi-transparent globe of the Earth. A stethoscope is overlaid on the globe, with its chest piece on the left and its earpieces extending towards the right. The overall aesthetic is clean and professional, representing the intersection of medicine and global health.

<https://ijma.journals.ekb.eg/>

Print ISSN: 2636-4174

Online ISSN: 2682-3780

of Medical Arts