

## Comparative Study of Local Injection of Platelet Rich Plasma versus Corticosteroids in the Treatment of Lateral Epicondylitis (Tennis Elbow)

Hesham D. Abd El Wahhab<sup>1</sup>, Tarek M. Emran<sup>2</sup>, Ashraf Abd S. Ahmed<sup>1</sup>, El Sayed M. Abd El Hami<sup>1</sup>, Mai M. Khalifa<sup>3</sup>

<sup>1</sup>Department of Physical Medicine, Rheumatology and Rehabilitation, and <sup>2</sup>Department of clinical pathology, Damietta Faculty of Medicine, Al-Azhar University, <sup>3</sup> Department of Physical Medicine, Rheumatology and Rehabilitation, Faculty of Medicine, Cairo University,  
Corresponding author: Mai Khalifa Mobile: 01002777146; Email: dr. [maikhalifa1012@gmail.com](mailto:maikhalifa1012@gmail.com)

### Abstract

**Background:** Lateral epicondylitis, also known as 'tennis elbow', is a very common condition affecting mainly middle-aged patients that is associated with local tendon pathology, alteration in pain perception and motor impairment. Several approaches to treatment have been proposed, the most frequently used is PRP. Platelet-rich plasma (PRP) is a growing modality for tissue healing, regeneration and has more pain relief lasting effect.

**Aim of the work:** was to estimate the clinical efficacy of local injection of Platelet Rich Plasma compared to local injection of corticosteroids in cases of lateral epicondylitis.

**Patients and Methods:** This study was a prospective clinical trial study in which 80 patients with lateral epicondylitis of both sexes between 21 - 60 years of age were recruited for the study. The included patients were divided into two groups: 1- **Platelet Rich Plasma group** (40 patients) were received a two injections of 1 ml of PRP with one month interval between the two injections, with absolute platelet count of 1 million platelets/ mm<sup>3</sup> as confirmed by automated cell counter. . PRP were prepared under complete aseptic conditions. 2- **Corticosteroids group** (40 patients) were received a two injections of corticosteroid (methyl-prednisolone, 40mg in 1 ml) with one month interval between the two injections. The site of injection and the technique used was same in both the groups.

**Results:** Affected side was higher in right hand than left hand in both studied groups. In PRP group, there were 92.5 % right hand and 7.5 % left handed patients. Whereas, in corticosteroid group, there were 95.0 % right handed and 5.0 % left handed patients; and there was no significant difference between the studied groups. Visual Analog Scale (VAS) was significantly improved at 1 and 3 months in PRP patients compared to only significant improvement at 3 months in corticosteroid group. Both studied groups showed significant improvement of grip strength at 1 and 3 months. qDASH at 1 and 3 months was significantly better in the PRP group, but it statically not reached. On the other hand, significant improvement of US edema was estimated in the corticosteroid group at 3 months when compared with PRP group. In addition, slight improvement of US tears was appeared in both groups after 3 months.

**Conclusion:** It could be concluded that both PRP and corticosteroids showed better improvement of pain, grip strength and qDASH at 3 months. However, PRP is suggested to be an effective treatment for lateral epicondylitis. PRP provides better improvement in all parameters with nearly durable effect when compared to corticosteroids. On the other hand, corticosteroids treatment resulted in better improvement of US detected edema.

**Keywords:** Lateral epicondylitis, PRP, Corticosteroids.

### Introduction

Lateral epicondylitis (also known as tennis elbow) is a painful degenerative condition affecting the proximal enthesis of the extensor carpi radialis brevis tendon <sup>(1)</sup>. It is characterized as an overuse injury of the forearm and the wrist extensors that typically presents as progressive pain over the lateral aspect of the elbow <sup>(2)</sup>. Tennis elbow is a common musculoskeletal condition affecting middle-aged patients with symptoms usually

lasting from 6 months to 2 years. Most of patients could respond to conservative therapy; whereas, others could need surgical intervention. A new treatment strategy has been developed for use with ultrasound guidance in the ultrasonic microresection of tendinopathic tissue <sup>(3)</sup>. The annual incidence of LE and rate of surgical intervention have remained constant from 2007 to 2014. The proportion of patients over >65 years

diagnosed with and receiving surgical treatment for LE has significantly increased in recent years<sup>(4)</sup>. Therefore, much research pays attention to novel therapies which try to regenerate tendon and regain function in patients with epicondylitis. One of these therapies is PRP injection that functions to enhancement, and improved healing<sup>(5)</sup>.

Platelet-rich plasma (PRP) is a concentrated source of platelets and platelet-derived growth factors that has been used in numerous medical fields. It is suggested to enhance the healing of wounds, bone, and tendons through release of specific growth factors upon platelet activation. For lateral epicondylitis, the reasoning for use is similar to that of autologous blood injections, but proponents of PRP laud the increased concentration of platelets and therefore platelet-derived growth factors<sup>(6)</sup>. PRP contains transforming growth factor-beta (TGF-beta) which plays a pivotal role in tendon healing<sup>(7)</sup>.

Treatment of patients with chronic lateral epicondylitis with PRP extract reduced pain and significantly increased function<sup>(8)</sup>. It has a relatively slower but longer-term therapeutic effect than corticosteroid injections in LE treatment and recurrence of symptoms<sup>(9)</sup>. Recently, PRP is utilized in a broad sector of diseases treatment. PRP injection provides supra-physiological concentrations of growth factors that may help in accelerated tissue remodeling and regeneration. It has the ability of rejuvenating the face<sup>(10)</sup>. It is more successful than HA and ozone injections in the treatment of mild-moderate knee OA<sup>(11)</sup>. The intra-articular PRP injection is an effective treatment modality in low back pain<sup>(12)</sup>. In addition, it is a superior treatment option for longer duration efficacy<sup>(13)</sup>. PRP is effective and better than corticosteroid injection in treatment of Periarthritis ShoulderPA<sup>(14)</sup>. Moreover, it is useful for treating muscle injuries in equine athletes through upregulate the expression of genes related to muscle regeneration<sup>(15)</sup>, and it is effective as other treatments in reducing pain and improving function in patients with plantar fasciitis<sup>(16)</sup>.

The aim of the current study was to compare the clinical efficacy of local injection of Platelet Rich Plasma versus local injection of corticosteroids in cases of lateral epicondylitis.

#### ***Patients and methods***

This clinical trial study included 80 patients with lateral epicondylitis of both sexes with mean age 41 years attending at Department of Physical Medicine, Rheumatology and Rehabilitation, Al-Azhar Damietta University Hospital. Approval of the ethical committee and a written informed consent from all the subjects were obtained. This study was conducted between September 2016, and June 2017.

The diagnosis was made on the basis of clinical signs and symptoms.

#### **Inclusion criteria:**

1- LE was defined as pain on the lateral side of the elbow and pain at the lateral epicondyle on direct palpation and during resisted dorsiflexion of the wrist. The duration of the symptoms ranged from one to six months.

2- Recruited patients were either on conservative treatment with analgesics and anti-inflammatory drugs or no treatment. A two week washout period was given to all the patients on analgesics and anti-inflammatory drugs

#### **Exclusion Criteria**

1- Patients with history of arthritis, trauma or fracture, nerve entrapment around elbow, upper limb pain due to causes other than the current Tennis elbow (carpal tunnel syndrome, radiculopathy).

2- Patients with systemic diseases (diabetes mellitus, hypertension, hepatitis), bleeding disorder and psychiatric disorder.

3- Tendon surgery or local CS injection in the past 6 months.

4- Pregnant females.

5- R A, deformity, infection, tumor.

#### **Patients were divided into two groups:**

**1. Platelet Rich Plasma group (n: 40):** The patients in this group had received a two injections of 1 ml of PRP with one month interval between the two injections, with absolute platelet count of 1 million platelets/mm<sup>3</sup> as confirmed by automated cell counter.

**Corticosteroids group (n: 40):** The patients in this group had received a two injections of corticosteroid (methyl-prednisolone, 40mg in 1 ml) with one month interval between the two injections. The site of injection and the technique used was same in both the groups.

#### **Preparation of PRP:**

PRP is obtained from a sample of patients' venous blood drawn and according to the baseline platelet count the technique is employed. In general, citrated blood samples were centrifuged two times, the first was at 1800 rpm for separation of red blood cells and the second was at 3500 rpm to concentrate platelets<sup>(17)</sup>. By this method, PRP will be obtained and injected immediately without storage because freshly-harvested PRP might preserve all the platelet functions better.

All patients included in the current study were subjected to the following:

- **Baseline Evaluation:**

**Full medical history includes:** age, sex, residence, occupation, family history, marital status, special habits of medical importance, review of other systems and complaint and history of present illness.

**General examination includes:** Present history of onset, course, appearance, body built, decubitus and facial expression and vital signs.

**Musculoskeletal examination includes:** local examination of elbow joint and special tests for diagnosis of tennis elbow.

- **Outcome Measures:** Outcome measures recorded at baseline at 1 and 3 months:

**1. Pain Intensity:** This was assessed using the Visual Analog Scale (VAS). Assessment was done before and after the assessment of grip strength.

**2. Grip Strength:** using a sphygmomanometer cuff inflated to 30

## Results

**Table (1) Demographic data of the studied patients' groups.**

	PRP Group (n=40)	Corticosteroid(n=40)	P value
Age (years)	39.4 ± 11.4	41.9 ± 11.8	0.33
BMI (Kg/m <sup>2</sup> )	27.4 ± 3.4	26.2 ± 3.4	0.12
Sex	Male	17 (42.5 %)	0.65
	Female	23 (57.4 %)	

In the current work, there were no statistically significant differences between the studied groups regarding age (39.4 ± 11.4 versus 41.9 ± 11.8; p=0.33), BMI (27.4 ± 3.4 versus 26.2 ± 3.4; p=0.12) and sex distribution (PRP group: 17 males and 23 females, corticosteroid group: 19 males and 21 females; p=0.65).

Regarding the affected side, there were 37 (92.5 %) right hand and 3 (7.5 %) left handed patients were determined in PRP group. Whereas, in corticosteroid group, there were 38 (95.0 %) right handed and 2 (5.0 %) left handed patients. No statistically significant differences between the studied groups regarding the affected side (p=0.64), this is graphically represented by Fig.1.

mmHg. Patients were instructed to squeeze the cuff as hard as he can with his elbow extend.

**3. Functional Outcome:** Functional outcome was measured using quick Disabilities of the Arm, Shoulder and Hand scale (qDASH). The qDASH uses 11 items to measure physical function and symptoms in persons with any or multiple musculoskeletal disorders of the upper limb.

**4. Ultrasonography:** Ultrasonography was performed before and after treatment to evaluate for tear at the common extensor origin, edema for all patients in the study. Linear high-frequency transducers have been used because the ligaments, tendons, and nerves about the elbow are superficial and linear. The examination of the lateral elbow was done in long and short axis planes of examination.

### Statistical analysis:

Data obtained from the present study were computed using SPSS versions 17 under the platform of Microsoft Windows 7. Continuous data were expressed in the form of mean ± SD while categorical data were expressed in the form of count and percent. Comparison of continuous data was performed utilizing repeated measures ANOVA or student t test, while categorical data were done using Chi-square test. P value less than 0.05 was considered statistically significant, p-value < 0.001 was considered highly statistically significant, and p-value ≥ 0.05 was considered not statistically significant.

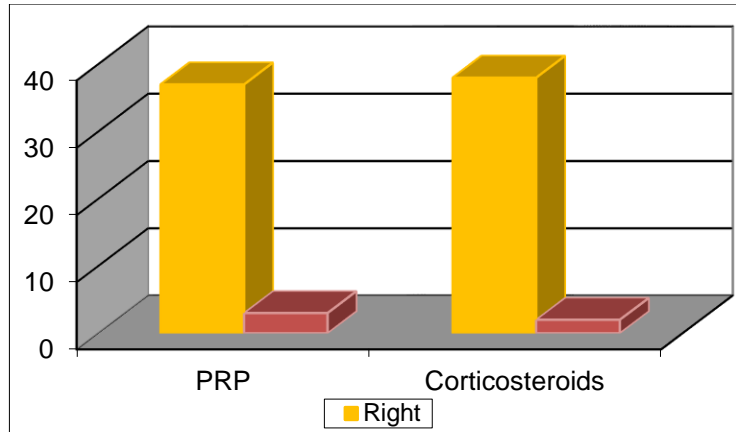


Fig. (1) Affected side in PRP patients compared to corticosteroids patients' groups

**Table (2) VAS in PRP patients compared to corticosteroids patients groups throughout the study period.**

	PRP PRP Group (n=40)	Corticosteroid(n=40)	P value
VAS baseline	6.4 ± 1.1	6.0 ± 1.3	0.07
VAS 1 month	4.9 ± 0.9	6.3 ± 0.9	0.0001*
VAS 3 months	3.5 ± 1.0	5.0 ± 0.8	0.0001*
<b>P value</b>	<b>0.0001*</b>	<b>0.0001*</b>	

As regard to VAS the present study reveals significant improvement of VAS in both groups at and 3 months. However, patients in the PRP group also showed significant improvement at 1 month. Comparison between the studied groups showed significantly lower VAS in PRP group at 1 month and 3 months, Fig.2.

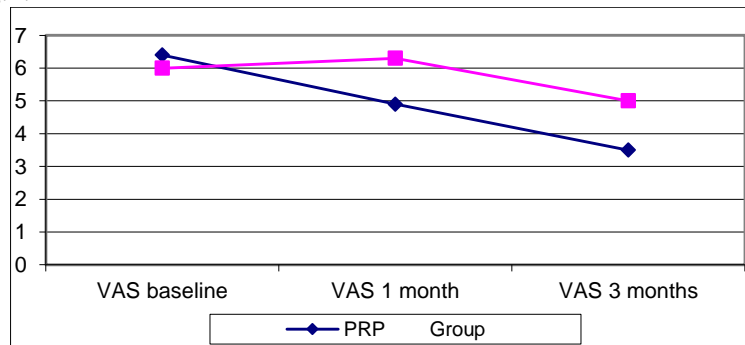
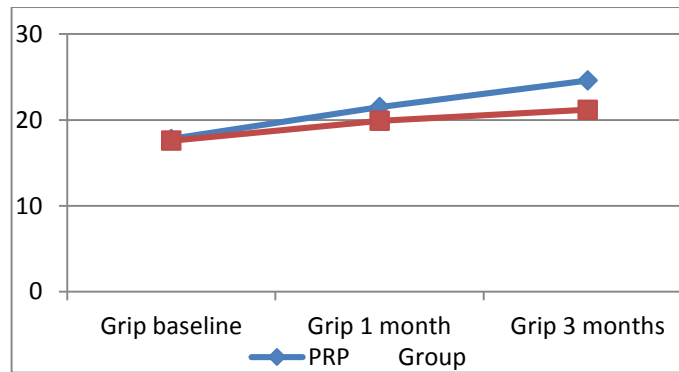


Fig. (2) VAS in PRP patients compared to corticosteroids patients groups.

**Table (3) Grip in PRP patients compared to corticosteroids patients throughout the study period.**

	PRP PRP Group (n=40)	Corticosteroid(n=40)	P value
Grip baseline	17.8 ± 3.4	17.6 ± 3.0	0.76
Grip 1 month	21.5 ± 1.9	19.9 ± 3.0	0.007*
Grip 3 months	24.6 ± 3.5	21.2 ± 3.6	0.0001*
<b>P value</b>	<b>0.0001*</b>	<b>0.0001*</b>	

According to grip, our results clarified that both studied groups showed significant improvement of grip strength at 1 and 3 months. However, PRP patients group showed significantly higher hand grip duration in at 1 month and 3 months than corticosteroids patients group, graphically represent by Fig.3.



Fig(3) Hand grip in PRP patients compared to corticosteroids patients groups.

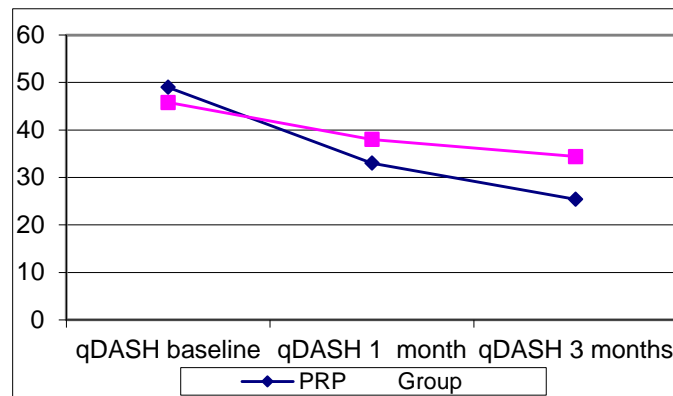


Fig (4) qDASH in PRP patients compared to corticosteroids patients groups.

In the present work, there were no differences between the studied groups according to qDASH. Both groups showed significant improvement of qDASH at 1 and 3 months but it was significantly better in the PRP group at 1 month and 3 months, Fig.4.

**Table (4) US tears in PRP patients compared to corticosteroids patients throughout the study period.**

		PRP PRP Group (n=40)	Corticosteroid(n=40)	P value
US tear baseline	+ve	16	18	0.65
	-ve	24	22	
US tear 1 month	+ve	16	18	0.65
	-ve	24	22	
US tear 3 months	+ve	12	15	0.48
	-ve	28	25	
P value		0.56	0.74	

The present study clarified slight improvement of US tears in both groups after 3 months. Whereas, this improvement was not statistically significant.

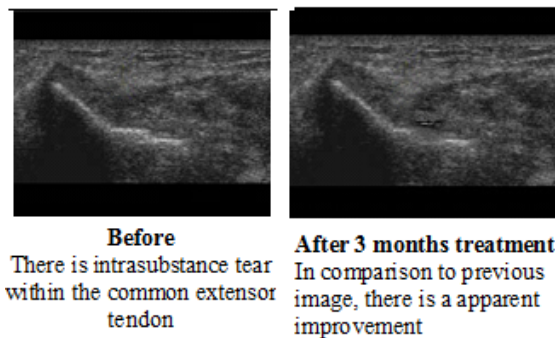


Fig (5) Musculoskeletal Ultrasound of right elbow 37 years old male patient with PRP injection

**Table (5) US edema in PRP patients compared to corticosteroids patients throughout the study period**

		PRP PRP Group (n=40)	Corticosteroid(n=40)	P value
US edema baseline	+ve	21	18	0.5
	-ve	19	22	
US edema 1 month	+ve	19	13	0.17
	-ve	21	27	
US edema 3 months	+ve	17	7	0.015*
	-ve	23	33	
P value		<b>0.67</b>	<b>0.03*</b>	

The current study reveals significant improvement of US edema in the corticosteroid group at 3 months when compared with PRP group.

### Discussion

Lateral epicondylitis (LE) is characterized as an overuse injury of the forearm and the wrist extensors that typically presents as progressive pain over the lateral aspect of the elbow<sup>(18)</sup>. LE can be treated conservatively using rest, non-steroidal anti-inflammatory drugs, bracing, and physical therapy with success. However, partial or complete rupture of the extensor origin, operative therapy is indicated<sup>(19)</sup>. So, new non-operative treatment alternatives have been developed in recent years<sup>(20)</sup>. Many researches deal with the utilizing of PRP in treatment of many diseases. Herein, PRP had evaluated for treatment of LE patients compared to corticosteroids. The present study comprised 36 males (45.0 %) and 44 (55.0 %) females, this agrees with **Fathy**<sup>(21)</sup>. Right side was affected in 82.5 % patients and the left was in 17.5 % patients. The dominance of right hand affections was also reported by the study of **Panthi et al.**<sup>(22)</sup>.

Our study reveals that at baseline evaluation there were no significant differences between the studied groups regarding VAS, grip, qDASH and ultrasonic data. Both groups showed significant improvement of VAS at 1 and 3 months. However, significantly lower VAS was estimated in PRP group at 1 month and 3 months. Our results are in accordance with the study of **Khaliq et al.**<sup>(23)</sup> was reported that 52.9% of patients who receiving corticosteroid injections showed effectiveness but 82.3% of patients who receiving injection of PRP showed effectiveness. Moreover, the recent study of **Varshney et al.**<sup>(24)</sup> found that PRP resulted in better improvement of pain as compared to corticosteroid treatment.

In respect to grip strength, both groups showed significant improvement of grip

strength at 1 and 3 months. However, PRP group revealed significantly higher hand grip duration at 1 month and 3 months. This in line with **Yadav et al.**<sup>(25)</sup> who noted that at 3 months, PRP treated patients had significantly better grip strength. Conversely, **Gautam et al.**<sup>(26)</sup> reported that grip strength at 3 months was better in the corticosteroid group.

As regard to qDASH score, we noted that significant improvement of qDASH was evaluated in both groups at 1 and 3 months. Moreover, qDASH was significantly better in the PRP group at 1 month and 3 months compared to corticosteroid group. This is in harmony with the aforementioned study of **Yadav et al.**<sup>(25)</sup>, **Khaliq et al.**<sup>(23)</sup> and **Varshney et al.**<sup>(24)</sup>.

According to the ultrasound assessment, there was no significant difference between the studied groups as regard to US tears. Whereas, there was significant improvement of US edema in the corticosteroid group at 3 months when compared with PRP group. This is in accordance with **Krogh et al.**<sup>(27)</sup> who clarified that corticosteroids were better than PRP in reducing tendon thickness after 3 months by using ultrasound. Also, **Shiple**<sup>(28)</sup> found a significant reduction of ultrasound detected tendon thickness at 3 months in the corticosteroid treated patients.

PRP is generally better than corticosteroids in reducing pain and improving function. Additionally, PRP injection for intractable lateral epicondylitis is considered not only a safe but also very effective tool in reducing symptoms. Moreover, it decreases the need for surgical intervention in **Hastie et al.**<sup>(29)</sup> studied patients group.

### Conclusion

Both PRP and corticosteroids showed better improvement of pain, grip strength and qDASH at 3 months. However, PRP is suggested to be an effective treatment for lateral epicondylitis. PRP provides better improvement in all parameters with nearly durable effect when compared to corticosteroids. On the other hand, corticosteroids treatment resulted in better improvement of US detected edema.

## References

**1-Walton MJ, Mackie K, Fallon M, Butler R, Bredahl W, Zheng MH and Wang A (2011):** The reliability and validity of magnetic resonance imaging in the assessment of chronic lateral epicondylitis. *J Hand Surg Am.*, 36(3):475-9.

**2- Buchanan BK and Hughes J. (2018):** Tennis Elbow (Lateral Epicondylitis). In *StatPearls*, Treasure Island (FL).

**3- Battista CT, Dorweiler MA, Fisher ML, Morrey BF and Noyes MP(2018).** Ultrasonic Percutaneous Tenotomy of Common Extensor Tendons for Recalcitrant Lateral Epicondylitis. *Tech Hand Up Extrem Surg.*, 22(1): 15-18.

**4- Degen RM, Conti MS, Camp CL, Altchek DW, Dines JS, and Werner BC (2018):** Epidemiology and Disease Burden of Lateral Epicondylitis in the USA: Analysis of 85,318 Patients. *HSS J.*, 14(1): 9-14.

**5- Tarpada SP, Morris MT, Lian J and Rashidi S (2018):** Current advances in the treatment of medial and lateral epicondylitis. *J Orthop.*, 15(1): 107-110.

**6- Sampson S, Gerhardt M and Mandelbaum B (2008):** Platelet rich plasma injection grafts for musculoskeletal in-juries: a review. *Curr Rev Musculoskelet Med.*, 1(3-4): 165-74.

**7-Lim W, Park SH, Kim B, Kang SW, Lee JW and Moon YL (2018):** Relationship of cytokine levels and clinical effect on platelet-rich plasma-treated lateral epicondylitis. *J Orthop Res.*, 36(3): 913-920.

**8- Tonk G, Kumar A and Gupta A (2014):** Platelet rich plasma versus laser therapy in lateral epicondylitis of elbow. *Indian J Orthop.*, 48(4): 390-3.

**9- Ben-Nafa W, and Munro W (2018):** The effect of corticosteroid versus platelet-rich plasma injection therapies for the management of lateral epicondylitis: A systematic review. *SICOT J.*, 4: 11.

**10- Elnehrawy NY, Ibrahim ZA, Eltoukhy AM and Nagy HM (2017):** Assessment of the efficacy and safety of single platelet-rich plasma injection on different types and grades of facial wrinkles. *J Cosmet Dermatol.*, 16(1): 103-111.

**11- Duymus TM, Mutlu S, Dernek B, Komur B, Aydogmus S and Kesiktas, FN (2017):** Choice of intra-articular injection in treatment of knee osteoarthritis: platelet-rich plasma, hyaluronic acid or ozone options. *Knee Surg Sports Traumatol Arthrosc.*, 25(2): 485-492.

**12- Singla V, Batra YK, Bharti N, Goni VG and Marwaha N (2017):** Steroid vs. Platelet-Rich Plasma in Ultrasound-Guided Sacroiliac Joint Injection for Chronic Low Back Pain. *Pain Pract.*, 17(6): 782-791.

**13- Wu J, Zhou J, Liu C, Zhang J, Xiong W, Lv Y and Liu Q. (2017):** A Prospective Study Comparing Platelet-Rich Plasma and Local Anesthetic (LA)/Corticosteroid in Intra-Articular Injection for the Treatment of Lumbar Facet Joint Syndrome. *Pain Pract.*, 17(7): 914-924.

**14- Kothari SY, Srikumar V and Singh N (2017):** Comparative Efficacy of Platelet Rich Plasma Injection, Corticosteroid Injection and Ultrasonic Therapy in the Treatment of Periarthritis Shoulder. *J Clin Diagn Res.*, 11(5): RC15- RC18.

**15- Fukuda K, Miyata H, Kuwano A, Kuroda T, Tamura N, Kotoyori Y and Kasashima Y (2017):** Does the injection of platelet-rich plasma induce changes in the gene expression and morphology of intact Thoroughbred skeletal muscle? *J Equine Sci.*, 28(2): 31-39.

**16- Ling Y and Wang S (2018):** Effects of platelet-rich plasma in the treatment of plantar fasciitis: A meta-analysis of randomized controlled trials. *Medicine (Baltimore)*, 97(37): e12110.

**17- Arora N, Ramanayake T, Romanos G et al. (2009):** Platelet-rich plasma: a literature review. *Implant Dent.*, 18(4): 303-310.

**18- Buchanan BK and Hughes J (2017):** Tennis Elbow (Lateral Epicondylitis). Treasure Island (FL): StatPearls Publishing.

**19-Altintas B and Greiner S (2016):** Lateral epicondylitis conservative - operative. *Orthopade.*, 45(10): 870-7.

**20-Vaquero-Picado A, Barco R and Antuna SA (2016):** Lateral epicondylitis of the elbow. *EFORT Open Rev.*, 1(11): 391-397.

- 21- Fathy AA (2015).** Iontophoresis Versus Cyriax-Type exercises in Chronic Tennis Elbow among industrial workers. *Electron Physician.*, Sep 16; 7(5):1277-83.
- 22- Panthi S, Khatri K, Kharel K, Byanjankar S, Shrestha R, Sharma JR, Vaishya R, Agarwal AK and Vijay V (2017):** Outcome of Percutaneous Release of Tennis Elbow: A Non-Randomized Controlled Trial Study. *Cureus.*, 9(1): e952.
- 23- Khaliq A, Khan I, Inam M, Saeed M, Khan H and Iqbal MJ (2015):** Effectiveness of platelets rich plasma versus corticosteroids in lateral epicondylitis. *J Pak Med Assoc.*, 65 (11): S100-S104.
- 24- Varshney A, Maheshwari R, Juyal A, Agrawal A and Hayer P. (2017):** Autologous Platelet-rich Plasma versus Corticosteroid in the Management of Elbow Epicondylitis: A Randomized Study. *IntJ Appl Basic Med Res.*, 7(2): 125-128.
- 25- Yadav R, Kothari SY and Borah D (2015):** Comparison of Local Injection of Platelet Rich Plasma and Corticosteroids in the Treatment of Lateral Epicondylitis of Humerus. *J ClinDiagn Res.*, 9(7): RC05-7.
- 26- Gautam VK, Verma S, Batra S, Bhatnagar N and Arora S (2015):** Platelet-rich plasma versus corticosteroid injection for recalcitrant lateral epicondylitis: clinical and ultrasonographic evaluation. *J OrthopSurg (Hong Kong)*, 23(1): 1-5.
- 27- Krogh TP, Fredberg U, Stengaard-Pedersen K, Christensen R, Jensen P and Ellingsen T (2013):** Treatment of lateral epicondylitis with platelet rich plasma, glucocorticoid, or saline: a randomized, doubleblind, placebo-controlled trial. *Am J Sports Med.*, 41(3): 625-35.
- 28- Shiple BJ (2013):** How effective are injection treatments for lateral epicondylitis? *Clin J Sport Med.*, 23(6): 502- 503.
- 29- Hastie G, Soufi M, Wilson J and Roy B (2018):** Platelet rich plasma injections for lateral epicondylitis of the elbow reduce the need for surgical intervention. *J Orthop.*, 15(1): 239-241.