

## QUANTITATIVE AND HISTOCHEMICAL STUDY ON THE ADRENAL MEDULLA IN POST NATAL PERIOD OF ALBINO RAT

Wagieh k.Baiomy; Abdel-mawgood Anas; Mamdooh Ghaly; Ashraf M. Moustafa;  
Atef I.Mohamed and Wagieh Mansour  
Histology Department, Faculty of Medicine Al Azhar University

### ABSTRACT

**Background:** The present work was based on the evaluation of histological, histochemical, and quantitative study on the adrenal medulla of the white albino rat in the different post natal age period.

**Material and methods:** Sixty male albino rats were used in this study.

The rats were classified to 4 main groups as follows:

- Group one : **One week** old albino rats.
- Group two: **One month** old albino rats.
- Group three: **Three months** old albino rats.
- Group four: **Senile** rats.

Three main parameters were performed in this study, the first was the study of the morphological changes in the adrenal medulla in the different postnatal age groups. The second was concerned with the histochemical studies while the last parameter was the quantitative studies on the gland volume as well as its cellular count. These three parameters were performed by using different staining techniques.

**Results:** The results showed that medullary cells in the early age groups were arranged in non-differentiated groups and become more differentiated in the older age groups. Both reticular and elastic fibers in the older age groups showed a definite increase especially at the region of corticomedullary zone. The different types of chromaffin cells were more observed at the old age groups. The concentration of ascorbic acid granules was more marked in the senile group. The quantitative changes were in the form of increased medullary volume especially in the old age.

The number of chromaffin cells as well as the concentration of ascorbic acid contents was more noticed in the old age group.

**Conclusions:** The differentiation of both divisions of the adrenal gland was not noticed in the early age groups. Cellular and fibrous differentiations were more seen in older age groups which may reflect an idea about the degree of gland maturation.

**Keywords:** Adrenal medulla , chromaffin cells , ascorbic acid .

### INTRODUCTION

The adrenal medulla represents one of the most important structures in the human body that needs extensive research study. Catecholamines secreted by the medullary Chromaffin cells have many important roles in both newly born and adults.

The adrenal gland was first described by **Eustachius in 1563** and its importance was later recognized by the works of (**Anderson and Axel, 1997**).

The adrenal glands are embedded in adipose tissues at the cranial pole of each kidney (**Don and Ronald., 2002**). Their weight and size vary with age and physiological condition of the individual

(**Junqueira et al., 2003**). Fresh sections of the adrenal gland show its covering capsule which is formed of collagenous connective tissue, the cortical tissue is yellow and peripherally situated while the medulla is reddish and vascular in the central location of the gland ( **Neville and Hare, 1982**).

The adrenal gland is composed of two tissues with different ontogenetic origin, the cortex and the medulla. The cortex develops from the mesoderm but the medulla of neural crest lineage origin (**Keith and Persaud,1993**). During the fetal life, a layer of fetal or provisional

cortex is located between the medulla and the thin permanent cortex. The function of such fetal cortex is the secretion of sulfate conjugates of androgens, which are converted in the placenta to active androgens and estrogens that enter the maternal circulation. Such fetal cortex undergoes involution after birth (Goldman, 2000).

The adrenaline-containing cells are termed chromaffin cells, there is a great histological difference between the developing Chromaffin tissue and the adult Chromaffin cells (Anderson and Axel, 1997).

Carmichael 1993, described the medullary cells as large epithelial cells arranged in rounded clusters or short cords that are in intimate relation to the blood capillaries.

Parenchymal cells of the adrenal medulla can be regarded as modified sympathetic postganglionic neurons that lost their axons and dendrites during their embryonic development and become a secretory cells (Junqueira et al., 2003).

The adrenal medullary cells have been considered as a substitute neurons in the human brains, parts of such gland were transplanted in the brain of patient with severe Parkinsonian disease (Backlund et al., 2003), more recently such technique may be one of the effective new therapy for this common disease (Madraza et al., 1998).

Although many studies were carried out on that organ, few literatures were available concerning the age associated structural variations. Hence, the aim of this work is to identify the different cellular changes in the adrenal medulla in different postnatal ages.

## MATERIAL AND METHODS

### The animals:

Sixty male albino rats were used in this study. The rats were divided to four main groups 15 rat /group as follows

Group 1: Albino rats aged seven days.

Group 2: Albino rats aged one month.

Group 3: Albino rats aged three months.

Group 4: Albino rats aged one and half year (Senile).

### Methods:

The study was planned to evaluate the following items:

1- Morphological study: It was performed by using paraffin sections which were stained by heamatoxylin and eosin stain (Kiernan 2001).The reticular fibers were examined by staining the sections with silver stain while the elastic fibers were stained with orcein stain (Bancroft and Gamble 2002).

2- Histochemical study, for the following:

I- Staining of both types of chromaffin cells by Wood technique (Wood 1963).

II- Staining the ascorbic acid (vitamin c) contents in the chromaffin cells using silver nitrate technique (Bancroft and Gamble 2002).

3- Quantitative study, for recording changes in the following:

I- Changes in the mean volume of the adrenal medulla in the different postnatal age groups. An eye piece micrometer "PZO" calibrated against stage micrometer was used to estimate the volume of the whole gland and that of the medulla according to the following formula: (Gobran 1972)

$$V = \frac{4}{3} \pi L^3$$

Where  $L = \frac{1}{2}$  the mean diameter and  $\pi = 22/7$

II- Changes in the number of both types of chromaffin cells in the different postnatal age groups.

III- Changes in the cellular contents of ascorbic acid in the different postnatal age groups.

Computer imaging system was used for counting cell number as well as estimating the optical density of the ascorbic acid.

4- The obtained data were analyzed using student (t) test, significant differences between the means in the different groups were considered at  $p < 0.05$  (Sokal and Rohlf, 1981).

## RESULTS:

### I- Morphological changes:

The gland of the one week old group showed ill differentiation between cortex

and medulla (**figure 1**). The medullary cells arranged either in groups or in cords separated by blood sinusoid .

In second group of one month (**figure 2**) , the gland become more larger in size and there is well differentiation between cortex and medulla The medullary cells arranged in smaller areas of the medulla separated by wide fenestrated blood sinusoid, the medullary cells become larger in size with large nuclei and deep basophilic cytoplasm In third group of three months (**figure 3**) and In fourth senile group (**figure 4**) the adrenal gland become larger in size and there is sharp differentiation between cortex and the medulla, the medullary cells were arranged mainly in anastomosing cords separated by wide fenestrated blood sinusoids . The medullary cells become larger in size and increase in number with large nuclei and deeply basophilic.

Changes in reticular fibers were variable in the different groups of the study (**figures 5-8**). In silver stained sections of adrenal gland of three months old and senile group rats there was an increase in the network of reticular fibers at corticomedullary junction but there was a decrease in both one week and one month old aged albino rats.

In orcein stained sections (**figures 9-12**) of adrenal gland, the elastic fibers showed less distribution in both one week and one month while the distribution of these fibers showed observable increase in both of three months and senile groups rats.

#### **II- Histochemical changes:**

Woods stain (figures 13-16) was the suitable stain for differentiation of both types of chromaffin cells.

The adrenaline secreting cells were stained purple in color with large purple nucleus and non granular cytoplasm. The noradrenaline secreting cells were yellowish orange in color with small purple nucleus and granular cytoplasm. The differentiation between the two types of cells was more noticed in older age groups.

Sections of adrenal medulla stained with silver nitrate for localization of sites of ascorbic acids (**figures 17-20**) .

In sections of adrenal gland of one week old age the reaction appear as weak black dots in the medulla while in sections of one month and three months the reaction was. In senile age the reaction was increased.

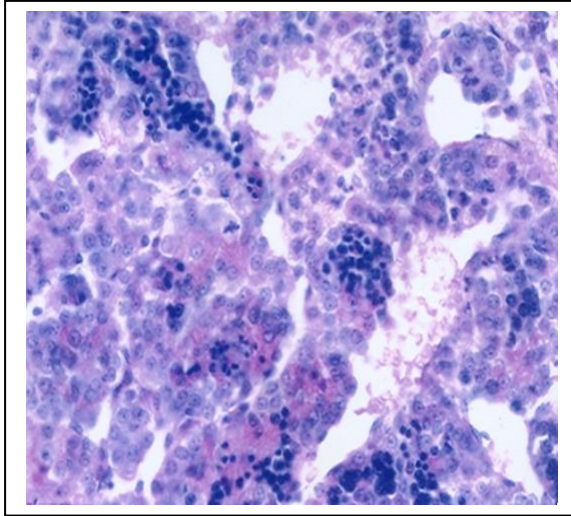
#### **III- Quantitative changes : (Tables 1-4 & Figs. 21-24)**

**Changes in the volume of the adrenal medulla:** The volume of the medulla showed gradual increase with age. The difference between the mean volume of the medulla of the adult rat and those of the other age groups showed statistical significant changes.

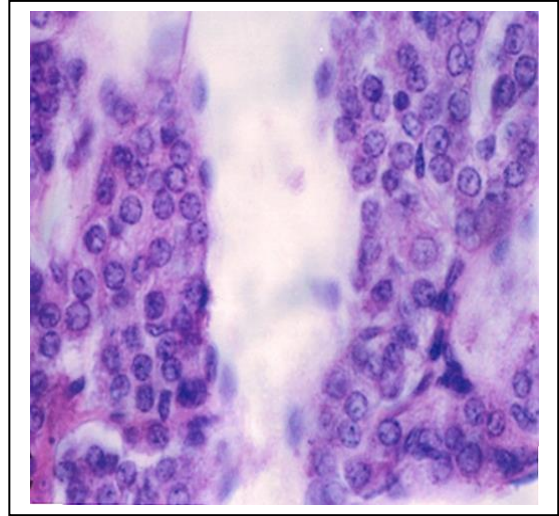
**Changes in the mean number of medullary cells:** The two types of chromaffin cells were difficult to be differentiated in young ages but the degree of differentiation was much more better in older age groups, it showed statistical significant increase in the number especially in old aged groups.

#### **Changes in the concentration of ascorbic acid in the medulla:**

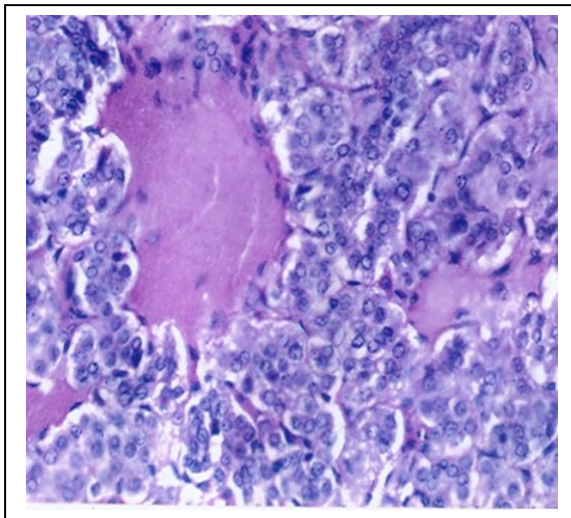
There was a significant increase in the optical density of ascorbic acid content with the advance in the age groups when compared to those of the adult ag



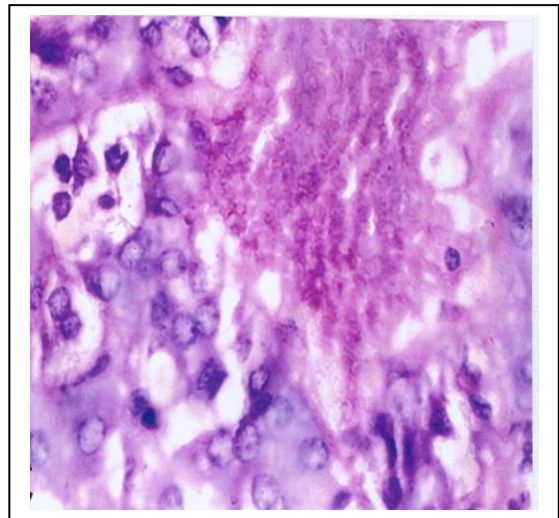
( Fig. 1) Photomicrograph of a section in the adrenal medulla of one week old age, showing cells collected in groups without differentiation. ( Hx.&E. stain X 500)



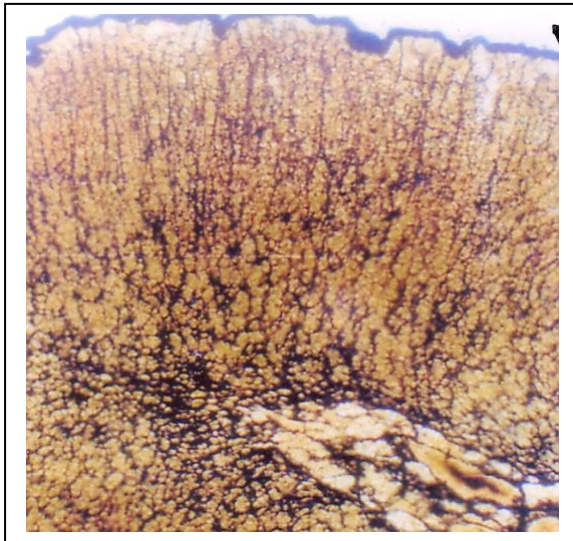
( Fig. 2) Photomicrograph of a section in the adrenal medulla of one month old age, showing differentiated cells collected in groups . ( Hx.&E. stain X 500)



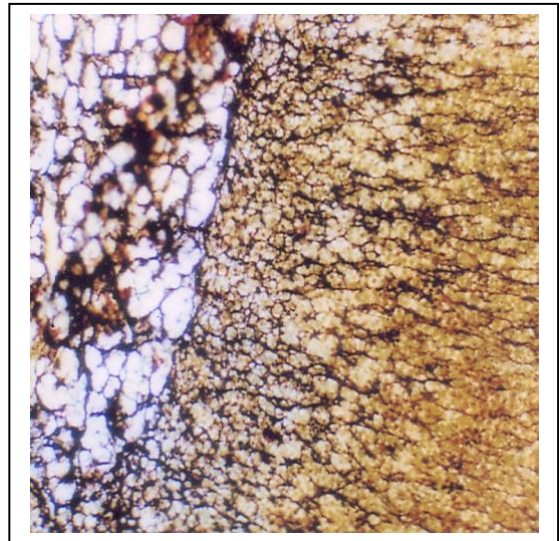
( Fig. 3) Photomicrograph of a section in the adrenal medulla of three months old age, showing differentiated cells collected in groups ( Hx.&E. stain X 500).



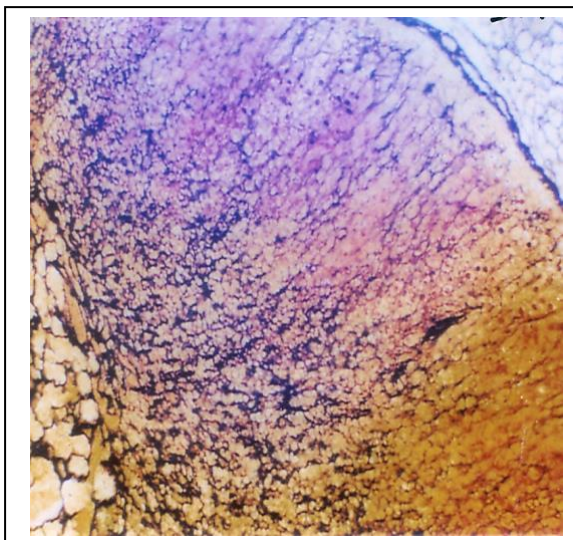
( Fig. 4) Photomicrograph of a section in the senile adrenal medulla , showing more differentiated cells collected in groups . ( Hx.&E. stain X 500).



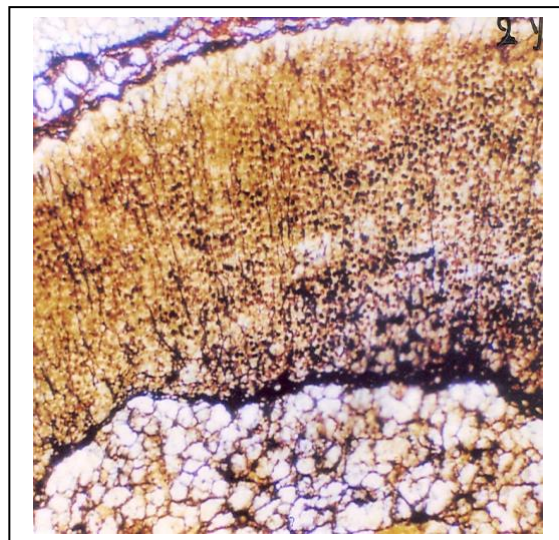
( Fig. 5) Photomicrograph of a section in the adrenal medulla of one week old age, showing the distribution of reticular fibers.  
( Silver stain X 500).



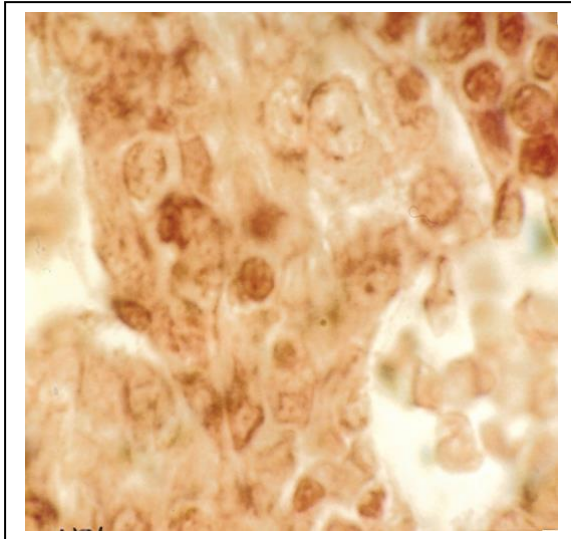
( Fig. 6) Photomicrograph of a section in the adrenal medulla of one month old age, showing the distribution of reticular fibers.  
( Silver stain X 500).



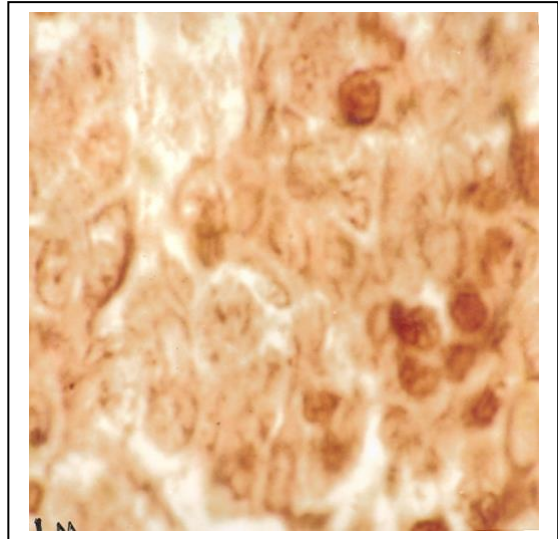
( Fig. 7) Photomicrograph of a section in the adrenal medulla of three months old age, showing the distribution of reticular fibers.  
( Silver stain X 500).



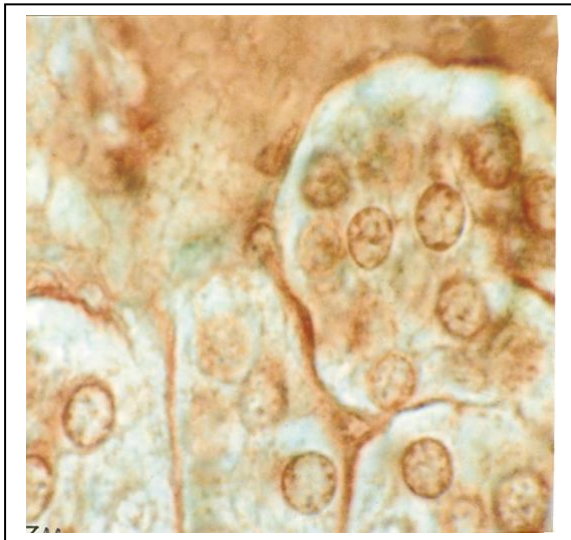
( Fig. 8) Photomicrograph of a section in the senile adrenal medulla , showing the distribution of reticular fibers.  
( Silver stain X 500).



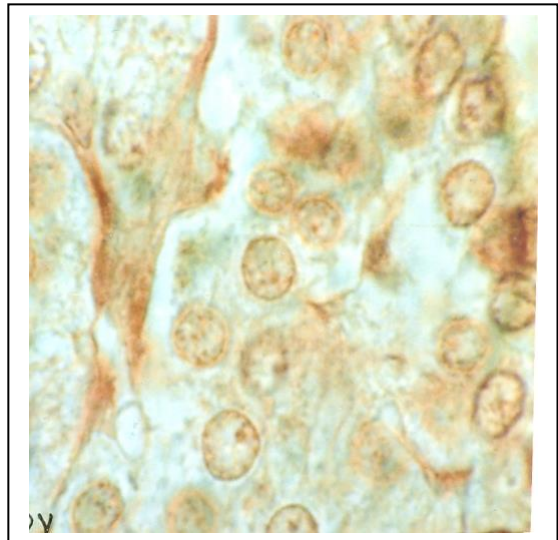
( Fig. 9) Photomicrograph of a section in the adrenal medulla of one week old age, showing the distribution of elastic fibers.  
( Orcein stain X 500).



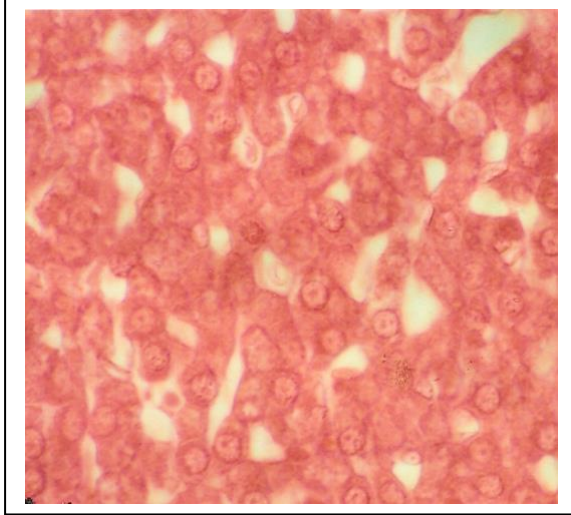
( Fig. 10) Photomicrograph of a section in the adrenal medulla of one month old age, showing the distribution of elastic fibers.  
( Orcein stain X 500).



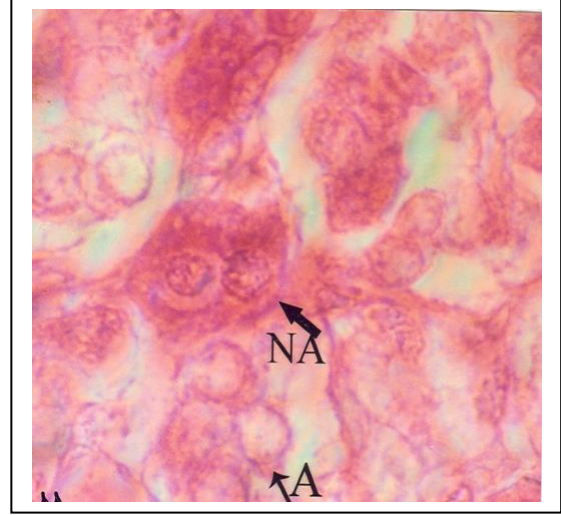
( Fig. 11) Photomicrograph of a section in the adrenal medulla of three months old age, Showing the distribution of elastic fibers.  
( Orcein stain X 500).



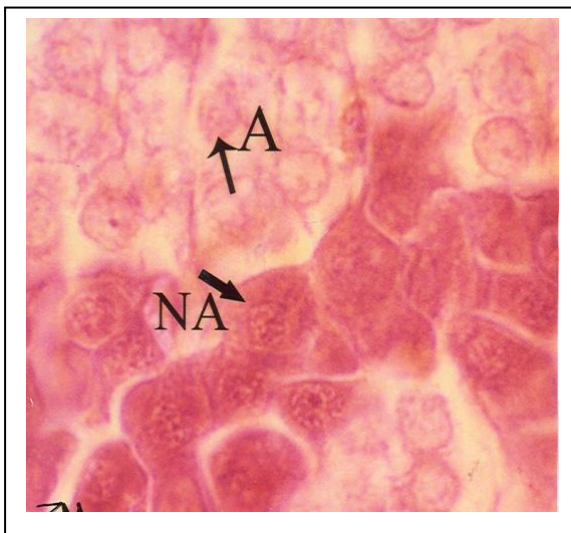
( Fig. 12) Photomicrograph of a section in the senile adrenal medulla , showing the distribution of elastic fibers.  
( Orcein stain X 500).



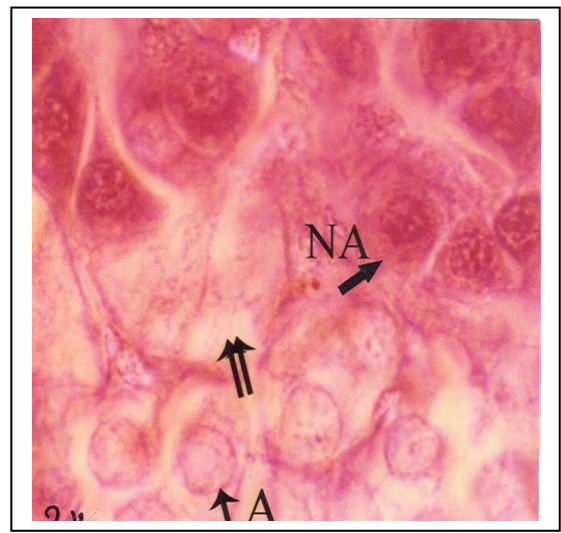
( Fig. 13) Photomicrograph of a section in the adrenal medulla of one week old age, showing ill differentiated chromaffin cells .  
( Wood stain X 500).



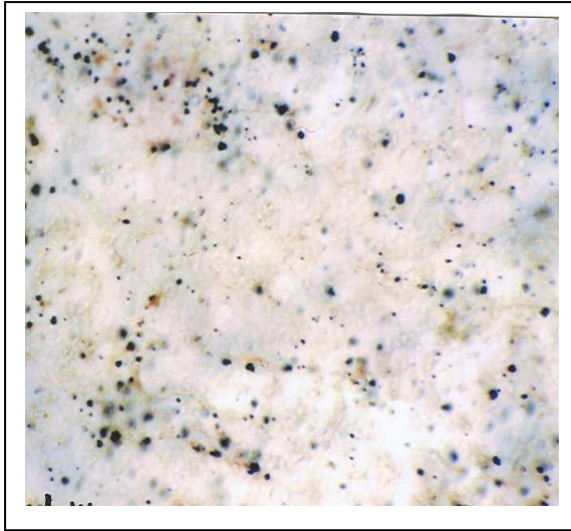
( Fig. 14) Photomicrograph of a section in the adrenal medulla of one month old age, showing more differentiated chromaffin cells .  
( Wood stain X 500).



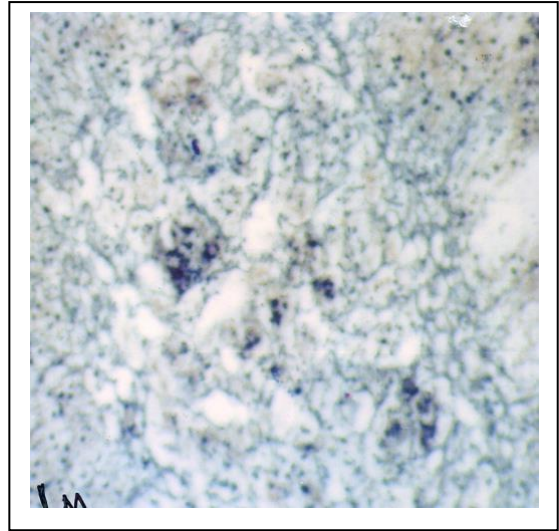
( Fig. 15) Photomicrograph of a section in the adrenal medulla of three months old age, showing more differentiated chromaffin cells .  
( Wood stain X 500).



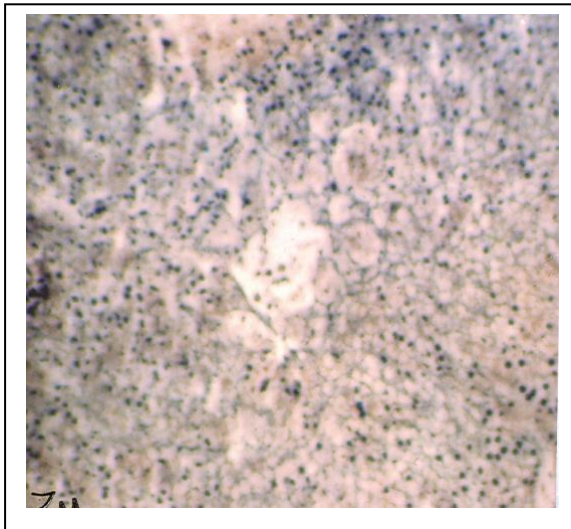
( Fig. 16) Photomicrograph of a section in the senile adrenal medulla , showing more differentiated chromaffin cells .  
( Wood stain X 500).



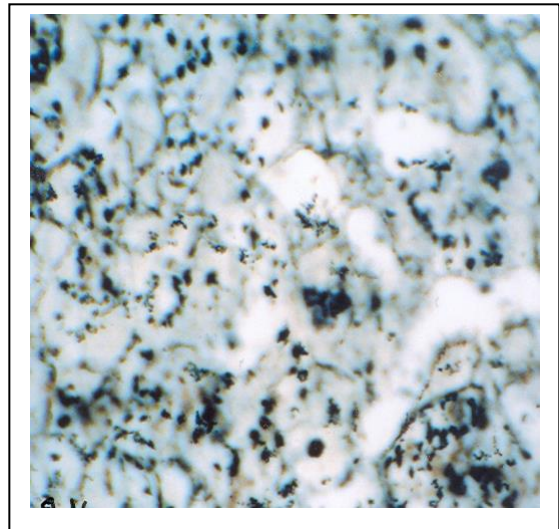
( Fig. 17) Photomicrograph of a section in the adrenal medulla of one week old age, showing ascorbic acid granules .  
( Silver nitrate X 500).



( Fig. 18) Photomicrograph of a section in the adrenal medulla of one month old age, showing ascorbic acid granules .  
( Silver nitrate X 500).



( Fig. 19) Photomicrograph of a section in the adrenal medulla of three months old age, showing ascorbic acid granules .  
( Silver nitrate X 500).

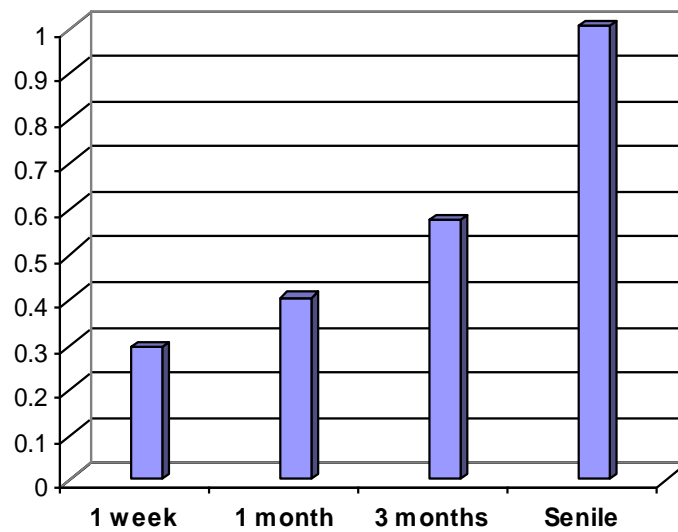


( Fig.20) Photomicrograph of a section in the senile adrenal medulla , showing ascorbic acid granules .  
( Silver nitrate ssX 500).



**(Table 1)** Changes in the mean volume of the adrenal medulla in the different post natal age groups.

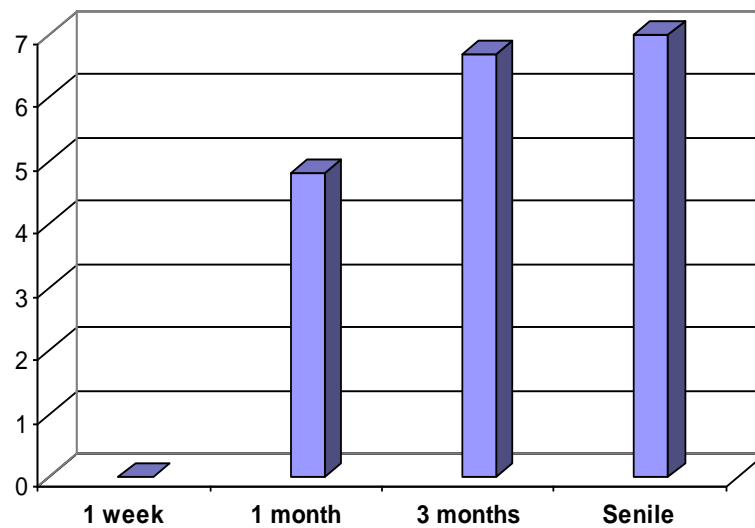
	<b>1 week</b>	<b>1 month</b>	<b>3 months</b>	<b>Senile</b>
<b>Mean volume</b>	0.29	0.4	0.57	1
<b>SD</b>	0.1	0.1	0.1	0.2
<b>SE</b>	0.1	0	0	0.07
<b>Comp. Groups</b>	<b>1 W: 3 Ms</b>	<b>1 M: 3Ms</b>	<b>control</b>	<b>S.: 3Ms</b>
<b>P value</b>	< 0.05	> 0.05	> 0.05	< 0.05
<b>Sig.</b>	<b>Sig. Increase</b>	<b>NS</b>	<b>NS</b>	<b>Sig. Increase</b>



**(Fig. 21)** Changes in the mean volume of the adrenal medulla in the different post natal age groups

**(Table 2)** Changes in the mean number of the nor adrenaline secreting cells in the different post natal age groups

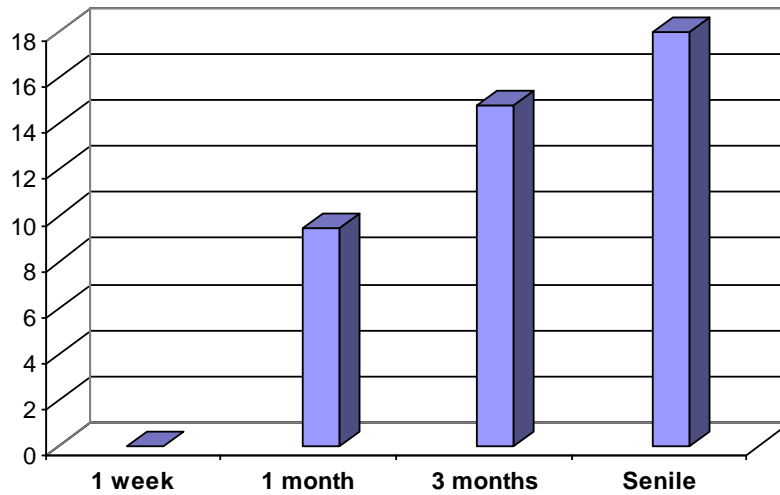
	<b>1 week</b>	<b>1 month</b>	<b>3 months</b>	<b>Senile</b>
<b>Mean number</b>	0	4.8	6.7	7
<b>SD</b>	0	0.56	0.28	0.4
<b>SE</b>	0	0.09	0.04	0.07
<b>Comp. Groups</b>	<b>1 W: 3 Ms</b>	<b>1 M: 3Ms</b>	<b>control</b>	<b>S.: 3Ms</b>
<b>P value</b>	<b>0</b>	<b>&gt; 0.05</b>	<b>0</b>	<b>&lt; 0.05</b>
<b>Sig.</b>	<b>NS</b>	<b>Sig. Increase</b>	<b>NS</b>	<b>NS</b>



**(Fig. 22)** Changes in the mean number of the nor adrenaline secreting cells in the different post natal age groups

**(Table 3)** Changes in the mean number of the adrenaline secreting cells in the different post natal age groups

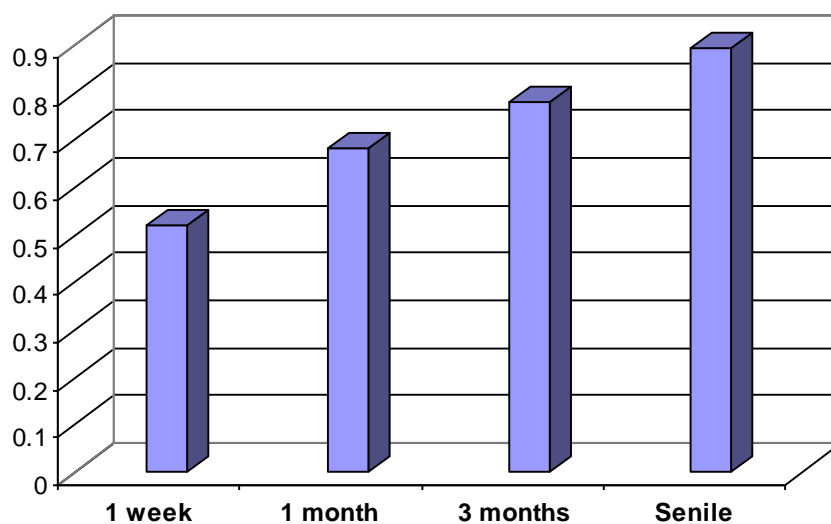
	<b>1 week</b>	<b>1 month</b>	<b>3 months</b>	<b>Senile</b>
<b>Mean number</b>	0	9.5	14.8	18
<b>SD</b>	0	0.14	0.028	0.42
<b>SE</b>	0	0.02	0.04	0.07
<b>Comp. Groups</b>	<b>1 W: 3 Ms</b>	<b>1 M: 3Ms</b>	<b>control</b>	<b>S.: 3Ms</b>
<b>P value</b>	<b>0</b>	<b>&gt; 0.05</b>	<b>0</b>	<b>&lt; 0.05</b>
<b>Sig.</b>	<b>NS</b>	<b>Sig. Increase</b>	<b>NS</b>	<b>Sig. Increase</b>



**(Fig. 23)** Changes in the mean number of the adrenaline secreting cells in the different post natal age groups

**(Table 4)** Changes in the mean optical density of vitamin C contents in the cells of adrenal medulla in the different post natal age groups

	<b>1 week</b>	<b>1 month</b>	<b>3 months</b>	<b>Senile</b>
<b>Mean OD</b>	0.52	0.68	0.78	0.89
<b>SD</b>	0.03	0.03	0.03	0.03
<b>SE</b>	0.01	0.01	0.01	0.01
<b>Comp. Groups</b>	<b>1 W: 3 Ms</b>	<b>1 M: 3Ms</b>	<b>control</b>	<b>S.: 3Ms</b>
<b>P value</b>	<b>&lt; 0.05</b>	<b>&lt; 0.05</b>	<b>&lt; 0.05</b>	<b>&lt; 0.05</b>
<b>Sig.</b>	<b>Sig. Increase</b>	<b>Sig. Increase</b>	<b>Sig. Increase</b>	<b>Sig. Increase</b>



**(Fig. 24)** Changes in the mean optical density of vitamin C contents in the cells of adrenal medulla in the different post natal age groups.

## DISCUSSION

Although many studies were carried out on the adrenal medulla, few literatures were available concerning the age-associated structural variations.

The white albino rat was the animal of our choice for its short post-natal life which enabled us to study the effect of aging on the adrenal medulla.

Various fixatives and stains were tried in this work to get the best results for both morphological and histochemical study on the adrenal medulla as well as the differentiation between adrenaline and nor adrenaline secreting cells of the medulla. The fixatives used were buffer formal saline or buffered potassium dichromate solution. (**Kiernan J.A., 2001**).

In this study it was observed that the growth curve showing increased volume gradually with age. This was in accordance with the study of **Jackson C.M., (1938)**. It was noticed that there are increased distribution of reticular fibers in the medulla of suprarenal gland especially at senile group. This observation is coincided with those observed by **Payne F. (1994)** who stated that both cortical and medullary cells were affected by fibrosis with advancing age.

The gland showed increased size as its mean volume was ( $3.35 \text{ mm}^3$ ) while the volume of the medulla was ( $0.29 \text{ mm}^3$ ).

There was ill differentiation between cortex and medulla. The medullary cells arranged either in groups and separated by blood sinusoids. The medullary cells become larger in size and well differentiated with advance in the age groups.

Rats of one month old age showed larger gland size and its mean volume was ( $5.29 \text{ mm}^3$ ). There is well differentiation between cortex and medulla. The medullary cells were arranged either in cords in most of the medulla or in groups in smaller areas of the medulla and separated by wide fenestrated blood sinusoid, the medullary cells become larger in size with larger nuclei and deep basophilic cytoplasm. These observations are in accordance with the study of **Payne F., (1994)**.

The fibrous elements in the gland becomes more distributed in the older age groups and such distribution was observed at the corticomedullary junction. Such fibrous change is the first age differentiation between two types of Chromaffin cells. The estimated number of adrenaline secreting cells per unit area ranged from 5 to 15 with mean 9.5. while the estimated number of nor adrenaline secreting cells per unit area ranged from 3 to 8. with mean 4.8.

Adrenal gland become larger in size at the adult age group so its mean volume was ( $8.82 \text{ mm}^3$ ) and there is sharp differentiation between cortex and the medulla. The volume of the medulla increased in size where the mean volume of the adrenal medulla at this age was ( $0.58 \text{ mm}^3$ ) such increase in size may be due to increase in the number of the medullary cells and the fibrous elements of the medulla. Such changes are in accordance with the study of **Payne F., (1994)**,

The ascorbic acid contents (vitamin c) showed moderate reaction in the medulla. The estimated number of adrenaline secreting cells per unit area ranged from 9 to 16 with mean 14.8 while the estimated number of nor adrenaline secreting cells per unit area ranged from 5 to 13 with mean 6.7. Such result goes hand in hand with observations of (**Hokfelt B., 1951**), (**Shefered and West 1955**), and (**Eranko and raisanen 1957**), They stated that the amount of Catecholamines steadily increased in the course of development.

In one month old age group albino rat the adrenaline and nor adrenaline percentages were 67% and 33% respectively so the ratio of adrenaline to nor adrenaline were 1.97:1. While in three months old age group the ratio of adrenaline to nor adrenaline increases in rat aged three month than in those aged one month from 1.97:1 to 2.2:1. This obtained data go hand in hand with that chemical observation of (**Shefered and West 1955**), in man, dog cat rabbit.

The adrenal gland in the senile age group was observed to be larger in size and there

is sharp differentiation between cortex and medulla. The volume of the medulla increases in size. Such increase in size may be due to increase in its vascularity and its fibrous elements in the medulla.

The medullary cells were well arranged mainly in anastomosing cords separated by wide fenestrated blood sinusoids the wide fenestrated blood sinusoids become larger in size and more congested with blood, The fibrous elements become more distributed than that of other groups, this was in accordance with the study of **Payne F., (1994)**, The ascorbic acid reaction becomes increased in the medulla.

However, the increase in the number of adrenaline cell is always going higher with age in contrast to the number of nor adrenaline cells .so the ratio of adrenaline to nor adrenaline cells reaches 2.57:1 in senile rat. Such observation is supported by the work of (**Hokfelt B., 1951**).

Although, the number of nor adrenaline cells increase with the progress of age, but it is not to the same extent as adrenaline cells ,which may be explained by the fact that the main source of nor adrenaline hormone is the nerve fibers (**bell et al., 1978**) and not the adrenal medulla. Also its little effect on the metabolic rate of animal (**Campbell et al., 1968**) beside the rats is not one of the aggressive animals which needs large amount of nor adrenaline hormone (**best and Taylor 1966**)

## REFERENCES

- 1- **Anderson D J, Axel R. A(1997)**: Potential neuroendocrine precursor whose choice Chromaffin cell Am J Anat. 47. 1079-1083.
- 2- **Backlund E., Granberg P and Sedvall G. (2003)**: Transplantation of the adrenal medulla to the striatum in parkinsonism, first clinical trials. J.Neurosurg. 169-173.
- 3- **Bancroft J D and Gamble A (2002)**:Theory and Practice of Histological Techniques. 4<sup>th</sup> Ed. pp 104-124.
- 4- **Bell J B , Gould R P , Hyatt P J ,Tait S A (1978)** :Properties of ratadrenal zona reticularis cells J.Endocrinol.,77(1):25-41.
- 5- **Bergstrom S , Von Euler U S and Hamberg,U.(1954)**:Isolation of noradrenaline from the adrenal gland. Acta Chem.Scand.3:305-310.
- 6- **Best C H and Taylor N B (1966)**:The physiological basis of medicalPractice, pp 1565-1571 8<sup>th</sup> ed.The William and Wilkins company, Baltimore.
- 7- **Campbel E J M , Dickinson C J and slater J D H (1968)**: Clinicalphysiology. pp 544-550 3<sup>rd</sup> ed.
- 8- **Carmiceal S W ( 1993)**: The adrenal medulla. PP 50-53. Eden. Press.
- 9- **Clayden E C (1971)**: Practical Section Cutting and Staining. 5<sup>th</sup> Edpp. 105-136. Churchill, Livingstone, Edinburgh and London.
- 10- **Don W F and Ronald P J (2002)**: Bloom & Fawcett Concise Histology. Chapman &Hall. International Thomson publishing. New York, Bonn, London, Paris, Tokyo and Madrid.
- 11- **Eranko O and Raisanen R.(1957)**: Morphology, physiology and molecular biology of catecholamines secretions. Physiol. Rev. 70:1067-1166.
- 12- **Gobran F.T.(1972)**: Quantitative study of the postnatal developmentof the adrenal gland. MD Thesis Ein Shams University.
- 13- **Goldmann (2000)**: Cecil Text Book of Medicine 21st ed. Chapter 28PP 1469- 1476. Saunders Company, Newhaven.
- 14- **Hokfelt B (1951)**: Selective depletion of the adrenaline content of the suprarenal gland by the injection of insulin in the cat. Acta physiol. Scand. 21: 858-862.
- 15- **Jackson C.M. (1938)**: Postnatal development of the suprarenalgland and the effects of inanition upon its growth and structure in the albino rat. Amer. J. Anat. 25: 201-215.
- 16- **Junqueira L C ; Caneiro J. And Kelley R. O. (2003)**: A Textbook of Histology. (10<sup>th</sup> Ed). Appleton & Lange. Asimon & Schuster Company.
- 17- **Kent C and Parker K Q (1993)**: Effects of ACTH and aminoglutethemide on the Catecholamines content and Chromaffine cell morphology of the adrenal medulla of the neonatal rat. Journal of anatomy, 183: 600-607.
- 18- **Kiernan J A (2001)**:Histological and Histochemical methods,Theoryand Practice.3<sup>rd</sup> Ed. pp111-113, 55-156, 90-293, Arnold, London, NewYork, New Delhi.
- 19- **Keith l and and Persaud T (1993)**: Developing human and clinicallyoriented embryology. 9<sup>th</sup> PP 279-281. London.
- 20- **Madrazo I. Drucker-Colin R.and Becerril J (1998)**: Open microsurgical auto graft to the right caudate nucleus in two patients with intractable Parkinson disease. New Eng. J. Med. 316: 831-839.
- 21- **Neville A and Hare M. (1982)** : The Human Adrenal Cortex.5<sup>th</sup> ed. PP 202-210. Springer-Verlage.
- 22- **Payne F (1994)**: Changes in the endocrine glands of the fowl with age. J. Gerontol. 4:193-199.
- 23- **Schneider W J (1990)** :Pathogenesis and patho-mechanism of coronary heart disease with familial hypercholesterolemia Cardiol. 79:3-7.
- 24- **Sokal R R and Rahif F. J.(1981)**: The Principles and Practical of Statistic in Biological Research. 2<sup>nd</sup> ed. free man, W.H. Company, San Francisco.

## دراسة كمية وهستوكيميائية لنخاع الغدة الفوق كلويه ( الكظرية ) في الجرذ الأمهق فى فترة ما بعد الولادة

وجيه كامل بيومي - عبدالموجود أنس - ممدوح عبدالحليم غالي - أشرف محمود مصطفى  
عاطف ابراهيم - وجيه منصور عبدالحى  
قسم الهستولوجى كلية الطب جامعة الازهر

يتكون نخاع الغدة الكظرية من نوعين من الخلايا المفترزة أحدهما يفرز الأدرينالين و الأخرى تفرز النورأدرينالين و يمكن التفرقة بين هذين النوعين لأختلاف تفاعلاتهما الصبغية و الأنزيمية. و قد تناولت أغلب الأبحاث السابقة على نخاع الغدة الكظرية الجوانب الهستوكيميائية و لم يركز البحث على الدراسة الكمية عن عدد هذه الخلايا و تأثير السن على الغده و على الحجم الكلى للنخاع. ولذلك تم اجراء هذه الدراسة الكمية و الهستوكيميائية لنخاع الغدة الكظرية لتقييم مدى تغير حجم النخاع فى مراحل العمر المختلفة.

و قد اجرى هذا البحث على عدد ستون من ذكور الجرذان حيث تم تقسيمهم حسب اعمارهم الى أربع مجموعات متساوية بكل منها خمسة عشر جرذاً.

– المجموعة الأولى واشتملت على جرذان عمرها سبعة ايام .

– المجموعة الثانية واشتملت على جرذان عمرها شهر .

– المجموعة الثالثة واشتملت على جرذان بالغة عمرها ثلاث شهور.

– المجموعة الرابعة واشتملت على جرذان مسنه عمرها سنه و نصف.

وقد تم تحضير القطاعات الشمعية حيث استخدمت المحاليل المثبتة للعينات المناسبة وصبغت بالصبغات المناسبة المختلفة لأظهار التركيب الخلوى لنخاع الغدة الكظرية وكذلك توزيع الألياف الكولونجية والمرنة فى المجموعات المختلفة للبحث . وقد أستخدم جهاز التحليل الضوئى وامتصل بالكمبيوتر لتحديد القياسات الكمية و التى عولجت نتائجها إحصائياً.

### نتائج البحث :

يزداد وزن الغده زياده طرديه مع زياده وزن الجسم مع تقدم العمر.

وفى الجرذان البالغه من العمر اسبوع واحد امكن قياس حجم النخاع وكانت هناك صعوبة فى التفرقه بين الخلايا وعددها.

أما الجرذان البالغه من العمر شهر واحد وجد زياده فى حجم النخاع , تركيز النسيج الضام وكذلك حمض الأسكوربيك . كما امكن عد الخلايا المفترزة احدهما يفرز الأدرينالين و الأخرى تفرز النورأدرينالين و أمكن التفرقة بين هذين النوعين بصبغة "وود" متزنه التفاعل.

وفى مجموعة الجرذان البالغه من العمر ثلاثه اشهر وجد أن هناك زياده فى حجم النخاع , تركيز فى النسيج الضام , حمض الأسكوربيك . وكذلك الخلايا المفترزة للأدرينالين و النورأدرينالين.

ودلت النتائج فى مجموعة الجرذان البالغه المسنة أن هناك زياده فى حجم النخاع , زياده فى تركيز النسيج الضام , حمض الأسكوربيك . وكذلك الخلايا المفترزة للأدرينالين و النورأدرينالين.

وبمقارنه أعداد الخلايا فى الأعمار المختلفه بجرذان المجموعة البالغه(ثلاثه اشهر) وجد انها فى إزدیاد مستمر وأن الخلايا المفترزة للأدرينالين و النورأدرينالين فى إزدیاد مستمر مع تقدم العمر وأن هذه الزياده ذو دلالة إحصائية.

كذلك وجد أن حجم نخاع الغدة الكظرية فى إزدیاد مستمر مع تقدم العمر.

كذلك دلت الدراسة أن الزياده فى عدد الخلايا المفترزة للأدرينالين يفوق الزياده فى عدد الخلايا المفترزة للنورأدرينالين.

وتدل الدراسة عن مدى التغيير فى التركيب الميكروسكوبى لنخاع الغدة الكظرية فى المجموعات المختلفه وكذلك عدد خلاياها المفترزة وعلاقة ذلك بالتقدم فى العمر.