*Original Paper***Protective effect of Quercetin compared to Silymarin against Phenylhydrazine induced anemia**

Rania M. Baker, Fatma A. Gad, Khaled M. Fararh

Clinical Pathology Department, Faculty of Veterinary Medicine, Benha University

**ARTICLE INFO****Keywords**

*Antioxidant*  
*Hemolytic Anemia*  
*Phenylhydrazine*  
*Quercetin*  
*Silymarin*

*Received* 02/03/2021*Accepted* 20/03/2021*Available On-Line*

01/04/2021

**ABSTRACT**

This study has developed to evaluate the protecting effect of Quercetin in phenylhydrazine (PHZ) induced hemolytic anemia comparing to traditional used antioxidant (Silymarin). For that 45 male white Albino rats were randomly allocated into 5 groups, control group, PHZ group which was injected by PHZ (20 mg/kg b.w, I/P at day 7<sup>th</sup>, 8<sup>th</sup> and 9<sup>th</sup>), Quercetin + PHZ group (Quercetin, 50 mg/kg b.w per os every day for 16 days), silymarin + PHZ group (Silymarin, 100 mg/kg b.w per os every day for 16 days) and Quercetin group. Serum samples of all groups were collected after 3, 5 and 10 days after injection of PHZ and used for biochemical and oxidative stress analysis. Also, specimens from spleen were collected for histopathological examination. The results of this study showed that, Quercetin ameliorated PHZ effect on total protein, total bilirubin, direct and indirect bilirubin, LDH, iron and ferritin levels. Also, Quercetin improved levels of oxidative stress parameters GSH, SOD and MDA, and had protective effect on tissue of spleen. Therefore, Quercetin had protective effect in experimental PHZ-induced hemolytic anemia. Also, it was more potent antioxidant than Silymarin.

**1. INTRODUCTION**

Oxidative stress is the main reason convoluted in the incidence of several cardiovascular diseases such as hypoxia and hypertension (Wilcox and Gutterman, 2005). Phenylhydrazine (PHZ) is a powerful oxidant, which is widely used as an antipyretic. It is known to shorten the lifespan of RBCs leading to severe hemolytic anemia, enhanced iron absorption and tissue iron over-loading (El-Tantawy and Temraz, 2009). Its oxidation induces generation of reactive oxygen species (ROS) and generation of a fancy number of derived radicals, like phenyldiazene, phenylhydrazyl radical and benzenediazonium ions (Nakanishi et al., 2003). Flavonoids are recognized to possess a well-established defending effect against membrane lipoperoxidative damages (Zhang et al., 2011). The phenols and flavonoids antioxidant activity is principally attributed to their redox properties because they act as singlet oxygen quenchers, electron/hydrogen donators and reducing agents (Bigoniya et al., 2013). Quercetin is a flavonolic plant from the flavonoid group of polyphenols. It found in several fruits and vegetables. It is characterized by a bitter flavor and used as one of ingredients in dietary supplements (Brüll et al., 2015). Quercetin has been shown in many studies as a potent antioxidant with a very powerful free radical scavenging ability. It has been reported to increase antioxidative defense system by up controlling antioxidant enzymes (Liu et al., 2012). Also, it possesses many pharmacological activities such as immunostimulatory and anti-inflammatory effects (Abdelmoaty et al., 2010). Silymarin effects have been

showed in various illnesses of different organs (Gazak et al., 2007). Besides anti-inflammatory, antifibrotic and immune-modulating effects of Silymarin, it has antioxidant properties by scavenging free radicals and enhancing the glutathione concentrations (WenWu et al., 2009). Therefore, our study was planned to evaluate the protective effect of Quercetin in PHZ-induced anemia comparing to Silymarin through serum biochemical and oxidative stress analysis and histopathological examination of spleen.

**2. MATERIAL AND METHODS***2.1. Animals*

The existing study was distributed on a complete number of 45 male Albino rats (180-210 gm body weight) obtained from the Animal House, Faculty of Veterinary Medicine, Benha University, Egypt. They were housed for one week within the same environmental and nutritional conditions almost like those under which the experiment was performed for accommodation. Rats were haphazardly allocated into five groups and held in separate cages. Each group of rats was provided by suitable diet and water ad libitum. The study performed with approval from the institutional review board for experiments of Faculty of Veterinary Medicine, Benha University

*2.2. Chemicals and diagnostic kits*

- Phenylhydrazine was obtained in the form of powder from Company of Sigma- Aldrich Chemical: st Louis, MO, USA.
- Quercetin powder was obtained from Company of Sigma- Aldrich Chemical: st Louis, MO, USA.

\* Corresponding author: Rania M. Baker, mariam162010@yahoo.com

- Silymarin (Legalon® 70 mg) was obtained from CID, Giza, Egypt.
- Diagnostic kits for total proteins, total bilirubin and direct bilirubin, lactate dehydrogenase, iron and ferritin were obtained from Qumica Clinica Alpicada (QCA) (Spain).
- The diagnostic kits for GSH, SOD and MDA were obtained from Caymon, Chemical: Ann Arbor, Michigan, (USA).
- The formalin 10% solution for preservation of spleen tissues was obtained from El-Gomhoria Company for chemicals and laboratory supplies.

### 2.3. Induction of hemolytic anemia

Phenylhydrazine solution was prepared in sterilized water and intraperitoneally injected (I/P) in a dose of (20 mg/kg body weight). PHZ solution was prepared and used as stated by method of Moreau et al. (2012) with some modification.

### 2.4. Treatment of hemolytic anemia

Quercetin powder was given orally by gastric gavage at a daily dose of 50 mg/kg body weight according to method of Luangaram et al. (2007). While, Silymarin was given orally by gastric gavage at a daily dose of 100 mg/kg body weight according to El-Tantawy and Temraz (2009).

### 2.5. Experimental design

Rats were distributed into 5 equal groups, Group (1): control group: received 1ml sterile distilled water /kg body weight by intraperitoneal injection daily for 16 days. Group (2): PHZ group: injected with PHZ (20 mg/kg body weight) intraperitoneally on day 7 for day 9. Group (3): PHZ + Quercetin group: given Quercetin 50 mg/kg body weight per os daily for 16 days and injected with PHZ (20 mg/kg body weight) intraperitoneally on day 7 for day 9. Group (4): PHZ + Silymarin group: given Silymarin (Legalon 70 mg) 100 mg/kg body weight per os daily for 16 days and injected with PHZ (20 mg/kg body weight) intraperitoneally on day 7 for day 9. Group (5): Quercetin group: given Quercetin 50 mg/kg body weight per os daily for 16 days.

### 2.6. Samples collection

Blood samples were collected by capillary tube from retroorbital venous plexus on plain tubes for serum separation from 3 rats from each group at the day 3, 5 and 10 after the first injection of PHZ. For histopathological examination small tissue specimens were collected from spleen fixed in 10 % formol saline solution.

### 2.7. Serum biochemical examination

Biochemical examinations included measurement of total proteins, total bilirubin and direct bilirubin, lactate dehydrogenase, iron and ferritin values was carried out according to methods of Christine and Roger (2015), Defreese et al. (1984), Stentz et al. (2010), Burtis and Ashoowd (1986) and Thorpe et al. (2008) respectively.

### 2.8. Measuring oxidative stress

GSH, SOD and MDA activities as indices of enzymatic and non-enzymatic antioxidant status were determined according to methods of Moron et al. (1979), Marklund and Marklund (1974) and Esterbauer and Cheeseman (1990) respectively.

### 2.9. Histopathological examination

After proper fixation, tissue paraffin sections were routinely prepared. These sections were stained with

hematoxylin and eosin stain for microscopic examination, in addition prussian blue staining technique was carried out for demonstration of hemosiderin pigment according to methods described by Bancroft et al. (1996).

### 2.10. Statistical Analysis

Statistical Package for Social Science: SPSS Inc. Chicago, IL, USA) statistical program release (16.0) was used for data analysis. For differentiation between 2 experimental groups, it was used Student's *t*-test. One-way analysis of variance (ANOVA) was used for analysis the significance of differences between more than two groups and *P*-value <0.05 was considered significant.

## 3. RESULTS

The recorded data of serum biochemical analysis are presented in figures (1 to 7). Significant decrease was recorded in total protein level in PHZ group when compared to control group at 1<sup>st</sup> and 3<sup>rd</sup> chick points. In contrast, there were significant increases in total bilirubin, direct bilirubin, indirect bilirubin and LDH at 1<sup>st</sup>, 2<sup>nd</sup> and 3<sup>rd</sup> chick points. Comparing to PHZ group, Quercetin + PHZ group showed significant increase in total protein level at 3<sup>rd</sup> chick point with significant decreases in total bilirubin, direct bilirubin, indirect bilirubin and LDH levels at 1<sup>st</sup>, 2<sup>nd</sup> and 3<sup>rd</sup> chick points. Silymarin + PHZ group showed significant increase in total protein level at 2<sup>nd</sup> and 3<sup>rd</sup> chick points comparing to PHZ group at 1<sup>st</sup> chick point with significant decreases in total bilirubin, direct bilirubin, indirect bilirubin and LDH levels at 1<sup>st</sup>, 2<sup>nd</sup> and 3<sup>rd</sup> chick points. Comparing with Silymarin + PHZ group, there were significant increases in total protein, total bilirubin and direct bilirubin levels in Quercetin + PHZ group at 1<sup>st</sup> chick point. While there was significant decrease in LDH level at 1<sup>st</sup> and 2<sup>nd</sup> chick points. Quercetin group showed non-significant changes in total bilirubin, direct bilirubin, indirect bilirubin and LDH levels at 1<sup>st</sup>, 2<sup>nd</sup> and 3<sup>rd</sup> chick points. Moreover, there was a significant decrease in total protein level comparing to control group at 1<sup>st</sup> chick point. While, there was significant increase at 2<sup>nd</sup> and 3<sup>rd</sup> chick points. Regarding to serum iron and ferritin levels changes, PHZ group showed significant increases in their levels at 1<sup>st</sup>, 2<sup>nd</sup> and 3<sup>rd</sup> chick points when compared to control group. Comparing to PHZ group, Quercetin + PHZ group showed significant decreases in iron and ferritin levels at 1<sup>st</sup>, 2<sup>nd</sup> and 3<sup>rd</sup> chick points also, Silymarin + PHZ group showed significant decreases in iron and ferritin levels at 1<sup>st</sup>, 2<sup>nd</sup> and 3<sup>rd</sup> chick points. Comparing Quercetin + PHZ group to Silymarin + PHZ group, there were significant decreases in iron and ferritin levels at 3<sup>rd</sup> chick point. Quercetin group showed no significant changes in iron and ferritin levels at 1<sup>st</sup>, 2<sup>nd</sup> and 3<sup>rd</sup> chick points comparing to control group.

The results of GSH, SOD and MDA levels measurement was showed in figures (8 to 10) revealed that PHZ group showed significant decreases in GSH and SOD levels when compared to control group with significant increase in MDA level at 1<sup>st</sup>, 2<sup>nd</sup>, and 3<sup>rd</sup> chick points. Comparing to PHZ group, Quercetin + PHZ group showed significant increases in GSH and SOD levels while, there was a significant decrease in MDA level at 1<sup>st</sup>, 2<sup>nd</sup> and 3<sup>rd</sup> chick points. Furthermore, Silymarin + PHZ group showed significant increase in GSH levels at 3<sup>rd</sup> chick point comparing to PHZ group.

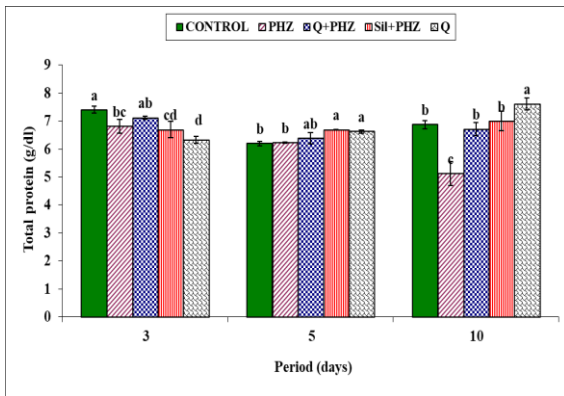


Fig. 1 Total protein changes after 3, 5 and 10 days of injection of phenylhydrazine

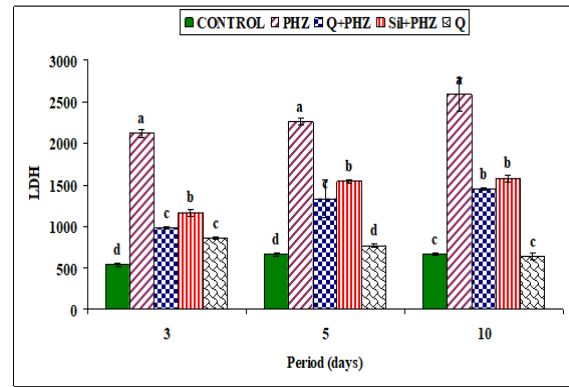


Fig. 5 LDH changes after 3, 5 and 10 days of injection of phenylhydrazine

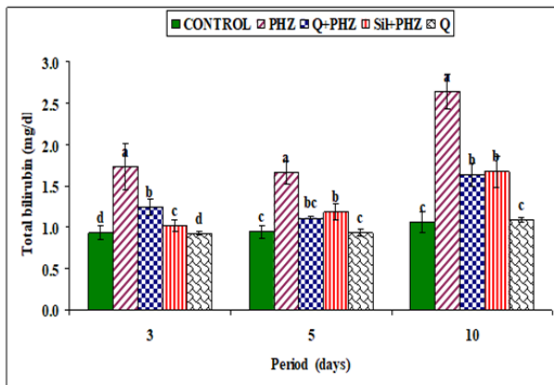


Fig. 2 Total bilirubin changes after 3, 5 and 10 days of injection of phenylhydrazine

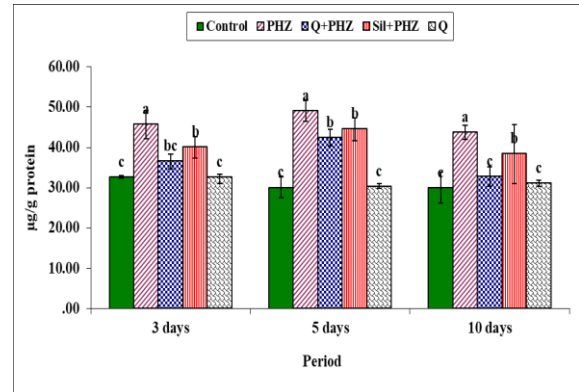


Fig. 6 Iron changes after 3, 5 and 10 days of injection of phenylhydrazine

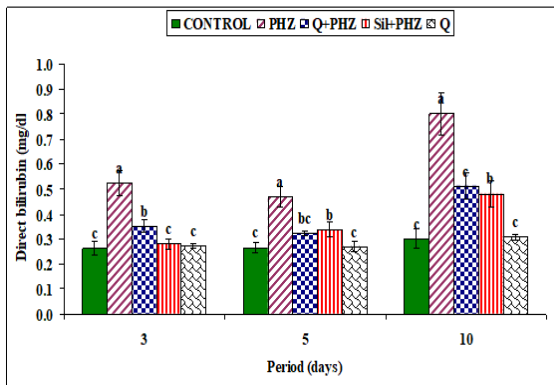


Fig. 3 Direct bilirubin changes after 3, 5 and 10 days of injection of phenylhydrazine

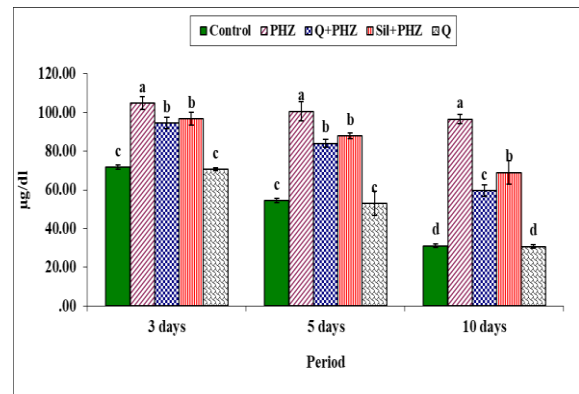


Fig. 7 Ferritin changes after 3, 5 and 10 days of injection of phenylhydrazine

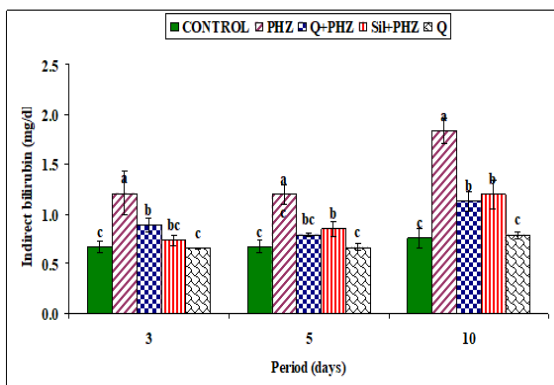


Fig. 4 Indirect bilirubin changes after 3, 5 and 10 days of injection of phenylhydrazine

Comparing Quercetin + PHZ group to Silymarin + PHZ group, there was a significant increase in GSH level at 1<sup>st</sup>, 2<sup>nd</sup> and 3<sup>rd</sup> chick points. Also, there was a significant increase in SOD level at 1<sup>st</sup> and 2<sup>nd</sup> chick points. Furthermore, there was a significant decrease in MDA level at 2<sup>nd</sup> and 3<sup>rd</sup> chick points. Quercetin group showed no significant changes in GSH and MDA levels at different chick points while there was a significant decrease at MDA level at 1<sup>st</sup> chick point.

Histopathological examination of the splenic tissue stained with H&E showed no histological alterations with normal white and red pulp in control group while, PHZ group showed severe congestion of red pulp and lymphoid depletion. Also, proliferation of fibrous reticular cells and marked hemosiderin pigment deposition within the red pulp were detected. Quercetin + PHZ group showed mild congestion and hemosiderosis within the red pulp with normal intact lymphoid follicles. Silymarin + PHZ group

showed minimal congestion within the red pulp and normal lymphoid follicles.

Quercetin group showed no histopathological alterations with normal white and red pulp (fig. 11). Prussian blue staining of spleen showed mild hemosiderin pigment deposition within the red pulp in control group. While, there was marked hemosiderosis in PHZ group. Quercetin + PHZ group showed marked decrease in hemosiderosis also, Silymarin + PHZ group showed marked decrease in hemosiderin pigment deposition within the red pulp of spleen. Quercetin group showed slight hemosiderin pigment deposition within the red pulp of spleen (fig. 12).

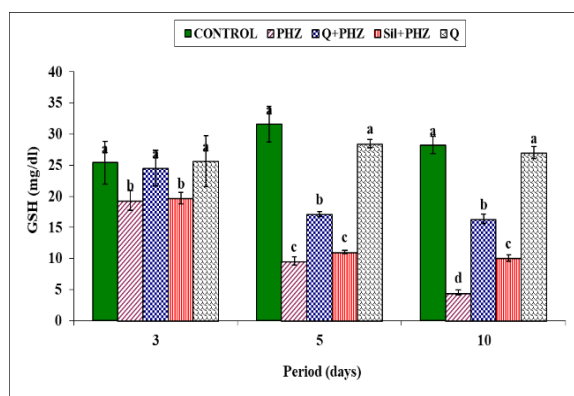


Fig. 8 GSH changes after 3, 5 and 10 days of injection of phenylhydrazine

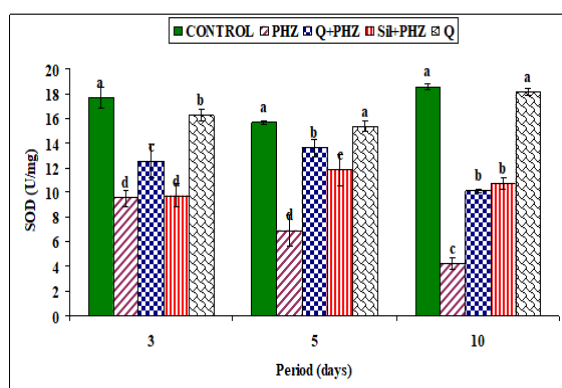


Fig. 9 SOD changes after 3, 5 and 10 days of injection of phenylhydrazine

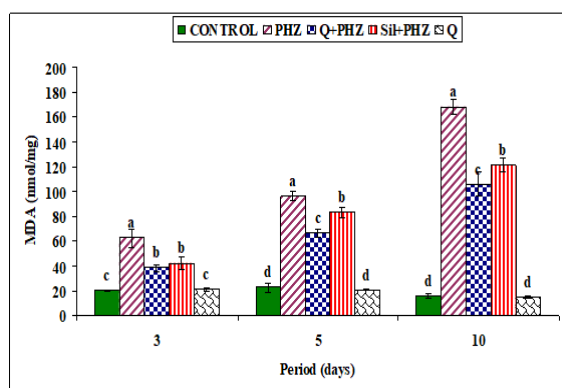


Fig. 10 MDA changes after 3, 5 and 10 days of injection of phenylhydrazine

#### 4. DISCUSSION

Developing medicinal agents from natural ingredients has sparked global interest and triggered a new surge of research into the healthy benefits of herbal medicine. Quercetin, one of the most common flavonoids which has been commonly linked with a significant range of several health benefits (Zhang et al., 2011). Regarding serum biochemical changes, PHZ group showed a significant decrease in total protein level comparing to control group while, there was significant increase in total bilirubin, direct bilirubin, indirect bilirubin and LDH. These results agree with El-Tantawy and Temraz, (2009), Zangeneh et al. (2019) and Ayoade et al. (2020). The significant reduction in the serum protein level may be a result of an impaired liver function. The liver cleared hemolytic products from the blood, but hemolysis once occurs at a very rapid rate, it may possibly lead to liver stress (Chakrabarti et al., 1990). It is well known that, acute hemolysis leads to a substantial increase in bilirubin and impaired production/conjugation of bilirubin (Mejia et al., 2007). In addition, LDH is an enzyme that catalysis the conversion of lactate to pyruvic acid, located in cytoplasm, and distributed in various organs. LDH-1 and LDH-2 isoenzymes are expressed in RBC. In hemolytic conditions, LDH (mainly isoenzymes 1 and 2) is often increased and may be useful for distinguishing extravascular as opposed to intravascular hemolysis (Barcellini and Fattizzo, 2015). Comparing to PHZ group, Quercetin + PHZ group showed improvement in serum biochemical parameters induced by PHZ induction. These results were in agreement with these reported by Selvakumar et al. (2013), who found that Quercetin administration improved total protein levels in rats exposed to oxidative stress. Also, Olayinka et al. (2014) found that Quercetin administration decrease total bilirubin level comparing to Melphalan-induced oxidative stress in rats. Furthermore, Ahmed et al. (2019) reported that level of LDH improved with administration of Quercetin. As Quercetin showed valuable effects on liver damage by improving antioxidant enzyme activity and decreasing pro-oxidant effect. This is due to ability of Quercetin to interact with hydroxyl, superoxide, alkoxyl and peroxy radicals subsequently scavenging them (Amália et al., 2007). Also, Silymarin + PHZ group improve serum biochemical parameters changed by PHZ induction. These results agree with Mahmoud et al. (2019) who they found that administration of Silymarin significantly improved serum total protein and total bilirubin levels. Also, our results agree with Pradeep et al. (2007) who found that Silymarin administration improved LDH serum level, this might be due to the protecting effect of silymarin on the cellular membranes. Quercetin group showed no significant changes in total bilirubin, direct bilirubin, indirect bilirubin and LDH levels. There was significant decrease in total protein level comparing to control rats at 1<sup>st</sup> chick point. While, there was significant increase at 2<sup>nd</sup> and 3<sup>rd</sup> chick points. These results were agree with Selvakumar et al. (2013), who reported that administration of Quercetin showed no significant changes in total bilirubin. Also, our results agree with Olayinka et al. (2014) who reported that administration of Quercetin showed significant increase in total protein levels and owing that to immune-stimulatory effect of it. Regarding to serum iron and ferritin levels changes, PHZ group showed significant increases in their values comparing to control group.



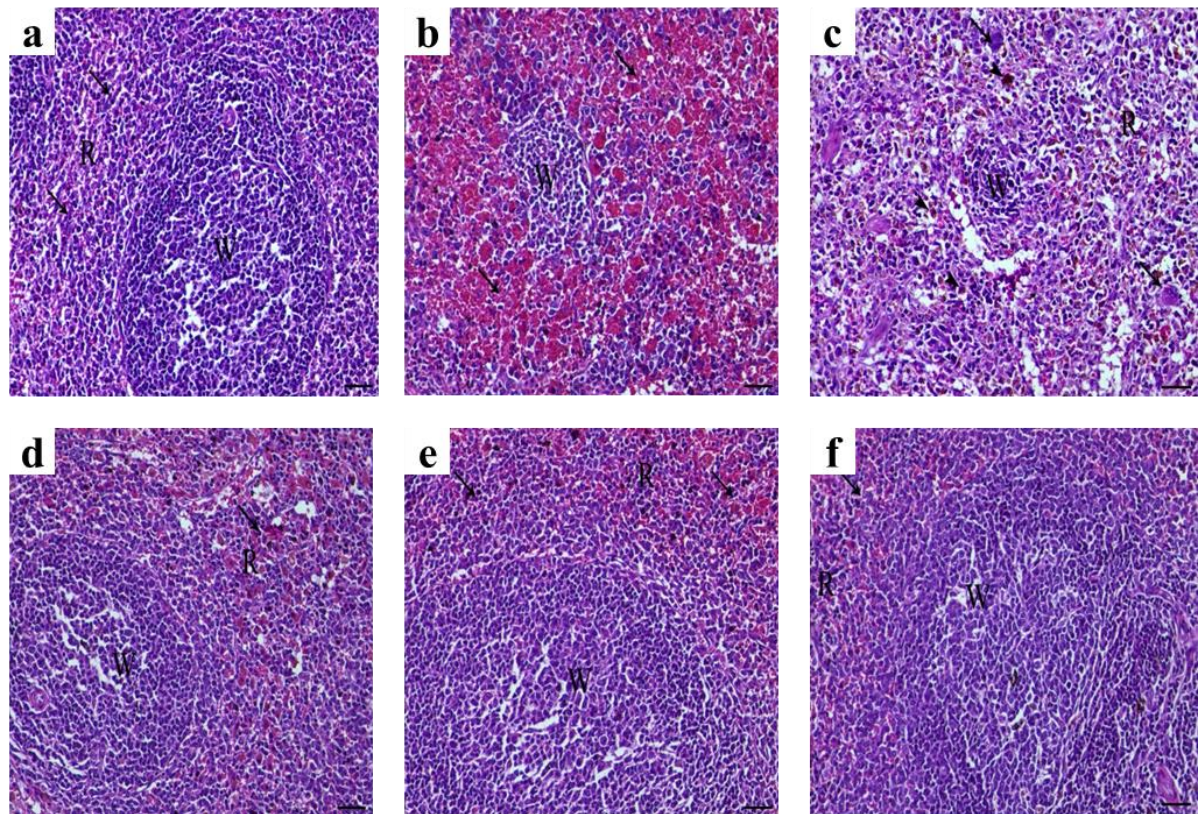


Fig. 11 (a) Spleen of control group showing normal white pulp containing large number of lymphocytes around the central arterioli and normal red pulp containing blood capillaries (arrow). (b) Spleen of PHZ group showing severe congestion of red pulp and lymphoid depletion (arrows indicate severe congestion of the blood capillaries within the red pulp). (c) Spleen of PHZ group showing severe degree of lymphoid depletion and marked hemosiderin pigment deposition within the red pulp (arrowheads) associated with extramedullary hematopoiesis features (arrows). (d). Spleen of Quercetin + PHZ group showing marked decrease of both congestion and hemosiderosis within the red pulp (arrow) and normal lymphoid follicle. (e). Spleen of Silymarin + PHZ group showing minimal congestion within the red pulp (arrow) and normal lymphoid follicle. (f) Spleen of Quercetin group showing normal white pulp and red pulp (arrow indicates the blood capillaries within red pulp). Staining, H&E, magnification X200, bar= 50  $\mu$ m. (W letter indicates white pulp and R letter indicates red pulp)

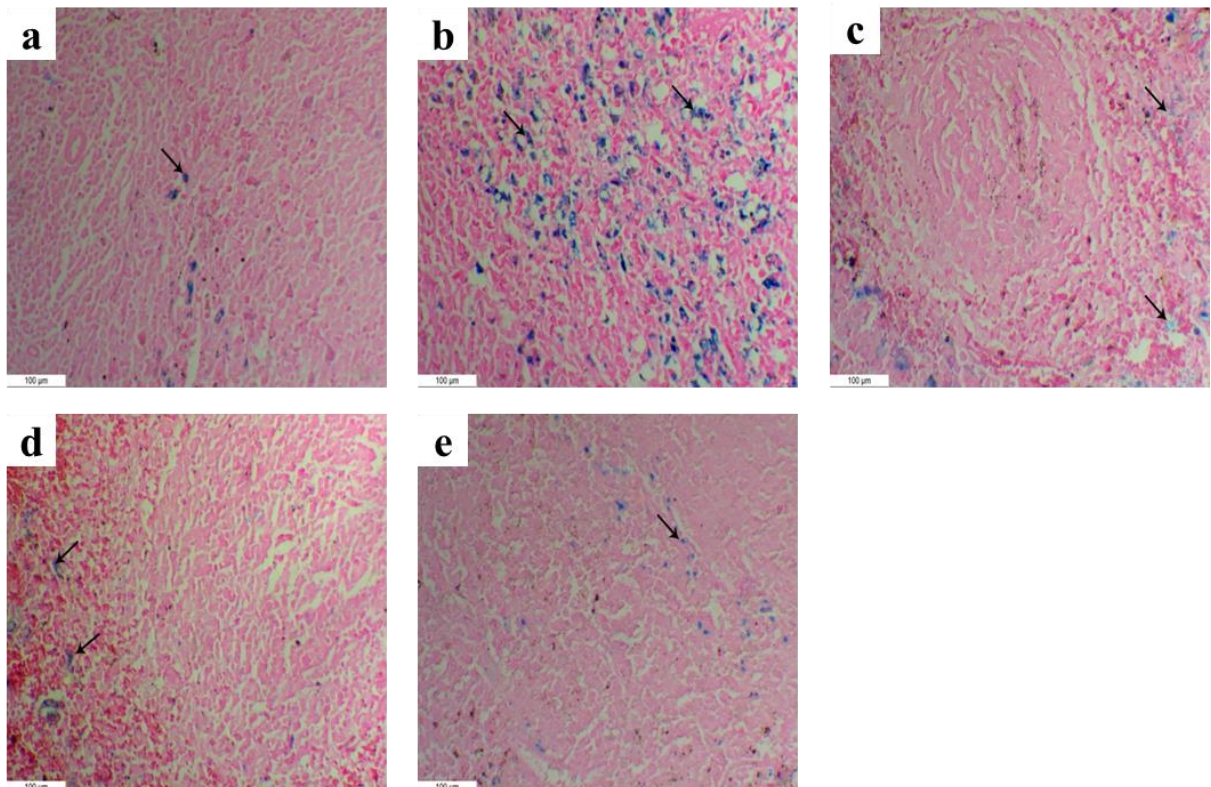


Fig. 12 (a) Spleen of control group showing mild hemosiderin pigment deposition within the red pulp (arrow). (b) Spleen of PHZ group((20 mg/kg b. w, I/P at day 7th, 8th and 9th) showing marked hemosiderosis within the red pulp (arrows). (c) Spleen of Quercetin + PHZ group (Quercetin, 50 mg/kg b. w per Os every day for 16 days) showing marked decrease hemosiderin pigment deposition within the red pulp (arrows) (d) Spleen of Silymarin + PHZ group (Silymarin, 100 mg/kg b. w per Os every day for 16 days) showing marked decrease hemosiderin pigment deposition within the red pulp (arrows). (e) Spleen of Quercetin group showing slight hemosiderin pigment deposition within the red pulp (arrow). Staining: Prussian blue, magnification: X200, bar= 100  $\mu$ m.

These results agree with Zangeneh et al. (2019). Conard et al. (1964) who mentioned that injection of PHZ into rats induced a hemolytic anemia and sequential changes in iron metabolism tests. The greater quantities of iron released from destroyed red blood cells primarily caused hyperferremia. Also, iron released from hemoglobin of phagocytosed erythrocytes is stored in ferritin and finally converted to hemosiderin afterward stored in the spleen which explained the increase of serum ferritin levels (Saito, 2014), this explained marked hemosiderosis in spleen and sever congestion in red pulp of it. Comparing to PHZ group, Quercetin + PHZ group improved iron and ferritin serum levels. Our results agree with Comporti et al. (2002) who found that the Quercetin addition led to marked protection against lipid peroxidation and hemolysis. Quercetin defense appears to be due to intracellular chelation of iron, as a semi-stoichiometric ratio between the amount of iron released and the amount of Quercetin required to prevent lipid peroxidation and hemolysis has been observed (Ferrali et al., 1997). Silymarin + PHZ group showed significant decrease in iron and ferritin levels. Our results agree with Hagag et al. (2015) who found that Silymarin administration intensely decreased ferritin and iron serum levels. Moayedi et al. (2013) has been reported that Silymarin could act as iron chelating agents and this was confirmed by histopathological examination of splenic tissue which showed mild congestion and hemosiderin deposition in both previous groups. Quercetin group showed no significant changes in iron and ferritin levels. GSH play an important role in protection alongside damage caused by oxidizing environments (Jakoby and Ziegler, 1990). Superoxide dismutase (SOD) is the one of greatest known enzymatic antioxidant, which it catalyzes the dismutation of superoxide radical ( $\bullet\text{O}_2$ ) into hydrogen peroxide ( $\text{H}_2\text{O}_2$ ) (Pandey and Rizvi, 2011). Malondialdehyde (MDA) is a main product of lipid peroxidation. The successive formation of PUFA hydroperoxide and  $\beta$  cleavage is the alternative mechanism for MDA generation and the main source of MDA generation in vivo. (Esterbauer and Cheeseman, 1990). Concerning to oxidative stress changes, PHZ group showed a significant decrease in GSH and SOD levels with significant increase in MDA comparing to control group. These results were in agreement with Bansode et al., (2019). Also, Ashour, (2014) reported that phz induced significant decrease in GSH level. As PHZ induced increases in reactive oxygen species (ROS) and lipid peroxidation with decreasing glutathione (GSH). Comparing to PHZ group, Quercetin + PHZ group showed improvement in GSH, SOD and MDA levels. These results agree with Luangaram, (2007), who found that Quercetin administration ameliorate effect of PHZ on GSH and MDA levels as Quercetin could lessen some of the toxic effect of PHZ by putting out many types of PHZ-resultant free radicals. Furthermore, Silymarin + PHZ group showed improvement in SOD and MDA levels also, GSH level only at 3<sup>rd</sup> chick point. These findings were in agreement with Pradeep et al. (2007) who informed that Silymarin ameliorate oxidative stress through restoration of lipid peroxidation. It may be due to its capability to scavenge reactive oxygen sorts as well as preventing extra damage to membrane lipids Ramakrishnan et al. (2006). Quercetin group showed no significant changes in GSH and MDA levels comparing to control group with significant decrease in SOD level only at 1<sup>st</sup> chick point. These results were in accordance with Abarikwu (2014), who reported that Quercetin administration showed no significant changes in serum oxidative markers. Also, Olayinka et al. (2014)

reported that administration of Quercetin significantly decrease SOD level, and this may be owed to stress.

## 5. CONCLUSIONS

Quercetin is a powerful antioxidant and has more protective effect than Silymarin. So, the present study suggests that Quercetin has beneficial effects against hemolytic anemia induced by phenylhydrazine.

## 6. REFERENCES

1. Abarikwu, S.O. 2014. Protective Effect of Quercetin on Atrazine-Induced Oxidative Stress in the Liver, Kidney, Brain, and Heart of Adult Wistar Rats. *Toxicology International* 21(2), 148-155.
2. Abdelmoaty, M.A., Ibrahim, M., Ahmed, N., Abdelaziz, M. 2010. Confirmatory studies on the antioxidant and antidiabetic effect of quercetin in rats. *Indian Journal of Clinical Biochemistry* 25, 188-92.
3. Ahmed, Z.A., Abtar, A.N., Othman, H.H., Aziz, T.A. 2019. Effects of quercetin, sitagliptin alone or in combination in testicular toxicity induced by doxorubicin in rats. *Drug Design, Development and Therapy* 13, 3321-3329.
4. Amália, P.M., Possa, M.N., Augusto, M.C., Francisca, L.C. 2007. Quercetin prevents oxidative stress in cirrhotic rats," *Digestive Diseases and Sciences* 52(10), 2616-2621.
5. Ashour, T.H. 2014. Hematinic and anti-anemic effect of Thymoquinone against phenylhydrazine-induced hemolytic anemia in rats. *Research Journal of Medical Sciences* 8(2), 67-72.
6. Ayoade, A.A., Ogunware, A.E., Odekunle, I.I., Adedigba, P.A. 2020. Effects of Aqueous Colocasia esculenta Extracts on Selected Biochemical Parameters in Phenyl Hydrazine Induced Male Anemic Albino Rats. *Asian Journal of Biochemistry, Genetics and Molecular Biology* 3(4), 13-23.
7. Bancroft, J.D., Stevens, A., Turner, D.R. 1996. *Theory and Practice of Histological Techniques*. 4th ed., Churchill, Livingston, New York, London, San Francisco, Tokyo.
8. Bansode, F.W., Arya, K.R., Meena, A.K., Singh, R.K. 2019. Haematinic and anti-haematinic effects of the methanol extract of *Saraca Indica* stem bark against phenylhydrazine induced anemia on rats. *World Journal of Pharmaceutical Research* 8(9), 1176-1201.
9. Barcellini, W. and Fattizzo, B. 2015. Clinical applications of hemolytic markers in the differential diagnosis and management of hemolytic anemia. *Dis Markers*. 635670, 1-7.
10. Bigoniya, P., Singh, S., Singh, C.S., Shukla, A. 2013. Antianemic potential estimation on mice and characterization of flavonoids using high performance thin layer chromatography in *Wrightia tinctoria* bark fraction. *Jundishapur Journal of Natural Pharmaceutical Products* 4, 47-56.
11. Burtis, C. and Ashwood, E. 1986. *Textbook of Clinical Chemistry*, 2<sup>nd</sup> Edition. London: WB Saunders.
12. Chakrabarti, S., Naik, A.A., Reddy, G.R. 1990. Phenylhydrazine mediated degradation of bovine serum albumin and membrane proteins of human erythrocytes. *Biochimica et Biophysica Acta (BBA)- Biomembranes* 1028(1), 89-94.
13. Christine, V.S. and Roger, L.L. 2015. Review of methods for determination of total protein and peptide concentration in biological samples. *Proteomics Clin. Appl.* 9, 268-276.
14. Comporti, M., Signorini, C., Buonocore, G., Ciccilio, L. 2002. Iron release, oxidative stress and erythrocyte ageing. *Free Radical Biology and Medicine* 32(7), 568-576.
15. Conard, M.E., Weuntraub, L.R., Crosby, W.H. 1964. Iron Metabolism in Rats with Phenylhydrazine-Induced Hemolytic Disease. *Blood* 25(6), 990-998.
16. Defreese, J.D., Wang, T.S.C., Renoe, B.W. 1984. Properties and Determination of Serum Bilirubin. *CRC Critical Reviews in Clinical Laboratory Sciences* 19(4), 267-296.
17. El-Tantawy, W.H. and Temraz, A. 2009. Treatment of Experimental Hemolytic Anemia by Some Antioxidant Drugs. *Journal of Pharmacy Research* 2(5), 798-802.



18. Esterbauer, H. and Cheeseman, K.H. 1990. Determination of aldehydic lipid peroxidation products: malonaldehyde and 4-hydroxynonenal. *Methods of Enzymology* 186, 407-421.
19. Ferrali, M., Signorini, C., Sugherini, L., Pompella, A., Maura, L., Caciotti, B., Ciccoli, L., Comporti, M. 1997. Release of free redoxactive iron in the liver and DNA oxidative damage following phenylhydrazine intoxication. *Biochemical Pharmacology* 53(11), 1743 – 1751.
20. Gazak, R., Walterová, D., Kren, V. 2007. Silybin and silymarin—new and emerging applications in medicine. *Current Medicinal Chemistry* 14(3), 315–338.
21. Hagag, A., Elfaragy, M., Elrifay, S., Abd El-Lateef, A. 2015. Therapeutic value of combined therapy with Deferiprone and Silymarin as iron chelators in Egyptian Children with Beta Thalassemia major,” *Infectious Disorders—Drug Targets* 15 (3), 189–195.
22. Jakoby, W. and Ziegler, D. 1990. The enzymes of detoxication. *Journal of Biological Chemistry* 265, 20715-20718.
23. Liu, H., Zhang, L., Lu, S. 2012. Evaluation of antioxidant and immunity activities of quercetin in isoproterenol-treated rats. *Molecules*. 17: 4281–4291.
24. Luangaram, S., Kukongviriyapan, U., Pakdeechote, P., Kukongviriyapan, V., Pannangpetch, P. 2007. Protective effects of quercetin against phenylhydrazine-induced vascular dysfunction and oxidative stress in rats. *Food and Chemical Toxicology* 45, 448-455.
25. Mahmoud, A.Z., Ibrahim, H.A., El-Sawi, M.R., Habza, M.N. 2019. Effects of silymarin and mesenchymal stem cells on hematological and some biochemical changes induced by gamma radiation in albino rats. *International Journal of Radiation Biology* 96 (2), 220-227.
26. Marklund, S. and Marklund, G. 1974. Involvement of the superoxide anion radical in the autooxidation of pyrogallol and a convenient assay for superoxide dismutase. *European Journal of Biochemistry* 47, 469–474.
27. Mejia, G.B., Sanz, C.R., Avila, M.M., Peraza, A.V., Guzm, D.C., Olgü, H.J., Ramirez, A.M., Cruz, E.G. 2007. Experimental hemolysis model to study bilirubin encephalopathy in rat brain. *Journal of Neuroscience Methods* 168, 35–41.
28. Moayedi, M., Gharagozloo, N., Esmail, M., Maracy, R., Hoorfar, H., Jalaeikar, M. 2013. A randomized double-blind, placebo-controlled study of therapeutic effects of silymarin in  $\beta$ -thalassemia major patients receiving desferrioxamine. *European Journal of Haematology* 90(3), 202–209.
29. Moreau, R., Malu, D.T., Dumais, M., Dalko, E., Gaudreault, V., Roméro, H., Martineau, C., Kevorkova, O., Dardon, J.S., Dodd, E.L., et al. 2012. Alteration in bone and erythropoiesis in hemolytic anemia: comparative study in bled, phenylhydrazine-treated and plasmodium-infected mice. *Pone Plos one journal* 7(9), e46101.
30. Moron, M.S., Depierre, J.W., Mannervik, B. 1979. Levels of glutathione, glutathione reductase and glutathione S-transferase activities in rat lung and liver. *Biochim. Biophys. Acta (BBA) General Subjects* 582, 67-78.
31. Nakanishi, A., Kinuta, K., Abe, T., Araki, K., Yoshida, Y., Liang, S., Li, S.A., Takei, K., Kinuta, M. 2003. Formation of meso, N-diphenylprotoporphyrin IX by an aerobic reaction of phenylhydrazine with oxyhemoglobins. *Acta Medica Okayama* 57, 249–256.
32. Olayinka, E.T., Ore, A., Ola, O.S., Adeyemo, O.A. 2014. Protective Effect of Quercetin on Melphalan-Induced Oxidative Stress and Impaired Renal and Hepatic Functions in Rat. *Chemotherapy Research and Practice* 2014, 936526.
33. Pandey, K.P. and Rizvi, S.I. 2011. Biomarkers of oxidative stress in red blood cells. *Biomedical papers of the Medical Faculty of the University Palacky, Olomouc, Czechoslovakia (Biomed Paper)* 155 (2),131–136.
34. Pradeep, K., Mohan, C.V.R., Gobianand, K., Karthikeyan, S. 2007. Silymarin: An Effective Hepatoprotective Agent Against Diethylnitrosamine-Induced Hepatotoxicity in Rats. *Pharmaceutical Biology* 45(9), 707–714.
35. Ramakrishnan, G., Raghavendran, H.R., Vinodhkumar, R., Devaki, T. 2006. Suppression of N-nitrosodiethylamine induced hepatocarcinogenesis by silymarin in rats. *Chem Biol Interact* 161, 104–114.
36. Saito, H. 2014. Metabolism of iron stores. *Nagoya Journal of Medical Science* 76, 235-254.
37. Selvakumar, K., Bavithra, S., Suganya, S., Bhat, B.A., Krishnamoorthy, G., Arunakaran, J. 2013. Effect of Quercetin on Haematobiochemical and Histological Changes in the Liver of Polychlorinated Biphenyls-Induced Adult Male Wistar Rats. *Journal of Biomarkers* 2013, 960125.
38. Stentz, J.E., Clark, V.L.P., Matkin, G. 2010. Applying mixed methods to leadership research: A review of current practices. *The Leadership Quarterly* 23(6), 1173-1183.
39. Thorpe, S.J., Walker, D., Arosio, P., Heath, A., Cook, J.D., Worwood, M. 2008. Automated immunoassay methods for ferritin: recovery studies to assess traceability to an international standard. *Clinical Chemistry and Laboratory Medicine*, 46(10),1450-1457.
40. WenWu, J., Lin, L., Tsai, T. 2009. Drug-drug interactions of silymarin on the perspective of pharmacokinetics. *Journal of Ethnopharmacology* 121, 185–193.
41. Wilcox, C.S. and Gutterman, D. 2005. Focus on oxidative stress in the cardiovascular and renal systems. *The American Journal of Physiology: Heart and Circulatory Physiology* 288, 3–6.
42. Zangeneh, M.M., Zangeneh, A., Salmani, S., Jamshidpour, R., Kosari, F. 2019. Protection of phenylhydrazine-induced hematotoxicity by aqueous extract of *Ocimum basilicum* in Wistar male rats. *Comparative Clinical Pathology* 28, 331–338.
43. Zhang, M., Swarts, S.G., Yin, L., Liu, C., Tian, Y., Cao, Y., Swarts, M., Yang, S., Zhang, S., Zhang, K., et al. 2011. Antioxidant properties of quercetin. *Advances in Experimental Medicine and Biology*, 701: 283–289.