



Official Journal Issued by
Faculty of
Veterinary Medicine

Benha Veterinary Medical Journal

Journal homepage: <https://bvmj.journals.ekb.eg/>



Since 1990

Original Paper

Preparation and evaluation of necrotic enteritis vaccine using alpha toxin with different adjuvants in broilers

Hashem E. Salama¹, Mohamed M. El-Shorbagy², Alaa A. El-Meneisy³, Gamal R. Hasab El-Naby¹

¹Animal Health Research, Tanta branch.

²Department of rabbits and birds diseases, Faculty of Veterinary Medicine, Benha University.

³Veterinary Serum and Vaccine Research Institute, Abbasia, Cairo

ARTICLE INFO

Keywords

Alpha toxin.
Broiler chicks
Clostridium perfringens
Necrotic enteritis

Received 07/01/2021

Accepted 01/03/2021

Available On-Line
01/04/2021

ABSTRACT

In the present study 125 broiler chicks (Arbo) one-day old were used as experimental birds. The chicks were divided into five groups each of twenty-five chicks. The 1st group kept as control, the 2nd group was non-vaccinated and challenged, the 3rd group was infected with *Eimeria tenella* at the 15th days of age and challenged, the 4th group was vaccinated and challenged, and the 5th group was vaccinated and challenged. The chicks in the 4th group were vaccinated by locally prepared necrotic enteritis (NE) vaccine adjuvanted with Aluminum hydroxide at a dose of 0.5 ml subcutaneously at the age of seven days and boosted at age of eighteen days. The chicks of the 5th group were vaccinated by locally prepared NE vaccine adjuvanted with Montanide oil. The challenged groups (2, 3, 4 and 5) were challenged at age of 27, 28 and 29 days with *C. perfringens* type A whole culture at dose of 3 ml contains 10⁹ colony forming unites (Cfu). Serum samples were collected after challenge at thirty-five days. The results showed that higher immune response, lower mortality rate and increase in body weight gain in chicks of group 5 compared to chicks of groups (1, 2, 3 and 4). In conclusion vaccination of broiler chickens with alpha toxoid using montanide oil is recommendable to be used for better controlling and eradication of necrotic enteritis.

1. INTRODUCTION

Necrotic enteritis (NE) and subclinical related diseases are important infectious diseases in poultry industry in whole world causing high economic loss due to high mortality rate and poor feed conversion rate (Timbermont et al., 2011). Necrotic enteritis is caused by *C. perfringens* type A and a lesser extent type C, which able to produce major toxins (alpha, beta, epsilon, iota, and necrotic enteritis B like toxin NetB) (Engstrom et al., 2003). Alpha toxin was proposed to be the main virulence factor for necrotic enteritis in poultry (Gholamiandehkordi et al., 2006). *C. perfringens* is gram-positive, anaerobic and spore forming bacterium. It widely distributed in soil, dust, litter, contaminated feed and found as normal inhabitant of intestinal microbiota (Songer and Mear, 1996).

There is a clear relation between coccidia infection and NE by physical damage to GIT epithelium due to development of *Eimeria* stages leading to open direct access to intestinal basal layer (Wade et al., 2015). Also, some viral diseases like infectious bursal disease (IBD), chick anemia virus and Marek's disease have been suggested to promote the development of NE under field conditions (Lee et al., 2011). Ration rich with non-starch poly saccharide (NSPs) such as arabinoxylans and β -glucans are also hydrophilic, with the ability of increasing the viscosity of the intestinal contents and predisposing the bird to NE (Iji and Tivey, 1998). Occurrence of NE could also be affected by anti-

nutritional factors such as protease inhibitors, lectins, tannins, and mycotoxins (Clarke & Wiseman, 2010).

Typical clinical signs of NE include depression, reluctance to move, diarrhea, ruffled feathers, decreased appetite, dehydration, and birds dying within 1–2 hr after onset of clinical signs (Timbermont et al., 2011). Small intestine is usually distended with gas and contains a foul-smelling dark brown bile-stained fluid, the intestinal wall is usually thin and extremely friable (Van Immerseel et al., 2004). The mucosal surface is typically covered by a multifocal to coalescing yellow-green to yellow-brown loosely to tightly adherent diphtheritic pseudomembrane (Cooper et al., 2013). These birds have an enlarged, firm, and pale liver with multiple scattered yellow necrotic foci and occasionally the gall bladder and bile duct walls are thickened and both cavities are distended with bile (Lovland and Kaldhusdal, 1999).

Several antibiotics were used to control NE as lincomycin, bacitracin, and Tylosin in water, or bacitracin, lincomycin, virginiamycin, and avoparcin, in feed (Brennan et al., 2001; Collier et al., 2003).

Probiotics are those live microorganisms which have antimicrobial and growth promoter effects due to preventing gut colonization by pathogens as *C. perfringens* by the mechanism of competitive exclusion as *Bacillus subtilis* and *B. licheniformis* (Sokale et al., 2019).

Prebiotics referred to oligosaccharides as Mannan Oligosaccharides (MOS), Fructo-Oligosaccharides (FOS)

* Corresponding author: Hashem E. Salama, Animal Health Research, Tanta branch.

and B-glucan that are not digested by enzymes but can selectively stimulate the replication of intestinal bacterial flora, which have beneficial effects on the host's health, also have a significant effect on reducing mortalities caused by NE and on increasing chickens' weight gain and feed conversion rates (Murshed and Abudabos, 2015).

Phytogenic feed additives (PFA) are a categorized sensory and flavoring compounds, which consist mainly of plant extracts as carvacrol, thymol, capsaicin, cineole, etc.. which have antimicrobial efficacy against pathogenic bacteria, such as *Escherichia coli* and *Clostridium perfringens* (Mountzouris et al., 2011; Yang et al. (2015).

After banning of antibiotics vaccination either by *C. perfringens* and/or its toxins has been an effective way to control its infections in animals, alpha toxoid may serve as an effective immunogen by producing specific IgY and IgA in serum (Kulkarni et al., 2007; Zekarias et al., 2008).

The aim of this study is to prepare alpha toxoid with different adjuvants (Montanide™ ISA 71 and aluminum hydroxide) and assessment the toxoid by measuring body weight gain, feed conversion rate, mortality rate, lesion scoring and immune response in vaccinated and unvaccinated chickens.

2. MATERIAL AND METHODS

2.1. Bacterial Strains:

2.1.1. *Clostridium perfringens* type A strain:

A locally isolated strain obtained from diseased broilers chickens and identified by microbiological ways and PCR in animal health institute was used for vaccine preparation and for experimental challenge (whole culture each 3ml contain 10^9 cfu).

2.1.2. *Eimeria tenella* oocysts:

Eimeria tenella oocysts were obtained kindly from animal health institute each 1ml contain 10^5 *Eimeria tenella* oocysts.

2.2. Laboratory animals:

2.2.1. Mice:

Mice with average weight of 20-25gm were used for safety tests, determination of toxigenic *C. perfringens* by mice lethality test, serum neutralization test and determination of minimum lethal dose (MLD) during vaccine preparation and evaluation.

2.2.2. Chickens:

One day old 125 broiler chicks (Arbo) used as experimental birds were kept on the floor "using shaving wood as litter." in animal health institute, Tanta under normal breeding temperature. Chicks were fed on ration not containing anticlostridial feed additives (Fat hens) and water from tape water.

2.3. Vaccine preparation:

2.3.1. Necrotic enteritis vaccine:

Clostridium perfringens type A toxoid was prepared according to Gadalla et al. (1974). The prepared toxoid was divided into two equal parts. Aluminum hydroxide was added to first part in a percentage of 20 aluminum hydroxide:80 antigen. While the second part was adjuvanted with montanide gel (SEPPIC^R, France) in a ratio of 71 montanide: 29 antigen. Purity and safety test for two vaccines were carried out according to British Veterinary Pharmacopeia (2007).

2.4. Experimental design: 125 one-day old broiler chicks were divided into 5 groups (25 chicks\group):

Group 1: kept as control.

Group 2: non-vaccinated and challenged.

Group 3: infected with *Eimeria tenella* at 15th days of age as predisposing factor and increase severity of NE and challenged.

Group 4: vaccinated by locally prepared NE vaccine adjuvanted with Aluminum hydroxide by dose of 0.5ml subcutaneously at age of seven days and boosted at age of eighteen days and challenged.

Group 5: vaccinated by locally prepared NE vaccine adjuvanted with Montanide oil by dose of 0.5ml subcutaneously at age of seven days and boosted at age of eighteen and challenged.

All groups 2, 3, 4 and 5 were challenged with 3ml of freshly prepared *C. perfringens* type A whole culture contain 10^9 Cfu for successive 3days from 27th days-old.

2.5. Blood samples

Blood samples were taken from wing vein of broiler chicks using plastic syringe. The samples were kept in refrigerator for 24hrs to separate plasma. Then the samples were centrifuged at 1000 rpm for 5mins, the separated sera were collected for SNT and ELISA.

2.6. Organ samples

Organ samples from sacrificed birds were taken at age of 35th day old from middle part of small intestine and liver for gross lesion observation according to Prescott et al. (1979). Lesions were scored from 0 to 4 (0: no apparent lesion, 1: thin friable wall of small intestine, 2: focal necrosis and/or ulceration, 3: patchy necrosis and/or ulceration, 4: severe extensive necrosis).

Small intestine and liver samples were taken from different groups and preserved by formalin 100% for histopathological examination according to Bancroft et al. (1996).

Mortalities and clinical signs were recorded during the experimental study. Also mean body weight of all groups was measured at the end of experiment to compare between vaccinated and unvaccinated groups.

2.7. Statistical analysis:

Data were analyzed by SPSS version 24 (IBM Corp. Released 2016. IBM SPSS Statistics for Windows, Version 24.0. Armonk, NY). Results were expressed as Mean \pm SD. One-Way ANOVA was run to test differences in body weight and antibody titer in ELISA test between groups, $P < 0.05$ was considered statistically significant

3. RESULTS

3.1. Clinical signs:

In groups (1): chicks showed no marked clinical signs. In groups (2 and 3): From 24:48hr post challenge, the birds in both groups showed decrease feed consumption, increase water intake, ruffled feather, and brownish diarrhea tinged with blood especially in group A (Figure 1). In vaccinated groups (4 and 5): No marked clinical signs were detected post challenge, also there is no mortality has been occurred.

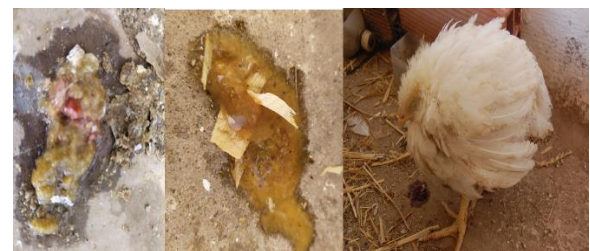

Figure 1 Chick shows ruffled feather, decrease feed consumption, increase water intake and brownish diarrhea tinged with blood.

3.2. Postmortem examination:

In group (1) the intestine and liver were apparently normal (score lesion 0) (Figure 2). In unvaccinated groups (group 2 & 3), score lesion varied between 2 to 4 as described in table 1, the postmortem examination showed ballooning of intestine, congestion of intestinal mucosa, friable intestinal wall, intestinal mucosal wall showed necrosis and ulceration as well as severe congestion in liver and in some cases jaundice liver (Figures 3-6). On the other hand, there were no apparent lesion detected in scarified birds obtained from vaccinated groups (group 4&5) either by gel or oil vaccine (score lesions between 0 to 1 as described in table (1) and Figure (7)).

Table 1 Lesion score in different groups after challenge with *C. perfringens*

Groups	Group1	Group 2	Group 3	Group 4	Group 5
Score 0	25	—	—	17	20
Score 1+	—	—	—	8	5
Score 2+	—	7	6	—	—
Score 3+	—	8	7	—	—
Score 4+	—	10	12	—	—

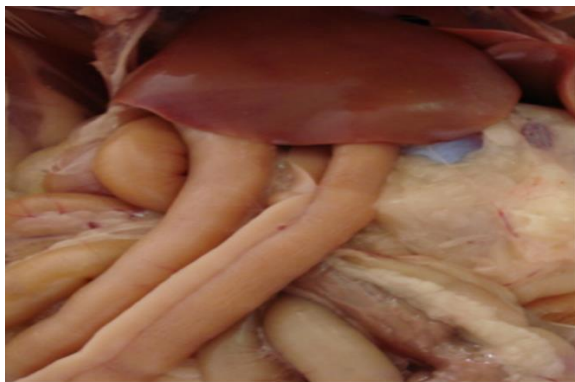

Figure 2 Control group show normal intestine and liver

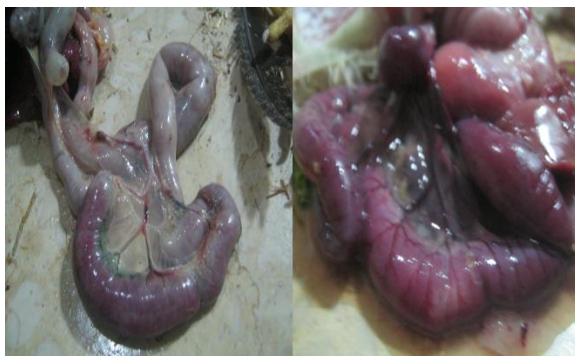

Figure 3 Postmortem examination in unvaccinated groups showed severe congestion in small intestine

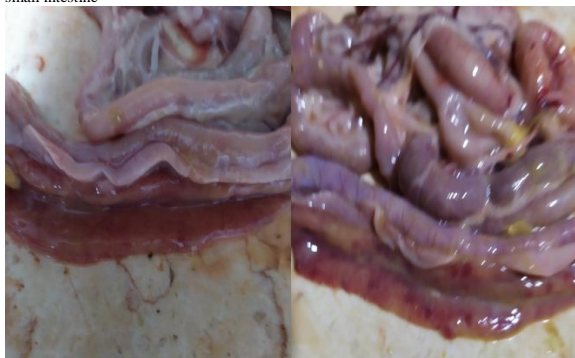

Figure 4 Postmortem examination in unvaccinated groups showed intestinal necrosis and ulcerations

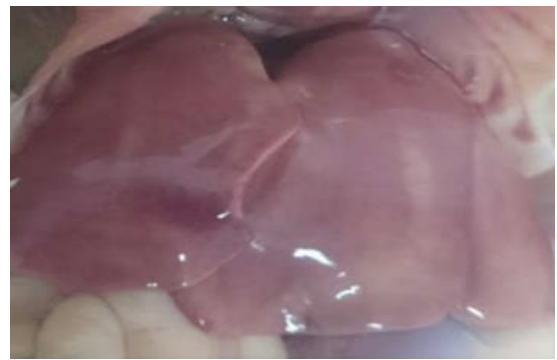

Figure 5 Postmortem examination in unvaccinated groups showed liver with multiple focal necrosis and petechial hemorrhage

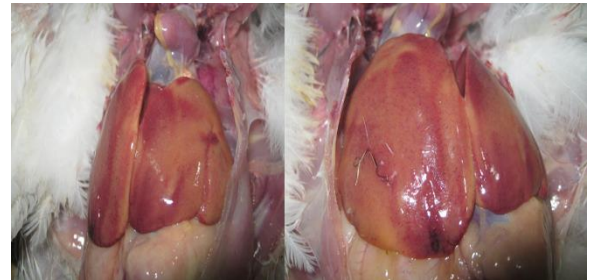


Figure 6 Postmortem examination in unvaccinated groups showed jaundiced liver with petechial hemorrhage

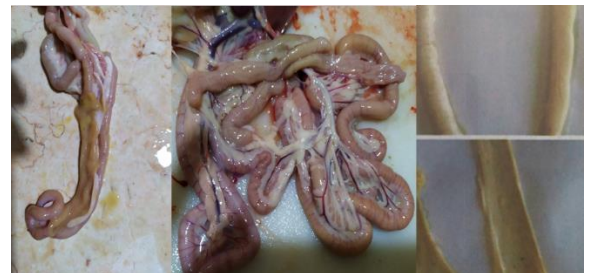

Figure 7 Postmortem examination in vaccinated groups showed apparently normal intestine

3.3. Histopathological examinations:

Unvaccinated groups (group 2 and 3):

Intestine: There were diffuse coagulative necrosis with inflammatory cell infiltration in superficial mucosa and sometimes it extended to deeper mucosa. Meanwhile, there were edema and necrosis in the muscle layer. Also, bacterial rod bacilli were found in the lumen of the intestine (Figure 8 A)

Liver: There were multiple necrotic areas in hepatic parenchyma with variable degenerative changes in adjacent hepatocytes. Also, there were marked lymphocytic infiltration and edema in portal vein (Figure 8 B).

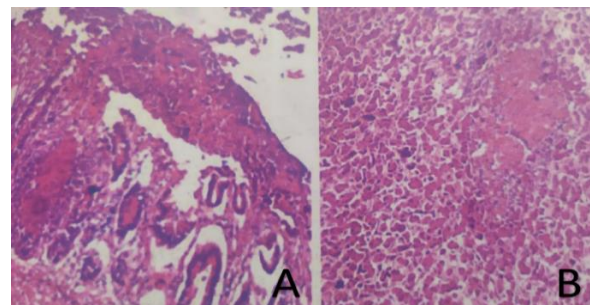


Figure 8 Histopathological examination in unvaccinated groups: A showed intestinal desquamation of mucosal lining epithelium, fusion of the villi with massive inflammatory infiltration in lamina propria, mucosal necrosis and lymphoid depletion in lamina propria (H&E x400), B showed multiple necrotic areas in hepatic parenchyma, congestion of portal vein, degeneration in hepatocytes with lymphocytic infiltration (H&E x400)

Vaccinated group (group 4 and 5):

Intestine: The intestine was apparently normal with mild desquamation in intestinal villi. Also, there were mild lymphocytic infiltration in mucosa and submucosa. Meanwhile, the muscle layer was apparently normal (Figure 9 A)

Liver: The hepatic parenchyma appeared apparently normal with mild lymphocytic infiltration in portal vein (Figure 9 B & C)

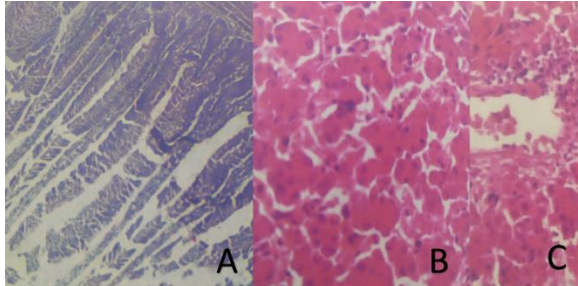


Figure 9 Histopathological examination in vaccinated groups: A showed normal intestinal villus (H&E x400), B showed normal hepatic parenchyma, C mild edema in portal vein with normal hepatocyte and mild lymphocytic infiltration around portal vein (arrow) (H&E x400)

3.5. Result of SNT

Table 2 Effect of necrotic enteritis vaccine on the communitive mortality and production performance in broiler chicken

Group	No.	Species	Consumed feed/bird through 35 days	Body weight (kg) at age of 35 days (Mean \pm SD)	Mortality through 35 days	Mortality percentage	FCR	
Control	1	25	Arbo	3.5 kg	2.28 \pm 0.19	0	0%	1.53
Unvaccinated	2	25	Arbo	3.5 kg	2.18 \pm 0.36	2	8%	1.65
	3	25	Arbo	3.5 kg	2.10 \pm 0.22	4	16%	1.71
Vaccinated	4	25	Arbo	3.5 kg	2.22 \pm 0.24	1	4%	1.59
	5	25	Arbo	3.5Kg	2.30 \pm 0.19*	0	0%	1.52

Table 3 Immune response of broiler chicken vaccinated with necrotic enteritis vaccine using SNT

Group	Treatment	After the 2 nd vaccination at age of 35 day
1	Control	0 IU/ml
2	Unvaccinated	0 IU/ml
3	Unvaccinated	0 IU/ml
4	Vaccinated with gel	6 IU/ml
5	Vaccinated with oil	8IU/ml

3.6. Result of ELISA

One-Way ANOVA results showed that there were highly statically significant differences between groups regarding the humeral immune response using ELISA ($P < 0.001^*$), the highest antibody titer recorded in group 5 (1.461 \pm 0.150) which represented the vaccinated group with Montanide. Meanwhile, the chickens vaccinated with gel gave a high antibody titer (1.255 \pm 0.047) but less than the group 5. On the other hand, the unvaccinated groups 1, 2 and 3 showed the lowest antibody titer (0.496 \pm 0.098), (0.497 \pm 0.097) and (0.499 \pm 0.099) respectively (Table 4)

Table 4 Comparison of humeral immune response between different groups by ELISA

Group	Treatment	After 2 nd dose of vaccination	One-Way ANOVA
1	Control	0.496 \pm 0.098	P<0.001
2	Unvaccinated	0.497 \pm 0.097	
3	Unvaccinated	0.499 \pm 0.099	
4	Vaccinated with gel	1.255 \pm 0.047	
5	Vaccinated with oil	1.461 \pm 0.150*	

4. DISCUSSION

Necrotic enteritis and subclinical related diseases are important infectious diseases in poultry industry in whole world causing high economic loss due to high mortality rate and poor feed conversion rate. These economic losses

SNT results revealed that, the group 4 vaccinated with gel gave protective antibody level 6 IU/ml. While, the group 5 vaccinated with oil gave high protective antibody level 8 IU/ml. Meanwhile, there was no antibody level in challenged unvaccinated groups (1, 2 and 3). So, the high antibody titers in vaccinated groups were protect chickens against alpha toxin and lower the mortality due to NE in comparison to those of non-vaccinated groups (Table 3).

3.4. Body weight and feed conversion ratio (FCR):

In group (1): the mean body weight of chicken at the 35th day was 2.28 kg; mortality rate was 0% and FCR was 1.53. -Unvaccinated group: In group 2 after challenge the mean body of chicken at the 35th day was 2.18 kg, 2 chicks died, and the mortality rate was 8% and FCR was 1.65. While group 3 the mean body of chicken at the 35th day was 2.10 kg, 4 chicks died, and the mortality rate was 16% and FCR was 1.71. -Vaccinated group: In group 4 after challenge, the mean body of chicken at the 35th day was 2.22 kg, 1 chick died, and the mortality rate was 4% and FCR was 1.59. Meanwhile, in group 5, the mean body of chicken at the 35th day was 2.30 kg, no chick died and FCR was 1.52 (Table 2).

may cost the poultry industry billions dollars annually (Engeström et al., 2003; Timbermont et al., 2011).

It was well known that vaccination is the cornerstone in controlling infectious diseases and it is known that flocks with high titers of maternal antibodies against alpha toxin had lower mortality during the production period than flocks with low titers (Heier et al., 2001).

In both vaccinated groups either with aluminum hydroxide or mantonide™ ISA 71 adjuvant and in control group (1) showed no marked clinical signs after challenge due to presence of antibodies that neutralize the effect of alpha toxin produced by *C. perfringens* culture challenge. Also, mortality rate was 4% and 0% respectively. While unvaccinated groups showed marked clinical signs of NE and mortality was 8% and 16% respectively. These results agreed with (Timbermont et al., 2011; Prescott et al., 2016).

Our result revealed that the score lesion varied between 2 to 4 in unvaccinated groups while in vaccinated groups score lesions between 0 to 1 and in control group score lesion was 0. This result explained the role of vaccination in controlling NE. This finding in agreement with Van Immerseel et al. (2004) and Keyburn et al. (2008). Histopathological results of intestine and liver from different groups were in agreement with Olkowski et al. (2006) and Cooper et al. (2013).

Measurement of performance parameters as body weight, FCR and mortality rate is useful to estimate the disease induction and vaccine trials for controlling the NE and related subclinical diseases. The statistical analysis of body weight in different groups reflected that there was significant difference between five groups ($P < 0.05$) after experimental challenge however all broiler chickens were reared under the same conditions and eating same quantity and quality of feed ration. These results run parallel with

saleh et al. (2011), Timbermont et al. (2011), Forder et al. (2012) and Wade et al. (2015).

The result of SNT was 0 IU/ml in unvaccinated groups and control group while in group 4 was 6 IU/ml and group 5 was 8 IU/ml these results reflected role of Montanide™ ISA 71 adjuvant in stimulating specific components of either humeral or cell-mediated immune response. Selecting the ideal or the most suitable adjuvant is one of the important tools in improving the efficacy of the vaccine. An ideal adjuvant is one which can stimulate the humeral immune response early (onset), and promote production of high antibody titers (strength/intensity) that would last long (duration). It should also stimulate the cellular immune response.

The results of SNT in this study were agreed with other studies according to El-Meneisy et al. (2007), Zekarias et al. (2008), Keyburn et al. (2008), Coursodon et al. (2010), Cooper et al. (2013) and Mot et al. (2014).

ELISA procedure is a rapid, specific, and sensitive serological assay which has been used for the detection of several bacterial toxins. ELISA results come in parallel with the results of SNT. These results agreed with El-Meneisy et al. (2007) and Cooper et al. (2013), who showed that the vaccination of chickens with NE vaccine resulted in strong and specific antibody against alpha toxin of *Clostridium perfringens* type A

5. CONCLUSIONS

In conclusion vaccination of broiler chickens with alpha toxoid using montanide oil is recommendable to be used for better controlling and eradication of necrotic enteritis.

6. REFERENCES

- Banchroft, J.D., Stevens, A., Turner, D.R. 1996. Theory and practice of histopathological techniques. Fourth Ed. Churchill Livingstone, New York, London, San Francisco, Tokyo.
- Brennan, J., Bagg, R., Barnum, D., Wilson, J., Dick, P. 2001. Efficacy of narasin in the prevention of necrotic enteritis in broiler chickens. *Avian Dis.* 45, 210–214 .
- Brennan, J., Moore, G., Poe, S.E., Zimmermann, A., Vessie, G., Barnum, D.A., Wilson, J. 2001. Efficacy of in-feed tylosin phosphate for the treatment of necrotic enteritis in broiler chickens. *Poult Sci* 80, 1451–1454.
- British Veterinary Pharmacopia 2007. The pharmaceutical press, London .
- Clarke, E. & Wiseman, J. 2010. The effects of dietary trypsin inhibitor content on digesta viscosity and excreta moisture content in broilers. *British Poultry Abstracts* 6, 2- 3.
- Collier, C.T., Van der Klis, J.D., Deplancke, B., Anderson, D.B., Gaskins, H.R. 2003. Effects of tylosin on bacterial mucolysis, *Clostridium perfringens* colonization, and intestinal barrier function in a chick model of necrotic enteritis. *Antimicrob Agents Chemother* 47, 3311–3317.
- Cooper, K.K., Songer, J.G., Uzal, F.A. 2013. Diagnosing clostridial enteric disease in poultry. *Journal of Veterinary Diagnostic Investigation* 25(3), 314–327 .
- Coursodon, C.F., Trinh, H.T., Mallozzi, M., Vedantam, G., Glock, R.D., Songer, J.G. 2010. *Clostridium perfringens* alpha toxin is produced in the intestines of broiler chicks inoculated with an alpha toxin mutant. *Anaerobe*, 16(6), 614–617.
- El-Meneisy, A.A., Abdalla, Y.A., Shafie, F., El-Boraay, I.M. 2007. Experimental vaccination of broilers with NE vaccine. *J. Egypt Vet. Med. Assoc.* 67(4), 155-163.
- Engström, B.E., Fermér, C., Lindberg, A. 2003. Molecular typing of isolates of *Clostridium perfringens* from healthy and diseased poultry. *Vet Microbiol.* 94, 225–235.
- Forder, R.E., Natrass, G.S., Geier, M.S., Hughes, R.J., Hynd, P.I. 2012. Quantitative analyses of genes associated with mucin synthesis of broiler chickens with induced necrotic enteritis. *Poultry Science*, 91, 1335-1341.
- Gadalla, M.S., Farrag, I., Sharaf, D. 1974. Effect of growth requirement on the improvement of clostridia vaccine. *Jornal of the Egyptian Veterinary Medical Association* 31, 135-150.
- Gholamiandehkordi, A.R., Ducatelle, R., Heyndrickx, M., Haesebrouck, F., Van Immerseel, F. 2006. Molecular and phenotypical characterization of *Clostridium perfringens* isolates from poultry flocks with different disease status. *Veterinary Microbiology*, 113, 143-152.
- Heier, B.T., Lovland, A, Soleim, K.B, Kaldhusal, M., Jarp, J. 2001. A field Study of Naturally Occurring Specific Antibodies against *C. perfringens* Alpha Toxin in Norwegian Broiler Flocks. *Avian diseases*, 45, 724-732 .
- Iji, P.A. and Tivey D.R. 1998. Natural and synthetic oligosaccharides in broiler chicken diets. *Worlds Poultry Science Journal* 54, 129-143.
- Keyburn, A.L., Bannam, T.L., Moore, R.J., Rood, J.I. 2008. Net B, a pore forming toxin from necrotic enteritis strains of *Clostridium perfringens* toxins, 2, 1913-1927.
- Kulkarni, R.R., Parrerira, V.R., Sharif, S., Prescott, J.F. 2007. Immunization of broiler chickens against *Clostridium perfringens* induced necrotic enteritis. *Clinical and Vaccine Immunology* 14, 1070-1077.
- Lee K.W., Lillehoj H.S., Jeong W., Jeoung, H.Y., An, D.J. 2011. Avian necrotic enteritis: Experimental models, host immunity, pathogenesis, risk factors, and vaccine development. *Poultry Science*, 90, 1381-1390.
- Lovland, A. and Kaldhusdal, M. 1999. liver lesions seen at slaughter as an indicator of NE in broiler flocks. *FEMS. Immunology and medical microbiol* 24, 345-351.
- Mot, D., Timbermont, L., Haesebrouck, F., Ducatelle, R., Van Immerseel, F. 2014. Progress and problems in vaccination against NE in broiler chickens. *Avian pathology* 43, 290-300.
- Mountzouris, K.C., Paraskevas, V., Tsirosikos, P., Palamidi, I., Stenier, T., Schatzmayr G. 2011. Assessment of a phytogetic feed additive effect on broiler growth performance, nutrient digestibility and cecal micro flora composition. *Anim Feed Sci. Tech.* 168, 22-33 .
- Murshed, M.A. and Abudabos, A.M. 2015. Effects of the dietary inclusion of probiotic, prebiotic or their combinations on the growth performance of broiler chickens. *Braz J Poultry Sci*, 159, 111-123.
- Olkowski, A.A., Wojnarowicz, C., Chirino-Trejo, M., Drew, M.D. 2006. Responses of broiler chickens orally challenged with *Clostridium perfringens* isolated from field cases of necrotic enteritis. *Research in Veterinary Science* 81, 99-108.
- Olkowski, A.A., Wojnarowicz, C., Chirino-Trejo, M., Laarveld, B., Sawicki, G. 2008. Subclinical necrotic enteritis in broiler chickens novel etiological consideration based on ultra-structural and molecular changes in the intestinal tissues. *Research in Veterinary Science* 85, 543-555.
- Prescott, J.F. 1979. The prevention of experimentally induced necrotic enteritis in chickens by avoparcin. *Avian Dis.* 23, 1072–1074.
- Prescott, J.F., Parreira, V.R., Mehdizadeh Gohari, I., Lepp, D., Gong, J. 2016. The pathogenesis of necrotic enteritis in chickens what we know and what we need to know a review. *Avian Pathology* 45(3), 288–294 .
- Saleh, N., Fathalla, S.I., Nabil, R. Mosaad, A.A. 2011. Clinicopathological and immunological studies on toxoids

- vaccine as a successful alternative in controlling clostridial infection in broilers. *Anaerobe* 17(6), 426–430.
28. Sokale, A., Menconi, A., Mathis, G., Lumpkins, B., Sims, M., Whelan, R., Doranalli, K. 2019. Effect of *Bacillus subtilis* DSM 32315 on the intestinal structural integrity and growth performance of broiler chickens under necrotic enteritis challenge. *Poult. Sci.*, 98, 5392–5400.
 29. Songer, J.G. and Meer, R.R. 1996. Genotyping of *Clostridium perfringens* by polymerase chain reaction is a useful adjunct to diagnosis of clostridial enteric disease in animals. *Anaerobe* Vol 2, Issue 4, August, Pages 197-203
 30. Timbermont, L., Haesebrouck, F., Ducatelle, R., Van Immerseel, F. 2011. Necrotic enteritis in broilers: an updated review on the pathogenesis. *Avian Pathology* 40(4), 341–347.
 31. Van Immerseel, F., De Buck, J., Pasmans, F. 2004. *Clostridium perfringens* in poultry: an emerging threat for animal and public health. *Avian Pathol* 33, 537–549.
 32. Wade, B., Keyburn, A.L., Seeman, T., Rood, J.I., Moore, R.J. 2015. Binding of *C. perfringens* to collagen correlates with the ability to cause NE in chickens. *Veterinary Microbiology* 180, 299-303.
 33. Yang, C., Kabir Chowdhury M.A., Hou, Y., Gong J. 2015. Phytogetic compounds as alternatives to in-feed antibiotics: potentials and challenges in application. *Pathogens* 4,137–56.
 34. Zekarias, B., MO, H., Curtiss, R. 2008. Recombinant attenuated *Salmonella enterica* serovar Typhimurium expressing the carboxy-terminal domain of alpha toxin from *Clostridium perfringens* induces protective responses against necrotic enteritis in chickens. *Clinical and Vaccine Immunology* 15, 805-816.