

## S100A1 Protein As A Potential Discriminating Marker Between Chromophobe Renal Cell Carcinoma And Renal Oncocytoma

Ahmed H. Abdel-Rahman<sup>1</sup> – Mostafa M. Khodeir<sup>2</sup> – Emad Salah Ali<sup>3</sup>  
Ahmed Murad<sup>4</sup> – Waled Elnabawy<sup>5</sup>

From Departments of Pathology<sup>1</sup> and Urology<sup>3</sup>, Al-Azhar University (Assiut) &  
From Departments of Pathology<sup>2</sup>, Internal Medicine<sup>4</sup>, Cairo University & Internal  
Medicine<sup>5</sup> Bany Sweef University

### Abstract

The morphological differentiation between chromophobe renal cell carcinoma (RCC) and renal oncocytoma (RO) may be difficult. This study evaluates S100A1 protein as a new marker for the differentiation between these two tumors. We selected twenty cases; fifteen of which were typically diagnosed after routine histopathological staining by hematoxylin and eosin (7 chromophobe RCC and 8 RO) while the remaining five cases showed confusing cytomorphological features and uncertainly diagnosed. Immunoperoxidase technique using anti-S100A1 antibody carried out semiquantitatively in all cases displayed a strong cytoplasmic positive granularity in five typical RO, moderate immunopositivity in two typical RO and weak reactivity in one typical RO while all seven typical chromophobe RCC cases were immunonegative. Regarding uncertainly diagnosed cases, three were immunopositive for S100A1 antibody (one strong, one moderate and one weakly reactive) in the same pattern as typical RO while the remaining two cases were immunonegative like typical chromophobe RCC cases.

From our study, we concluded that S100A1 may be a potentially powerful marker to differentiate the chromophobe RCC from RO particularly when these tumors are in doubt about routine histologic diagnosis.

**Key words:** S100A1 antigen – Immunohistochemistry – Chromophobe renal cell carcinoma – Renal oncocytoma.

### Introduction

Renal cell carcinoma is a common tumor. It has different subtypes as conventional, papillary & chromophobe renal cell carcinoma. (Zambrano *et al.*, 1999). The differentiation of each subtype is of clinical importance since each may have a different clinical evolution (Cheville *et al.*, 2003).

One of the diagnostic problems may be the discrimination between the granular chromophobe RCC and benign oncocytoma. Both have eosinophilic cells which cause diagnostic difficulty (Li *et al.*, 2005).

Immunohistochemical study is often used when routine morphological features are confusing. However, very few molecular markers have been verified in renal tumors and also few molecular markers can differentiate chromophobe RCC from renal oncocytoma are scarce.

S100A1 was studied in tumor samples but its role has not been published in the differential diagnosis of common subtypes of renal tumors (Heizmann *et al.*, 2002; Teratani *et al.*, 2002 and Li *et al.*, 2005).

In this study, we evaluated S100A1 as a new molecular marker to differentiate chromophobe RCC from renal oncocytoma.

### Material and Methods

The material of this work consisted of twenty selected cases of chromophobe RCC and renal oncocytoma collected from Urology, Internal Medicine and pathology Departments, Al-Azhar University and Kasr El-Aini Hospitals during the period from January 2005 to December 2007. All patients were males with ages ranged from

48 to 62 years (mean;  $51.7 \pm 2.1$  years) all patients were subjected to renal biopsy.

In preparation for biopsy, bleeding disorders are excluded and corrected if present. Localization of the kidney by anatomical landmarks, an abdominal ultrasound is performed at some earlier time to determine that the patient has two kidneys in the usual location. After sedation, patients are placed in the prone position, with a bolster under the abdomen. The Tru-Cut needle is used. Post-biopsy care includes observation of vital signs, bed rest overnight and some limitation of activity for 2 days to 2 weeks subsequently.

#### Histopathological and immunohistochemical procedures:

Formalin-fixed & paraffin-embedded blocks were sectioned at  $5\mu$  thickness and examined microscopically using Hx & E stain to confirm the diagnosis before the immunohistochemistry. In addition, the sections on pretreated (coated) slides (superplus, Menzel-Glaser, Germany) used for immunohistochemistry study were deparaffinized in xylene and rehydrated using ethanol gradients, then pretreated three times in a microwave oven for 5 minutes in citrate solution (Biogenex - Neufahrn, Germany). Endogenous peroxidase activity was blocked by immersion in 3% hydrogen methanol for 20 minutes. Washing three times with cold 0.01M phosphate buffered saline (PBS), then blocking with 10% normal rabbit serum followed by incubation for 30 minutes with monoclonal antibody S100A1( Clone 4C4.9,MS-296-R7,Neomarkers Co.,USA) at a dilution of 1:25. Then, an En Vision Kit (DakoCytomation) is added to the slides and incubated for 15 minutes. Finally the diaminobenzidine, (DakoCytomation) was used as a chromogen and hematoxylin as a counterstain. Cardiac muscle as a positive control and section untreated with the primary antibody as a negative control were carried out in this study.

#### Assessment of immunoreactivity:

Positive reaction for anti-S100A1 antibody was evaluated in a semiquantitative manner and appeared as a coarse dense brownish cytoplasmic granularity in the main areas of the tumor samples.

However, nuclear and membranous reactions were rare and had been omitted. The evaluation of immunohistochemical results of S100A1 expression was performed taking into account the density and the intensity of reactive cells and quantitated in the following frequency score (Li et al., 2007): 0, negative; 1+, weak (positive tumor cells <25%); 2+, moderate (positive tumor cells from 25% - <50%) and 3+, strong (positive tumor cells >50%).

#### Statistical analysis:

S100A1 immunopositivity was described as number of cases and percentage. Comparison of S100A1 immunopositivity between both renal tumor subtypes was compared using Fisher exact test. P value < 0.05 was considered statistically significant. All statistical calculations were done using computer programs Microsoft Excel version 7 (Microsoft Corporation, NY, USA) and SPSS (Statistical Package for the Social Science; SPSS Inc., Chicago, IL, USA) version 13 for Microsoft Windows.

#### Results

Microscopic re-examination of the routinely stained sections (Table 1) diagnosed seven cases (7/20; 35%) as typical chromophobe RCC (Fig.1) all cases were grade II and staged as pT<sub>2</sub>NoMo) characterized by tubular, trabecular and solid patterns of granular malignant cells with eosinophilic cytoplasm, large pleomorphic central nuclei and small nucleoli. The stroma is scanty but highly vascularized. Moreover, eight cases (8/20; 40%) were typical benign renal oncocytoma (Fig.2) composed exclusively of large eosinophilic granular tumor cells arranged in nests (organoid pattern) separated by fibrovascular septa. The cells have uniform round nuclei and inconspicuous nucleoli. The remaining five cases (5/20; 25%) showed confusing cytomorphological features, including eosinophilic granular cytoplasm, pleomorphic nuclei in the tumor cells and mitosis, which cause diagnostic problems making them indefinitely diagnosed (Fig.3).

Immunoperoxidase staining of all selected cases of renal neoplasms (Tables 2&3) revealed positive S100A1

immunoreactivity in all typical RO cases (5 were strong; Fig.8, 2 were moderate; Fig.7 and one was weak in intensity; Fig.6; in total 8/8; 100%) while all typical chromophobe RCC were S100A1 immunonegative; Fig.4.

Regarding the indefinitely diagnosed cases, three were S100A1 immunopositive (one strong; one moderate Fig.5 and one

weak in intensity) in the same pattern as the positive typical RO cases (dense coarse brownish cytoplasmic granularity) while the remaining two cases were not immunoreactive like the negative typical chromophobe RCC. There was a significant difference in the percentages of positivity between both types of renal tumors ( $P < 0.01$ ).

**Table 1: Routine histopathological diagnosis of all studied cases (n=20):**

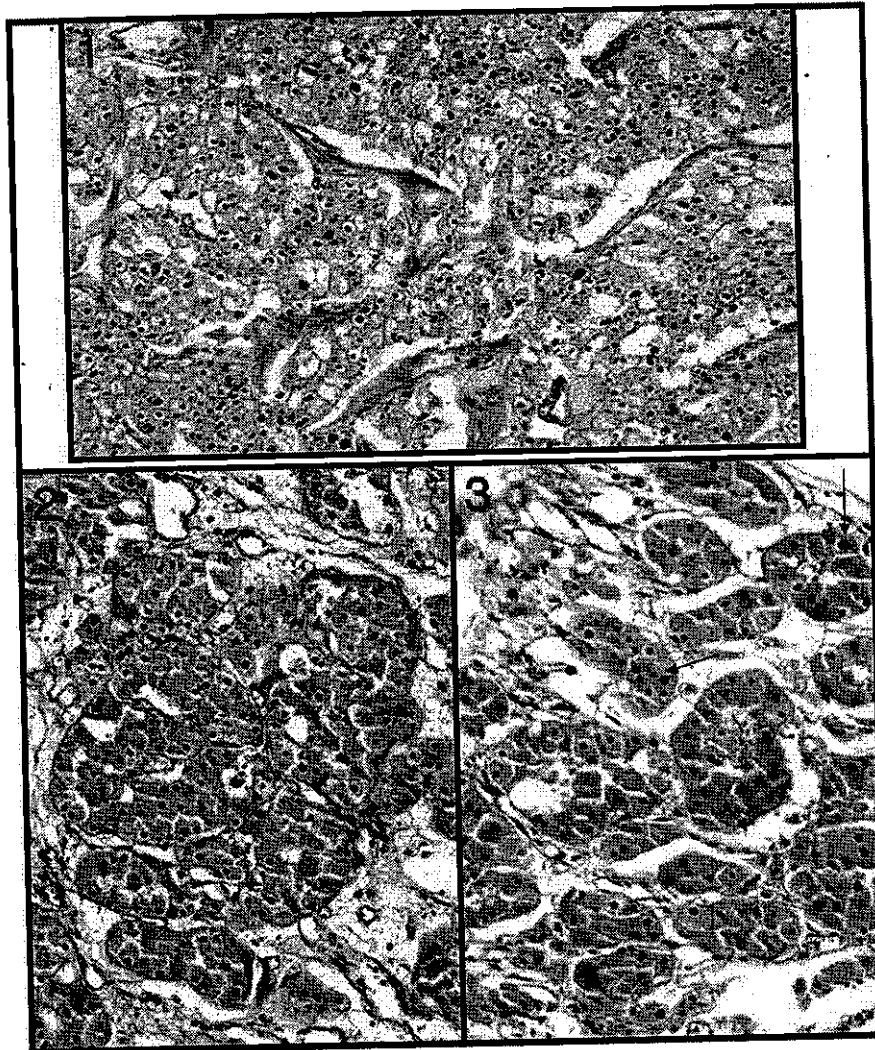
Diagnosis	No; of cases	Percentage(%)
Typical benign renal oncocytoma (RO)	8	40
Typical chromophobe RCC	7	35
Indefinitely diagnosed tumors	5	25
Total	20	100

**Table 2: S100A1 immunoreactivity in all studied cases (n=20):**

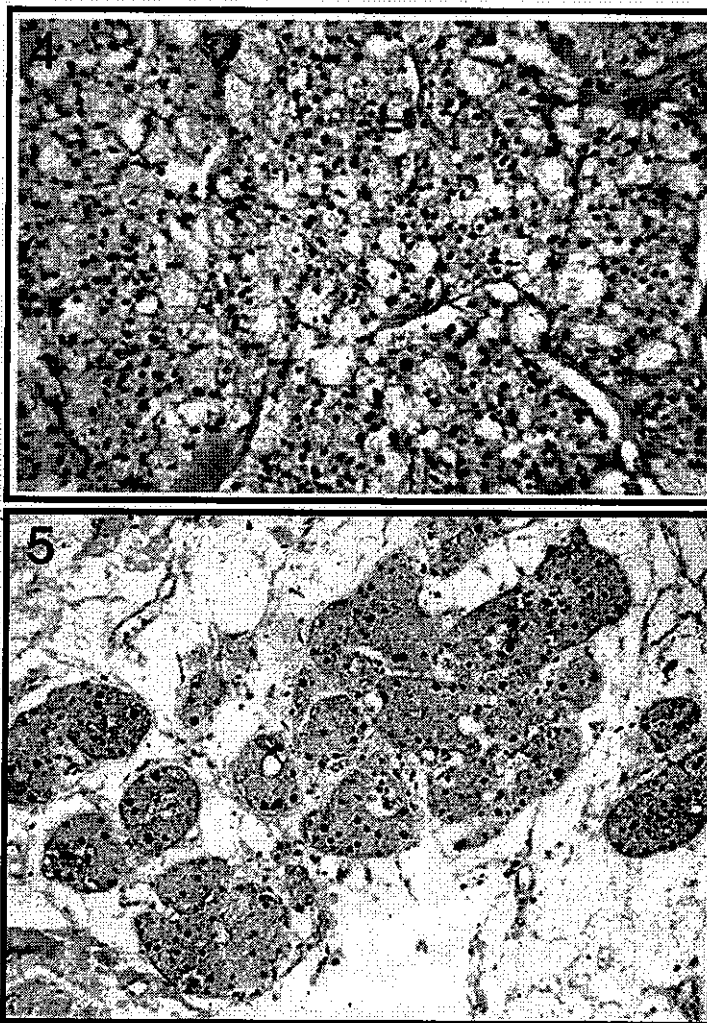
Diagnosis	S100A1 Positivity			S100A1 negativity (0)
	Strong (3+)	Moderate (2+)	Weak (1+)	
Typical Renal Tumors:				
Renal oncocytoma	5	2	1	0
Chromophobe RCC	0	0	0	7
Uncertain diagnosed:	1	1	1	2
Total	6(54.5%)	3(27.3%)	2(18.2%)	9(100%)

**Table 3: S100A1 immunoreactivity in typical renal tumour cases (n=15):**

Diagnosis	S100A1 Positivity	S100A1 Negativity	P value
Renal oncocytoma	7	0	<0.01
Chromophobe RCC	0	8	
Total	7	8	

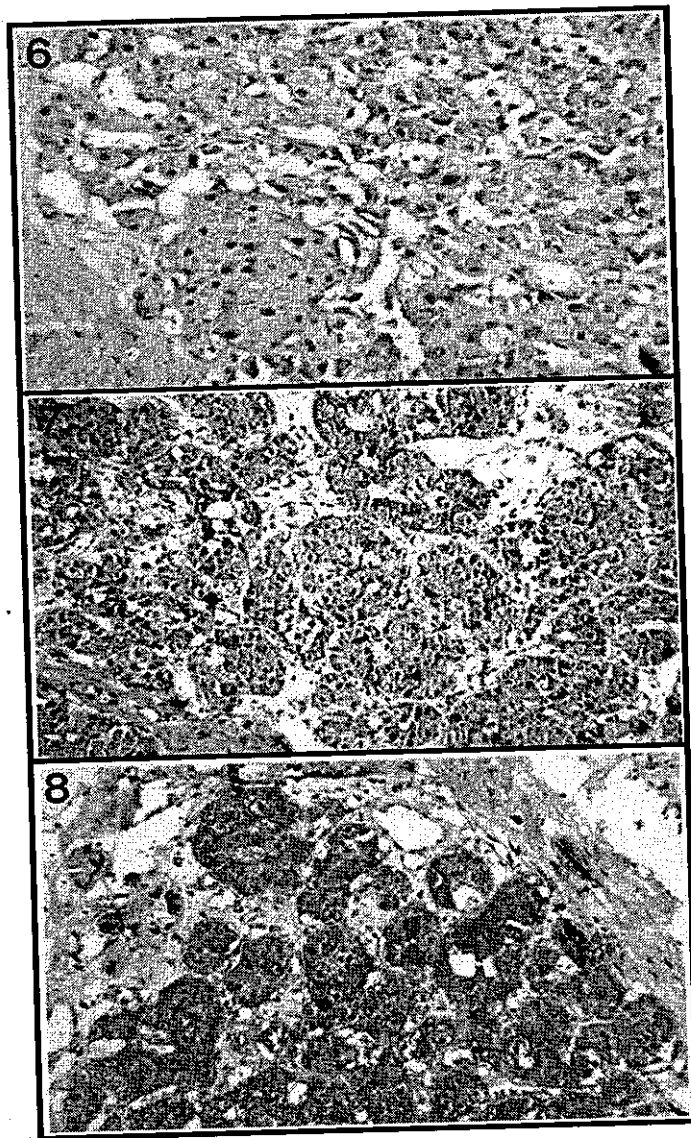


- Fig.1:** A case of chromophobe RCC showing malignant cells with eosinophilic granular cytoplasm & central pleomorphic nuclei, arranged in trabecular & solid patterns separated by a fibrovascular stroma. (Hematoxylin & eosin x 150).
- Fig.2:** A case of renal oncocytoma composed of large eosinophilic granular tumor cells arranged in nests (organoid pattern) in a myxoid stroma. (Hematoxylin & eosin x 200).
- Fig.3 :** A case of renal oncocytoma composed of large eosinophilic granular tumor cells arranged in nests and trabeculae with confusing features , scattered large pleomorphic nuclei with multiple mitotic figures (Arrows). (Hematoxylin & eosin x 200).



**Fig.4:** A case of chromophobe RCC immunonegative for S100A1.  
(DAB chromogen and Hematoxylin counter stain x 200).

**Fig. 5:** A case of renal oncocytoma with confusing features, a moderate brownish cytoplasmic granular immunopositivity for S100A1.  
(DAB chromogen and Hematoxylin counter stain x 200).



**Fig.6:** A case of renal oncocytoma showing a weak brownish cytoplasmic granular S100A1 immunopositivity.  
(DAB chromogen and Hematoxylin counter stain x 250).

**Fig.7:** A case of renal oncocytoma showing a moderate brownish cytoplasmic granular immunopositivity for S100A1.  
(DAB chromogen and Hematoxylin counter stain x 200).

**Fig.8:** A case of renal oncocytoma showing a strong brownish cytoplasmic granular immunoreactivity for S100A1.  
(DAB chromogen and Hematoxylin counter stain x 200).

## Discussion.

Chromophobe RCC and oncocytoma are subtypes of renal tumors. Each has its characteristic histogenesis and clinical evolution. Therapy may be determined according to each subtype; radical or partial nephrectomy should be carried out for carcinoma while partial nephrectomy or observation is favorable for benign oncocytoma. Thus, the distinction between each subtype is clinically important. The differentiation of granular chromophobe RCC from oncocytoma is mandatory; since they are morphologically overlap (*Patton et al., 2004; Mete et al., 2005; Skinnider et al., 2005; Brunelli et al., 2005 and Shen et al., 2005*).

Hale's colloidal iron stain is often used for this differentiation; however, more than 80% were reported to be positive for chromophobe RCC and 60% negative for renal oncocytomas. Its disadvantages include the difficult performance & interpretation of the results. (*Wang and Milles, 2005*).

Ultrastructurally, chromophobe-type microvesicles demonstrated in the cytoplasm of neoplastic cells are another significant feature of chromophobe RCC (*Mete et al., 2005*) but this technique is routinely inconvenient (*Li et al., 2007*).

Various cytokeratins have been used for the differentiation (*Skinnider et al., 2005*); however, these markers have been limited in their value by other investigators (*Wang and Milles, 2005*).

Moreover; controversial results in the use of kidney-specific cadherin and Ron immunohistochemistry in had been found in this differentiation (*Patton et al., 2004 & Shen et al., 2005*).

S100A1 gene as one of 10 S100 gene family members is located on human chromosome 1q21. It has been reported that S100 proteins are involved in various biological activities like transduction of intracellular calcium signaling and cytoskeleton-mediated interactions in addition to cell cycle progression and cell differentiation. S100A1 is favourably studied in heart tissues (*Most et al., 2001*) as well as being reported to be expressed in human tumors (*Ilg et al., 1996; Heizmann et al., 2002; Teratani et al., 2002 and Li et al., 2005*).

Our study observed S100A1 immunoreactivity in all typical renal oncocytomas (100%) and was completely negative in all typical chromophobe RCC and also by immunoperoxidase we can differentiate the indefinitely diagnosed cases by routine Hx. & E. stain into three S100A1 positive tumors showing similar pattern of reactivity like the typical oncocytomas (most probably diagnosed RO) and two negative tumors like the typical chromophobe RCC (most probably diagnosed chromophobe RCC). These findings agreed with those displayed by *Li et al., 2007* who supported their immunohistochemical results by the RT-PCR findings as none of the chromophobe RCC expressed the S100A1 gene whereas all renal oncocytomas expressed this gene.

*Lin et al., (2006)* used a polyclonal antibody against S100 protein in the renal tumors and found that one of sixteen chromophobe RCCs expressed S100 while thirteen of fifteen oncocytomas expressed that protein. Therefore, S100A1 as such is more specific than S100 considering our and *Li et al., (2007)* findings.

Many techniques used to differentiate renal tumors such as flow cytometry, histochemistry for Hale's colloidal iron stain and electron microscopy are not clinically appropriate (*Li et al., 2005*). Moreover, fluorescence in-situ hybridization and comparative genomic hybridization have been shown promising in the differentiation of renal cell carcinomas by detecting chromosomal aberrations, however, they are also performed with difficulty (*Heinze and Kovacs, 2002; Wilhelm et al., 2002 and Li et al., 2007*).

Like in other human tumors, immunohistochemistry is the keystone in the discrimination of confusing renal tumors (*Li et al., 2007*).

In addition, the application of molecular markers in the differentiation of renal tumors is of a considerable interest (*Li et al., 2003 & Li et al., 2006*).

### Conclusion and Recommendation:

Our data indicate that S100A1 marker may be used in the differentiation of

chromophobe RCC from renal oncocytoma since there was a significant difference between both lesions. However, we can't assess the accuracy of this marker owing to the low number of our cases of these very uncommon neoplasms. In addition, this protein could be applied in the preoperative biopsy specimens of such tumors since the in fine-needle technique is difficult to differentiate their diagnosis.

Further studies on a large scale of cases are recommended to assess the accuracy of S100A1 in differentiating between these problematic renal tumors.

## References

- 1- Brunelli M, Eble JN, Zhang S, Martignoni G, Delahunt B, Cheng I (2005): Eosinophilic and classic chromophobe renal cell carcinoma have similar frequent losses of multiple chromosomes from among chromosomes 1,2,6,10 and 17 and this pattern of genetic abnormality is not present in renal oncocytoma. *Mod. Pathol.*, 18:161-9.
- 2- Cheville JC, Lohse CM, Zincke H, Weaver AL, Blute ML (2003): Comparisons of outcome and prognostic features among histologic subtypes of renal cell carcinoma. *Am. J. Surg. Pathol.*, 27:612-24.
- 3- Heinze F and Kovacs G (2002): Identifying BAC clones for diagnosis of conventional renal cell carcinoma by FISH. *Histopathol.*; 4:308-12.
- 4- Heizmann CW, Fritz G, Schafer BW (2002): S100 proteins: structure, functions and pathology. *Frontiers Bioscience*, 7:1356-8.
- 5- Iig EC, Schafer BW, Heizmann CW (1996): Expression pattern of S100 calcium-binding proteins in human tumors. *Int. J. Cancer*, 68:325-32.
- 6- Li G, Barthelémy A, Feng G, Gentil-Perret A, Peoc' hM, Genin C, Tostain J (2007): S100A1: a powerful marker to differentiate chromophobe renal cell carcinoma from renal oncocytoma. *Histopathol.*, 50:642-7.
- 7- Li G, Cuilleron M, Cottler M *et al* (2003): Rapid and sensitive detection of messenger RNA expression for molecular differential diagnosis of renal cell carcinoma. *Clin. Cancer Res.*, 9:6441-6.
- 8- Li G, Cuilleron M, Cottler M *et al* (2006): The use of MN/CA9 gene expression in identifying malignant solid renal tumors. *Eur. Urol.*, 49:401-5.
- 9- Li G, Gentil-Perret A, Lambert C, Genin C, Tostain J (2005): S100A1 and KIT gene expressions in common subtypes of renal tumors. *Eur. J. Surg. Oncol.*, 31:299-303.
- 10- Lin F, Yang W, Betten M, Teh BT, Yang XJ (2006): The French kidney cancer study group. Expression of S100 protein in renal cell neoplasms. *Hum. Pathol.*, 37:462-70.
- 11- Mete O., Kilicaslan I., Gulluoglu M.G., Uysal V. (2005): Can renal oncocytoma be differentiated from its renal mimics? The utility of antimitochondrial, caveolin 1, CD63 and cytokeratin 14 antibodies in the differential diagnosis. *Vichows Arch.*, 447:938-46.
- 12- Most P, Bernotat J, Ehlermann P *et al.* (2001): S100A1: a regulator of myocardial contractility. *Proc. Natl. Acad. Sci. USA*; 98:13889-94.
- 13- Patton KT, Tretiakova MS, Yao JL *et al.* (2004): Expression of RON proto-oncogene in renal oncocytoma and chromophobe renal cell carcinoma. *Am. J. Surg. Pathol.*, 28:1045-50.
- 14- Shen S.S., Krishna B., Chirala R., Amato R.J. (2005): Kidney-specific cadherin, a specific marker for the distal portion of the nephron and related renal neoplasms. *Mod. Pathol.*, 18:161-9.
- 15- Skinnider BF, Folpe AL, Henniger RA, *et al.* (2005): Distribution of cytokeratins and vimentin in adult renal neoplasms and normal renal tissue: potential utility of a cytokeratin antibody panel in the differential diagnosis of renal tumors. *Am J. Surg. Pathol.*, 29:747-54.
- 16- Teratani T, Watanabe T, Kuwahara F *et al.* (2002): Induced transcriptional expression of calcium-binding protein S100A1 and S100A10 genes in human renal cell carcinoma. *Cancer Lett.*, 175:71-7.
- 17- Wang HY and Milles SE (2005): KIT and RCC are useful in distinguishing chromophobe renal cell carcinoma from the granular variant of clear renal cell carcinoma. *Am. J. Surg. Pathol.*, 29:640-6.
- 18- Wilhelm M, Veltman JA, Olshen AB *et al.* (2002): Array-based comparative genomic hybridization for the differential diagnosis of renal cell carcinoma. *Cancer Res.*, 62:957-60.
- 19- Zambrano NR, Lubensky IA, Merino MJ, Linehan WM, Walther MM (1999): Histopathology and molecular genetics of renal tumors: toward unification of a classification system. *J. Urol.*, 162:1246-58.



بروتين اس 100 ايه 1 كدليل تمييزى محتمل بين سرطان خلايا الكلية الكروموفوبى

وورم الكلية الانكوسيتومى

احمد حسن عبد الرحمن 1 - مصطفى محمود خضير 2 - عماد صلاح الدين على 3 - أحمد مراد 4 -

وليد النبوى 5

من قسمى الباثولوجى 1 والمسالك 3 بكلية طب الازهر فرع اسيوط وقسمى الباثولوجى 2 والباطنه 4 بكلية

طب القاهرة والباطنه بكلية طب بنى سويف 5

تشتمل الانواع الشائعة لاورام الكلية على الورم التقليدى او ذو الخلايا المفرغة والورم الحليمى والورم الكروموفوبى ( الذى لايقبل الصبغة ) والانكوسيتومى ونظرا لصعوبة التفرقة بين الورم الكروموفوبى والانكوسيتومى فقد تم تقييم البروتين S100A1 كدليل تمييزى جديد بين هذين النوعين من الاورام ففى هذه الدراسة التى اجريت على عشرين حالة مختارة منهما شخصت بالطريقة الروتينيه الهستوباثولوجية - باستخدام صبغة الهيماتوكسلين والايوسين- الى سبع حالات للورم الكروموفوبى النموذجى وثمانى حالات للورم الانكوسيتومى النموذجى اما الحالات الخمس الباقية فأظهرت خصائص شكلية متشابهة لخلايا الورم ولم يتم تأكيد تشخيصها بهذه الصبغة ولكن بعدعمل البيروكسيد باستخدام الجسم المضاد للبروتين S100A1 اتضح وجود حبيبات كثيفة بنيه اللون فى سيتوبلازم خلايا الورم لثلاثة من الحالات الغير مؤكده التشخيص بالطريقة الروتينيه وبنفس النمط الايجابى فى الحالات الثمانية للورم الانكوسيتومى النموذجى بينما كانت الحالتين الباقيتين غير ايجابية لهذا البروتين مثل كل حالات الورم الكروموفوبى النموذجى ومن ذلك نستنتج ان البروتين S100A1 قد يكون دليلا مميزا قويا له القدرة على التفرقة بين الورم الكروموفوبى والورم الانكوسيتومى خصوصا عند وجود شك فى تشخيص هذه الاورام بالطريقة الهستوباثولوجية الروتينيه .