

Department of Veterinary Medicine,
Al-Qassim Univeristy, Buraydah, Kingdom of Saudi Arabia

A CASE REPORT ON SPONGIFORM ENCEPHALOPATHY LESION IN A PIGEON (With 3 Figures)

By

O.M. MAHMOUD and M.A. AL-DUBAIB

(Received at 26/12/2005)

أفات الاعتلال الاسفنجي الدماغى فى حمامة

أسامة محمد محمود ، مساعد أحمد الضبيب

شكا صاحب مزرعة حمام بمدينة بريدة بالقصيم (وسط المملكة العربية السعودية) بأن إحدى الطيور ظهر بها سلوك وأعراض مرضية غريبة. عند فحص الطائر وجد أنه فقد القدرة على الطيران ويصطدم بالأشياء حوله مع وجود حركات غير طبيعية وضعف فى عضلات الرقبة والرأس، فى بعض الأحيان يفقد الطائر التحكم فى الوضع الطبيعى للرأس ويسقط تجاه الأرض وقد يسند عليها، كذلك قد يلتوى الرأس الى أعلى أو جانبيا. فى بعض الاحيان يظهر الضعف على الأرجل ويجلس الطائر ممتعا عن الحركة. عند إجراء فحص بسيط لنظر الطائر (يتجنب الطائر تقريبا الاصبع تجاه العين) وفحص السمع (يتحرك الطائر عند التصفيق باليد) وجد أن قدرة الحمامة على البصر والسمع الطائر جيدة. فى بعض الاحيان كان الطائر يعود طبيعيا حيث يأكل ويشرب. تم التحفظ على الطائر فى حظيرة حيوانات التجارب التابعة لقسم الطب البيطرى ولكن اعتلت صحتة بعد أربعة أيام وتم قتله وتشريحه. أوضح التشريح عدم وجود آفات عيانية فى كل أعضاء الجسم، كذلك أوضح الفحص المجهرى عدم وجود آفات فى كل أعضاء الجسم ماعدا الدماغ، وكانت آفات النسيج العصبى عبارة عن فجوات فى الخلايا العصبية بالنخاع المستطيل. هذه الآفات تطابق إلى حد كبير آفات الاعتلال الدماغى الاسفنجى، كما وجد تنكس للخلايا العصبية خاصة تلك الموجودة حول الأوعية الدموية.

SUMMARY

An owner of a pigeon farm in Buraydah (Central Saudi Arabia) complained that one of his birds developed abnormal behaviour and signs. Clinically the bird was unable to flight, running into objects and showed unusual movement of the head and neck together with weakness of the muscles of legs and neck. In certain instances, the pigeon failed to hold the head in position and it dropped downward and rested on the ground. The head might also be twisted to face upwards or laterally.

Sometimes the legs were so weak and the bird assumed a sitting position and was reluctant to move when pushed. Simple tests for vision

(avoiding an approaching figure towards the eyes) and hearing (jerking to clamping) showed that the bird vision and hearing were normal. At certain times, the bird reverted to normal and when it offered grains and water, it ate and drank normally. The bird was kept in the Experimental Animal House at the Department of Veterinary medicine for observation but its condition deteriorated 4 days later and was sacrificed and post-mortemed. On post-mortem examination, no gross lesions could be observed in internal organs or the brain. Histopathological examination showed no microscopical lesions in the liver, heart or kidneys, but a nearly typical lesion of spongiform encephalopathy was seen in the brain. Small to very large vacuoles were seen in the cytoplasm of medullary neurons. Degeneration of some neurons was also seen especially around blood vessels.

Key words: Pigeon, spongiform encephalopathy, mad pigeon disease

INTRODUCTION

Spongiform encephalopathy is a neuro-degenerative brain-lesion that has been shown to occur in diseases like scrapie of sheep and goat, bovine spongiform encephalopathy (BSE, mad cow disease), chronic wasting disease of mule deer and elk, transmissible spongiform encephalopathy of mink, spongiform encephalopathy of cats; Creutzfeldt-Jakb disease (KJD), Kuru disease and Gerstmann-Straussler syndrome of man (Thomson, 1988). These diseases have common characteristics in being chronic and fatal. They also present a similar histopathological picture of degeneration and vacuolation of central nervous system neurons and absence of inflammation. This microscopic picture remains a core diagnostic feature of spongiform encephalopathy diseases (Jones *et al.*, 1997).

The etiology of spongiform encephalopathy has been linked to deformed prion protein (Jones *et al.*, 1997). Genetic background has been extensively studied in sheep and cattle for the purpose of controlling these diseases and protecting against transmission to humans.

Spongiform diseases have characteristic clinical signs. For example, scrapie of sheep presents different manifestations of clinical signs including behavioural changes, pruritus, incoordination, wool loss, weight loss and death (Martin, 1997).

The available literature revealed no reports dealing with spongiform encephalopathy in pigeons or any other birds.

In this case report, we describe behavioural changes and clinical signs in a pigeon that had lesions in the midbrain characterized by vacuolation and degeneration of nerve cells, a lesion consistent with spongiform encephalopathy occurring in other species of animals.

MATERIALS and METHODS

A pigeon that developed unusual clinical signs was sacrificed and post-mortmed. Specimens from the heart, kidneys, liver, and brain were fixed in 10% formol-saline. These were later processed for routine histopathology and thin section (5 um) were cut and stained with haematoxylin and eosin..

RESULTS

Case history:

An owner of a pigeon farm in Buraydah city (Central Saudi Arabia) complained that one of his pigeons started to behave abnormally and lost its ability to fly. The farm comprised about 350 pigeons of a local saudi mixed-breed. The birds were kept in a semi-free system of husbandry where they are released from their pens early morning and allowed to fly free around the farm. They return to their pens at sunset. The farm also grew some date and pomp trees, and alfa alfa fodder. No other animals were kept in the farm. The pigeons were fed on grains and pick from the alfa alfa green leaves. The farmer said that he had not seen this disease before and no other pigeons showed similar clinical signs in the farm. The pigeon was about 1.5 years of age and white feathered.

Clinical signs:

The signs appeared in episodes for about of 1-2 minutes followed by complete reversion to normal for several minutes. During the normal period, the bird ate and drank normally. The clinical signs were running into objects, failure to hold the head and neck in position and then dropped downwards or rested on the floor. In certain instances, the head was twisted to face upwards or laterally with evident weakness of the legs and the pigeon assumed sitting position (Fig. 1a & b).

Simple test of vision (avoiding an approaching finger towards the eye) indicated the pigeon was seeing normally. Again, when the hands were clapped the bird jerked indicating that hearing was normal.

The pigeon was kept in a cage at the Department of Veterinary Medicine for observation. Its condition deteriorated 4 days later and it was sacrificed and post-mortmed.

Post-mortm examination:

No gross lesions in any of the internal organs including the brain could be detected.

Histopathological examination:

No microscopic lesions were observed in all tissue specimens except the brain. The medullary neurons contained vacuoles in their cytoplasm. The size and number of these vacuoles varied. Some cells had one or two vacuoles in their cytoplasm but multiple small vacuoles were also seen filling the neuronal cytoplasm (Fig. 2). Degeneration of some neurons was seen in some nerve cells especially those around blood vessels (Fig.3).




Fig. 1a: Failure to control the head and neck floor




Fig. 1b: Resting of head on the floor

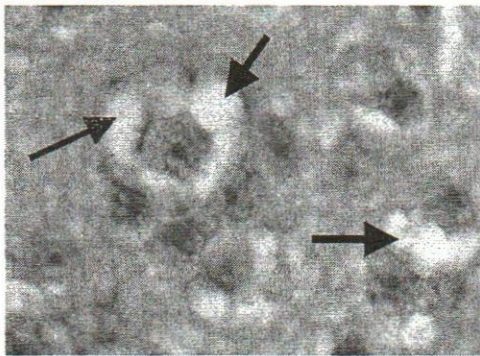


Fig. 2: Vacuoles alllover the cytoplasm
H&E x400

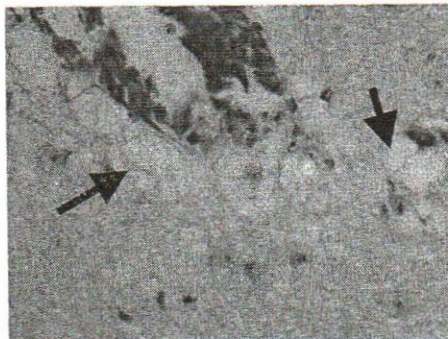

Fig. 3: Neuronal degeneration and vacuolation around blood vessels

DISCUSSION

The vacuolation of neurons is a consistent diagnostic lesion of spongiform encephalopathy diseases (Jones *et al.*, 1997 and Soto, 2004). The lesion has been seen in the brains of animals and man affected with diseases such as scrapie of sheep, bovine spongiform encephalopathy, human Creutzfeldt-Jacob Disease (CJD) and Kuru. All of which are classified as spongiform encephalopathies. No previous report described of such lesions in the brain of birds.

Atrefacts similar to spongiform encephalopathy lesions in neurons may occur in autolysed brains, but in this study the pigeon has been sacrificed and its brain was fixed immediately, thus eliminating such possibility.

Spongiform encephalopathy diseases in farm animals and man have been linked to relevant causes of transmission. For example, BSE has been considered to originate from sheep with scrapie through incorporation of infected meat and bones into bovine rations. Humans developed the disease after eating infected bovine meat. The disease has also been reported in cats (wild and domestic) and linked to eating BSE-infected meat (Martin, 1997).

Trying to trace possible links to the cause of spongiform encephalopathy disease in the examined pigeon, we failed to reach a possible explanation. The pigeons were feed on grains and some alfaalfa fodder and there was no spongiform disease reported in farm animals in the area.

Spongiform encephalopathy diseases have been extensively studied in farm animals particularly sheep and cattle to control transmission to humans. The disease in the avian species remained unknown. Human health concerns, economical factors (sheep and cattle farming), preformed concept that the disease is linked to meat consumption, have diverted scientists from looking for the disease in species other than mammals. The disease is not expected to occur in pigeons because of the speices barrier for transmission (pigeons do not eat meat). This barrier has been crossed only in scrapie of sheep (BSE) and mad cow disease of cattle (KJD). Pigeon meat is eaten by many African and Asian populations and if there is a remote chance this disease may be transmitted to humans or any meat eating species (canines, felines, birds of pray etc), steps should be taken to investigate its epidemiology in these species.

There is always the question as to whether this disease is new or was it there before and are there other factors that can alter the normal prions (other than infected meat). A recent hypothesis suggested that spongiform encephalopathies may be a result of a chronic CNS autoimmune disease (Zhu, 2005).

Control measures in farm animals based on genetic analysis and slaughter of carriers of defective prions will soon be put in action. It will not be easy to implement these measures in birds and other methods of control should be thought..

REFERENCES

- Jones, T.C.; Hunt, R.D. and King, N.W. (1997): Prions. In: Veterinary Pathology, 6th edition. Williams and Wilkins, a Waverly Company, pp. 360 – 367.*
- Martin, W.B. (1997): Scrapie, BSE and CJD. Proceedings of the 4th International Congress for Sheep Veterinarians. University of New England. Australia, pp 445.*
- Soto, C. (2004): Diagnosing prion diseases: Needs, challenges and hopes. Nature Review of Microbiology, 2 (10) 809 – 819.*
- Thomson, R.G. (1988): Scrapie. In: Veterinary Pathology. Marcell Dekker Inc. Toronto, Philadelphia, USA, pp. 546 – 547.*
- Zhu, B.T. (2005): Human and animal spongiform encephalopathies are the result of chronic autoimmune attack on the central nervous system: A novel medical theory supported by experimental evidence. Histology and Histopathology, 20 (2): 575 – 592.*