

Dept. of Forensic Medicine and Toxicology,  
Fac. of Vet. Med., Assiut Univ., Egypt.

## EAR CONFIGURATION AS A TOOL FOR IDENTIFICATION AND AGE DETERMINATION IN CAMEL FETUSES

(With One Table, 4 Figures and 3 Plates)

By

**MANAL ABDEL-LATIF; EMAN EZ-ALDAWLA SHARKAWY;  
M. ABDEL MONEIM, \* and A.M. SALEH\***

\* Dept of Anatomy and Histology, Fac. of Vet. Med., Assiut Univ., Egypt.

(Received at 21/9/2006)

الشكل الخارجى للأذن كوسيلة للاستعراف وتقدير العمر فى أجنة الجمال

منال عبد اللطيف ، ايمان عز الدولة شرقاوى ، محمد المحرزى عبد المنعم،  
عبد المهيمن صالح

يعتبر تقدير العمر فى الأجنة من النقاط الهامة من الوجهه الطبية الشرعية خاصة فى حالات الإجهاض الجنائى للأناث. وقد أمكن تقدير العمر فى الأجنة بوسائل كثيرة مثل قياس طول العمود الفقرى أو تحديد مواعيد ظهور وتوزيع الشعر على جسم الجنين. وقد تم فى هذا العمل دراسة الشكل الخارجى لأذن أجنة الجمال وكذلك مقاييسها الخارجية كوسيلة سهلة لتقدير العمر بالإضافة الى بعض المقاييس المورفولوجية الأخرى المساعدة. وقد تمت هذه الدراسة على عدد ١٥٠ جنين جمل يمثل الفترة الجنينية الكاملة طول العمود الفقرى حيث تراوح عمرها ما بين ٢،٤ و ١٢،٠٢ شهر وما يعادل ٢،٨ سم و ١٠،٨ سم من طول العمود الفقرى. وقد أوضحت النتائج أن عند عمر ٢،٤ شهر (٢،٨ سم) يبدأ ظهور بدايات تكون الأذن الخارجية على هيئة تجويف محاط بنمو نسيجي يحيط بفتحة بيضاوية. عند عمر ٢،٦٦ - ٢،٧٨ شهر (٥،٢ - ٦،٥ سم) يزيد هذا النسيج فى الحجم ليكون أنثانتين طويلتين، إحداهما أمامية وأخرى خلفية. عند عمر ٢،٩١ - ٣،٥٥ شهر (٨ - ١٥ سم) تزيد الأنثانة الخلفية فى الحجم تدريجيا لتصنع زائدة مثلثة الشكل تغطى معظم فتحة الأذن الخارجية. عند عمر ٣،٦٤ - ٤،٠١ شهر (١٦ - ٢٠ سم) تتعكس هذه الزائدة للخلف لتأخذ وضعها الطبيعى بعد ذلك. بعد هذا العمر تم متابعة تطور الأذن توصيفيا وقياسيا حتى نهاية العمر الجنينى حيث يتم تكوين الأذن.

### SUMMARY

This study was conducted on 150 camel fetuses representing the whole prenatal life. The age was represented by months and crown vertebral rump length (CVRL), where they aged from 2.4 to 12.02 months and

2.8 cm to 108 cm CVRL. Several morphological measurements Head length (HL), Interear distance (IED), IED/HL %, Ear length (EL), Ear width (EW), ear-eye distance and ear-mouth distance were carried out. The results revealed that at age 2.4 months (2.8 cm CVRL) first branchial groove (the premordium of external ear) appeared as a growth of mesenchymal tissue surrounding oval opening. At 2.66 – 2.78 months (5.2 – 6.5 cm CVRL) the mesenchymal tissue increased in size to form two longitudinal folds, rostral and caudal. At 2.91 – 3.55 (8.0 – 15.0 cm CVRL), the caudal fold gradually increased in size forming triangular flap covering almost the external ear opening. At 3.64 – 4.01 months (16 – 20 cm CVRL) the fold reflected caudally. Morphological and biometric studies were followed on ear till full term fetuses where the external ear reached nearly its mature form.

*Key words: Camel fetuses, external ear, age determination*

## INTRODUCTION

Determination of fetal age is very important in forensic medicine specially in case of criminal abortion. Determination of age can be done by means of crown vertebral rump length (CVRL, Alam El-Din, *et al.*, 1992) or by appearance and distribution of hair along the fetal body (Manal Abdel-latif and Saleh, 2005). Many authors studied the development of external ear in domestic animals and human (Jakobovits, *et al.*, 1972, Shinohara, *et al.*, 1991, Shimizu, *et al.*, 1992, Alvord and Farmer, 1997, Wright, 1997, Bruzewiez, 2000). As the available literature lack any data about the development or morphology of the external ear of camel fetuses. The aim of this work is to study the configuration and biometric illustration of fetal camel ear as a fine and much easier method for age determination.

## MATERIALS and METHODS

The present study was carried out on 150 camel fetuses aged from 2.4 to 12.02 months and CVRL ranged from 2.8 to 108 cm (Table 1). The fetuses were collected from Cairo slaughterhouse. Immediately after slaughtering, the fetuses were fixed by perfusion of 10% formalin through the umbilical artery and then stored in the same solution.

The CVRL was measured by a line extending between the medial canthi of the two eyes to the root of the tail passing through the hump.

HL was measured from the line extending between the medial canthi of the two eyes to the base of the skull. IED measured by a line extends between the tips of the two ears. EL was measured as a line between the tip of the ear till its base, while EW was measured as a distance between the dorsal and ventral edges of the ear. Distance between ear and eye was measured as a line between the base of the ear and lateral canthus of the eye. Distance between ear and mouth was measured as a line extends between the base of the ear and the labial commissure. Camel fetuses were divided into 8 groups according to their CVRL (Table 1). Gestation days were calculated according to the formula stated by El-wishy, *et al.* (1981):

$$Y = 0.366X - 23.99$$

(Y = CVRL and X = gestation days)

- Angle between ear, eye and mouth was measured using computer program Autocad

## RESULTS

### 1- Morphological investigation:

In the camel fetus of 2.4 months (2.8 cm CVRL) a growth of mesenchymal tissue was observed surrounding a small nearly oval opening which represents the first branchial groove. This structure is considered to be the primordium of the external ear. This primordium is situated ventral to the primordia of both the mouth and eye (Plate 1a & 2).

At 2.53–2.6 months (3.8–4.2 cm CVRL), the mesenchymal tissue was increased in the size, the opening has a slit like appearance. The future external ear lies caudal to the mouth but at a lower level, it situates ventrocaudally to the eye (Plate 1a & 2).

In the camel fetuses of 2.66–2.78 months (5.2–6.5 cm CVRL), the mesenchymal tissue of the external ear is divided into two unequal folds. The rostral smaller one is the mandibular fold and the caudal larger one is the hyoid fold. The opening which is flanked by the two folds becomes curved in outline. This opening is the future external acoustic meatus. At this developmental period the external ear lies caudal to the mouth but at the same level (Plate 1a & 2).

In 2.91–3.55 months (8.0–15.0 cm CVRL), showed that the caudal or the hyoid fold becomes larger in size and has the form of triangular ear flap with a rostrally directed apex covering the external acoustic meatus. Therefore the internal aspect of the ear flap is not

visible. The external ear lies here caudal to the mouth but at a higher level (Plate 1a & 2).

At 3.64 months (16 cm CVRL), the flap of the left ear has a rhomboid shape, it becomes inverted consequently its apex is directed caudally. The external and internal aspects of the auricle can be differentiated, the external aspect is directed medially, while the internal one is directed laterally. On the contrary, the flap of the right ear at this age is still triangular in shape and everted as the previous ages, therefore the apex of the auricle remains here rostrally directed (Plate 1a & 2).

At 4.01 months (20 cm CVRL), the flap of both right and left ears becomes inverted. The external and internal aspects of both ears are visible. Moreover, the internal aspect of the auricle shows poorly developed folds (Plate 2).

At 4.64 months (25 cm CVRL), the auricle is ovoid-shaped with a laterally directed internal aspect carrying folds. The auricular folds are separated by deep fissures. At this age the primordium of the tragus is differentiated at the basal part of the external ear (Plate 2).

At 8.56 months (70 CVRL), short fine hairs are observed in the internal aspect of the ear auricle, at 10.84 months (95 cm CVRL), the border and the internal aspect of the auricle are covered by dense hair with the advancement of the age while at 11.11–11.75 months (98–105 cm CVRL), the external ear is covered by heavy pigmented hair (Plate 1b).

## **2- Morphometrical analysis:**

The external ear measures 0.10 cm long at 2.4–2.68 months (2.8–5.5 cm CVRL), it increases in length with the advancement of the age to reach 1.05cm at 5.01–5.74 months (31–39 cm CVRL) and 4.00 cm at 10.84–12.02 months (95–108 cm CVRL). This means that the length of the ear at the last stage is about forty folds at the early stage of development. The width of the ear is 0.18 cm at 2.4 – 2.68 months (2.8 – 5.5 cm CVRL) and reaches 3.33 cm at 10.84–12.02 months (95–108 cm CVRL). This indicates that the width of the ear at the last stage is about eighteen folds at the early stage of development (Table 1 & Fig. 2).

The correlation between the length and width of the external ear at the different stages of the prenatal period shows that at the early stage (2.4–2.68 months, 2.4–2.68 months), the ear length is about 55% of the ear width. However, at 3.32–3.92 months (12.5–19 cm CVRL), the length and width of the ear are nearly equal. Then after the rate of increasement in the length is more than in the width, therefore at the last

stage (10.84–12.02 months, 95–108 cm CVRL) the ear length becomes about 121.2 % of the ear width (Table 1 and Fig. 2).

The interear distance is about 0.78 cm at the early stage of development (2.4–2.68 months, 2.4–2.68 months). This distance increases with the advancement of the age till reaches its maximum value at 5.01–5.74 months (31–39 cm CVRL). Then after the interear distance decreases towards the end of the gestation period to reach 1.27 cm at full term fetus. (Table 1 and Fig. 1).

The distance between the ear and both of the mouth and eye are nearly equal at the early developmental stage. These distances increase during the whole prenatal period to become 15.33 cm in case of the mouth and 7.90 cm in case of eye at the last stage of development (Table 1 and Fig. 3).

### **3- Position of the ear and its relation to eye and mouth**

During the development of the head region, the primordial of ear showing marked migration caudally and dorsally. So, the position of the ear at 2.4 months (2.8 cm CVRL) lies ventral to the eye and mouth, moreover the angle between ear, eye and mouth was 33.7 degree (Plate 1a & Fig. 4a).

At 2.66 months (5.2 cm CVRL) the developing ear migrates caudodorsally and lies at the same level of the angle of the mouth and the ear, eye and mouth angle increases and becomes more or less abright (95.68 degree) (Plate 1a & Fig. 4c).

At age 3.64 months (16.0 cm CVRL) the developing ear migrates farther caudodorsally and takes intermediate position between eye and mouth, therefore the ear, eye and mouth angle becomes obtuse (135.86 degree) (Plate 1a & Fig. 4e).

At full term fetus the developing ear lies more or less at the level of the eye, consequently the angle becomes more obtuse (143.51 degree) (Plate 1a & Fig. 4f).

Table 1: Measurements of camel fetuses

No.	Age by CVRL	Age by days	Age by months	Head length (HL)	Inter ear distance (IED)	IED/HL (%)	Ear length (EL)	Ear width (EW)	Ear eye distance	Ear mouth distance
1	2.8	73.2	2.4	0.7	0.6	85.7	ND	0.2	0.2	0.1
2	3.0	73.7	2.5	0.9	0.8	88.9	0.1	0.2	0.2	0.2
3	3.8	75.9	2.53	1.1	0.6	54.5	0.1	0.1	0.2	0.2
4	4.0	76.5	2.55	1.5	0.6	40.0	0.1	0.2	0.2	0.1
5	4.7	78.4	2.61	1.9	1.0	52.6	0.1	0.2	0.3	0.35
6	5.2	79.8	2.66	2.0	0.9	45.0	0.1	0.15	0.3	0.4
7	5.5	80.5	2.68	2.1	1.0	47.6	0.1	0.2	0.3	0.4
Mean				1.46±0.5	0.78±0.17	59.19±18.34	0.1±0.0	0.18±0.04	0.24±0.05	0.25±0.05
8	6.5	83.3	2.78	3.0	1.1	36.7	0.1	0.2	0.4	0.8
9	7.0	84.7	2.80	2.3	1.2	52.2	0.1	0.2	0.4	0.8
10	8.0	87.4	2.91	2.5	1.2	48.0	0.1	0.2	0.5	0.9
11	8.8	89.6	2.99	2.7	1.2	44.4	0.15	0.2	0.6	1.0
12	10.5	92.9	3.10	5.0	1.9	38.0	0.2	0.2	0.8	1.4
13	10.8	95.1	3.17	4.0	1.6	40.0	0.2	0.2	0.6	1.3
Mean				3.25±0.9	1.37±0.3	43.22±5.6	0.14±0.04	0.20±0.0	0.55±0.1	1.03±0.2
14	12.5	99.7	3.32	4.3	1.4	32.6	0.2	0.3	0.8	1.5
15	13.5	102.4	3.41	4.8	1.8	37.5	0.2	0.3	1.0	1.8
16	13.8	103.3	3.44	5.1	1.9	37.3	0.2	0.3	1.0	1.9
17	14.3	104.6	3.49	6.4	2.1	32.8	0.2	0.3	1.1	2.0
18	14.6	105.4	3.51	5.7	1.9	33.3	0.2	0.3	1.2	2.2
19	15.0	106.5	3.55	7.2	2.5	34.7	0.3	0.3	1.3	2.3
20	16.0	109.3	3.64	7.4	2.2	29.7	0.4	0.4	1.4	2.7
21	18.0	114.7	3.82	7.2	1.6	22.2	0.4	0.4	1.5	2.9
22	19.0	117.5	3.92	7.8	1.7	21.8	0.6	0.4	1.7	2.9
Mean				6.21±1.2	1.9±0.3	31.32±5.5	0.3±0.1	0.33±0.04	0.22±0.3	2.24±0.4
23	24.0	131.1	4.37	9.1	1.9	20.8	0.7	0.6	2.1	4.0
24	26.0	136.6	4.55	9.7	2.0	20.6	0.8	0.7	2.2	4.0
25	27.5	139.3	4.64	9.8	2.1	21.4	0.9	0.7	2.3	4.2
26	28.0	142.0	4.73	9.7	2.9	29.9	0.8	0.6	2.5	4.3
27	29.0	144.8	4.83	10.5	2.7	25.7	1.0	0.8	2.5	4.4
28	30.0	147.5	4.92	9.9	2.8	28.3	1.0	0.8	2.6	4.4
Mean				9.78±0.4	2.4±0.4	24.45±3.7	0.87±0.1	0.7±0.1	2.37±0.2	4.22±0.2
29	31.0	150.2	5.01	10.2	3.0	29.4	1.0	0.9	2.6	4.8
30	32.0	153.0	5.1	11.0	3.0	27.3	0.9	0.7	2.5	5.0
31	33.0	155.7	5.19	11.2	3.3	29.5	1.0	0.8	2.7	5.0
32	35.5	161.2	5.37	10.8	3.2	29.6	1.2	1.0	3.0	5.3
33	36.0	163.9	5.46	12.5	3.5	28.0	1.0	0.9	3.4	5.5
34	39.0	172.1	5.74	14.0	3.4	24.3	1.2	1.1	3.5	6.0
Mean				11.62±1.3	3.23±0.2	28.02±1.9	1.05±0.1	0.9±0.1	2.95±0.4	5.27±0.4
35	43.0	183.0	6.10	14.8	3.0	20.3	1.3	1.1	4.0	6.7
36	43.5	184.4	6.15	15.0	3.0	20.0	1.4	1.2	4.0	6.8
37	44.0	185.8	6.19	15.7	3.1	19.7	1.5	1.2	4.0	7.0
38	47.5	195.3	6.31	15.5	3.2	20.6	1.4	1.2	4.2	7.2
39	49.0	199.4	6.65	17	3.3	19.4	1.5	1.4	4.0	7.3
Mean				15.6±0.8	3.12±0.1	20.0±0.4	1.42±0.1	1.22±0.1	4.04±0.1	7.00±0.2
40	61.0	232.2	7.74	19	3.3	17.4	2.0	1.7	5.0	9.0
41	62.0	234.9	7.83	19	2.8	14.7	2.0	1.7	5.3	9.5
42	65	243.1	8.10	20	3	15.0	2.2	1.9	5.5	10.0
43	67	248.6	8.29	20	3	15.0	2.3	2.0	6.0	10.5
44	70	256.8	8.56	21	2.5	11.9	2.5	2.4	6.5	11.0
Mean				19.8±0.8	2.92±0.5	14.8±1.8	2.2±0.2	1.94±0.2	5.66±0.5	10.0±0.7
45	95	325.1	10.84	23	1.3	5.7	3.2	2.5	7.2	14.5
46	105	352.4	11.75	27	1.3	4.8	3.8	3.3	8.0	15.5
47	108	360.6	12.02	27.5	1.2	4.4	5.0	4.2	8.5	16.0
Mean				25.83±2.01	1.27±0.1	4.97±0.5	4.0±0.6	3.33±0.7	7.9±0.5	15.33±0.5

Fig. 1: Head length in relation to the interear distance during prenatal period in camel.

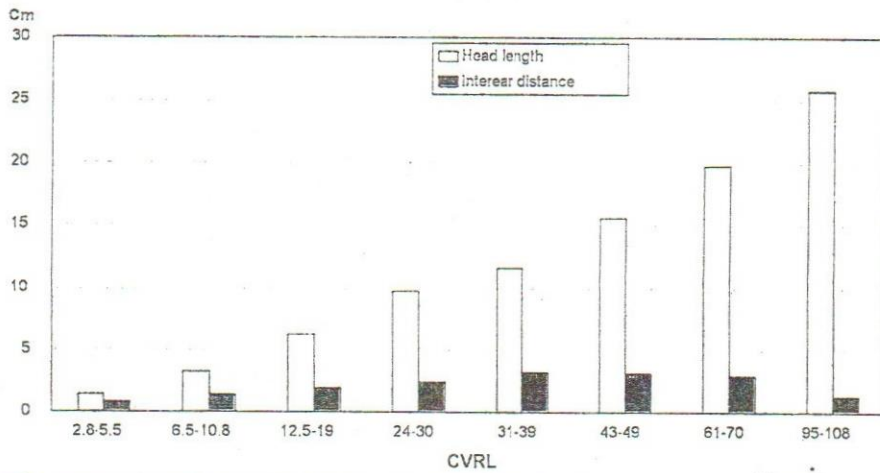


Fig. 2: Ear length in relation to the ear width during prenatal period in camel.

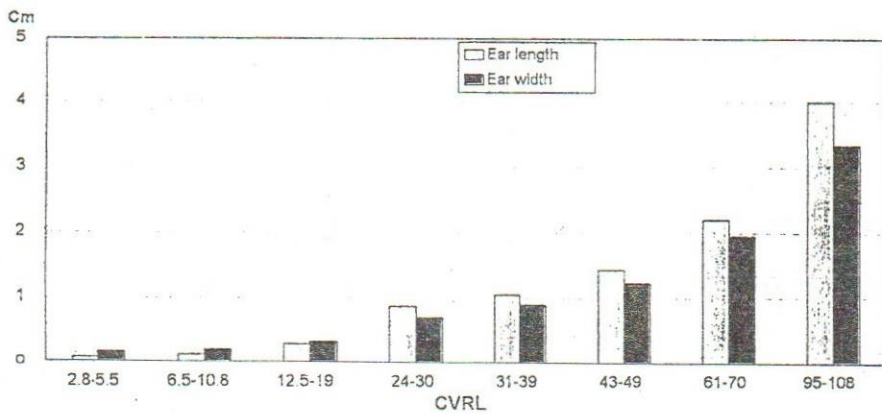
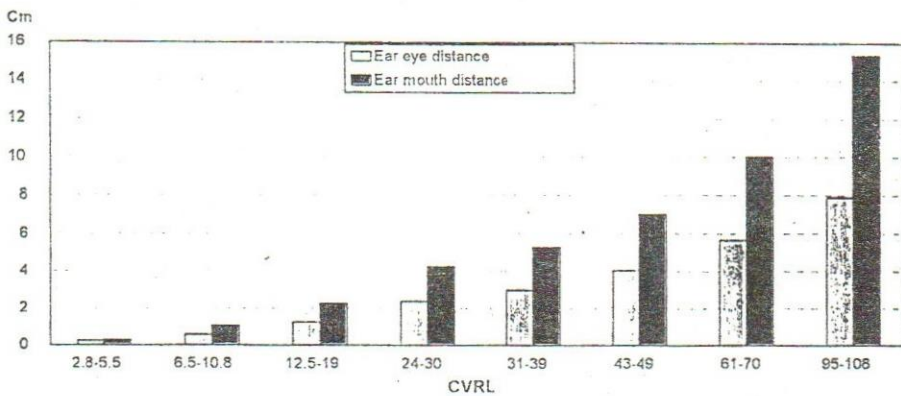
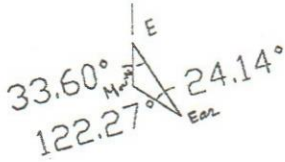


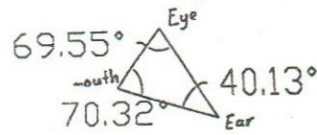
Fig. 3: Ear eye-distance in relation to ear-mouth distance during prenatal period in camel.



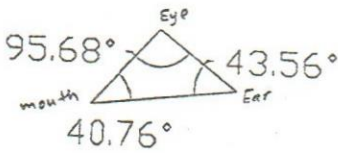
**Fig. 4: Triangles between ear, eye and mouth at different CVRL**



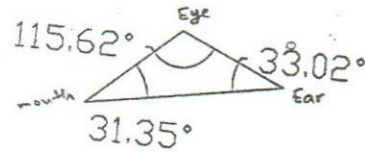
**a) 2.4 months  
(2.8 cm CVRL)**



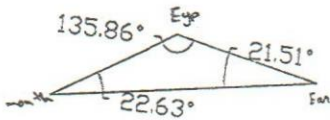
**b) 2.6 months  
(4.2 cm CVRL)**



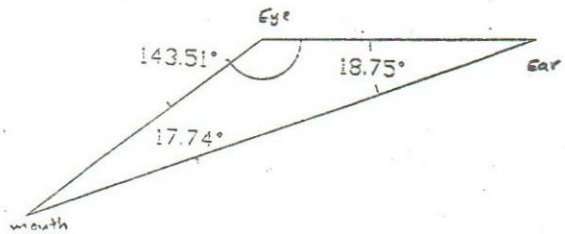
**c) 2.66 months  
(5.2 cm CVRL)**



**d) 2.91 months  
(8.0 cm CVRL)**



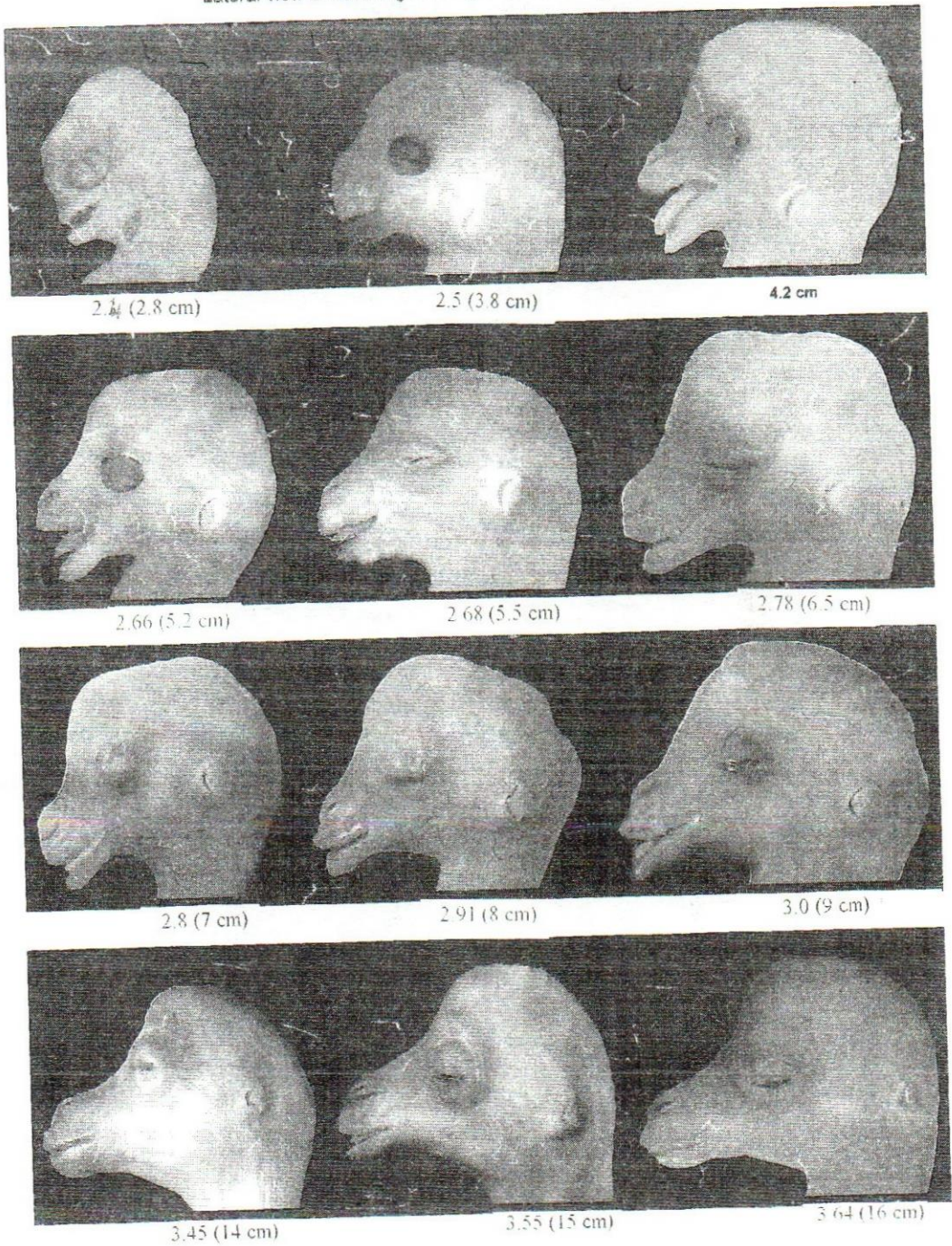
**e) 3.64 months  
(16.0 cm CVRL)**



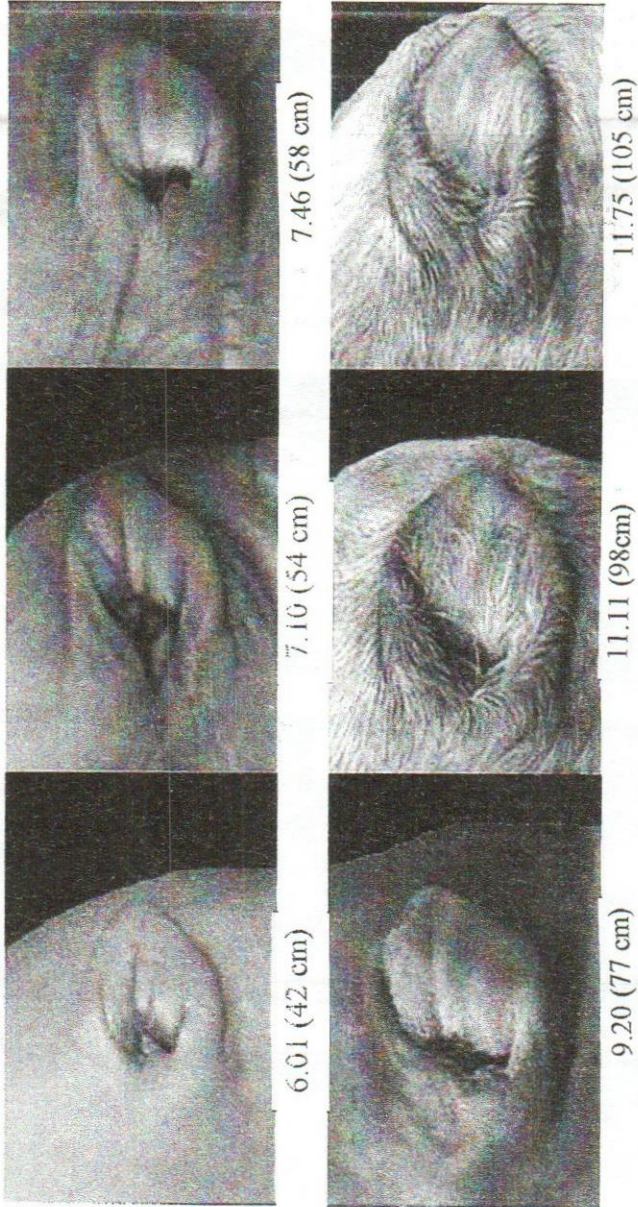
**f) 11.75 months  
(105.0 cm CVRL)**



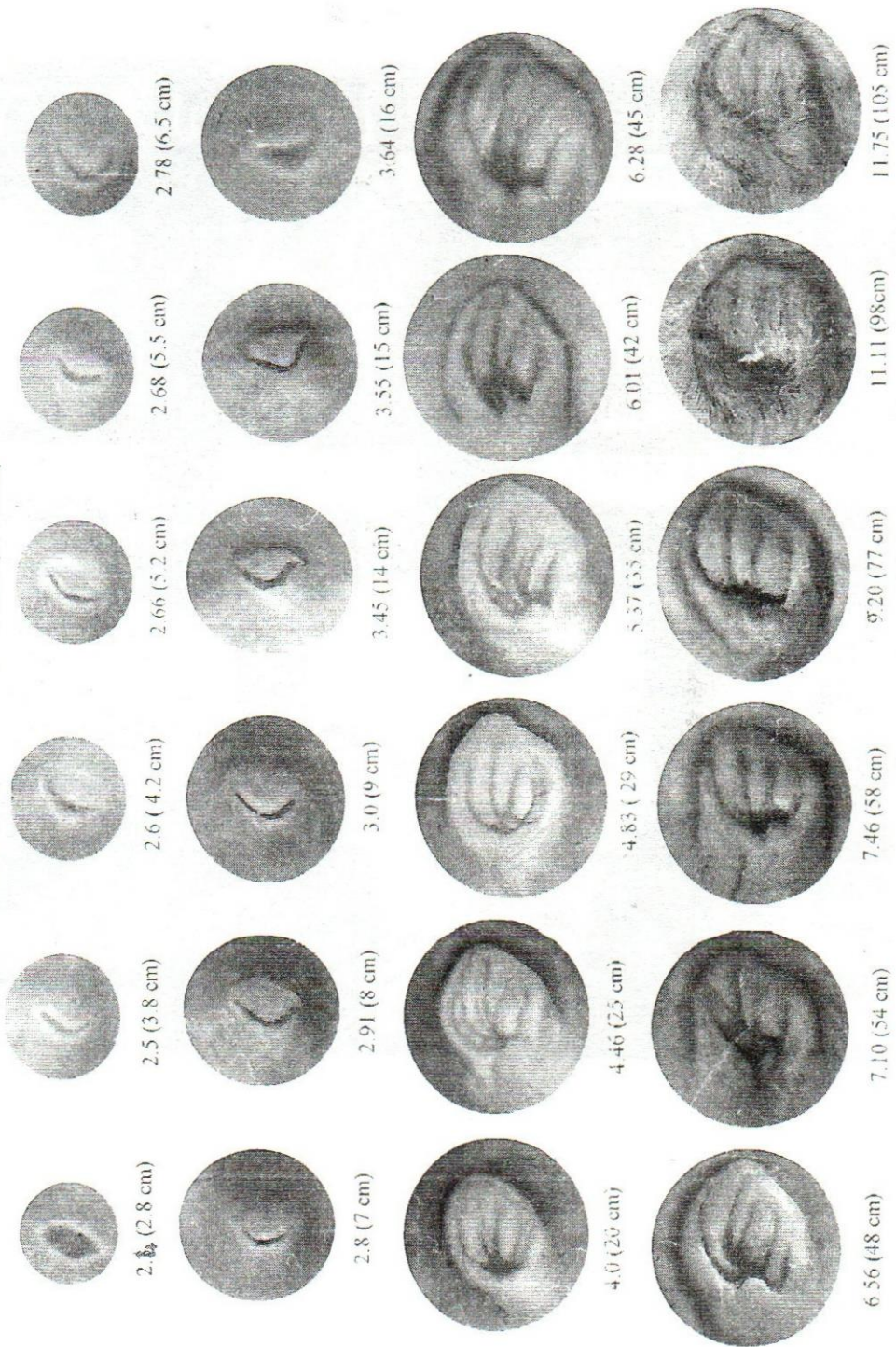
**Plate 1a: Prenatal development of the external ear in one humped Camel .**  
Lateral view of head region . age represented by months (CVRL)



**Plate 1b : Lateral view of head region {age represented by months (CVRI.)}**



**Plate 2: Prenatal development of the external ear in one humped camel.**  
 {age represented by months (CVRL)}

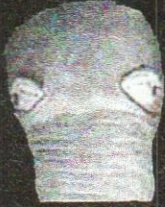

**Plate 3** Inter ear distance ( caudal view )

{age represented by months (CVRL)}



7.65 (60 cm)



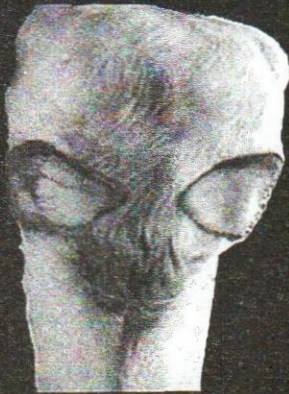8.56 (70 cm)



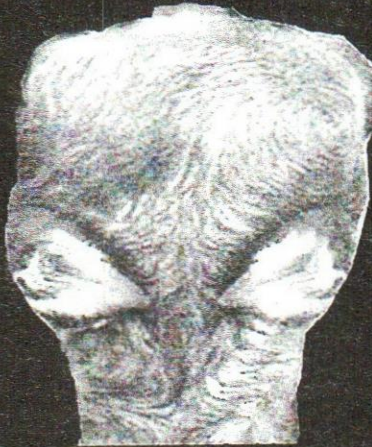9.47 (80 cm)



10.38 (90 cm)



10.84 (95 cm)



11.75 (105 cm)



12.02 (108 cm)

## DISCUSSION

The present work shows that in the camel fetus of 2.4 months (2.8 cm CVRL), a growth of mesenchymal tissue was observed surrounding small nearly oval opening (first branchial groove). This structure is considered to be the primordium of the external ear. At 2.66–2.78 months (5.2–6.5 cm CVRL), the mesenchymal tissue of the external ear is divided into two unequal folds, rostral small mandibular and caudal large hyoid fold. The opening becomes curved in outline. Patten and Carison (1974) supported this statement in the human and reported that the pinna of the ear is formed by the growth of the mesenchymal tissue flanking the first gill furrow of the young embryo. During the second month several nodular enlargements appear, some of them arising from the mandibular arch tissue rostral to the gill furrow, and others from the hyoid arch along the caudal border of the furrow. Wright (1997) mentioned that the external ear development is a lengthy and complex process that extends from the early embryonic life until well into the postnatal period. Initial development of the auricle and external auditory canal during fourth and fifth weeks of gestation is closely associated with anatomical changes involving pharyngeal arch apparatus of human embryo. However, Nishizaki and Anniko (1997) stated that the mouse external auditory canal matures postnatally until 12 DAB, while in human its development is complete at birth.

Concerning the shape of the camel auricle of the external ear, the present findings indicate that it has the form of triangular ear flap at 2.91–3.55 months (8.0–15.0 cm CVRL), the left auricle becomes rhomboid-shaped while the right one is still triangular shape at 3.64 months (16 cm CVRL), both auricles are ovoid-shaped at 4.5 months (25 cm CVRL). The swine auricle was observed as triangular ear flap at 24<sup>nd</sup> day of gestation, ovoid-shaped at 58–70 day-old fetuses and heart-shaped at 71–84 day-old fetuses (Bruzewicz, 2000). Zietzchmann and Krolling (1955) described an embryo of 55 mm length with well developed ear-flap.

The present study shows that there is a relationship between the position of the ear and that of both the mouth and eye. The future ear lies ventral to both the mouth and eye at 2.4 months (2.8 cm CVRL), it situated caudal to the mouth but at a lower level at 2.53 – 2.57 months (3.8 – 4.2 cm CVRL), caudal to the mouth but at the same level at 2.66 – 2.78 months (5.2 – 6.5 cm CVRL) and caudal to the mouth and at a higher level at 2.91–3.55 months (8.0–15.0 cm CVRL). The

morphometrical data indicates that the increasement of the distance between the ear and mouth has a higher rate than between the ear and eye. Noden and Delahunta (1985) indicated that the changes of auricular location are the result of intensive growth of the mandible. Bruzewiez (2000) explained that the rostroventral descensus of swine auricle is connected either with mandibular growth or with the growth of calvarium.

Corresponding to the present morphometrical data the length and width of the camel external ear is strongly correlated with each other at the different prenatal developmental stages. At the early stage (2.4–2.68 months or 2.8–5.5 cm CVRL) the ear length is about half of its width, at 3.32–3.92 months (12.5–19 cm CVRL), the length and width are nearly equal, but at the last stage (10.84–12.02 months or 95–108 cm CVRL) the length is more double the width. It is concluded that, the increase of the ear length growth of the camel fetuses seems to be more intensive than the width growth of the ear. Similar conclusion was obtained during the prenatal growth of the swine auricle by Bruzewiez (2000). The investigation of Shimizu *et al.*, (1992) demonstrated linear relationship between both ear length and width and gestational age in normal fetuses. In this respect, shinohara, *et al.*, (1991) mentioned also that the auricular length, auricular base and auricular width showed linear increase as the CR length increased, suggesting that they are useful parameters to indicate intrauterine growth. They added that the measurements values also suggested that mandibular and hyoid derivatives did not grow independently, but did grow with maintaining a certain relationship.

According to the present investigation the length of the camel external ear at the last stage is about forty folds at the early stage of the prenatal development. In this respect, Birnholz and Farrell (1988) reported that the fetal ear length increased from about 6 mm at 15 weeks to 33 mm at term. He added that short ears were associated strongly and specifically with chromosomal disorders. Birnholz and Farrell (1988) evaluated fetal ear length measurements ultrasonically. The ear measurements of shimizu *et al.*, (1992) were closer to the newborn ear length values of Stivan *et al.*, (1983) than to those of Birnholz and Farrell (1988). The ear measurements may be helpful in the antenatal prediction of the fetuses with chromosomal abnormalities (Shimizu *et al.*, 1992). Most congenital malformations of the auricle in the human occur during the third to twelfth weeks of embryonic life. During this period, the external ear is undergoing development and can be affected in many ways (Karmody and Annino, 1995).

Finally on the basis of the morphometrical analysis, it is possible to draw a general developmental conclusion that all the measurements of the various investigated items (head length, ear length, ear width, distance between the ear and both the mouth and eye) except interear distance increase along the whole prenatal period of the camel. But the rate of the development differs according to the before mentioned examined items. Concerning to the interear distance, it increases firstly, then decreases towards the end of the gestation period. The decrease in the interear distance is attributed to the considerable increase in the fetal ear length.

## REFERENCES

- Alam El-Din, M.A., Abdel-moneim, M.E., Mansour, A.A., Ibrahim, I.A., and Abdalla, K.H. (1992):* New equations to determine the CVR length and age of the one humped camel fetuses. Tenth Scientific Annual Conference, 15 – 17 April, Faculty of Medicine, Assiut University Hospital, Assiut University.
- Alvord, L.S. and Farmer, B.L. (1997):* Anatomy and orientation of the human external ear. *J. Am. Acad. Audiol. Dec.*, 8(6): 383 – 390.
- Birnholz, J.C. and Farrell, E.E. (1988):* Fetal ear length. *Pediatrics*. 81 (4): 555 – 558.
- Bruzewicz, S. (2000):* Prenatal growth of the swine auricle. *Ann. Anat.* 182(3): 293 – 298.
- El-wishy, A.B., Hemeida, N.A., Omer, M.A., Mobarak, A.M. and Sayed, M.A.I. (1981):* Functional changes in the pregnant camel with special reference to foetal growth. *Br. Vet. J.*, 137, 527 – 537.
- Jakobovits, A.; Iffy, L.; Wingate, M.B.; Slate, W.G., Chatterton, R.T. and Kerner, P. (1972):* The rate of early fetal growth in the human subject. *Acta Anat. (Basel)*. 83(1): 50 – 59.
- Karmody, C.S. and Annino, D.J. (1995):* Embryology and anomalies of the external ear. *Facial Plast. Surg.* 11(4): 251 – 256.
- Manal Abdel-latif and Saleh, A.M. (2005):* Hair appearance and distribution in camel fetuses as a method for age determination. Egyptian Society for Cattle Diseases. 11 – 13 desember, Faculty of Veterinary Medicine, Assiut University, p 282 – 292.
- Nishizaki, K. and Anniko, M. (1997):* Developmental morphology of the middle ear. *Auris Nasus Larynx*. 24(1): 31 – 38.

- Noden, D.M. and Delahunta, A. (1985):* The embryology of domestic animals. Williams & Wilkins, Baltimore, London, Los Angeles, Sydney.
- Patten, B.M. and Carison, B.M. (1974):* Foundation of Embryology. McGraw-Hill Book Company, New York, St. Louis, San Francisco, Dusseldorf, Johann, KJuala Lumpur, London, Mexico, Montreal, New delhi, Panama, Paris, San Paulo, Singapore, Sudney, Tokyo, third edition, p. 437.
- Shimizu, T.; Salvador, L.; Allanson, J.; Hughes-Benzie, R. and Nimrod, C. (1992):* Ultrasonographic measurements of fetal ear. *Obstet. Gynecol.* 80(3 Pt 1): 381 – 384.
- shinohara, H.; Morisawa, S.; Nakatani, T. and Ohtani, O. (1991):* Measurements of the auricle in the human fetus. *Okajimas Folia Anat. Jpn.* 68(4): 215 – 218.
- Stivan, Y.; Merlob, P. and Reisner, S.H. (1983):* Assessment of ear length and low set ears in newborn infants. *J. Med. Genet.*, 20: 213 – 215.
- Wright, C.G. (1997):* Development of the human external ear. *J. Am. Acad. Audiol.* 8(6): 379 – 382.
- Zietzchmann, O. and Krolling, O. (1955):* Lehrbuch der Entwicklungs Geschichte der Haustiere, Paul Parey, Berlin, Hamburg.