

Dept. of Theriogenology,
Fac. Vet. Med., Assiut University.

STUDYING THE DEVELOPMENT OF THE CHIOS RAM GENITALIA FROM 6 TO 24 MONTHS AGE USING ULTRASONOGRAPHY

(With 3 Tables and 8 Figures)

By

A.KH. ABDEL-RAZEK; M.M.A. AWAD-ALLAH*
and S. FAHMY*

*Dept. of Animal Prod., Fac. Agric., Al-Azhar University (Assiut branch).
(Received at 5/3/2006)

تطور نمو الجهاز التناسلي لكباش الكيوس من عمر ٦:٢٤ شهر باستخدام
الموجات فوق الصوتية

عبد الرزاق خليفه ، محمد محمد عزب عوض الله ، سالم فهمي

خطت هذه الدراسة لمتابعة التغيرات التي تحدث نتيجة لنمو الجهاز التناسلي لكباش الكيوس باستخدام جهاز الموجات فوق الصوتية وأجهزة قياس الخصية (الشريط والمسمالك). استعمل في هذه الدراسة عدد عشرون كبشا ثم تقسيمها إلى أربعة مجموعات : المجموعة أ (متوسط العمر ٦ أشهر ومتوسط الوزن ٣و١٩±٨ كجم) ومجموعة ب (متوسط العمر ١٢ أشهر والوزن ٢و٢٨±٤ كجم) والمجموعة ج (متوسط العمر ١٨ شهر والوزن ٣و٣٤±٢ كجم) ومجموعة د (متوسط العمر ٢٤ شهر والوزن ٥و٧±٤٢ كجم) تم في كل مجموعة قياس متوسط محيط كيس الصفن (SC) وعرض الخصية (TB) وقطر الغدة البصلية المبالية (BUG) ارتفاع جزء البروستاتة حول المبالية الحوضي (PDP) وكذلك الغدة المنوية (SG) وتم حساب العلاقة بين نموهم . وقد وجد ازدياد ملحوظ في قياسات محيط الصفن في الفترة من ٦-١٨ شهر وكان الازدياد بطيئا في الفترة من ٢٢ الى ٢٤ شهر وبالمثل كانت الزيادة في عرض الخصية. وكان قياس ارتفاع جزء البروستاتة ثابتا طوال ١٢ شهر من العمر ثم لوحظ ازدياده في الفترة من ١٢-١٨ شهر. كما كانت الزيادة في حجم الغدة المنوية ملحوظة في الفترة من ١٢-٢٤ شهر. وقد وجدت علاقة ايجابية ملحوظة بين نمو محيط الصفن وعرض الخصية وكل من الغدة البصلية المبالية وارتفاع البروستاتة وكذلك الغدة المنوية ومن البحث نخلص إلى أن الأعضاء التناسلية لكباش الكيوس تنمو في أنماط مختلفة ما بين ٦-٢٤ شهر وقد ساعدت الدراسة بالموجات فوق الصوتية في دراسة نمو الأجزاء التناسلية الموجودة في الحوض وذلك في الحيوانات الحية دون الحاجة إلى ذبحها كمان كان يحدث من قبل.

SUMMARY

Testes and accessory glands measurements are taken as a potential for male selection. This study was designed to follow up the developmental changes of Chios rams genitalia using ultrasonography, tape and caliper. Twenty rams were allocated into equal four age groups: A (6 months, BW: 19.3±2.8 kg), B (12 months, BW: 28.2±4.8 kg), C (18 months, BW: 34±2.8), and D (24 months, BW: 42.7±7.5 kg). In each group, the mean values of scrotal circumference (SC), testicular breadth (TB), and diameters of bulbourethral gland (BUG), pars disseminate of prostate (PDP), and seminal glands (SG) were measured and correlated. SC increased rapidly between 6 and 18 months and non-significantly between 18 and 24 months. Similarly, TB increased rashly between 6 and 18 months and slowly between 18 and 24 months. BUG increased slowly between 6 and 18 months and non-significantly between 18 and 24 months. PDP remained constant until 12 months, then increased significantly between 12 and 18 months, to remain constant again between 18 and 24 months. SG increased non-significantly between 6 and 12 months, then increased rapidly between 12 and 24 months. Positive correlations were found between SC, TB and each of BUG, PDP and SG. It could be concluded that male genitalia of Chios rams developed in different patterns between 6 and 24 months age. Ultrasonography assists studying the accessory glands directly in the living animals, which was unattainable before.

Key words: Chios ram, genitalia, development, ultrasonography

INTRODUCTION

Fertility evaluation of rams, which includes an examination of the genitalia and an assessment of libido, should be carried out in flocks before the beginning of the breeding season. It may also take place during selection of ram-lamb replacement, before the private purchase of a ram, or when investigating reproductive problems in a flock (Edgar 1963, Boundy 1992 and Bruere and West 1993, Gouletsou *et al.*, 2003). In evaluating rams for use in natural mating, three parameters have been shown to be the most reliable and repeatable. A complete breeding sound examination is normally conducted by veterinarian and includes: physical examination, measurements of scrotal size and semen evaluations.

Methods for assessment of the health of ram external genitalia were previously limited to palpation, measurements of the scrotal circumference and testicular dimensions as well as evaluation of semen. Other methods like thermography, tonometry and biopsy have also been employed as diagnostic aids but have not gained widespread acceptance in veterinary medicine (Pechman and Eilts 1987). At the same time, studying the development of the reproductive tract has been carried out previously by removing the tract after slaughter or indirectly by analyzing semen composition for presence and secretion of accessory glands. Recently, the same basic principles and technique of transrectal ultrasonography used for female can also be applied to the ram for examination of the pelvic genitalia of the ram. Ultrasound has an increased the number of diagnostic tools applied in veterinary practice, with both large and small animals. Being non invasive, it has considerable advantages over other methods. It allows the clinician to obtain instant information about a wide range of body systems and in some cases the dynamic function of organs can be assessed. In addition, ultrasonography has led to new insights into basic anatomy and physiology processes (Goddard, 1995).

The present study was designed to study the developmental changes of Chios rams genitalia from the age of 3 months to 2 years old using ultrasonography, tape and caliper.

MATERIALS and METHODS

Clinical Examination:

Twenty Chios rams maintained under general husbandry conditions were included in the present study. General health examination was formerly performed for these rams. Clinical examination of genitalia was carried out and followed as previously described by (Fthenakis *et al* 2001), with the ram in the standing position and restrained by two assistants, one of them lifted its tail. The scrotum was observed for the presence of lesions and asymmetry of the two halves. Exerting pressure on through squeezing it gently between fingers tested consistency of testicles and pain reaction. Free movement of the testes into the scrotum and lack of other masses therein were confirmed. The spermatic cord was palpated as far as possible and similarly the epididymal head and tail.

The rams were allocated in four age and weight groups (n=5 each): A (6 months, BW: 19.3±2.8 kg), B (12 months, BW: 28.2±4.8 kg), C (18 months, BW: 34±2.8), and D (24 months, BW: 42.7±7.5 kg).

The scrotal length (SL) as estimated from the origin at the inguinal region until free border of scrotum and scrotal circumference (SC: at the most largest point) were recorded using measuring tape. The three dimensions, length, width and depth of testes were measured using the caliper after deduction of scrotal layer thickness. Also the largest dimension of epididymal tail was recorded using the caliper.

Ultrasonographic Examination:

Ultrasonographic imaging of the testis and the epididymes was carried out using a 6/8 MHz linear array transducer connected to B-mode ultrasound scanner (Pie Medical, 100 LC, Holland). Before examination, the testes were pulled down into the scrotum and retained by grasping the spermatic cord at the neck of the scrotum with one hand of the examiner while the other hand was used to remove the transducer across the organ. This was done over the caudal surface while the animal was restrained in standing position. The probe was placed, after applying water-soluble jell, on the caudal surface of the scrotum along its longitudinal axis and was moved from left to right to monitor the scrotal tunics, the testicular parenchyma and mediastinum. The probe was also applied transversely to show a transverse image of the testes. The tail of the epididymis was visualized from a diagonal plane near the distal end of testis. The thickness of tunics, testicular width(TW), thickness of mediastinum and the largest dimension of epididymal tail were estimated from frozen images by the scanner.

The pelvic genitalia were scanned after removing the feces from the rectum and applying ultrasound transmission jell. The accessory glands and pelvic urethra were examined using 6 MHz linear probe. The maximum breadth of seminal gland (SG), the height of pars desseminata of prostate (PDP) and the diameter of the bulbourethral gland (BUG) were recorded from frozen images.

All data were entered into an excel spreadsheets. Means and standard deviation were presented for the recorded values. The correlations between age and the recorded results were calculated.

RESULTS

Table (1) presents the developmental changes in SC, SL and testicular dimensions for Chios rams from 6 to 24 months age. The SC

increased rapidly between 6 and 18 months and non-significantly between 18 and 24 months and length increased significantly from 6-12 month. Similarly, TB increased rashly between 6 and 18 months and slowly between 18 and 24 months

The ultrasonographic longitudinal images of ram lamb testis from group A appeared as a hypoechoic structure with the absence of the characteristic hyper echogenic mediastinum from the middle of image (Fig 1). In mature ram the same image (Fig 2) showed a centrally located mediastinum testis represented by a hyperechogenic line surrounded by homogenous echogenic structure. The tunica albugenia and scrotum layers were evident as clear hyperechogenic lines at the border of testis image, which separated by a thin non-echogenic layer of fluid seemingly between two layers of tunica vaginalis. The mediastinum testis appeared as round spot in transverse ultrasonographic plane (Fig 3). The tail of the epididymis was clearly visible, where it appeared less echoic than testicular parenchyma and with a heterogenic structure (Fig 4). The pampiniform plexus could be seen as a dome shaped structure on the upper pole of the testis, which appeared as numerous convoluted sonlucent tubular structures (Fig 5). Developmental changes of tunics, breadth and mediastinum of testes were estimated from ultrasonographic images and reported in Table (2). The data showed that the testis breadth increased significantly until 12 months while the tunica albugenia decreased steadily with the advancement of age. The mediastinum showed non-significant slight increase in its growth pattern. The epididymal tail showed significant growth from age 6 to 12 month and from 18 to 24 month.

The circumscribed homogenous hyperechogenic appearance of BUG is demonstrated in Fig 6. Table (3) reported that, BUG increased non-significantly between 6 and 18 months and significantly from 18 to 24 months. PDP, which appear as homogenous hyperechogenic area and pelvic urethra demonstrated in fig 7. It was found, that PDP remained constant until 12 months, then increased significantly between 12 and 18 months, to keep constant once more between 18 and 24 months (Table 3). The ultrasonographic image of SG in fig 8 appear as moderately echogenic areas separated by hyperechogenic CT. The gland increased non-significantly between 6 and 12 months, then increased significantly between 12 and 24 months (Table 3). Positive correlations were found between SC and TB and each of BUG, PDP and SG.

Table 1: Developmental changes of scrotum and testes of Chios rams as measured by caliper and tape in relation to age and body weight (M±SD).

Age (M)	Body Weight(Kg)	SC(cm)	SL(cm)	TL(cm)	TD(cm)	TB(cm)
6	19.33±2.89 ^a	12.33±2.31 ^a	6.33±0.58 ^a	2.75±1.06 ^a	1.50±0.00 ^a	1.45±0.49 ^a
12	28.20±4.87 ^b	20.40±1.14 ^b	14.20±1.10 ^b	5.00±0.93 ^b	2.50±0.35 ^b	2.90±0.35 ^b
18	34.00±2.83 ^c	24.00±3.39 ^{bc}	15.00±1.73 ^b	7.80±0.84 ^c	4.20±1.15 ^c	5.60±0.93 ^c
24	42.67±7.50 ^d	26.00±2.65 ^c	15.67±2.89 ^b	9.50±0.87 ^d	4.27±0.25 ^c	5.90±0.50 ^c

Means in the same column with similar letter do not differ significantly at $p>0.05$
 SC: scrotal circumference, SL: scrotal length, TL: testis length, TD: testis depth,
 TB: testis breadth

Table 2: Developmental changes of testes and epididymal tail of Chios rams as measured from ultrasonographic images (M±SD).

Age(M)	Tb(cm)	Ta.(cm)	Med. (cm)	Epi. tail(cm)
6	1.47±0.20 ^a	0.23±0.04 ^a	0.20±0.02	1.10±0.14 ^a
12	3.01±0.33 ^b	0.21±0.08 ^a	0.20±0.19	1.64±0.11 ^b
18	3.68±0.41 ^b	0.18±0.09 ^{ab}	0.21±0.04	1.77±0.67 ^{bc}
24	3.67±0.42 ^b	0.15±0.04 ^b	0.23±0.07	2.05±0.13 ^c

Means in the same column with similar letter do not differ significantly at $p>0.05$
 Tb: testis breadth, Ta: Tunica albugenia, Med.: Mediastinum,
 Epi. Tail: Epididymal tail

Table 3: Developmental changes in pelvic genitalia of Chios rams as measured from ultrasonographic images (M±SD).

Age (M)	BUG(cm)	PDP (cm)	SG(cm)
6	0.91±0.56 ^a	0.60±0.04 ^a	0.75±0.50 ^a
12	0.90±0.13 ^a	0.55±0.05 ^a	0.91±0.13 ^a
18	1.08±0.27 ^a	0.85±0.19 ^b	1.20±0.23 ^b
24	1.47±0.25 ^b	0.79±0.03 ^b	1.71±0.19 ^c

Means in the same column with similar letter do not differ significantly at $p>0.05$
 BUG: Bulbourethral Gland, PDP: Pars Disseminata,
 SG: Seminal Gland

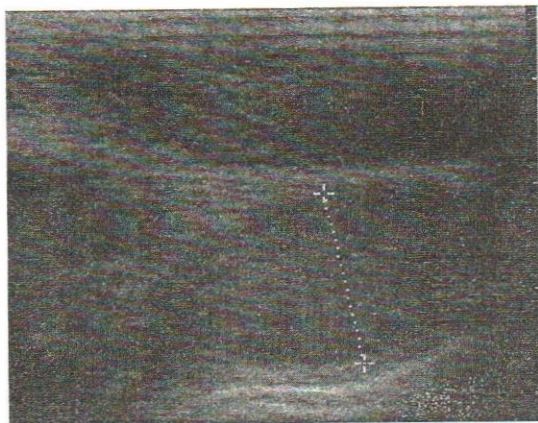


Fig. 1: longitudinal image of lamb ram (prepuberty)

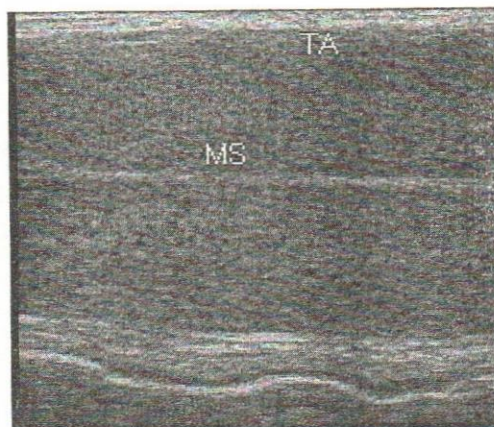


Fig. 2: Longitudinal image of testis (post pubertal): Mediastinum (MED) Tunica Alb (TA)

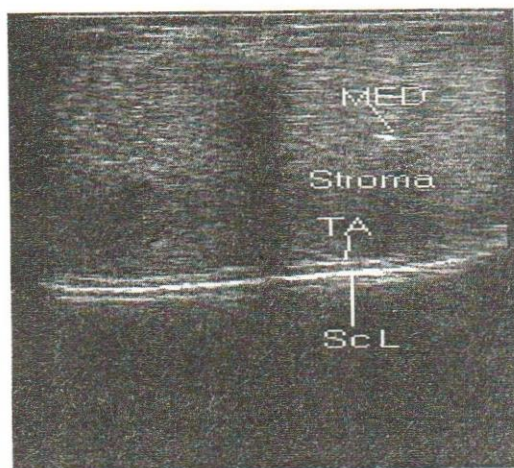


Fig. 3: Transverse image of testes (post pubertal): mediastinum (MED), tunica albugenia (TA), scrotal layer (Sc L)

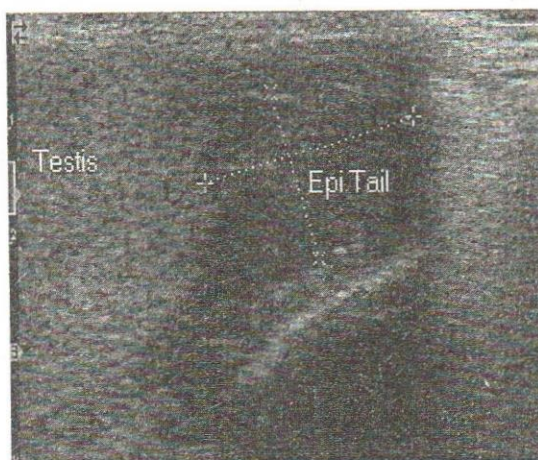


Fig. 4: Lower pole of Testis and Epididymal Tail (post pubertal)

for its detection and examination with the linear probe. No detailed studies were available for the ultrasonographic appearance of the pelvic urethra and accessory genitalia of rams although few studies were conducted on examination of testes and epididymes (Ahmed *et al.*, 1991 and Gouletsou *et al.*, 2003).

High correlations existed between the rates of growth of the testes and those of the epididymal tail, seminal glands and bulbourethral glands. Significant growth rate of the accessory glands were pronounced from 12 months of age. This was parallel to the peak level of testosterone as recorded by Drymundeson (1973).

Finally, it could be concluded that male genitalia of Chios rams developed in different patterns between 6 and 24 months age. Ultrasonography assists studying the accessory glands directly in the living animals, which was unattainable before without animal slaughtering.

REFERENCES

- Ahmed, N.; Noakes, D.E. and Subandrio, A.L. (1991): B- mode real time ultrasonographic imaging of the testis and epididymes of sheep and goats. *Vet. Rec.*, 128: 491-496.
- Boundy, T. (1992): Routine ram examination. *In-Practice*, 14: 219-228
- Bruere, A.N. and West, D.W.(1993): The sheep: health, disease & production. Palmerston North: Foundation for Veterinary Continuing Education of the New Zealand Veterinary Association.
- Colas, G. ; Guerin, Y; Lemaire, Y.; Montassier, Y. and Despierres, J. (1986): Seasonal variation in the testis diameter and sperm morphology in the Vendean ram and Texel ram. *Reprod Nutr Dev.*, 26: 863-75.
- Coulter, G.H. and Keller, D.G. (1982): Scrotal circumference of young beef bulls: Relationship to paired testes weight, effect of breed, and predictability. *Can J. An. Sci.*, 62: 133-139.
- Drymundeson, O.R.(1973): Puberty and early reproductive performance in sheep. II. Ram lambs. *Anim. Breed. Abstr.*, 41: 419.
- Edgar, D.G. (1963): The place of ram testing in the sheep industry. *NZ Vet. J.*, 11:113-115.
- Foster, R.A.; Ladds, P.W.; Hoffmann, D. and Briggs, G.D. (1989): The relationship of scrotal circumference to testicular weight in rams. *Aust. Vet. J.*, 66: 20-22.

- Fthenakis, G.C.; Karagiannidis, A.; Alexopoulos, C.; Brozos, C.; Saratsis, P. and Kyriakis, S. (2001):* Clinical and epidemiological finding during ram examination in 47 flocks in southern Greece. *Prev. Vet. Med.*, 52: 43-52.
- Gipson, T.A.; Vogt, D.W.; Massey, J.W. and Ellerseck, M.R. (1985):* Association of scrotal circumference with semen traits on young beef bulls of different breeds. *Theriogenology*, 24:217-225.
- Goddard, P.J. (1995):* General Principles. In: Goddard, P.J. (ed) *Veterinary ultrasonography*, CABI, Uk.
- Gouletsou, P.G.; Amiridis, G.S.; Cripps, P.J.; Lains, T.; Deligiannis, K.; Saratsis, P. and Fthenakis, G.C. (2003):* Ultrasonographic appearance of clinically healthy testicles and epididymides of rams. *Theriogenology*, 59: 1959-1972.
- Lapwood, K.R. (1980):* Development of male reproductive tract, Spermatogenesis and Puberty. In: Morrow PA (ed), *Current Therapy in Theriogenology*, WB Saunders Company, Philadelphia, 927-930.
- Makerchian, M.; Farid, A. and Berg, T. (1985):* Scrotal circumference, semen characteristics, growth parameters, and their relationships in young beef bulls. *Can J. An. Sci.*, 65:789-798.
- Ott, R.S. (1987):* Current thinking on breeding soundness examinations of bulls. *Proc. Soc. Theriogenology*, 14-31.
- Ott, R.S. and Menon, M.A. (1980):* Breeding soundness examination of rams and bucks, a review. *Theriogenology*, 13:155-164.
- Palasz, A.T.; Cates, W.F.; Barth, A.D. and Mapletoft, R.J. (1994):* The relationship between scrotal circumference and quantitative testicular traits in yearling beef bulls. *Theriogenology*, 42:715-726.
- Pechman, R.D. and Eilts, B.E. (1987):* B- mode ultrasonography of the bull testicle. *Theriogenology*, 27: 431-441.
- Salhab, S.A.; Zarkawi, M.; Wardeh, M.F.; Al-Masri, M.R. and Kassem, R. (2001):* Development of testicular dimensions and size, and their relationship to age, body weight and parental size in growing Awassi ram lambs. *Small Rumin. Res.*, 40: 187-191.
- Smith, B.A.; Brinks, J.S. and Richardson, G.V. (1989):* Estimation of genetic parameters among breeding soundness examination components and growth traits in yearling bulls. *J. Anim. Sci.*, 67: 2892-2896.
- Wildeus, S. and Entwistle, K.W. (1982):* Postpubertal changes in gonadal and extragonadal sperm reserves in *Bos indicus* strain bulls. *Theriogenology*, 17: 655-667.