

Dept. of Surgery, Anesthesiology and Radiology,
Fac. Vet. Med., Cairo Univ., Beni-Suef Branch.

DORSAL VERSUS VENTRAL URETHROTOMY TECHNIQUE FOR TREATMENT OF OBSTRUCTIVE URETHROLITHIASIS IN CATTLE CALVES.

(With One Table and 9 Figures)

By

M. ABDEL-FATTAH and A.M. SEDEEK

(Received at 26/6/2005)

الشق العلوى للأحليل مقارنة بالشق السفلى كطريقة لعلاج انسداد الأحليل
بالحصوات فى عجول الأبقار

محمد عبد الفتاح ، أيمن صديق

اجريت هذه الدراسة على عدد ٦٦ حيوان من عجول الأبقار تتراوح اعمارها من ٤-٢٤ شهر جميعها مصابة بانفجار المثانة البولية نتيجة انسداد الأحليل بالحصوات وذلك للمقارنة بين الشق العلوى والسفلى للأحليل. تم إجراء التدخل الجراحى على عدد ٦٣ حيوان بمحافظة المنيا وبنى سويف فى الفترة من ديسمبر ٢٠٠٤ وحتى مايو ٢٠٠٥. تم تقسيم الحيوانات الى مجموعتين واحتوت المجموعة الاولى على ٣٠ حيوان وكان التدخل الجراحى فيها بالطريقة التقليدية وذلك عن طريق فتح الأحليل من الناحية السفلية اما المجموعة الثانية فقد اشتملت على ٣٣ حيوان تم علاجها جراحيا بفتح الأحليل من الناحية العلوية. تم تجميع عينات من ثلاث حيوانات مذبوحة اضطراريا بالمجزر وذلك لعمل الفحص الهستوباثولوجى لمكان انسداد الأحليل بالحصوات. هذا وقد اسفرت الدراسة عن ارتفاع نسبة المضاعفات فى المجموعة الاولى والمتمثلة فى انفجار الأحليل البولى بينما لم تحدث اى مضاعفات فى المجموعة الثانية مما يؤكد فعاليتها لفترة طويلة. وبناء على المعلومات المتوفرة يمكن اعتبار هذا التدخل الجراحى جديد من نوعه.

SUMMARY

The present study was conducted on a total number of (66) cattle calves, 4-24 months old, suffered from obstructive urethrolithiasis and ruptured urinary bladder. 63 cases were operated in veterinary practices in Elminya and Beni-suef Governorates during the period from December 2004 to May 2005. Two techniques of urethrotomy had been evaluated in this study including conventional urethrotomy (ventral urethral approach) in 30 cases and a new technique of urethrotomy (dorsal

urethral approach) in 33 cases. Histopathologic investigation was performed on three formalized samples collected from abattoirs for examination of the seat of urethral obstruction. It was concluded that the ventral urethrotomy technique associated with high probability of urethral rupture or leakage of urine after removal of the Rayl's tube while the dorsal urethrotomy technique proved its effectiveness for long-term success urethrotomy with no complications. To our knowledge, the dorsal urethrotomy technique hasn't been reported before.

Key words: *Urethra, urethrotomy, urethrolithiasis*

INTRODUCTION

Urethrolith in ruminants is one of the most important problems facing veterinary surgeons in our location and all over the world. Obstruction induced by urethroliths causes urine retention and leads to bladder distention, abdominal pain, and eventual urethral perforation or bladder rupture, with death from uremia or septicemia (Ragab and Saif, 1997 and Susan, 2003).

Treatment of obstructive urolithiasis generally involves establishing a patent urethra and correcting fluid and electrolyte imbalances (Nancy, 1995). Different surgical techniques were used for solving of this problem. These techniques included; perineal urethrostomy when the bladder still intact (Turner, *et al.*, 1982; Nancy, 1995; Ragab and Saif, 1997, Smeak, 2000 and Susan, 2003); simple urethrotomy when the bladder is intact and the calculi can be palpated and removed (Turner, *et al.*, 1982 and Susan, 2003); urethrotomy in adjunction with trans-urethral tube cystotomy when the bladder is ruptured (Ragab and Saif, 1997); or tube cystotomy (Ragab and Saif, 1997; Streeter, *et al.*, 2002; Harari, 2003; Pearce, *et al.*, 2003 and Fortier, *et al.*, 2004). Many complications were recorded with different incidence for each technique (Skelcher and Steele 1978).

All the previously mentioned techniques for urethrotomy were applied to the posterior or ventral aspect of the urethra, as the calculus was lodged superficially in this place. However, Halland, *et al.*, (2002) observed severe urethral necrosis or stricture formation at the time of urethroscopy in 25% of the examined animals. The same phenomena was observed by McIlwraith, *et al.*, (1998) in the esophagus of animals with choking and by Turner, *et al.*, (1982) in the urethra of bulls with

urethroliths, accordingly the authors advised not to induce incision directly over the obstructing object, to avoid suturing at the necrotic site.

The aim of the study was to evaluate two techniques of urethrotomy (dorsal approach versus ventral approach) and to investigate the histopathologic changes at the seat of obstruction.

MATERIALS and METHODS

This study was conducted on a total number of (66) cattle calves of native breeds, of age varied from 4-24 months, weights from 70 to 300 kg, suffering from obstructive urethrolithiasis and ruptured urinary bladder, in Elminia and Beni-Suef provinces, in the period from December 2004 to May 2005.

Animals were classified into three main groups. The first group consisted of (30) animals, was used for evaluation of the ventral urethrotomy. The second group consisted of (33) animals, was used for performing dorsal urethrotomy, and third group of three animals was used for histopathologic study of the obstructed urethra. These three animals were not operated and were subjected to emergency slaughter in abattoirs and the seat of obstruction was excised.

The surgical interferences were performed under the effect of I.M. Xylaject® (xylazine HCl 2%, Egypt Co. for chemicals and pharmaceuticals, ADWIA) in a dose rate 0.22 mg/kg b.wt. and posterior epidural analgesia in adjunction with pre-pubic linear infiltration analgesia (Hall and Clarke, 1983). The animals to be operated were secured in lateral recumbency on the right side, and then the animals were routinely prepared for aseptic surgery.

The technique, used for group (I), was made with modification after Ragab and Saif (1997), the technique included exteriorization of the penis either by preputial splitting or via post-scrotal incision according to the seat of the stone. The seat of the stone was detected by penile palpation, and then urethrotomy was made over the calculus at the posterior or ventral aspect of the urethra. The calculus was picked up and the urethra was sutured by Vicryl 2/0-4/0 (according to the size of the urethra) in simple continuous manner, then the penis was lubricated with oily broad spectrum antibiotic preparation, returned to its normal position, and the preputial or the post scrotal incisions were closed.

Pre-pubic laparotomy was performed, the abdomen was evacuated from urine, and the ruptured urinary bladder was located, evacuated from sand, other adhered stones, necrotic tissues, or clotted

blood, and irrigated with normal saline. Then a Rayl's tube (Poly Medicure Limited, 105, sector 59, HSIDC Ind. Area, Faridabad, India), number 8-12 according to the weight of the operated calf, supported with flexible stainless steel wire, was passed through the wound of the bladder into the urethra and fixed to the hair of the prepuce after emerging from the external urethral orifice. The stainless steel wire was removed from the tube, the stump of the Rayl's was excised, and the tube was fenestrated and coiled into the bladder after bi-directional flushing with normal saline.

The bladder was sutured by chromic catgut number 0 in simple continuous manner according to Ludovic, *et al.*, (2005), and the abdominal wall was sutured in layers. Rayl's tube was removed after 3-5 days, and nursing of the animal included massive dose of antibiotic, fluid therapy, oral administration of sodium chloride 5 gm/animal daily for a week, diuretics, and easily accessible water at all times (Blood, *et al.*, 1995)

The same technique was used for group (II), but urethrotomy was applied at the dorsal surface of the penis (Figures 1: 4). Tourniquets were applied anterior and posterior to the seat of obstruction to initiate engorgement of the vessels, and then an incision was made among the dorsal veins and the two dorsal nerves of the penis. The incision was continued deeply into the body of the penis till reaching the stone then the stone was picked up and the wall of the penis and the dorsal urethral wound were closed in the same fore mentioned manner, the tourniquets were removed, and the operation as well as the nursing were continued as group (I).

All animals of both groups were monitored till the time of publication of the research and complications were recorded. All animals suffered from rupture urethra were subjected to perineal urethrostomy according to Smeak (2000), scarification of the swelling, dressing with antiseptic, and administered massive dose of antibiotic.

Tissue specimens from sigmoid flexure of the penile urethra of 3 calves suffering form urethrolithiasis were collected. The samples were conventionally processed, sectioned and stained with Haematoxylin and Eosin according to Bancroft and Stevens (1996).

RESULTS and DISCUSSION

Concerning cases of group (I) which operated by conventional urethrotomy (ventral approach), results revealed that the number of the animals suffered from colic 4-10 days after removal of the catheter were

(13) animals, and those suffered from ruptured urethra were (8) animals (Table 1 & Figure 5).

High incidence of colic in group (I) might be related to stenosis of urethra at the seat of urethrotomy that might be predispose to recurrence of urine retention with small stones and this coincide with Gasthuys, *et al.* (1993).

All the animals that had rupture of the urethra were subjected to perineal urethrostomy (PU). A trial of forward passing a Rayl's tube from the seat of urethrostomy failed as a result of urethral impaction with sand and/or necrotic tissue as well as enlargement of para-urethral tissue. After urethrotomy, all the animals retained normal and urinated from the created fistula and this is in agreement with Walker and Vaughan (1980).

The incidence of postoperative subcutaneous urine infiltration within the scroto-preputal region was high in group I (8 out of the 30 animals), and it might be related to; leakage either as a result of poor security of urethral suturing as the two lips of the urethral wound were too small especially if the weight of the animal under 100 kg, and this didn't permit proper suturing of the urethra (Halland, *et al.*, 2002), or improper healing of the sutured urethra with subsequent leakage, as the sutured site was subjected to pressure necrosis by the lodged stone; or stenosis of the urethra after suturing with subsequent accumulation of sabulous or necrotic tissue sloughed from the mucosa of the bladder leading to rupture of the urethra (Turner, *et al.*, 1982; Ahmad, *et al.*, 1991; McIlwraith, *et al.*, 1998 and Halland, *et al.*, 2002)

Perineal urothrosotmy have been associated with stricture formation and subsequent recurrence of urethral obstruction leading to short-term success. The animal penalized in a lower value for slaughter as a result of the urethral fistula and urine scald which is considered as one of the most important complications of urethrostomy (May, *et al.*, 1988; Nancy, 1995; Fortier, *et al.*, 2004 and Van Meter, 2005).

Regarding the cases of group (II), which was operated by the new technique (dorsal approach), results revealed that 12 animals showed colic 5-14 days after removal of the trans-urethral tube but there was no rupture of the urethra in any of them (Table 1 & Figure 5).

All cases of colic were solved spontaneously without surgical interferences, one case pushed a stone that was kept by the owner and another case ejected a mass of necrotic tissue suspected to be a fibrin clot or sloughed mucosa of the bladder, then both animals urinated normally. The other 10 animals urinated about 1-2 hours prior to our

arrival to their locations and on examination, no signs of obstruction were detected and we suspected that sabulous or small stones were the cause of the painful urinary effort and colic. All the 12 cases are healthy and none of them suffered from colic episode again and all of the 33 animals of this group are healthy till the time of publication of this research.

The new technique of urethrotomy permitted proper suturing with preservation of the maximal urethral diameter, as the two lips of the wound are thick and the stitch didn't involve the wall of the urethra. The technique provided good apposition of the two edges to enhance healing, and suturing was applied to the wall of the penis, so incision and suturing of the suspected site of necrosis of the urethra was avoided.

The new technique (dorsal urethrotomy) needed skills, as the seat of incision is highly vascularized and the possibility of bleeding is high and the stone is located deeply. Injury of blood vessels could be prevented by application of tourniquet in front of the seat of obstruction that caused engorgement of vessels to avoid its injury.

Gross examination of the three samples revealed urethroliths at the sigmoid flexure nearly occupied the whole lumen and was tightly adhered to the wall in two cases. These two cases showed dilatation of the urethra proximal to the stone. However, microscopically the surface epithelium of the urethra, contained recently formed calculi, was transformed into psuedostratified epithelium. The epithelial cells appeared enlarged with severe hydropic degeneration (Figure 6) especially in the upper layers. Sloughing of the surface epithelium was detected (Figure 7) in the urethra containing elderly formed stone and the submucosa of the same case appeared compressed. Edema was found in the submucosa with dilatation of numerous vascular channels, some of which appeared congested (Figure 8). Hemorrhage was also seen in some areas (Figure 9). Few mononeuclear cell infiltrations could be seen in urethral stroma.

The pressure of the stone on the urethral tissue might predispose to ischemia or reduction of oxygenation, attenuation of oxidative phosphorylation, and reduction of (ATP). This finally causes anaerobic glycolysis, intracellular acidosis, and accumulation of hypoxanthine in endothelial cells and mucosa. Finally cellular edema ensues with release of lysosomal degradative enzymes that will cause cellular death. Reperfusion-induced injury is a contributing cause of cellular death, as reperfusion and re-oxygenation can result in a cascade of biochemical events that can aggravate the state of ischemia-induced injury. This stage

is characterized by increased microvascular permeability and mucosal necrosis and is caused in part by oxygen free radicals (OFRs) as O_2^- and OH^- that initiate structural and functional damage to the cell membrane by lipoperoxidation (Maxine, 1985; Burtis and Ashwood, 1996; William and Bud, 1997 and Moore, 1999).

We advise the use of the new technique of urethrotomy (dorsal urethrotomy) because it doesn't cause stenosis of the urethra, easier in suturing, associated with no probability of leakage, and the necrotic wall of the urethra doesn't involved in the suturing pattern.

LEGENDS

- Figure 1:** The penis directly after being exteriorized and application of tourniquet dorsal to the seat of obstruction. a- tourniquet, b- the engorged dorsal veins of the penis
- Figure 2:** Dorsal incision of tunica albugenia. a- engorged dorsal vein, b- dorsal nerve, and c- the dorsal surface of the penis to be incised.
- Figure 3:** The new technique of dorsal incision of the urethra. a- the wall of the incised penis, b- the stone, and c- the urethral mucosa.
- Figure 4:** Suturing of the dorsal incision of the penis.
- Figure 5:** Number of animals used and results
- Figure 6:** Urethra of calf suffering from urethrolith showing severe hydropic degeneration (H&E- X400)
- Figure 7:** Urethra of calf suffering from urethrolith showing sloughing of the surface epithelium (H&E- X40)
- Figure 8:** Urethra of calf suffering from urethrolith showing edema and congestion (H&E- X100)
- Figure 9:** Urethra of calf suffering from urethrolith showing hemorrhage (H&E- X100)

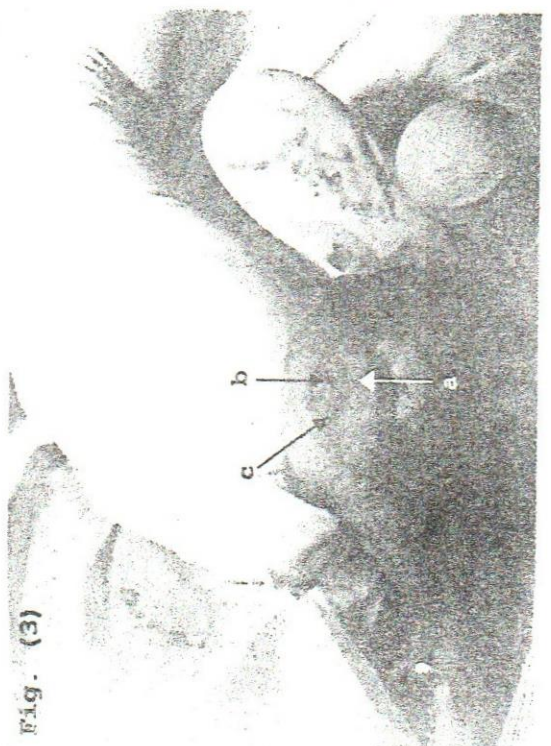
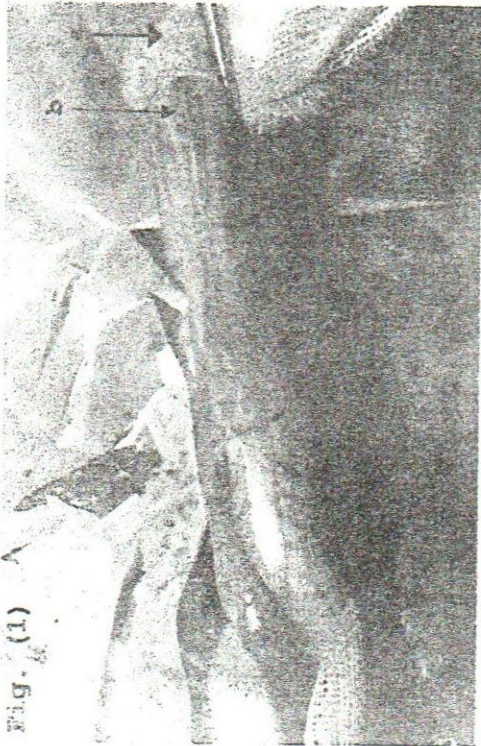
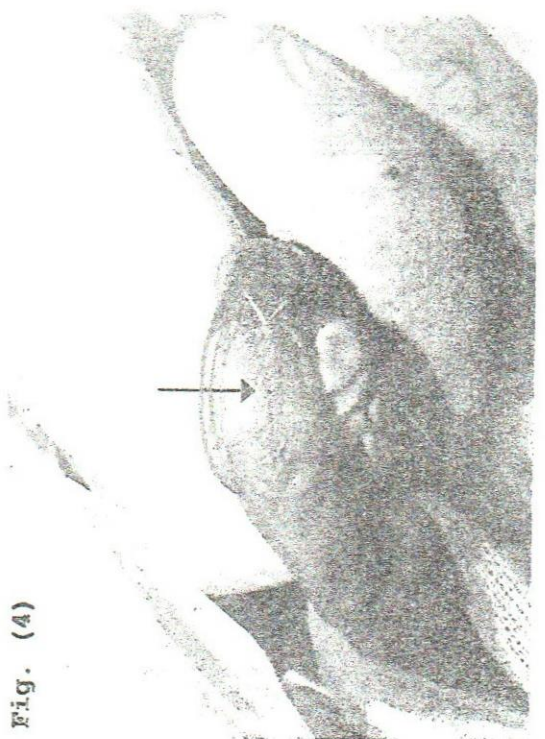
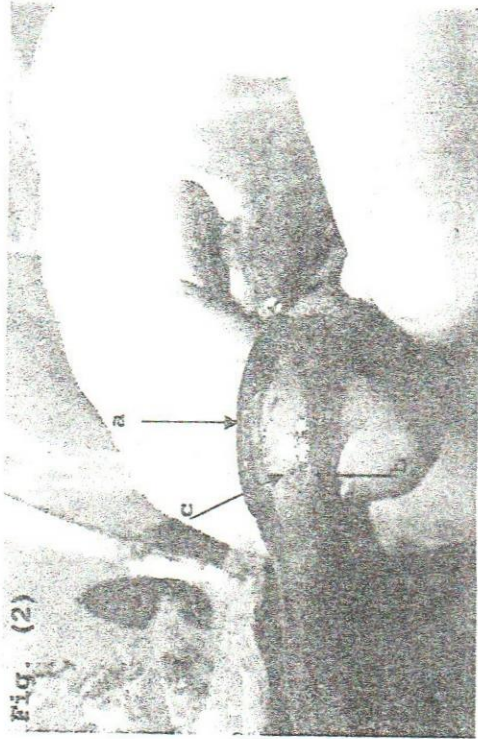


Table (1): Animals used for the experiment

	Number	Animals showed colic after surgery	Animals subjected to urethrostomy after urethral rupture
Animals used for the traditional technique of urethrotomy	30	13 (43.3 %)	8 (61.53 %)
Animals used for the new technique of urethrotomy	33	12 (36.36 %)	0
Animals used for histopathologic investigation	3	-	-
Total	66		

Figure (5): Number of animals used and results

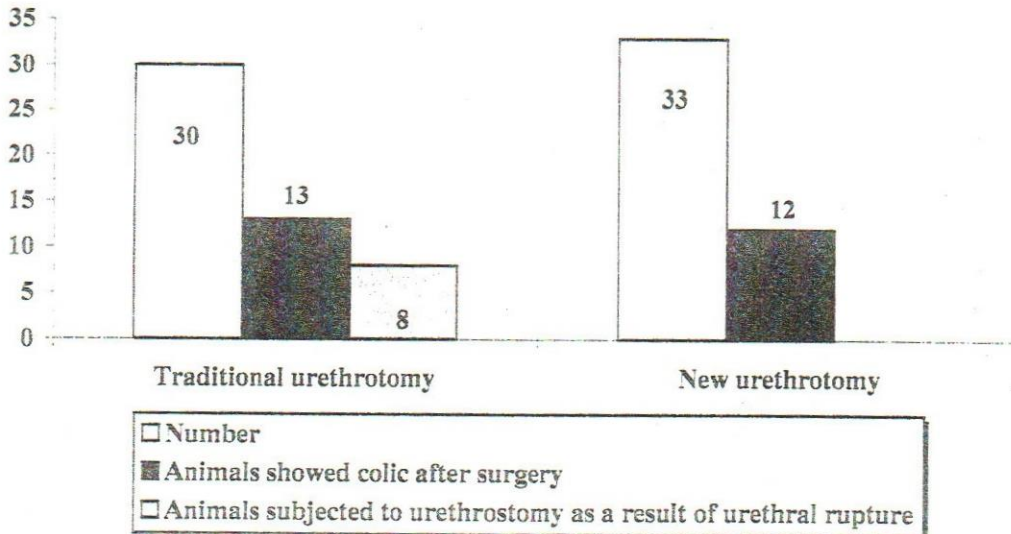

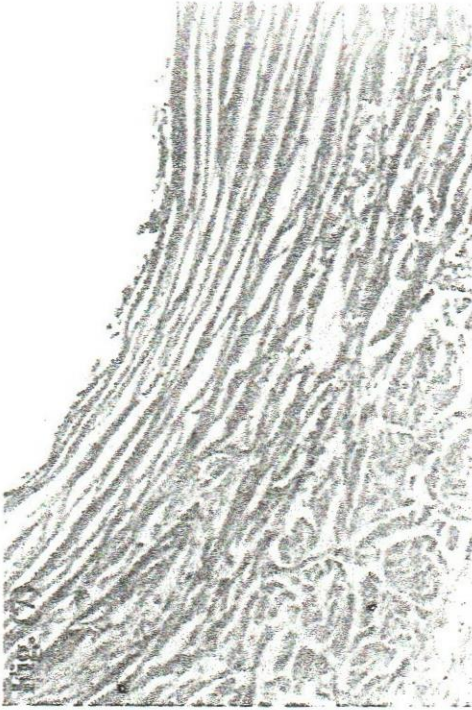


Fig. (7)




Fig. (8)

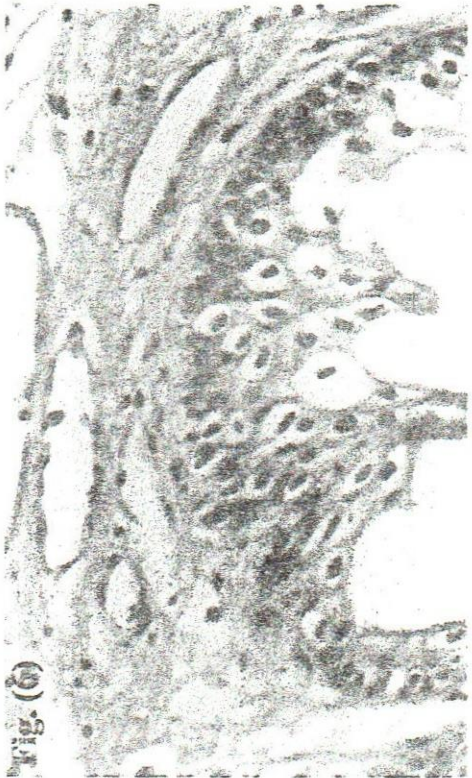

Fig. (6)

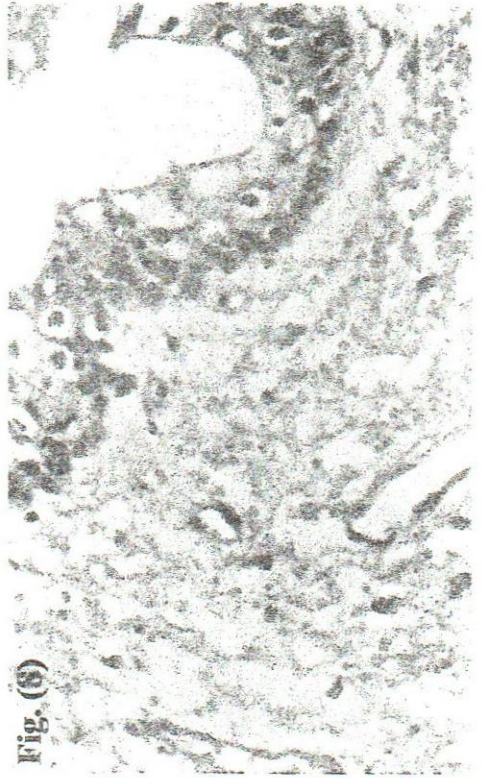

Fig. (5)

REFERENCES

- Ahmad, A.S. and Ragab, G.A. (1991):* Studies on rupture of the urethra in bovine. 1st Scientific congress; Egyptian society for cattle disease, 1-3 Dec. Assiut, Egypt.
- Bancroft, J.D. and Stevens, A. (1996):* Theory and practice of histological techniques. Churchill liveingstone, New York.
- Blood, D.C.; Radostitis, O.M. and Gay, C.C. (1995):* Veterinary Medicine. Pp 157-240, 8th edition, Bailliere Tindal.
- Burtis, A.C. and Ashwood, R.E. (1996):* Tietz fundamentals of clinical chemistry. 4th ed., W. B. Saunders Co.
- Fortier, L.A.; Gregg, A.J.; Erb, H.N. and Fubini, S.L. (2004):* Caprine obstructive urolithiasis: requirement for 2nd surgical intervention and mortality after percutaneous tube cystostomy, surgical tube cystostomy, or urinary bladder marsupialization. *Vet Surg.* Nov-Dec; 33 (6): 661-7.
- Gasthuys, F.; Steenhaunt, M.; DeMoor, A. and Sercu, K. (1993):* Surgical treatment of urethral obstruction due to urolithiasis in male cattle: a review of 85 cases. *Vet. Rec.*, Nov. 20; 133 (21): 522-526.
- Hall, L.W. and Clarke, K.W. (1983):* Veterinary anesthesia. 8th ed., ELBS and Bailliere Tindall.
- Halland, S.K.; House, J.K. and George, L.W. (2002):* Urethroscopy and laser lithotripsy for the diagnosis and treatment of obstructive urolithiasis in goats and pot-bellied pigs. *JAVMA.* Jun 15; 220 (12): 1831-4.
- Harari, O. (2003):* Tube cystotomy for treatment of urethral calculi and obstruction in pet pigs. *Israel Vet. J.* Vol. 58 (4).
- Ludovic, P.B.; Carolyn, L.K.; Simon, G.P.; John, R.; Jennifer, L. and Jeff, L.C. (2005):* Comparison of two laparoscopic suture patterns for repair of experimentally ruptured urinary bladders in normal neonatal calves. *Vet Surg.* Jan, Vol. 34 Issue 1 Page 47.
- Maxine, M.B. (1985):* Outline of veterinary clinical pathology. 3rd ed., Iowa State University Press.
- May, K.A.; Moll, H.D.; Wallace, L.M.; Pleasant, R.S.; and Howard, R.D. (1998):* Urinary bladder marsupialization for treatment of obstructive urolithiasis in male goats. *Vet. Surg.* Nov-Dec; 27(6): 583-8.

- McIlwraith, C.W. and Robertson, J.T. (1998):* Equine surgery. Urethrostomy. Williams and Wilkins Awaverly Co.
- Moore, R.M. (1999):* Principles of intestinal injury and determining intestinal viability: In Auer, A. J. and Stick, A. J. (ed): Equine surgery, 2nd ed., W. B. Saunders Co., Philadelphia, London.
- Nancy, W. (1995):* Urolithiasis in Pygmy Goats. Pygmy Goat WORLD magazine, Nov.
- Pearce, S.; Dearo, A.; Howard, B. and Brisson, B. (2003):* Management of obstructive urolithiasis and concurrent urethral rupture in a goat. Aust. Vet. J., May; 81(5): 268-70.
- Ragab, G.A. and Saif, M.M. (1997):* Urolithiasis in bull and buffalo-bull calves in Beni-Suef governorate. Part I- surgical management. 4th Sci. cong, Egypt. Soci. for Cattle Dis, 7-9 Dec., Assiut, Egypt.
- Skelcher, P.B. and Steele, R.P. (1978):* Use of silicone shunt for the surgical relieve of feline urethral obstruction. Vet. Rec. 102: 98-99.
- Smeak, D.D. (2000):* Urethrotomy and urethrostomy in dog. Clin Tech Small Anim Pract, Vol. 15, No. 1 (feb) 25: 34
- Streeter, R.N.; Washburn, K.E. and McCauley, C.T. (2002):* Percutaneous tube cystostomy and vesicular irrigation for treatment of obstructive urolithiasis in a goat. J A V M A., Aug 15; 221(4): 546-9, 501.
- Susan, E.A. (2003):* Non-infectious diseases of the urinary system in large animals, urolithiasis in ruminants. The merk veterinary manual, 8th Edition
- Turner, A.S.; McIlwraith, C.W. and McCracken, T. (1982):* Techniques in large animal surgery. PP. 254, Lea and Febiger.
- Van Metre, D.C. (2005):* Urolithiasis in Small Ruminants: Surgical and Dietary Management. Presentation by Van Meter, Colorado State Univ, hot topics, net
- Walker, D.F. and Voughan, J.L. (1980):* Bovine and equine urogenital surgery. Philadelphia, Leax, Fibiger, 59-66.
- William, E.H. and Bud, C.T. (1997):* Gastrointestinal Function: In Kaneko, J. J.; Jhon, W. H. and Michael, L. B. (ed): Clinical Biochemistry Of Domestic Animals. 5th edition, Academic Press.