

## Histopathological Changes in Lesional and Perilesional Vitiligo Skin

Ola A Bakry<sup>1</sup>, Rehab M Samaka<sup>2</sup>, Wafaa Shehata<sup>1</sup>, Basma F Elsayah<sup>1</sup>, Iman Seleit<sup>1</sup>

<sup>1</sup>Department of Dermatology and Andrology and STDs, <sup>2</sup>Department of Pathology,

Faculty of Medicine, Faculty of Medicine, Menoufiya University, Egypt.

\*Corresponding Author: Ola Bakry, Mobile: (+20)00201065190509, Email: olabakry8@gmail.com

### ABSTRACT

**Background:** Vitiligo is a skin disease with complex, multifactorial pathogenesis. Abnormalities in surrounding keratinocytes may cause melanocyte death due to deprivation of growth factors.

**Objective:** To evaluate Haematoxylin and Eosin (H&E) histopathological findings in lesional and perilesional vitiliginous skin.

**Patients Methods:** Lesional skin biopsies were taken from 18 vitiligo patients. Perilesional biopsies were taken from 5 patients. All biopsies were stained with Hematoxylin and Eosin for histopathological assessment.

**Results:** Detected changes in lesional skin included increased epidermal thickness, epidermal atrophy, focal disruption of dermoepidermal junction and vacuolar degeneration with focal degree. All examined sections showed congested blood vessels and scanty melanin pigment. Dermal perivascular lymphocytic infiltration was present in all cases.

Detected changes in perilesional skin included increased epidermal thickness, epidermal atrophy, plenty of melanin pigment and focal vacuolar alteration. All examined sections showed congested blood vessels and focally disrupted dermoepidermal junction. Dermal perivascular lymphocytic infiltration was present in all sections.

**Conclusion:** Histopathological changes occur in perilesional as well as lesional vitiligo skin. Therefore, topical or physical treatment for vitiligo should be extended to the surrounding apparently normal skin. This may help in arresting disease course by preventing subclinical or silent lesions from progression to clinically visible lesions.

**Keywords:** Hematoxylin and eosin, Lesional, Perilesional, Vitiligo.

### INTRODUCTION

Vitiligo is an acquired pigmentary disorder of the skin presenting as depigmented or hypopigmented macules or patches. It affects 0.1-2% of population worldwide <sup>(1)</sup>. The prevalence of disease in Egypt's general population was estimated to be 1.22 percent <sup>(2)</sup>. It can begin at any age with almost half of the patients presenting before the age of 20 years <sup>(3)</sup>.

Vitiligo is divided into two types; segmental and nonsegmental. Generalized vitiligo, focal vitiligo, acral vitiligo, acrofacial vitiligo, and vitiligo universalis are examples of nonsegmental vitiligo <sup>(4)</sup>. Vitiligo's pathophysiology is poorly known. The presence of several pathogenic factors for the disease, which progress as a result of the interaction of numerous genes and the environment, is the fundamental explanation <sup>(5)</sup>.

Although epidermal melanocytes form a functional and structural unit with surrounding keratinocytes, most investigations on vitiligo have focused on the abnormalities of melanocytes rather than the abnormalities of keratinocytes <sup>(6)</sup>.

The current work aimed to study histopathological changes in lesional and perilesional vitiligo skin.

### PATIENTS AND METHOD

This study was carried out on 18 patients with vitiligo. Patients were selected from the Dermatology Outpatient Clinic, Menoufia University Hospital in the period between October 2015 and October 2017.

#### Ethical approval:

The study was approved by the Ethics Board of Menoufia Faculty of Medicine University and

an informed written consent was taken from each participant in the study prior to study initiation.

The studied cases were either newly diagnosed or old patients with completely depigmented lesions. The diagnosis of vitiligo was based on the patient's history and the typical clinical features of discrete, well circumscribed, milky white macules and patches.

**Inclusion criteria:** Newly diagnosed patients with different clinical varieties of nonsegmental vitiligo irrespective of age and gender who agreed to join the study and signed written consent.

**Exclusion criteria:** Dermatologic disease other than nonsegmental vitiligo, systemic autoimmune or inflammatory disease, cases having leukoderma secondary to other diseases and patients with vitiligo under treatment.

Every patient was subjected to:

#### 1- History taking:

A) **Personal history:** Name, age and sex.

B) **Present history:** Onset, course and duration of disease.

C) **Family history of vitiligo.**

**2-Examination:** Full general and dermatological examination.

#### 3-Skin biopsies:

Three millimeter punch biopsies were taken under 2% lignocaine local anesthesia from vitiliginous skin of patients. Biopsies from perilesional area were taken from 5 patients. Biopsies were fixed in neutral formalin 10% and submitted to routine tissue processing ending with paraffin embedded blocks



This article is an open access article distributed under the terms and conditions of the Creative Commons Attribution (CC BY-SA) license (<http://creativecommons.org/licenses/by/4.0/>)

formation, in Pathology Department, Faculty of Medicine, Menoufiya University. Several paraffin sections, each 4 um thick, were cut from each block, one of them was stained by Haematoxylin and Eosin to evaluate pathological changes

**Histopathological evaluation:**

- 1- Evaluation of keratinocytes as regard to the presence of vacuolization as a sign of degradation.
- 2- Evaluation of the basement membrane (BM) thickness.
- 3- Presence of residual melanin pigment in the basal layer, or dermal melanophages.
- 4- Evaluation of dermal perivascular inflammatory infiltrate density.
- 5- Presence or absence of dermal angiogenesis.

**Statistical analysis**

Data were collected, tabulated and statistically analyzed using an IBM personal computer with statistical package for the social sciences (SPSS, INC, Chicago, Illinois, USA). Descriptive statistics were used in which quantitative data were presented in the form of mean (X), standard deviation (SD), range and qualitative data were presented in the form numbers and percentages.

**RESULTS**

This study was carried out on 18 patients with vitiligo. Patients were 7 (38.9%) males and 11 (61.1%) females with a male: female ratio of 0.6:1. Their age ranged from 10 to 66 years with 30.2±19.6 as a mean± SD value.

**Clinical characters of studied cases:**

Disease duration ranged from 4 to 12 months with 8.83±3.5 months as a mean ± SD value. Mean± SD duration of biopsied lesion/month was 4±3.23 months. Positive family history was present in 7 (38.9%) cases. Onset of vitiligo was gradual in 14 (77.8%) cases and was accidental in 4 (22.2%) cases. Course of vitiligo was stationary in 4 (22.2%) cases, progressive in 13 (72.2%) cases and was regressive in 1 (5.6%) case. According to site of involvement among studied cases; hands were affected in 7 (38.9%) cases, trunk was affected in 4 (22.2%) cases, lower limbs were affected in 4 (22.2%) cases and neck was affected in 3 (16.7%) cases. Spontaneous re-pigmentation was present in one (5.6%) case but it was absent in 17 (94.4%) cases. Leucotrichia and mucosal lesions were absent in all cases.

According to type of vitiligo; focal vitiligo was present in 6 (33.3%) cases, acrofacial vitiligo was present in 7 (38.9%) cases and generalized vitiligo was present in 5 (27.8%) cases.

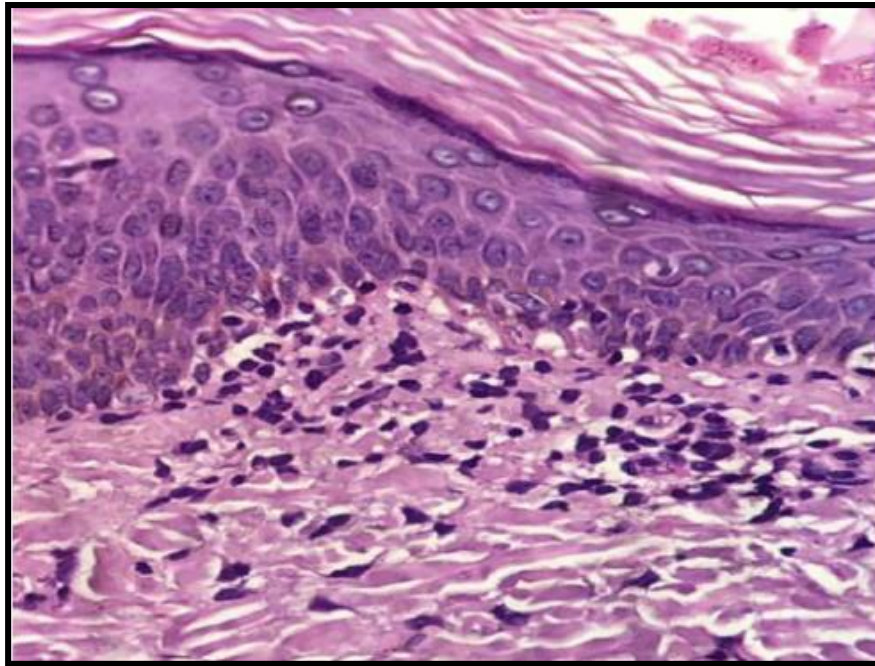
**Hematoxylin and Eosin (H&E) histopathological findings in lesional skin:**

Epidermal thickness was normal in 4 cases and atrophied in 14 cases. No parakeratosis was present in all examined sections. Scanty melanin pigment was present in all examined sections. Dermoepidermal junction was focally disrupted in 12 cases and absent in 6 cases. Vacuolar alteration was present in 13 cases with focal degree. All examined sections showed congested blood vessels. Regarding dermis: perivascular lymphocytic infiltration was present in all cases (**Table 1, Figure1**).

**Table (1): Hematoxylin and Eosin (H&E) histopathological findings among the studied cases (lesional skin)**

Variable		Cases (No=18)	
		No.	%
<b>Epidermis</b>			
Thickness	Normal	4	22.2
	Atrophy	14	77.8
Parakeratosis	Absent	18	100
Melanin pigment	Present	18	100
Dermoepidermal status	Normal	6	33.3
	Disrupted	12	66.7
Degree of disruption	Focal	12	66.7
	Absent	6	33.3
DEJ vacuolar alteration	Present	13	72.2
	Absent	5	27.8
DEJ degree of vacuolar alteration	Focal	13	72.2
	Normal	5	27.8
Epidermal congested blood vessels	Present	18	100
	Absent	0	0
<b>Dermis</b>			
Perivascular lymphocytic infiltration	Present	18	100
	Absent	0	0
Degree of perivascular lymph infiltration	Mild	12	66.6
	Moderate	3	16.7
	Marked	3	16.7

No: number; %: Percentage; DEJ: Dermoepidermal junction



**Figure (1): Histopathology of lesional skin showing intracellular hydropic degeneration of lower epidermis (H&E X 400).**

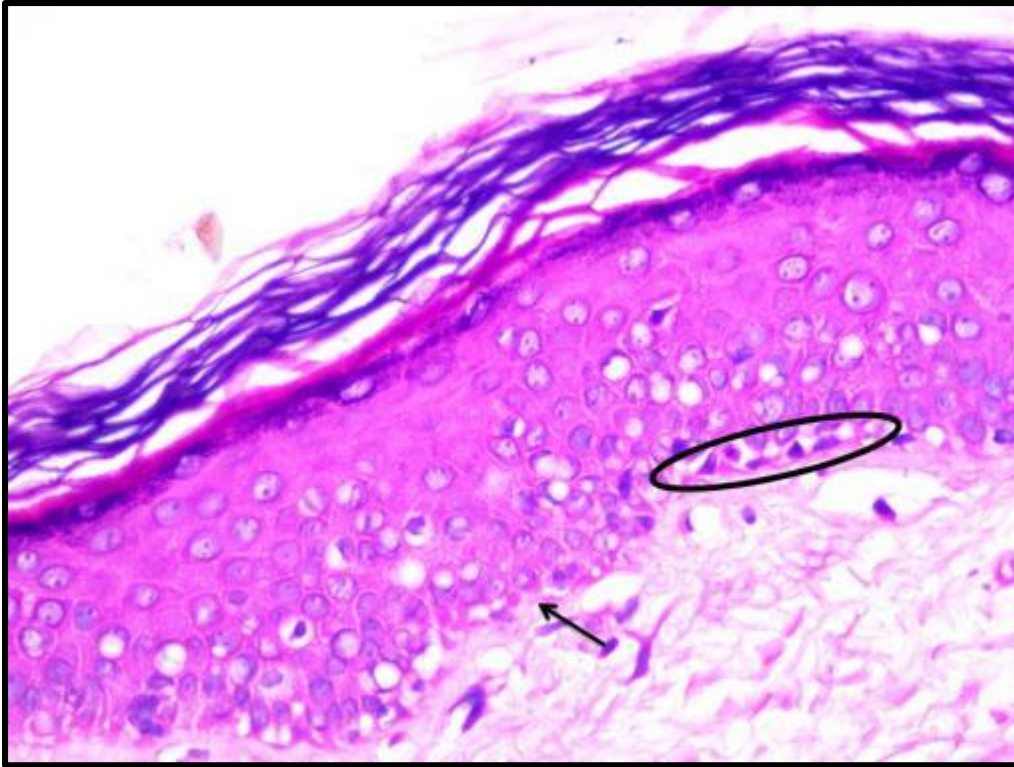
**Hematoxylin and Eosin (H&E) histopathological findings in perilesional skin:**

Epidermal thickness was normal in 3 sections and atrophied in 2 sections. No parakeratosis was present in all examined sections. Melanin pigment was numerous in 4 sections and was scanty in 1 section. Dermoepidermal junction was focally disrupted in all sections. Focal Vacuolar alteration was present in 4 sections. All examined sections showed congested blood vessels. Regarding dermis: perivascular lymphocytic infiltration was present in all sections (**Table 2, Figure 2-8**).

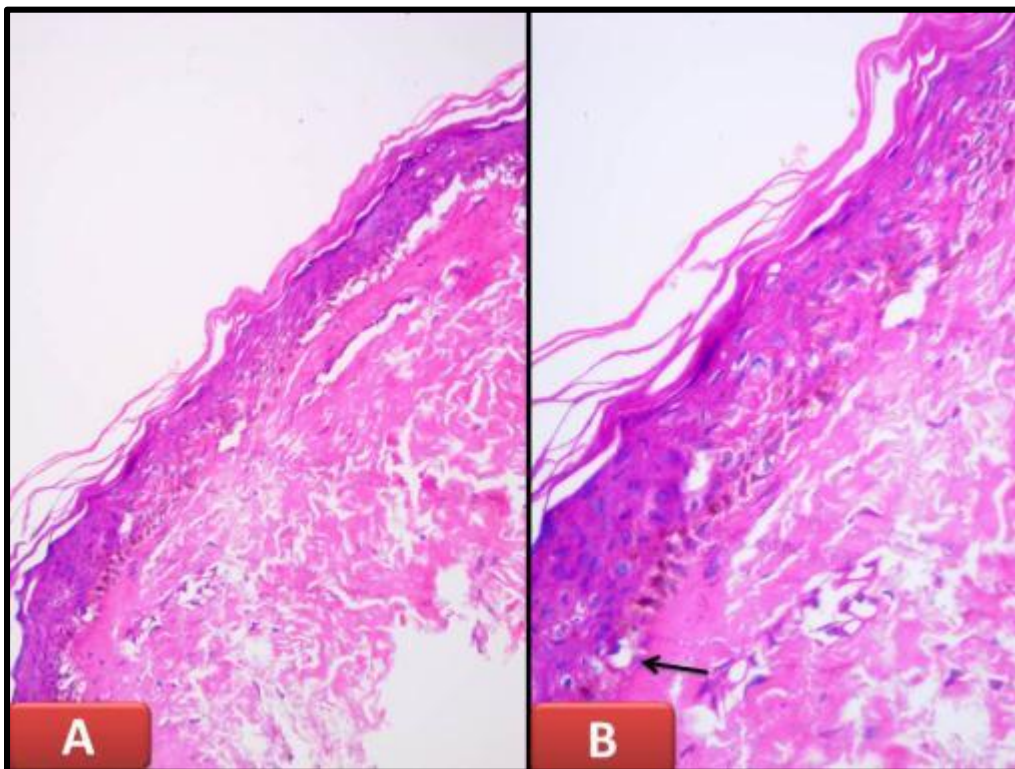
**Table (2): Hematoxylin and Eosin histopathological finding of studied cases (perilesional skin)**

Variables		Perilesional (No=5)	
		No.	%
<b>Epidermis</b>			
Thickness	Normal	3	60
	Atrophy	2	40
Parakeratosis	Present	0	0
	Absent	5	100
Melanin pigment	Present	5	100
	Absent	0	0
Density of pigment	Numerous	4	80
	Few	1	20
Dermoepidermal status	Normal	4	80
	Disrupted	1	20
Degree of disruption	Focal	5	100
DEJ vascular alteration	Present	4	80
	Absent	1	20
DEJ degree of vascular alteration	Focal	5	100
Epidermal congested blood vessels	Present	5	100
	Absent	0	0
<b>Dermis</b>			
Perivascular lymphocytic infiltration	Present	5	100
	Absent	0	0
Degree of perivascular lymph infiltration	Mild	5	100
	Moderate	0	0
	Marked	0	0

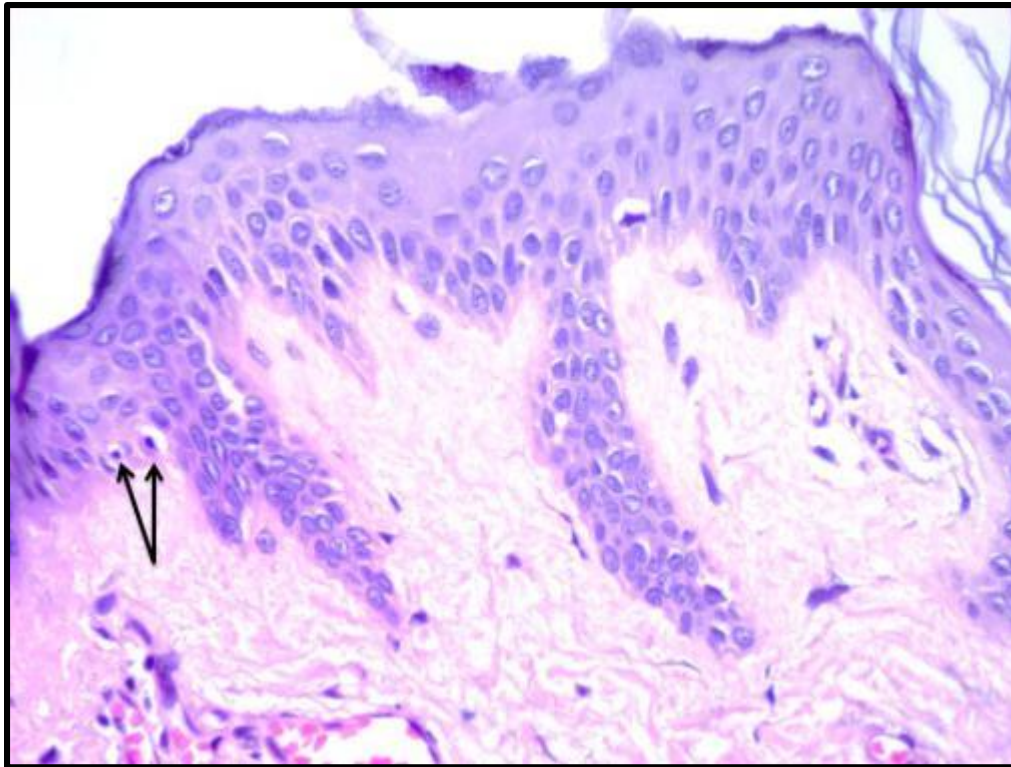
No: number; %: Percentage; DEJ: Dermoepidermal junction



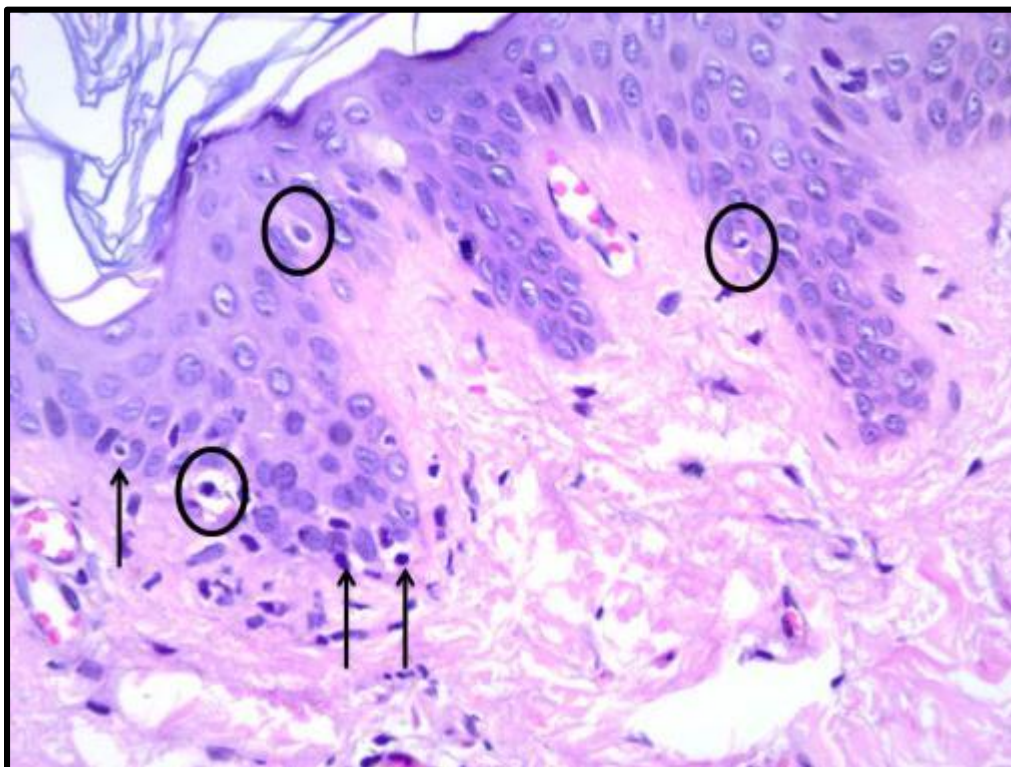
**Figure (2):** Section of vitiligo skin showed absence of melanin pigment, focal dermoepidermal junction disruption (arrow) and focal vacuolar alteration (elliptical figure) (H and E X400).



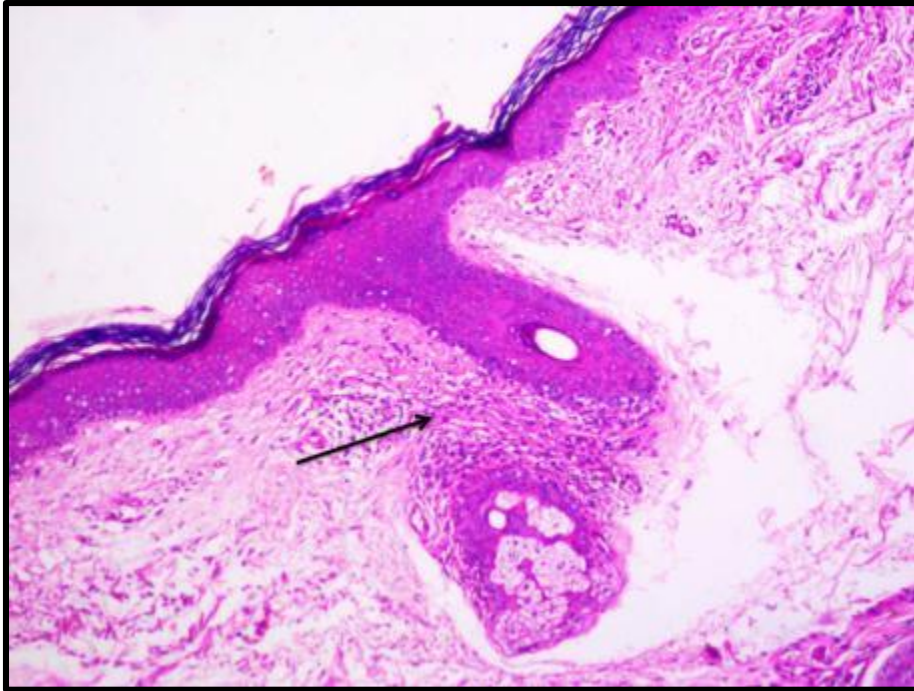
**Figure (3):** Two sections of vitiligo skin showed (A) atrophic epidermis with absence of melanin pigment. (B) Focal dermoepidermal junction vacuolar alteration (arrow) was noted (H and E X100 for A and X 200 for B).



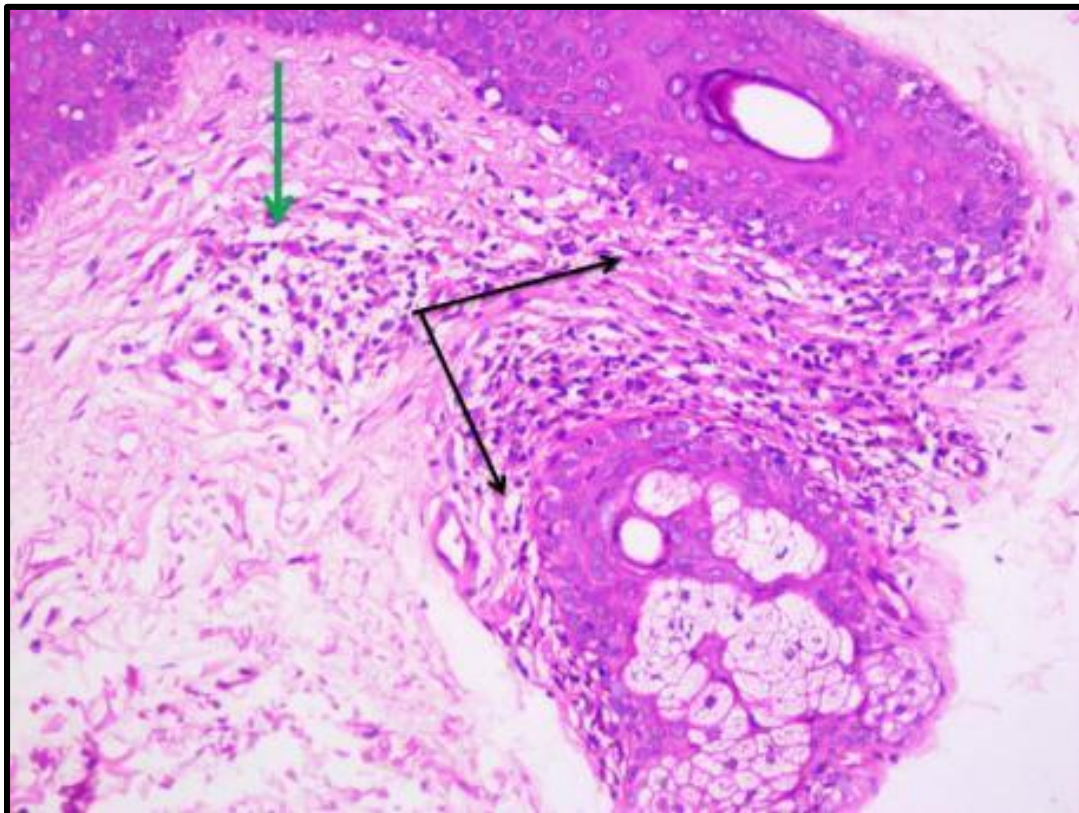
**Figure (4):** Section of vitiligo skin showed apparently normal epidermis with absence of melanin pigment. Focal dermoepidermal junction vacuolar alteration (arrows) was noted (H and E X400).



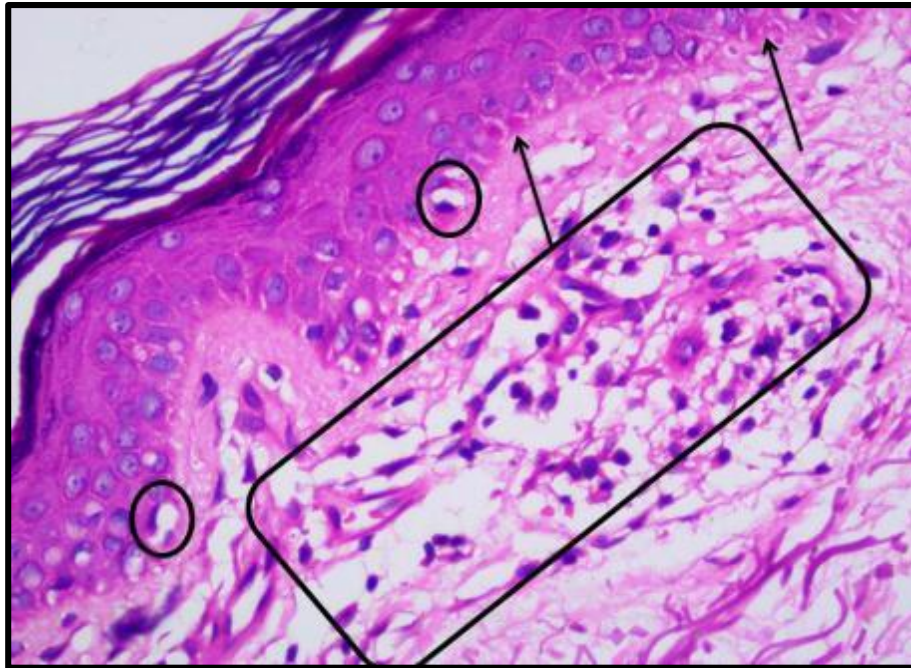
**Figure (5):** Section of vitiligo skin showed normal thickness of epidermis with absence of melanin pigment. Extensive dermoepidermal junction vacuolar alteration were noted. Upper dermis showed fibrosis and scattered lymphocytes (H and E X400).



**Figure (6):** Section of vitiligo skin showed dense inflammatory cellular infiltrates (black arrow) (H and E X100).



**Figure (7):** High power view of previous photo showed dense inflammatory cellular infiltrates at periadnexal (black arrows) and perivascular regions (green arrow) (H and E X 200).



**Figure (8):** Section of vitiligo skin showed atrophic epidermis with absence of melanin pigment, focal dermoepidermal junction disruption (arrows) and focal dermoepidermal junction vacuolation (circles). Dermis showed moderate degree of perivascular inflammatory infiltrates (rectangle) and edema (H and E X 400).

## DISCUSSION

In the current study, lesion epidermal thickness was normal in 4 (22.2%) cases and atrophied in 14 (77.8%) cases. The observed atrophy may be due to wide areas of vacuolar degeneration in the basal and supra basal layers, leading to loss of normal epidermal architecture. Similarly, **Ali Khan et al.**<sup>(7)</sup> reported thinned epidermis in 53% of vitiligo specimens. They also observed degenerative changes in long-standing cases.

In the present work, all examined lesional biopsies showed melanin pigment. The presence of melanin in vitiligo skin is a matter of controversy. An earlier study performed by **Bartosik et al.**<sup>(8)</sup> reported the presence of low amounts of melanin in lesional skin even in long-lasting disease, and ascribed these melanin granules to functioning melanocytes in the perilesional, rather than the amelanotic epidermis. Also **Tobin et al.**<sup>(9)</sup> observed small amounts of melanin granules in the amelanotic skin of vitiligo patients, even up to 25 years of disease duration and suggested that some partially functioning melanocytes are retained in this disorder, as it is highly unlikely that this melanin could be transferred from outside the lesion. They proved their suggestion by demonstrating retention of single melanocytes in lesional epidermis, by light and electron microscopy. These melanocytes could be isolated in vitro from all samples of lesional and normal skin, independent of disease duration and treatment. However, **Ortonne and Bose**<sup>(10)</sup> suggested that the remaining melanocytes are without melanogenic activity. Another study by **Singh et al.**<sup>(11)</sup> found that melanocytes at basal layer were absent among the majority of their patients. Histopathological

examination of H&E-stained sections revealed absent melanin pigment in lesional skin in all patients. Going with that **Le Poole et al.**<sup>(12)</sup> and **Abdallah et al.**<sup>(13)</sup> postulated that long-standing vitiligo patches show complete loss of melanin and absence of melanocytes from the epidermis. **Le Poole et al.**<sup>(12)</sup> concluded that melanocytes are completely absent within vitiligo lesions. Also, **Hewedy et al.**<sup>(14)</sup>, reported that vitiligo lesions showed mature melanocytes which means that the disease is not caused by absence of melanocytes and it is a hypomelanotic and not a hypomelanocytic disorder.

In the current study, the dermis of lesional skin showed perivascular lymphocytic infiltration in all cases. This went with **Abdou et al.**<sup>(15)</sup> who reported perivascular lymphocytic infiltrate in 73.3% of their cases. However, this was much more than what had been reported by **Kim et al.**<sup>(16)</sup> who found inflammation in only 41% of vitiliginous skin biopsies. Also, **Gamil et al.**<sup>(17)</sup> reported lymphocytic infiltrate in lesional skin in papillary dermis (50%). A perivascular lymphocytic infiltrate was also noted in these patients. **Van Geel et al.**<sup>(18)</sup> reported discrete perivascular and perifollicular infiltrate composed of CD4+ and CD8+T lymphocytes, as observed in pilomatrixomas. These may be due to inflammatory changes. These changes were found more frequently in early lesions<sup>(19)</sup>.

In the current study, there was an increase in basement membrane thickness in all examined cases. This was in agreement with an ultrastructural study by **Roig-Rosello and Rousselle**<sup>(20)</sup> as normal dermal nerves are performed. Also, **Stylianou et al.**<sup>(21)</sup> reported that, in vitiligo it is well-documented that epidermis is thicker than in normally pigmented skin in frozen

sections and that inflammatory changes are more frequent and intense in the epidermis and dermis of perilesional skin. **Gniadecka et al.** <sup>(22)</sup> and **Aroni et al.** <sup>(23)</sup> concluded that the depigmented epidermis in vitiligo became hyperplastic with increased rete ridges.

In the present work, perilesional skin showed perivascular lymphocytic infiltration in all examined sections. Basement membrane thickening and epidermal atrophy were detected in 14 cases (77.8%) of perilesional skin biopsies. This went with **Gamil et al.** <sup>(17)</sup> who showed that, histopathological examination of both lesional and perilesional skin revealed lymphocytic infiltrate along the basal layer and in perivascular distribution in (50%) of patients before therapy. Authors concluded that extension of inflammatory changes to apparently normal perilesional skin indicates the importance of using therapeutic modalities that have access to pigmented perilesional skin in order to prevent disease progression. Narrow-band ultraviolet B (NB-UVB) phototherapy seems to be a useful modality that may help to achieve this purpose.

In the current study, the density of pigment was numerous in perilesional area compared to lesional vitiliginous areas. This was in agreement with **Van Geel et al.** <sup>(18)</sup>. Another study conducted by **Le Poole et al.** <sup>(12)</sup> confirmed the presence of degenerated melanocytes in the borderline area within a vitiligo lesion. In another patient, enlarged dendritic melanocytes were found in such areas. The finding of such melanocytes with altered morphology was in accordance with findings of **Bhanulyengar and Misra** <sup>(24)</sup>. Because the biopsies used were taken from skin that was clinically white, depigmentation may precede melanocyte destruction in vitiligo lesions.

## CONCLUSION

Histopathological changes occur in perilesional as well as lesional vitiligo skin. Therefore, topical or physical treatment for vitiligo should be extended to the surrounding apparently normal skin. This may help in arresting disease course by preventing subclinical or silent lesions from progression to clinically visible lesions.

## REFERENCES

1. **Krüger C, Schallreuter K (2012):** A review of the worldwide prevalence of vitiligo in children/adolescents and adults. *International journal of dermatology*, 51(10):1206-12.
2. **Abdel-Hafez K, Abdel-Aty M, Hofny E (2003):** Prevalence of skin diseases in rural areas of Assiut Governorate, Upper Egypt. *International Journal of Dermatology*, 42(11):887-92.
3. **Speeckaert R, van Geel N (20017):** Vitiligo: an update on pathophysiology and treatment options. *American Journal of Clinical Dermatology*, 18(6):733-44.
4. **Ezzedine K, Lim H, Suzuki T et al. (2012):** Revised classification/nomenclature of vitiligo and related issues: the Vitiligo Global Issues Consensus Conference. *Pigment Cell & Melanoma Research*, 25(3): 1-3.
5. **Mohammed G, Gomaa A, Al-Dhubaibi M (2015):** Highlights in pathogenesis of vitiligo. *World Journal of Clinical Cases*, 3(3):221-25.
6. **Singh A, Gotherwal V, Junni P et al. (2017):** Mapping architectural and transcriptional alterations in non-lesional and lesional epidermis in vitiligo. *Scientific Reports*, 7(1):1-10.
7. **Ali Khan A, Lesley M, Felsten D et al. (2011):** Vitiligo: A comprehensive overview Part I. Introduction, epidemiology, quality of life, diagnosis, differential diagnosis, associations, histopathology, etiology, and work-up. *J Am Acad Dermatol.*, 65: 473-491.
8. **Bartosik D, Baj J, Wlodarczyk M (1998):** Molecular and functional analysis of pTAV320, a repABC-type replicon of the *Paracoccus versutus* composite plasmid pTAV1. *Microbiology*, 144(11):3149-57.
9. **Tobin D, Swanson N, Pittelkow M et al. (2000):** Melanocytes are not absent in lesional skin of long duration vitiligo. *J Pathol.*, 191:407-416.
10. **Ortonne J, Bose S (1993):** Vitiligo: where do we stand? *Pigment cell Ros.*, 6(2):61-72.
11. **Singh J, Gupta V, Kumar S et al. (2019):** Clinical and histopathological study in vitiligo patients. *JMSCR.*, 7(3):1457-1463.
12. **Le Poole I, van den Wijngaard R, Westerhof W et al. (1993):** Presence or absence of melanocytes in vitiligo lesions: an immunohistochemical investigation. *Journal of Investigative Dermatology*, 100(6):816-22.
13. **Abdallah M, Abdel-Naser M, Moussa M et al. (2003):** Sequential immunohistochemical study of depigmenting and repigmenting minigrafts in vitiligo. *Eur J Dermatol.*, 13:548-552.
14. **Hewedy E, Hassan A, Salah E et al. (2012):** Clinical and ultrastructural study of nevus depigmentosus. *Journal of Microscopy and Ultrastructure*, 1(1-2):22-9.
15. **Abdou A, Maraee A, Shoeb M (2012):** Immunolocalization of Tenascin C in vitiligo. *Appl Immunohistochem Mol Morphol.*, 20:501-511.
16. **Kim YC, Kim YJ, Kang HY, Sohn S, Lee ES (2008):** Histopathologic features in vitiligo. *Am J Dermatopathol.*, 30:112-116.
17. **Gamil H, Assaf M, Khater M et al. (2019):** Histopathological findings in lesional and perilesional skin of vitiligo patients before and after narrow band ultraviolet b phototherapy. *Zagazig University Medical Journal*, 25(3):326-34.
18. **Van Geel N, Mollet I, De Schepper S et al. (2010):** First histopathological and immunophenotypic analysis of early dynamic events in a patient with segmental vitiligo associated with halo nevi. *Pigment Cell & Melanoma Research*, 23(3):375-84.
19. **Glassman S (2011):** Vitiligo, reactive oxygen species and T-cells. *Clinical Science*, 120(3): 99-120.
20. **Roig-Rosello E, Rousselle P (2020):** The human epidermal basement membrane: A shaped and cell instructive platform that aging slowly alters. *Biomolecules*, 10(12):1607-17.
21. **Stylianou V, Eleftherios I, Nikolaos K et al. (2012):** Correlating epidermal thickness and basement membrane length to angiogenesis in the centre and the periphery of vitiligo lesion. *Indian Journal of Dermatology, Venereology, and Leprology*, 78(3):368-73.
22. **Gniadecka M, Wulf H, Mortensen N et al. (1996):** Photoprotection in vitiligo and normal skin. A quantitative assessment of the role of stratum corneum, viable epidermis and pigmentation. *Acta Dermato-Venereologica*, 76(6):429-32.
23. **Aroni K, Voudouris S, Ioannidis E et al. (2010):** Increased angiogenesis and mast cells in the centre compared to the periphery of vitiligo lesions. *Archives of Dermatological Research*, 302(8):601-7.
24. **Bhanulyengar B, Misra R (1988):** Neural differentiation of melanocytes in vitiliginous skin. *Cells Tissues Organs*, 133(10):62-5.