

## Original Article

## Multiple Intracranial Aneurysms Presented with Subarachnoid Hemorrhage; Which to Secure and How?

Tamer Ibrahim Metwaly, Ahmed Elsayed Sultan, Tarek Abd El-Wahab Rayan

Department of Neurosurgery, Faculty of Medicine, Alexandria University, EGYPT

Received: 21 March 2021 / Accepted: 26 May 2021 / Published online: 29 June 2021

**BACKGROUND:** Dealing with multiple intracranial aneurysms (MIA) presenting with subarachnoid hemorrhage (SAH) is challenging.

**OBJECT:** To make a proposal for the decision-making regarding which aneurysm to secure and how, as the most challenging part in the management of MIA.

**METHODS:** This descriptive study included 25 patients presenting with SAH and having multiple intracranial aneurysms. All patients had a brain computed tomography (CT) scan, CT angiography (CTA), and digital subtraction angiography (DSA). Patients were treated in our institution using microsurgical clipping and/or endovascular embolization according to the clinical and radiological situation. Functional outcome was assessed by modified Rankin scale.

**RESULTS:** Fifteen females and 10 males with average age of 48 years were included. All patients (100%) presented with hemorrhage. Ten patients (40%) were Hunt and Hess (H&H) grade I, seven patients (28%) grade II, 3 patients (12%) grade III, 3 patients (12%) grade V and 2 patients (8%) grade IV. Fisher scale was grade II in 11 patients (44%), grade IV in 9 patients (36%) and 5 patients (20%) were grade III. Criteria for the suspected ruptured aneurysm were aneurysm wall irregularity in 24 patients (96%) and the largest size in 23 cases (92%). The epicenter of hemorrhage was a satisfactory localizing sign on CT in only 10 cases (40%). Fifty-six aneurysms were encountered in the 25 patients; 19 patients (76%) had 2 aneurysms and 6 patients (24%) had 3 aneurysms. Clipping was done for 40 aneurysms (71%), wrapping for 2 aneurysms (3%), 4 aneurysms (7%) were followed up, 8 aneurysms (14%) were coiled, and 2 aneurysms (3%) were treated by flow diverters. Twenty patients (80%) had a good outcome on the modified Rankin scale, 4 patients (16%) had mental changes and one patient (4%) had residual neurological deficit.

**CONCLUSION:** The ruptured one in multiple intracranial aneurysms can be suspected by its size and wall irregularity especially in the absence of localizing sign in the CT scan. High-resolution CTA and/or 3D DSA are highly helpful. These cases should be managed in specialized centers where the surgical and endovascular treatment modalities are available.

**KEYWORDS:** Clipping, coiling, multiple aneurysms, subarachnoid hemorrhage.

### INTRODUCTION

Multiple intracranial aneurysms (MIA) are present in 5-30% of the cases with spontaneous subarachnoid hemorrhage (SAH). Of these MIA, 75% are two aneurysms, 15% are three aneurysms, and 10% are more than three aneurysms. Risk factors include smoking, hypertension, elder age, female sex, family history, obesity, vasculopathy, fibromuscular dysplasia, and polycystic renal disease. The prognosis is less favorable than for those with a single aneurysm.<sup>1-3</sup>

High resolution CTA and or three-dimension DSA should be used for the detection of multiple cerebral aneurysms. Clues for which aneurysm had bled include lateralizing focal neurological deficits, the epicenter of blood clot on CT or Magnetic Resonance Imaging (MRI) brain, area of maximal vasospasm on the angiogram, location at high flow angles, aneurysm morphology, and hemosiderin distribution on susceptibility weighted image (SWI). Aneurysm morphology include irregular outline, multiple lobules,

presence of a bleb, high height to width ratio, high height to neck (aspect ratio) and high width to neck ratio (bottleneck ratio). If none of the above is found, suspect the largest one. Recently, computational flow dynamics (CFD) may be helpful in the determination of the ruptured one.<sup>4-7</sup>

Treatment options include surgical, endovascular, or combined securing depending on the clinical situation, imaging findings, and center experiences. Securing of all aneurysms in one session whenever feasible protects the patient from rebleeding and treating only the unruptured ones.<sup>8-10</sup>

The decision making regarding which aneurysm to secure and how in patients presented with SAH and having MIA will be highlighted in our study.

### METHODS

Our descriptive study was conducted on 25 patients presented with SAH. All patients were subjected to full neurological examination, relevant laboratory investigations, brain CT, and cerebral angiography (CTA and DSA). All patients had MIA on angiogram.

#### Correspondence:

Dr. Tamer Ibrahim Metwaly  
Email: tarekcrayn@hotmail.com

Patients were admitted to the neurosurgical intensive care unit (NICU) and all the measures for management of SAH were started. Emergency planning for aneurysm securing either surgical, endovascular, or combined was conducted according to the clinical situation, radiological findings and the feasibility of intervention modality including financial issues.

Cerebrospinal fluid (CSF) diversion was performed in 15 patients (60%) with active hydrocephalus, either by lumbar drain (5 patients; 20%) or external ventricular drain (EVD) (10 patients; 40%). After the securing procedure, the patient was returned to NICU to continue the measures against vasospasm; good hydration, hypertension, hemodilution, selective Calcium channel blocker Nimodipine, and angioplasty if needed in refractory cases. Patients were also observed for fluid and electrolytes balance

The patients stayed in the hospital until the vasospasm period ended. The follow-up CT brain was done immediately after surgery. Patients were followed up for at least 3 months clinically and by angiography.

The study was submitted to and approved by our institutional ethics committee (ethics committee, faculty of medicine, Alexandria University (IRB NO: 00007555- FWA NO: 00018699, <http://www.hhs.gov/ohrp/assurances/index.html>).

**Table 1: Master table**

Case	Age/sex	H & H	Fisher Grade	Aneurysms				Intervention	Outcome MRS
				Site	Largest diameter	Morphology	Suspected bled		
1	70 F	1	2	Rt ICB	3 mm	Irregular	Suspected	Clipping by Rt pterional ICA: ruptured one	Good
				A Com A	4 mm	Regular			
2	65 F	1	3	Rt MCB	3 mm	Regular		Clipping by Rt pterional A Com A: ruptured one	Good
				A Com A	4mm	Irregular	Suspected		
				Lt M1	3 mm	Regular			
3	50 F	2	3	Rt M1	4 mm	Irregular	Suspected	Clipping by Rt pterional M1: ruptured one	Good
				A Com A	3 mm	Regular			
				Rt SCA	3 mm	Regular			
4	55 F	2	4	A Com A	3 mm	Regular	Suspected	Clipping of 2 aneurysms by Lt COZ approach (unruptured) Endovascular balloon assisted coiling of BA (ruptured one)	Good
				Lt P1	2 mm	Regular			
				BA	1 mm	Regular			
5	45 F	1	4	Lt MCB	4 mm	Irregular surrounded by ICH	Suspected	Clipping of ruptured Lt MCB by Lt pterional Clipping of unruptured Rt MCB by Rt pterional 3 months later	Good
				Rt MCB,	3mm	Regular			

**RESULTS**

Fifteen females and 10 males with an average age of 48 years were studied (Table 1). All patients presented with hemorrhage. Ten patients (40%) were H&H grade I, seven patients (28%) grade II, 3 patients (12%) grade III, 3 patients (12%) grade V and 2 cases (8%) grade IV. Fisher scale was grade II in 11 patients (44%), grade IV in 9 patients (36%) and 5 patients (20%) grade III. Criteria for the suspected ruptured aneurysm were wall irregularity in 24 patients (96%) and the largest size in 23 cases (92%). The epicenter of hemorrhage was a satisfactory localizing sign on CT in only 10 cases (40%).

Fifty-six aneurysms were encountered in the 25 patients. Nineteen patients (76%) had 2 aneurysms and 6 patients (24%) had 3 aneurysms. Clipping was done for 40 aneurysms (71%), wrapping for 2 aneurysms (3%), 4 aneurysms (7%) were followed up, 8 aneurysms (14%) were coiled, and 2 aneurysms (3%) were treated by flow diverters because these aneurysms were dissecting ones with wide necks and unhealthy vessel segment. Twenty patients (80%) had a good outcome on the modified Rankin scale (observed in patients presents with H& H grade I, II and III), 4 patients (16%) had mental changes and one patient (4%) had residual neurological deficit.

6	22 M	2	2	Lt ICB	5 mm	Irregular	Suspected	Clipping of ruptured ICA by Lt pterional	Good
				RT M1	4 mm	Regular		Coiling of unruptured MCA 1 month later	
7	44 M	3	4	A Com A	5 mm	Irregular	Suspected	Clipping of ruptured A Com A by Rt pterional	Good
				Distal ACA,	4 mm	Regular		Coiling of unruptured Distal ACA 1 month later VPS for late HCP	
8	36 M	2	4	Distal ACA	5 mm	Irregular	Suspected	Clipping of ruptured ACA	Good
				Rt MCB	5mm	Regular		Coiling of unruptured MCA 1 month later	
9	30 M	5	4	Basilar tip	9 mm	Irregular	Suspected	VPS for HCP	Residual mental changes
				Rt ICA dissecting aneurysm	Blister			Coiling of ruptured basilar tip	
				Lt ICA dissecting aneurysm	Blister			Flow diverters for ICA aneurysms one by one after 1 month 2 weeks interval	
10	55 F	2	2	Lt P Com A	3 mm	Irregular	Suspected	VPS for HCP	Good
				Rt ICB	2 mm	Regular		Clipping of ruptured P Com A by Lt pterional	
11	58 M	5	4	A Com A	6.5 mm	Irregular	Suspected	Clipping of both aneurysms by Rt pterional	Residual mental changes
				Rt anterior choroidal	2.5mm	Regular		A Com A is ruptured one	
12	30 M	1	2	Lt ICA	6 mm	Irregular	Suspected	Clipping of ruptured ICA by Lt pterional	Good
				Rt MCB	3 mm	Regular		Clipping of Rt MCB by Rt pterional 3 months later	
13	32 F	1	2	Rt MCB	4 mm	Irregular	Suspected	Clipping of ruptured MCB and wrapping of M1 by Rt pterional	Good
				Rt M1	3 mm	Regular			
14	48 M	1	3	A Com A	4 mm	Irregular	Suspected	Clipping of A Com A and MCB by Rt pterional	Good
				Rt MCB	3 mm	Regular		(A com ruptured one)	
				Lt MCB	1mm	Regular		Follow up of Lt MCB	

15	49 M	4	4	A Com A	9 mm	Irregular with 2 lobes	Suspected	VPS for HCP	Residual mental changes
				Rt Ophthalmic	2 mm	Regular		Clipping and wrapping of ruptured A Com A	
16	55 M	5	4	A Com A	5 mm	Irregular	Suspected	Coiling of ruptured A Com A	Residual mentality and personality changes
				Distal ACA	7 mm	Regular		Clipping of ACA 1 month later	
17	54 F	2	2	Lt Ophthalmic	12mm	Irregular	Suspected	Coiling of ruptured Ophthalmic	Good
				A Com A	2 mm	Regular		Follow up of A Com A	
18	50 F	1	2	A Com A	5 mm	Irregular	Suspected	Clipping of both by Lt pterional	Good
				Lt MCB	4 mm	Regular		A Com A is ruptured one	
19	45 F	1	2	A Com A	5 mm	Irregular	Suspected	Clipping of both by Rt pterional	Good
				Rt MCB	3 mm	Regular		A Com A ruptured one	
20	56 f	2	3	Rt MCB	12 mm	Irregular	Suspected	Clipping by Rt pterional	Good
				Rt M1	3 mm	Regular		MCB is ruptured one	
21	35 f	4	3	Lt P Com A	13 mm	Irregular	Suspected	Clipping of both	Good
				LT MCB	4 mm			P Com A is ruptured one	
22	14 f	3	4	Lt ICA bifurcation	11 mm	Irregular (2 lobes)	Suspected	Endovascular coiling of Lt ICA	Good
				Rt ICA bifurcation	3 mm	Regular		Follow up of Rt ICA one	
23	50F	1	2	A Com A	5 mm	Irregular	Suspected	Clipping of both by Rt pterional	Good
				Rt MCB	3 mm	Regular		A Com A is ruptured one	
24	52 M	3	2	Rt MCB	5 mm	Irregular		Clipping of the 3 aneurysms by Rt pterional	Residual mild Lt side weakness (as pre-op)
				Rt M1	2 mm				
				Lt MCB	3 mm	Regular			
25	47 f	1	2	A Com A	5mm	Irregular		Clipping of both by Rt pterional	Good
				Rt MCB	3 mm	Regular		A Com A is ruptured one	

H&H: Hunt & Hess, MRS: Modified Rankin Scale, Rt: Right, ICB: Internal carotid bifurcation, A Com A: Anterior communicating artery, ICA: Internal carotid artery, MCB: Middle cerebral bifurcation, Lt: Left, SCA: Superior cerebellar artery, BA: Basilar artery, COZ: Cranio-orbito-zygomatic, ICH: Intracerebral hemorrhage, MCA: Middle cerebral artery, ACA: Anterior cerebral artery, VPS: Ventriculo-peritoneal shunt, HCP: Hydrocephalus, P Com A: Posterior communicating artery.

Illustrative cases

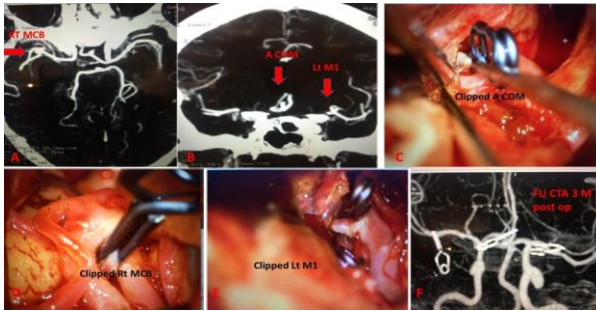


Fig 1: Case 2, 65 years female, H&H grade 1, Fisher grade 3, presented with 3 aneurysms (A Com A, right MCA, left M1) operated by right pterional approach, with clipping of ruptured A Com artery aneurysm and both unruptured right MCA and left M1 aneurysms.

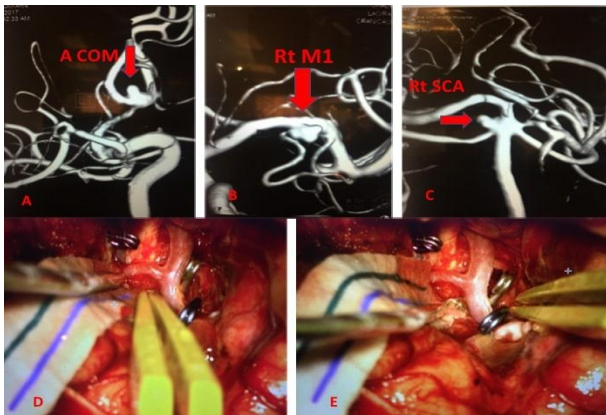


Fig 2: Case 3, 50 years female, H&H grade 2, Fisher grade 3, presented with 3 aneurysms (A Com artery, right M1, right SCA), operated by right pterional approach with clipping of ruptured A Com artery aneurysm and both unruptured right M1 and right SCA aneurysms.

DISCUSSION

About 30% of the patients with cerebral aneurysms present with multiple ones. Determination of the ruptured one is very important for decision making regarding which aneurysm to secure to prevent the most serious complication which is rebleeding. This is especially important for endovascular planned cases where antiplatelet medications are needed for most of the patients and the source of hemorrhage cannot be confirmed visually as in microsurgery.<sup>11-13</sup>

Aneurysms are either spherical (the width  $\geq$  80% of the dome height), lobulated (the lobules were smooth and of approximately the same size), or complex (the lobules are asymmetric or multiple) which is strongly associated with rupture.<sup>14,15</sup>

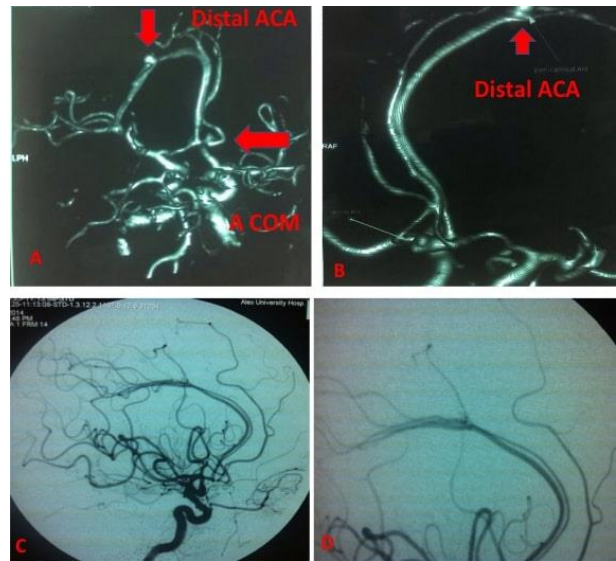


Fig 3: Case 7, 44 years male, H&H grade 3, Fisher grade 4 presented with 2 aneurysms (A Com artery and distal ACA) managed by clipping of ruptured A Com artery aneurysm and coiling of unruptured distal ACA aneurysm 1 month later.

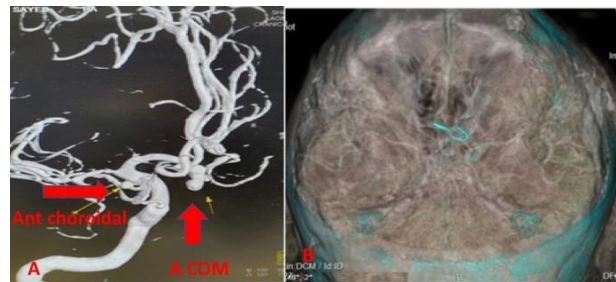


Fig 4: Case 11, 58 years male, H&H grade 5, Fisher grade 4, presented with 2 aneurysms (A Com artery and right anterior choroidal artery), operated by right pterional approach with clipping of ruptured A Com artery and unruptured anterior choroidal artery aneurysms.

The epicenter of blood clot on CT scans was the primary indicator of the bleeding source in a study by Orning et al. where the blood clot was clearly confining to the ruptured aneurysm. The ruptured one was misidentified in 16.2% of the patients with non-definitive bleeding patterns.<sup>16</sup> In our study, the epicenter of hemorrhage was a satisfying localization sign in only 10 cases (40%).

A prediction score, developed by Hadjiathanasiou et al., is a good way to determine the ruptured one. They used the size, shape (regular or irregular), and location (anterior or posterior circulation) (Table 2). They concluded that the higher the score of the aneurysm, the more probable it is the ruptured one.<sup>17</sup>

**Table 2: Aneurysm - specific prediction score = A + B + C<sup>17</sup>**

A	0.0427 x size of aneurysm (mm)
B	0 if Location = AcomA and AA 0.0104 if location = PcomA 0.1831 if location = posterior circulation 0.4055 if location = MCA 0.5973 if location = ICA without PcomA
C	0 if shape = regular 0.5387 if shape = irregular

Neyazi et al. utilized the population, hypertension, age, size of aneurysms, SAH in history, and site of the aneurysms (PHASES) score, originally used to predict the risk of bleeding in unruptured aneurysms. They could apply the score to predict the ruptured one in cases of MIA.<sup>18</sup>

Different rupture identification models were designed to predict the rupture in MIA. Rajabzadeh-Oghaz et al. retrospectively collected the medical data of 93 patients with at least 2 cerebral aneurysms presented with SAH in which the ruptured one was confirmed in surgery or by definitive bleeding patterns. They established 13 morphologic and 10 hemodynamic parameters along with site and type (sidewall/bifurcation) and found that size ratio was the best individual indicator for the ruptured aneurysm.<sup>19</sup>

Berg et al. documented Multiple Aneurysms Anatomy Challenge (MATCH). Seventeen different centers constructed hemodynamic simulations to detect the ruptured one in a patient with MIA. Most of the centers (7 centers) concluded that the largest one was the ruptured one.<sup>20</sup>

Aneurysm location was reported as a risk factor for aneurysm rupture. According to the international study of unruptured intracranial aneurysms (ISUIA), the posterior circulation aneurysms, including the posterior communicating artery (P Com A) aneurysm, have a higher risk of rupture.<sup>21</sup> Juvela et al. reported that the anterior cerebral artery (ACA) aneurysms were at higher risk of rupture.<sup>22</sup> Nehls et al concluded that anterior communicating artery (A Com A) aneurysm had the highest risk of bleeding.<sup>23</sup> Hadjiathanasiou et al. found that the ACA aneurysms including the A Com A aneurysms had the highest rupture risk.<sup>17</sup> Also, aneurysm size was also concluded to be a risk factor for bleeding. Backes et al. found that the ruptured one was not the largest aneurysm in 29% of the patients.<sup>24</sup>

Irregular aneurysms are risky to bleed independent of size or location, as concluded by Backes et al. <sup>24</sup> Maslehaty et al found that size and shape were predictive of bleeding. <sup>25</sup> Nehls et al. concluded that

those irregular aneurysms were risky to bleed, the same with Hadjiathanasiou et al study.<sup>17,23</sup>

In our study, we relied on clinical and radiological findings (high-resolution CTA and DSA were performed to all cases); (1) the site of maximum blood clot thickness on CT that were relevant in 10 cases, (2) larger aneurysm size (was correlated in 24 cases), (3) larger aspect ratio (dome height to neck width), and (4) irregular shape aneurysm (was correlated in 23 cases). We could accurately predict rupture in 24 out of 25 cases.

In our study, the average age was 48 years, and the female to male ratio was 3:2. The correlation between increased age and female sex and the incidence of SAH in patients with multiple aneurysms remains controversial.<sup>26</sup>

In our study, A Com A aneurysms were the most common ruptured ones in 9 cases followed by middle cerebral artery (MCA) aneurysms in 5 cases. In a study of Roethlisberger et al., MCA aneurysms were the most common ruptured aneurysms. They have also found that in patients with MIA, aneurysms were not randomly distributed along the circle of Willis, but rather located in defined patterns. Patients with a ruptured P Com A aneurysm were more likely to harbor a basilar artery aneurysm and more likely to have a mirror image P Com A aneurysm.<sup>27</sup>

In our study, the decision making as regards which aneurysm to secure and how was taken by our neurovascular team which consists of hybrid neurosurgeons that can perform surgical and endovascular securing. In decision making, we considered the clinical condition of the patient (H&H grading), SAH Fisher scale, angiographic features (suitable for surgery, endovascular or both), vasospasm, Intra-Cranial Pressure (ICP), financial issues (endovascular treatment is more expensive relative to surgical treatment in our developing country and not all the citizens are covered by National Health Insurance (NHI), radiation exposure and renal condition to balance the benefits and risks particularly for poor-grade SAH patients.

So far, there is no common agreement regarding the optimum treatment plan of multiple unruptured intracranial aneurysms, and the plan differs from one center to another.<sup>28</sup> Juvela et al. concluded that age was the predictor of rupture in patients with MIA, and surgical clipping was recommended.<sup>29</sup> Some centers consider that if all the aneurysms can be coiled with low risk, they go for coiling. If one or more is not suitable, they go for surgery first and clip as many aneurysms as possible and leave the risky clipping ones for coiling later on.<sup>30,31</sup>

We recommend treating all aneurysms at the same session whenever feasible to protect the patient from the risk of rebleeding and eliminate the risk of mistakenly treating only the unruptured ones. Some centers consider treatment of unruptured aneurysms in the same session controversial due to the risk of additional

complications, thus they were treated in a second session, however; there is a risk of missing treating the ruptured one.<sup>32,33</sup>

In our study, if the patient has poor clinical and SAH grade, significant vasospasm, and high ICP, we favored CSF diversion (lumbar drain or EVD) and endovascular treatment, while surgical clipping was mainly for low-grade SAH, no significant vasospasm or high ICP and for the patients that cannot afford endovascular treatment as not all patients are covered by national health insurance.

## CONCLUSION

Aneurysm size and wall irregularity, especially in the absence of localizing signs on CT scan, are good clues for which aneurysm was the ruptured one in patients with SAH and multiple aneurysms. High-resolution CTA and 3D DSA are highly helpful.

Both surgical and endovascular options should be equally available in centers dealing with these cases. Aneurysm size, morphological features and location, ICP, and vasospasm should be well studied for wise decision making regarding which aneurysm to secure and how to secure.

## List of abbreviations

ACA: Anterior cerebral artery.  
 A com A: Anterior communicating artery.  
 CFD: computational flow dynamics.  
 CSF: Cerebrospinal fluid.  
 CT: Computed tomography.  
 CTA: Computed tomographic angiography.  
 DSA: Digital subtraction angiography.  
 EVD: External ventricular drain.  
 H&H: Hunt and Hess.  
 ICP: intracranial pressure.  
 ISUIA: international study of unruptured intracranial aneurysms.  
 MATCH: Multiple Aneurysms Anatomy Challenge.  
 MCA: Middle cerebral artery.  
 MIAs: multiple intracranial aneurysms.  
 MRI: Magnetic resonant imaging.  
 NHI: national health institute.  
 NICU: neurosurgical intensive care unit.  
 P com A: posterior communicating artery.  
 PHASES: population, hypertension, age, size of aneurysms, SAH in history, and site of the aneurysms.  
 SAH: Subarachnoid hemorrhage.  
 SWI: susceptibility weighted image.

## Disclosure

The authors report no conflict of interest in the materials or methods used in this study or the findings specified in this paper.

## Funding

The authors received no financial support for the research, authorship, and/or publication of this paper.

## Acknowledgement

Special thanks to the whole medical staff and our kind patients.

## REFERENCES

1. Berg P, Saalfeld S, Voß S, et al. Does the DSA reconstruction kernel affect hemodynamic predictions in intracranial aneurysms? An analysis of geometry and blood flow variations. *J Neurointerv Surg.* 2018;10(3):290-296.
2. Carty G, Chatpun S, Espino D. Modeling blood flow through intracranial aneurysms. A comparison of newtonian and non-newtonian viscosity. *J Med Biol Eng.* 2016;36(3):396-409.
3. Cebral J, Mut F, Weir J, Putman C. Quantitative characterization of the hemodynamic environment in ruptured and unruptured brain aneurysms. *AJNR Am J Neuroradiol.* 2011;32(1):145-151.
4. Zolnourian A, Borg N, Akhigbe T, Machdonald J, Bulters D. Vessel wall imaging after subarachnoid hemorrhage in patients with multiple intracranial aneurysms: A cautionary case. *World Neurosurg.* 2019;127:414-417.
5. Chnafa C, Brina O, Pereira V, Steinman D. Better than nothing: A rational approach for minimizing the impact of outflow strategy on cerebrovascular simulations. *AJNR Am J Neuroradiol.* 2018;39(2):337-343.
6. Doddasomayajula R, Chung B, Hamzei-Sichani F, Putman C. Differences in hemodynamics and rupture rate of aneurysms at the bifurcation of the basilar and internal carotid arteries. *AJNR Am J Neuroradiol.* 2017;38(3):570-576.
7. Frolov S, Sindeev S, Liepsch D, et al. Newtonian and non-Newtonian blood flow at a 90°-bifurcation of the cerebral artery. A comparative study of fluid viscosity models. *J Mech Med Biol.* 2018;18(05):1850043.
8. Detmer F, Chung B, Mut F, et al. Development of a statistical model for discrimination of rupture status in posterior communicating artery aneurysms. *Acta Neurochir.* 2018;160(8):1643-1652.
9. Detmer FJ, Chung BJ, Mut F, et al. Development and internal validation of an aneurysm rupture probability model based on patient characteristics and aneurysm location, morphology, and hemodynamics. *Int J Comput Assist Radiol Surg.* 2018;13(11):1767-1779.
10. Hu P, Yang Q, Wang D-D, Guan S-C, Zhang H-Q. Wall enhancement on high-resolution magnetic resonance imaging may predict an unsteady state of an intracranial saccular aneurysm. *Neuroradiology.* 2016;58(10):979-985.
11. Berg P, Beuing O. Multiple intracranial aneurysms: A direct hemodynamic comparison between ruptured and unruptured vessel malformations. *Int J Comput Assist Radiol Surg.* 2018;13(1):83-93.
12. Chalouhi N, Ali M, Jabbour P, et al. Biology of intracranial aneurysms: Role of inflammation. *J Cereb Blood Flow Metab.* 2012;32(9):1659-1676.
13. Guresir E, Vatter H, Schuss P, et al. Natural history of small unruptured anterior circulation aneurysms: A prospective cohort study. *Stroke.* 2013;44(11):3027-3031.
14. Mandell D, Mossa-Basha M, Qiao Y, et al. Intracranial vessel wall MRI: Principles and expert consensus recommendations of the American Society of Neuroradiology. *AJNR Am J Neuroradiol.* 2017;38(2):218-229.

15. Soize S, Gawlitza M, Raoult H, Pierot L. Imaging follow up of intracranial aneurysms treated by endovascular means: Why, When, and How? *Stroke*. 2016;47(5):1407-1412.
16. Orning J, Shakur S, Alaraj A, et al. Accuracy in identifying the source of subarachnoid hemorrhage in the setting of multiple intracranial aneurysms. *Neurosurgery*. 2018;83(1):62-68.
17. Hadjiathanasiou A, Schuss P, Brandecker S, et al. Multiple aneurysms in subarachnoid hemorrhage - identification of the ruptured aneurysm, when the bleeding pattern is not self-explanatory - development of a novel prediction score. *BMC Neurology*. 2020;20:70.
18. Neyazi B, Sandalcioglu E, Maslehaty H. Evaluation of the risk of rupture of intracranial aneurysms in patients with aneurysmal subarachnoid hemorrhage according to the PHASES score. *Neurosurg Rev*. 2019;42(2):489-492.
19. Rajabzadeh-Oghaz H, Wang J, Varble N, et al. Novel models for identification of the ruptured aneurysm in patients with subarachnoid hemorrhage with multiple aneurysms. *AJNR Am J Neuroradiol*. 2019;40(11):1939-1946.
20. Berg P, Voß S, Janiga G, et al. Multiple Aneurysms AnaTomy CHallenge 2018 (MATCH)—phase II: Rupture risk assessment. *Int J Comput Assist Radiol Surg*. 2019;14(10):1795-1804.
21. Ishibashi T, Murayama Y, Urashima M, et al. Unruptured intracranial aneurysms: Incidence of rupture and risk factors. *Stroke*. 2009;40(1):313-316.
22. Juvela S. Risk factors for multiple intracranial aneurysms. *Stroke*. 2000;31(2):392-397.
23. Nehls DG, Flom RA, Carter LP, Spetzler RF. Multiple intracranial aneurysms: Determining the site of rupture. *J Neurosurg*. 1985;63(3):342-348.
24. Backes D, Vergouwen MD, Velthuis BK, et al. Difference in aneurysm characteristics between ruptured and unruptured aneurysms in patients with multiple intracranial aneurysms. *Stroke*. 2014;45(5):1299-1303.
25. Maslehaty H, Capone C, Frantsev R, et al. Predictive anatomical factors for rupture in middle cerebral artery mirror bifurcation aneurysms. *J Neurosurg*. 2018;128(6):1799-1807.
26. Mirams G, Pathmanathan P, Gray R, Challenor P, Clayton R. Uncertainty and variability in computational and mathematical models of cardiac physiology. *J Physiol*. 2016;594(23):6833-6847.
27. Roethlisberger M, Achermann R, Bawarjan S, et al. Predictors of occurrence and anatomic distribution of multiple aneurysms in patients with aneurysmal subarachnoid hemorrhage. *World Neurosurg*. 2018;111:e199-e205.
28. Sano T, Ishida F, Tsuji M, Furukawa K, Shimosaka S, Suzuki H. Hemodynamic differences between ruptured and unruptured cerebral aneurysms simultaneously existing in the same location: 2 case reports and proposal of a novel parameter oscillatory velocity index. *World Neurosurg*. 2016;98:868:e5-e10.
29. Juvela S, Poussa K, Lehto H, Porras M. Natural history of unruptured intracranial aneurysms: A long-term follow-up study. *Stroke*. 2013;44(9):2414-2421.
30. Roloff C, Stucht D, Beuing O, Berg P. Comparison of intracranial aneurysm flow quantification techniques: Standard PIV vs stereoscopic PIV vs tomographic PIV vs phase-contrast MRI vs CFD. *J Neurointerv Surg*. 2019;11(3):275-282.
31. Siddiq F, Chaudhry S, Tummala R, Suri M, Qureshi A. Factors and outcomes associated with early and delayed aneurysm treatment in subarachnoid hemorrhage patients in the United States. *Neurosurgery*. 2012;71(3):670-677.
32. Paliwal N, Damiano R, Varble N, et al. Methodology for computational fluid dynamic validation for medical use: Application to intracranial aneurysm. *J Biomech Eng*. 2017;139(12):1210041-12100410.
33. Schiavazzi D, Arbia G, Baker C, et al. Uncertainty quantification in virtual surgery hemodynamics predictions for single ventricle palliation. *Int J Numer Method Biomed Eng*. 2016;32(3): e02737.