

Classification of Spinal Lipomas Based on Embryonic stage: Overview and Case Series

Tariq Elemam Awad¹, Hesham Habba²

¹Department of Neurosurgery, Faculty of Medicine, Suez Canal University, Ismailia, EGYPT

²Department of Neurological Surgery, School of Medicine, Suez Canal University Hospital, EGYPT

Received: 9 April 2021 / Accepted: 26 May 2021 / Published online: 29 June 2021

BACKGROUND: Unsuccessful primary neurulation is usually considered to be the main origin of spinal lipomatous malformations. Yet, we are not able to clarify many of its characteristics using this hypothesis. A new system of spinal lipomatous malformations categorization based on embryological development observed in the course of the first and second stages of neurulation process may be more realistic.

OBJECT: The aim of this study was to introduce our experience in the surgical treatment of spinal lipoma correlated with the most recent classification by Morota.

METHODS: This study is a retrospective clinical study of 39 cases of spinal lipoma who have been subjected to surgery from August 2007 to May 2019 in neurosurgery department in our institution. The authors classified them to four categories depending on neural tube evolution in the course of embryological growth. Category one is characterized by failing in the first stage of neurulation process; category two includes failing between the first and second stages of neurulation process; category three is characterized as failing in the beginning of the second stage of neurulation process; and category four is characterized as failing in the end of the second stage of neurulation process. We will evaluate the application of this new categorization system.

RESULTS: Twenty-one cases of category one, ten cases of category two, six cases of category three and two cases of category four were included in the study. Filar spinal lipomatous malformations were included in category four. Concomitant anomalous disorders were detected only for categorizes 2–4 lipomatous malformations involving failing in the second stage of neurulation process. Only cases with category one lipomatous malformations underwent complete excision.

CONCLUSION: Conus medullaris and filum terminale are usually affected in spinal lipomatous malformations and they are the products of the second stage of neurulation process. Evolution of spinal lipomatous malformations looks as an ongoing mechanism involving the first and the second stages of neurulation in some cases. Total excision was feasible for category one only.

KEYWORDS: Primary neurulation, spinal lipoma, surgical treatment.

INTRODUCTION

Occult spinal dysraphism is a broad category of neural tube defects. The vast majority of them are covered by skin.¹ Spinal lipoma is one of the most prevalent shapes of occult spinal dysraphism mostly present in infants. The term "lipomyelomeningocele" (LMM) incorporates all sorts of congenital spinal lipomatous abnormalities.^{2,3} Development of spinal lipoma is defined by immature detachment between the neural and cutaneous ectoderm in the time of the first stage of neurulation.⁴ Unsuccessful first stage of the neurulation process leads to the development of spinal lipoma which permits encroachment of mesenchymal cells of mesodermic basis to the neural tissue. In spite of the fact that failed primary neurulation is regarded the essential cause of spinal lipomas, there is no general agreement over its embryonic origin.⁵

Failed secondary neurulation is generally thought to be the origin of closed spinal congenital abnormalities.⁵

Spinal lipomatous malformation in the filum terminale, which is the end result of the second stage of neurulation process, backs this theory. Introduction of magnetic resonance imaging (MRI) facilitated diagnosis of caudally based lipomatous malformations, without spina bifida and without infiltration of the dura mater or fascia posteriorly.⁶

Most classifications of spinal lipoma have depended on the position of lipoma in relation to the spinal cord. Chapman system of spinal lipomatous malformations categorization has relied on surgical knowledge before the existence of MRI and it classified spinal lipomas into 3 groups; dorsal, caudal, and transitional.⁷ Filar lipoma and the lipomyelomeningocele were included in this system by Arai et al. after introduction of MRI.⁸ Later, spinal lipoma was categorized into 3 groups by McLone and Thompson; those without dural perforation, those of the conus medullaris, and those of the filum terminale.⁹

Pang et al. introduced the first classification of spinal lipoma relying on embryological features. He classified spinal lipoma into 4 types; the first two types are dorsal

Correspondence:

Dr. Hesham Habba

Email: heshamhabba@gmail.com

and transitional which evolves in the first stage of neurulation process and the other two types are terminal lipoma which arise during secondary neurulation and chaotic lipoma which happen between primary and secondary neurulation.^{10,11} In 2017, Morota et al. proposed the most current classification based on embryogenic origin. Spinal lipomas were classified into 4 types.¹²

Type 1: Primary neurulation failure complete.

Type 2: Failing between the first and second stages of neurulation process.

Type 3: Failing in the beginning of the second stage of neurulation process.

Type 4: Failing in the end of the second stage of neurulation process.

The aim of operative intervention for spinal lipoma is to remove fatty tissue, identify defect in the lumbosacral fascia, possible release of the filum terminale, avoid neural tissue injury, and prevent spinal cord retethering.¹³

The aim of this article is to introduce our practice in the operative management of spinal lipomas correlated with the most recent classification by Morota et al.¹²

METHODS

Files of cases of spinal lipoma who were subjected to operative management at our department between 2007 and 2019 were retrospectively analyzed. A sum of 64 cases was detected. Patients with incomplete data, radiological studies or regular follow-ups were eliminated. A sum of 39 cases with spinal lipoma and complete medical records were included. They underwent surgeries between August 2007 and May 2019 at neurosurgical department in our institution. There were 15 males and 24 females. Range of age was from one month to 7 years with an average of 1.7 ± 1.2 years.

The identification and designation of spinal lipoma were based on T1 and T2-weighted MRI. Axial MRI images provided data for excision of spinal lipomatous malformations but did not provide data for their categorization. Spinal lipomatous malformations were organized according to the traditional scheme of Arai et al.⁸ and the recent system of Morota et al.¹²

The purpose of surgery was to perform complete resection when possible and the indication of surgery was as prophylactic surgery.

Preoperative Evaluation

The preoperative evaluation included general and neurological evaluation. General evaluation included searching for associated congenital anomalies, while neurological evaluation was done by watching for spontaneous movement of the lower limbs and assessment of the lowest level of neurologic function by checking response of lower limbs to painful stimulus. In order to evaluate outcome of management, cases were classified before and after surgical intervention based on

the functional classification by Hoffman et al.¹⁴ (Table 1).

Surgical Technique

Surgery was performed in prone position under general anesthesia with all the pressure points well padded. A linear skin incision was performed at the most bulging part of lipomatous lump. Dissection was done around the middle part of lipomatous part using scissors and bipolar cautery until the lumbosacral fascia was reached. Laminotomy was done. Dura was incised starting from the location of defect cranially and caudally and the intradural compartment of lipoma was excised. Untethering of the cord was done. Reconstruction of the spinal cord with suturing of the pial margins, if feasible, was performed. Dura was sutured primarily without the use of artificial dural patch in most cases then lumbosacral fascia was sutured followed by adequate closure of the wound in layers to close the dead space. Neutral drain was used in all cases.

Operative Data

In all cases, operative time, blood loss, and the duration of inpatient admission were documented. Preoperative and postoperative complications were recorded.

Clinical Follow Up

Cases were followed up at intervals of 1, 3, 6, 9 months and one year after surgery and then each 6 months. The following data were collected: wound status, neurological deficit, spine deformity, sphincters control and motor developmental milestones.

Ethical approval: We have no institutional review board (IRB) in our institution and the authors had been stick to the declaration of Helsinki.

RESULTS

A sum of 39 cases was subjected to operative intervention. There were 15 males and 24 females. Range of age was from one month to 7 years with an average of 1.7 ± 1.2 years. Cases were followed in the outpatient clinic of neurosurgery department, Suez Canal University hospital. The average follow up time was 48 ± 16 months.

Clinical Picture

All 39 cases had one or more skin manifestations (Table 2). Preoperatively, 20 of the 39 cases did not have neurological deficit, the other 19 patients had diverse neurological manifestations such as reflexes and sensation disturbances, motor deficit and sphincter affection. Postoperatively, the 19 patients with grades 1-3 showed improvement of at least one grade (Table 1).

Neuro-imaging Findings

The MRI showed low lying conus medullaris in all cases. Moreover, depending on the findings of MRI, all spinal lipomatous malformations can be classified to five classes: (1) Dorsal type lipoma (17 cases) (Figs. 1,2) (2) Transitional type lipoma (8 cases) (3) Lipomyelomeningocele (8 cases) (Fig. 3) (4) Caudal

lipoma (4 cases) (5) Filum Lipoma (2 cases). A syrinx in the caudal part of the spinal cord was found in 5 of the 39 cases; 2 were wide and 3 were narrow (Fig. 2).

The patients were classified according to Arai classification (Table 3) and Morota classification (Tables 3,4). Filar spinal lipomatous malformations

were categorized as type 4. Concomitant abnormalities were detected only for types 2–4 spinal lipomatous malformations (10 patients) (Table 4). These concomitant abnormalities included massive filum terminale in 5 patients, Chiari abnormality in 1 case, and dilated ventricles in 1 case.

Table 1: Pre-and postoperative functional grading scheme by Hoffman

Grade	Description	Preoperative	Postoperative
Grade 0	No significant neurological, orthopedic, or urological problems. The patients may have reflex changes and/or sensory deficits.	20	23
Grade 1	Minimal weakness and/or muscle waste and/or foot deformity affecting only one leg without significant gait disturbance. Normal bladder and sphincter function.	11	12
Grade 2	Neurogenic bladder alone or combined with minimal weakness of one leg; or intact bladder function with minimal weakness affecting both legs.	7	4
Grade 3	Moderate to severe weakness of one leg producing gait disturbance with or without neurogenic bladder or minimal weakness of both legs combined with neurogenic bladder.	1	0
Grade 4	Severe paraparesis requiring aids for walking, with or without neurogenic bladder.	-	-
Grade 5	Inability to walk.	-	-

Table 2: Dermal stigmata in the study group

Dermal stigmata	No
Subcutaneous lipoma	32
Sacral or coccygeal skin dimple	8
Dermal sinus	5
Altered colored skin patch, haemangioma	13
Tuft of hair, hairy nevus	5
Tail-like appendage	4
scar-like white skin patch	5

Table 3: Types of spinal lipomas according to Arai's classification













Arai's classification					
Characteristic	Dorsal lipoma	Transitional Lipoma	Lipomyelomeningocele	Caudal Lipoma	Filum Lipoma
No. of cases	17	8	8	4	2
Morota Classification					
Type 1	17	4	-	-	-
Type 2	-	4	6	-	-
Type 3	-	-	2	4	-
Type 4	-	-	-	-	2

Table 4: Classification of spinal lipomas and associated anomalies

Characteristic	Spinal lipoma type							
								12
	Type 1. Failed primary neurulation.		Type 2. Failed neurulation between the primary and secondary stages including junctional neurulation.		Type 3. Failed early phase of secondary neurulation.		Type 4. Failure in the late phase of secondary neurulation	
No. of cases	21		10		6		2	
Age at surgery	12 months		11 months		2 years		3 years	
Median	4-24		5-27		1-5 years		3-7 years	
range								
Associated anomalies								
Anorectal\sacral anomalies	-	3	2	1				
Urogenital anomalies	-	-	1	-				
Anomaly Syndromes	-	1	1	1				

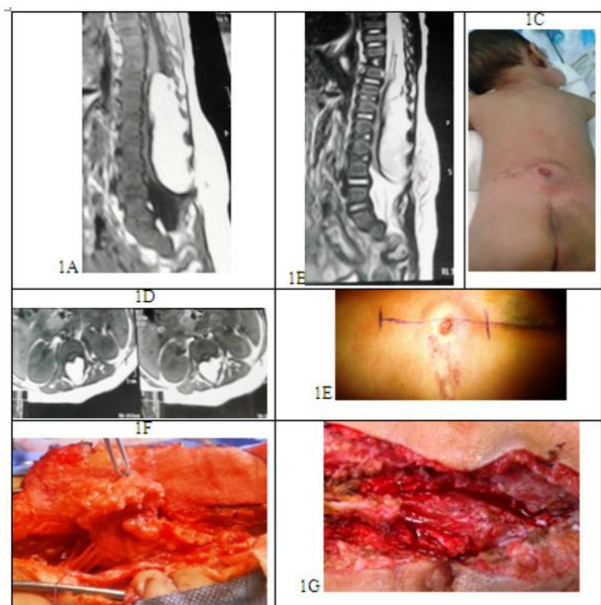


Fig 1: A 7 months old girl, having a spinal lipomatous malformation. A, B: MRI sagittal T1- & T2-weighted images showing the lipomatous malformation expanding the caudal aspect of the dural sac and is attached to the subcutaneous fat via spina bifida. C: Photo showing back of the child, a hump could be seen due to the presence of the lipoma. D: Axial MRI showing the conus medullaris covered by the dorsal-dorsolateral expanded lipomatous malformations. The lipomatous malformation looks to be transitional type. E: Photo demonstrating the presence of skin dimple in addition to the hump seen in back of the

child. F: Intraoperative photo showing caudal part of the lipomatous malformations reflected to dissect the cauda equina till visualization of the conus medullaris tip. G: Intraoperative photo demonstrating the operative field after excision of the lipomatous malformation, myeloplasty and after suturing of the dura.

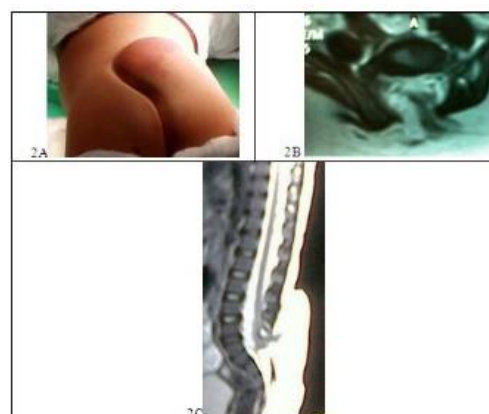


Fig 2: A case of type 1 spinal lipoma. A, photo of back of the child showing the lipomatous malformation. B, C: MRI axial and sagittal images showing a spinal lipomatous malformation constricting the spinal cord anteriorly with relatively smooth borders; an associated congenital dermal sinus could be also noted. Sagittal image shows a flattened spinal cord with smooth borders; the conus medullaris is located caudal to the spinal lipomatous malformation.

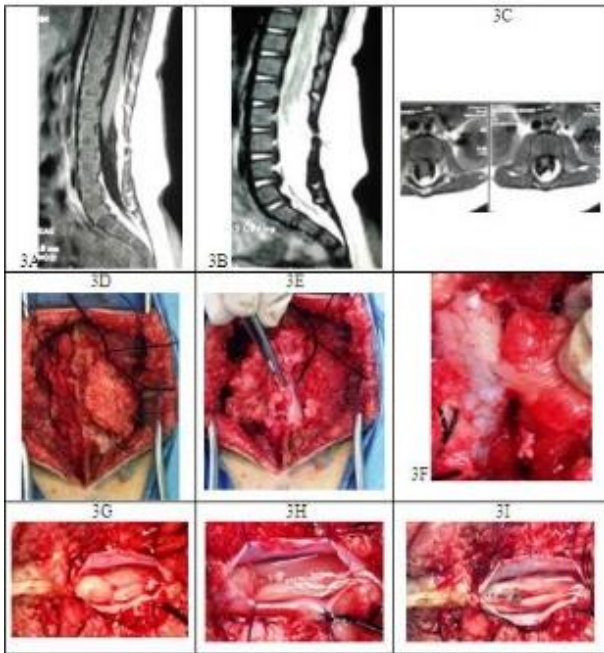


Fig 3: A 9-month-old female patient with type two spinal lipomatous malformation, has a lumbosacral subcutaneous lipoma. A-C: sagittal and axial MRI images showing caudal end of the spinal cord wide and disorganized without conus medullaris formation, with neural tissue extrusion from the spinal canal. The spinal cord is blended with subcutaneous lipoma. D-I: show steps of surgical repair.

Surgical treatment

Average operative time was 120 min and average blood loss was 70 cc. Complete excision was possible only for category 1 spinal lipomatous malformations. No considerable operative complications occurred.

Subcutaneous cerebrospinal fluid (CSF) accumulation was detected in 10 cases (25%) after surgery. Three cases needed another operative intervention to close the defect. One case was complicated by meningitis, which was managed by intravenous antibiotics with successful result. A temporary reduction in anal tone was detected in 2 patients postoperatively.

DISCUSSION

Spinal lipomas, also known as congenital spinal lipomatous malformations consist of fatty lesions conjoined with the spinal cord, either without invasion of the dura (filar lipomatous malformations, caudal lipomatous malformations without invasion of the dura, and intramedullary lipomatous malformations) or with invasion of the dura (dorsal lipomatous malformations, caudal lipomatous malformations with invasion of the dura, transitional lipomatous malformations, lipomyelocele, and lipomyelomeningocele). Their accurate prevalence is unknown due to their occult nature. The percentage of recognized cases has been estimated to be 1 per 4000 births, which constitutes 25% of all open dysraphic anomalies.^{12,14}

Lipomas without dural defect could be defined as follows: Filum lipoma with fatty involvement of the terminal filum, caudal lipoma with intact dura including fusiform-like lipomas adherent to the spinal cord posteriorly with nerve roots not passing across the lipoma, and intramedullary lipoma with fatty involvement of the cord parenchyma without infiltration of pia mater.⁷

Lipomas with dural defect could be defined as follows: Dorsal lipoma spreading to the thecal sac by dural infiltration and adhering to the spinal cord dorsally, caudal lipomatous malformation with dural invasion that extends to subcutaneous lipoma with expansion to the caudal dural sac and adheres to the conus medullaris, transitional lipoma that includes extra-theal lipoma infiltrating the dura to adhere to the posterior and caudal surfaces of the conus medullaris, lipomyelocele and lipomyelomeningocele. Lipomyelocele is an extra-spinal cord herniation that ends in a subcutaneous lipoma, while lipomyelomeningocele has extra-spinal cord herniation to form a subcutaneous meningeal sac with a terminal lipomatous lump on it.^{2,4,15}

Categorization of spinal lipomatous malformations has classically relied on its location regarding the spinal cord. Chapman categorized spinal lipomas into 3 classes; dorsal, caudal and transitional based on the relationship of lipoma to the cord and the posterior spinal nerve root.⁷ This classification still remains important despite being dependent on surgical experience before MRI. After introduction of MRI, Arai et al. included the filar lipomatous malformation and the lipomyelomeningocele to this system.⁸ Lipomyelomeningocele is characterized by invasion of a subcutaneous lipomatous malformation across a deficiency in the fascia to the spinal canal. McLone and Thompson classified the spinal lipomatous malformation to those without dural defect (subpial lipomatous malformation), conus medullaris lipomatous malformation, and filar lipomatous malformation.⁹ Conus medullaris lipomatous malformation were categorized to 3 types, with the lipomyelocele as an example of spinal lipomatous malformation developing as a result of unsuccessful first stage of neurulation process.

Pang presented the initial classification depending on embryological origin by adding the dorsal, terminal, and transitional lipomatous malformation types with lipomyelomeningoceles considered part of the latter.¹⁵

The dorsal and transitional categorizes occur in the first stage of neurulation process, while the terminal category occurs in the second stage of neurulation process. Afterwards, he included the chaotic lipomatous malformation and considered its developmental origin to be between the transitional and terminal lipomas.^{16,17}

The most novel classification by Morota et al includes 4 types. The Type 1 spinal lipomatous malformation contains formerly categorized transitional lipomatous

malformation if the conus medullaris is located anteriorly despite compression of the lipomatous malformation, which is present posteriorly and expands caudally. Pang merged the caudal and filum terminale lipomatous malformation with the terminal lipomatous malformation as they are the end results of unsuccessful second stage of neurulation process.¹¹

This novel system categorized terminal lipomatous malformation to multiple types, types three and four, depending on its occurrence either at the beginning or the end of the second stage of neurulation process. Spinal lipomatous malformation developing from the conus medullaris end is considered a type three spinal lipomatous malformation. In type four spinal lipomatous malformation, the normal terminal part of the conus medullaris moves approaching the filum terminale which locates the lipomatous malformation at the caudal end of the filum terminale.

In our series, postoperatively, the 19 patients with grade 1-3 showed improvement at least one grade. (**Table 1**) Our surgical outcomes are reasonably satisfactory when compared to other series.^{12,17}

CONCLUSION

Conus medullaris and filum terminale are usually affected in spinal lipomatous malformations and they are the products of the second stage of neurulation process. Evolution of spinal lipomatous malformations looks as an ongoing mechanism involving the first and the second stage of neurulation in some cases. Total excision was feasible for category one only.

List of abbreviations

CSF: Cerebrospinal fluid

IRB: Institutional review board

LMM: Lipomyelomeningocele

MRI: Magnetic resonance imaging.

Disclosure

The authors report no conflict of interest in the materials or methods used in this study or the findings specified in this paper.

Funding

The authors received no financial support for the research, authorship, and/or publication of this paper.

REFERENCES

1. Finn MA, Walker ML. Spinal lipomas: Clinical spectrum, embryology and treatment. *Neurosurg Focus.* 2007;23(2): E10.

2. Huang SL, Shi W, Zhang LG. Surgical treatment of lipomyelomeningocele in children. *World J Pediatr.* 2010; 6:361-365.
3. Sarris C, Tomei K, Carmel P, Gandhi C. Lipomyelomeningocele: Pathology, treatment and outcomes. *Neurosurg Focus.* 2012;33(4): E3.
4. Pang D. Total resection of complex spinal cord lipomas: How, why, and when to operate? *Neurol Med Chir (Tokyo).* 2015;55(9):695-721.
5. Copp AJ, Greene ND. Neural tube defects—disorders of neurulation and related embryonic processes. *Wiley Interdiscip Rev Dev Biol.* 2013;2(2):213-227.
6. Yoshifuji K, Morota N, Ihara S. Developmental feature of the lumbosacral vertebral arch in childhood. *Shoni No Noshinkei.* 2007;32(6):426-429.
7. Chapman PH. Congenital intraspinal lipomas: Anatomic considerations and surgical treatment. *Childs Brain.* 1982;9(1):37-47.
8. Arai H, Sato K, Okuda O, et al. Surgical experience of 120 patients with lumbosacral lipomas. *Acta Neurochir (Wien).* 2001; 143:857-864.
9. McLone DG, Thompson DNP. Lipomas of the spine. In: McLone DG, ed. *Pediatric Neurosurgery: Surgery of the Developing Nervous System.* 4th ed. Philadelphia: Saunders; 2001: 289-301.
10. Pang D, Zovickian J, Oviedo A. Long-term outcome of total and near-total resection of spinal cord lipomas and radical reconstruction of the neural placode: Part I—surgical technique. *Neurosurgery.* 2009;65(3):511-529.
11. Pang D, Zovickian J, Wong ST, Hou YJ, Moes GS. Surgical treatment of complex spinal cord lipomas. *Childs Nerv Syst.* 2013;29(9):1485-1513.
12. Morota N, Ihara S, Ogiwara H. New classification of spinal lipomas based on embryonic stage. *J Neurosurg Pediatr.* 2017;19(4):428-439.
13. Patil P, Gupta A, Kothari P, et al. Immediate and long-term outcome analysis of lipo-myelo-meningocele repair in asymptomatic infants in a tertiary care center. *J Pediatr Neurosci.* 2016;11(2):99-104.
14. Hoffman HJ, Taecholarn C, Hendrick EB, Humphreys RP. Management of lipomyelomeningoceles. Experience at the Hospital for Sick Children, Toronto. *J Neurosurg.* 1985;62(1):1-8.
15. Pang D. Spinal cord lipomas. In Pang D, ed. *Disorders of the Pediatric Spine.* New York: Raven Press; 1995: 175-201.
16. Pang D, Zovickian J, Moes GS. Retained medullary cord in humans: Late arrest of secondary neurulation. *Neurosurgery.* 2011;68(6):1500-1519.
17. Shimokita E, Takahashi Y. Secondary neurulation: Fate-mapping and gene manipulation of the neural tube in tail bud. *Dev Growth Differ.* 2011;53(3):401-410.