

PROTECTIVE EFFECT OF N-ACETYLCYSTEINE (NAC) AGAINST DI-ETHYLHEXYL PHTHALATE (DEHP) INDUCED PULMONARY TOXICITY IN MALE ALBINO RATS (HISTOLOGICAL AND IMMUNOHISTOCHEMICAL STUDY)

Amina A. Farag^{1*}, Eman M. Faruk², Taghrid G. Kharboush³, Nashwa H. Abu-Raia⁴,
Haidy M. Fakher¹

¹ Department of Forensic Medicine and Clinical Toxicology, Faculty of Medicine, Benha University, Benha 13518, Egypt

²Department of Histology and Cell Biology, Faculty of Medicine, Benha University, Benha, Egypt

³Department of Microbiology and Immunology, Faculty of Medicine, Benha University, Benha, Egypt

⁴Department of Pharmacology, Faculty of Medicine, Benha University, Benha, Egypt

* Corresponding author: Dr. Amina A. Farag, MD

Tel:+201015906446

Email: amina.farag@fmed.bu.edu.eg

Date of submission: 18 May 2020

Revised at: 26 June 2020

Accepted at: 21 September 2020

ABSTRACT

Di-Ethylhexyl phthalate (DEHP) is a global environmental pollutant. Human exposure to DEHP occurs through environmental sources. Community exposure (food, air, water), as well as medical settings' exposure, impose crucial effects on human health. DEHP had been reported to have cytotoxic, immunotoxic, genotoxic, and reproductive toxic properties. This work aims to assess the possible toxic effects of DEHP on adult albino rats' lungs and to evaluate the possible protective effects of N-acetylcysteine (NAC) using bodyweight and relative lung weight parameters. Assessment of DHEP toxicity is measured by biochemical, histopathological, and immunohistochemical methods. Fifty male adult albino rats were divided into five equal groups as follows: Group I (Negative control group), Group II (Positive control group), Group III (NAC-treated group): was given NAC orally (200 mg/kg/day), Group IV (DEHP-treated group): was given DEHP orally (3gm/kg once daily for 4 weeks) and Group V: (DEHP + NAC-treated group): was treated with DEHP concomitantly with NAC at the same previous doses. The results of the present study revealed that DEHP has significantly increased the lipid peroxidation level and significantly reduced glutathione content (GSH), superoxide dismutase (SOD) activity, and catalase activity. The histological results of group IV showed inflammatory cellular infiltration of the lungs associated with interstitial edema, hemorrhage, and inter-alveolar septal thickening that were markedly reduced in group V. Also, group V, showed a significant decrease in the collagen fibers accumulation and caspase-3 expression as compared to group IV. Conclusion: treatment with NAC can protect against DEHP induced pulmonary toxicity in rats by decreasing oxidative stress, inflammation, and apoptosis.

Keywords: Di-Ethylhexyl Phthalate, N-acetylcysteine, lung, lipid peroxidation; glutathione.

INTRODUCTION

Di-Ethylhexyl phthalate (DEHP) is a diester of phthalic acid (PAE) that is used globally, as a plasticizer to improve the flexibility and elasticity of plastics. DEHP is used in several polyvinyl chlorides (PVC) products such as plastic sheets, wire coverings, artificial leather, agricultural vinyl films, adhesive agents, and medical products (JCIA, 2018).

Di-Ethylhexyl phthalate is a viscous, colorless substance that is soluble in lipophilic liquids. It can easily diffuse and accumulate in the environment under high temperatures or through contacting hydrophobic substances. However, little DEHP can be detected in the air because it does not evaporate easily (JCIA, 2018 and Rowdhwai & Chen 2018). Over 470 million pounds of PAE are manufactured annually throughout the world, and they exist in many consumer products such as food packaging materials, construction materials, children's toys, medical equipment, and other products (Muczynski et al., 2012; Bernard et al., 2014).

Di-Ethylhexyl phthalates are bound to the polymer they are associated with by non-covalent bonds. This allows for leaching of these compounds to occur leading to increased risk of environmental pollution and eventually adverse effects on human health (Junaid et al., 2018). In living organisms, DEHP is metabolized to mono-Ethylhexyl phthalate (MEHP), by glucuronidation as well as by the lipases' action. MEHP can be further degraded to phthalic acid and other metabolites and it represents around 12 % of DEHP metabolism that is recognized as the key metabolite (Ticker et al., 2001).

Different ways of human exposure to DEHP are reported such as inhalation, oral ingestion, and dermal exposure. Orally ingested DEHP is mainly absorbed through the intestinal mucosa into the blood and consequently, it can reach the lungs (Engel and Wolff, 2013).

Di-Ethylhexyl phthalate or its metabolites have been demonstrated to induce various negative health effects in the liver, genital tract, kidneys, lungs, and heart. DEHP appears to produce a relatively low risk of cancer liver in humans. So, the possibility of developing DEHP related malignancies in humans cannot be excluded (Ticker et al., 2001).

An estimation of the exposure dose of DEHP that is taken by inhalation is about 2.5 mg/kg/day for newborns and children. As regards to the adults, the estimated dose is about 0.14- 9.5 mg/kg/day (Sathyanarayana, 2008).

Many epidemiological studies have discussed the association between phthalates exposure and respiratory symptoms in both residential and occupational environments (Hoppin et al., 2013). Researches have discussed the possible relationship and mechanisms of respiratory diseases such as asthma and allergy among plastic industry workers and the children exposed to phthalates and PVC (Jaakkola and Knight, 2008).

The parent compound (DEHP) and its metabolites induce hazardous effects in the airways of neonatal rats, particularly in the alveoli. Multiple effects have been noted such as alveolar simplification where the alveoli become larger but fewer in numbers with decreased septation, impaired alveolarization process, and a decrease in the levels of the surfactant protein. Such effects suggest that the lung and the alveolar

epithelium could be target sites for phthalate toxicity (**Rosicarelli and Stefanini, 2009**).

Superoxide dismutase (SOD), catalase (CAT), and glutathione-dependent enzymes (GSH) represent an antioxidant defense system that can control the reactive oxygen species (ROS) levels in the tissues (**Eren et al., 2007; Arikan et al., 2010**). One of the lung principal enzymes responsible for catalyzing the dismutation of O₂ to H₂O₂ is SOD. H₂O₂ is further broken down by either the GSH redox cycle or by CAT enzymes (**Beers, 2008**).

An imbalance between the production and degradation of ROS in tissues leads to oxidative stress phenomena. These ROS-induced tissue injuries are characterized by oxidative damage of the DNA, lipids, and proteins. Malondialdehyde (MDA) is known to be an indicator of oxidative stress as it is produced during tissues' lipid peroxidation (**Laskin et al., 2010**).

Studies done on aquatic organisms have shown that exposure to DEHP results in lipid peroxidation as well as to changes in the activities of the enzymatic antioxidant (**Yuan et al., 2017**).

N-Acetylcysteine (NAC) is characterized by being an inexpensive and commonly used drug. It is the precursor of the amino acid L-cysteine (**Mokhtari et al., 2016**). NAC metabolites are good sources of sulfhydryl groups which stimulate GSH production to enhance detoxification and to directly act as a scavenger of the free radicals (**Saha et al., 2013**). It has a powerful antioxidant activity and it is one of the suggested alternatives for treating diseases associated with the generation of ROS (**Shahin et al., 2009**).

In light of the above-mentioned background, this work aims to assess the toxic effects of DEHP on adult albino rat's lung and the possible protective effect of NAC against its toxicity (biochemical, histological, and immunohistochemical study).

MATERIAL AND METHODS

A- Chemicals:

Di-Ethylhexyl phthalate (DEHP) is provided in a liquid state of purity $\pm 99\%$ (The CAS number 117-81-7), Corn oil is also a liquid of purity $\pm 99\%$ (The CAS number 8001-30-7), and N-acetylcysteine (NAC) as a powder (CAS number 616-91-1) were obtained from Sigma-Aldrich (USA). The assay kits used for biochemical measurements of lipid peroxidation and antioxidants markers in the lung tissue were purchased from BioDiagnostics Company (Dokki, Giza, Egypt) (CAS number 324-24-2). Whereas, the assay kit used for protein estimation in the supernatants was obtained from Thermo Scientific (Rockford, Illinois, USA).

B- Experimental design and animal grouping:

Fifty adult male Wistar albino rats, weighing between 180-200g and their age ranges between 90-120 days old at the beginning of the experiment were included in this study. Rats were purchased from the animal house at the Faculty of Veterinary Medicine, Benha University (Egypt). Rats were allowed for adaptation (1 week before the experiment) at the Anatomy Department, Faculty of Medicine, Benha University, to ascertain their physical wellbeing, and to exclude any diseased animal. The rats were

housed in separate fairly ventilated cages (5-rat per cage). All rats were receiving the same diet (wheat, bread & milk) with tap water ad libitum, and were housed under standard conditions of temperature ($25 \pm 2^\circ\text{C}$), humidity ($50 \pm 5\%$), and 12-hour dark/light cycles. The time of the DEHP administration was fixed for all the animals (12:00 PM). The study design was accepted by the Committee of Animal Research Ethics of the Faculty of Medicine, Benha University, Egypt.

Rats were randomly divided into five groups (10 rats /each group) as follows:

Group (I) negative control group:

This group is left without intervention to measure the basic parameters, with free access to food and water for 4 weeks.

Group (II) positive control (corn oil-treated) group:

Each rat received 1 ml/ day of corn oil by oral gavage for 4 weeks according to **Takai et al. (2009)**.

Group (III) NAC treated group:

NAC was dissolved in distilled water and the rats received NAC in a daily oral dose of 200 mg/kg bodyweight for 4 weeks (**Maheswari et al., 2014**).

Group (IV) DEHP treated group:

DEHP was dissolved in corn oil and given to the rats by oral gavage at a dose of 3gm/kg once daily for 4 weeks according to **Takai et al. (2009)**.

Group (V) DEHP + NAC treated group:

Rats received combined treatment of both DEHP and NAC at the same previously mentioned doses and route of administration for 4 weeks.

Before each administration, both drugs were freshly prepared by dissolving DEHP in corn oil (used in many types of research as a delivery vehicle for fat-soluble compounds including toxins) and NAC in distilled water to acquire the prerequisite drug level in one ml solution. All Animals were kept fasting for 4 hours, weighed before gavage, and received their respective substance dosage once daily for 4 consecutive weeks. The doses were calculated according to animals' daily weights.

Lungs sampling:

Twenty-four hours after the last dose of each drug is given for each group and under ether inhalation anesthesia animals' weight was taken and they were subjected to thoracotomy incision to collect their lungs and then all the animals were sacrificed by cervical dislocation. The right lungs were perfused gently with 10 ml of 0.9% saline to remove the blood, and then they were cut into pieces and put in Eppendorf tubes for biochemical analyses. The Eppendorf tubes were stored in the deep freezer at -80°C . The left lungs were fixed in 10% formalin for histopathological and immunohistochemically studies (**Morton and Snider, 2017**).

C) Biochemical analysis

Biochemical analysis was done to test for the lipid peroxidation marker (MDA) and the antioxidants (GSH, CAT, and SOD) in the lung tissues.

Mortar and pestle were used to homogenize 100 mg of the rats' lung tissues in 2 mL of an ice-cold buffer (50 mmol/L potassium KPO₄, pH 7.5, 1 mmol/L EDTA). Then, centrifugation of the homogenized lung tissue was done at 4°C for 15 min. The supernatant was stored at -20°C until being analyzed for oxidant/antioxidant

markers of oxidative stress. The supernatant concentrations of (MDA), reduced glutathione (GSH), (SOD) (Nemmar et al., 2013), and (CAT) activity (Nabavi et al., 2012; Nemmar et al., 2015) were evaluated using colorimetric assays according to the details given in each kit's instructions.

D) Western Blot Analysis

Western blotting was used to measure protein expressions for cleaved caspase-3 in the lung tissues. Lung tissue was first frozen with liquid nitrogen at -80°C . Then the lung tissue was washed with salt. This step is followed by homogenization of the lung tissues by using a lysis buffer (pH 7.4) that contains (300mM) KCl, (140mM) NaCl, (10mM) trizma base, (1mM) EDTA, sodium deoxycholate 0.5 g/100ml distilled water, protease, Triton X-1000.5/100ml distilled water and phosphatase inhibitor. Then lung homogenate was centrifuged at 4°C for 15min. The supernatants were collected and the Pierce bicinchoninic acid protein assay kit was used for protein estimation. The cleaved caspase-3 level was estimated by using a sample of (80 μg) protein that was separated by 12% sodium dodecyl sulfate-polyacrylamide gel electrophoresis. Then it was probed with the rabbit monoclonal cleaved caspase-3 antibody (1:250 dilutions, Cell Signaling Technology) at 4°C overnight (Koch et al., 2015).

E) Histological study

Neutral buffered formalin (10%) was used to fix the left lung lobes, and then they were sliced into transverse sections that were embedded in paraffin. For light microscopic evaluation, the tissue specimens were prepared as 5- μm -thick sections and stained with hematoxylin and eosin (H&E). The following factors were assessed (pneumocyte hyperplasia, alveolar septa

Thickening and inflammatory cells infiltration) by using the semi-quantitative method.

A graded scale of 0- 4 was used to measure the level of damage. According to the scale, grade 0 = no damage, grade 1 = very low level of damage, grade 2 = mild damage, grade 3 = moderate damage and grade 4 = severe damage. Sirius Red stain was also done for observation of the collagen fibers (Bancroft and Layton, 2013).

F) Immunohistochemical method for detection of caspase-3:

The immunohistochemical assay of caspase-3 protein (anti-apoptotic factor) was done for sections of 4 μm thickness (Ummanni et al., 2010). Polyclonal rabbit antibodies were used to detect caspase-3 by using the avidin-biotin-peroxidase system. The kit was purchased from sigma laboratories (Novacastra` laboratories Ltd., UK) (CAS number AB2302).

The kit contains (6 ml) normal rabbit serum-like protein blocking reagent, (0.3 ml) avidin, (5 ml) of Poly L- lysine solution as a tissue adhesive,(0.3 ml) biotinylated rabbit anti-mouse secondary antibody, and (2 ml) hydrogen peroxide (H_2O_2) with(15) foil-wrapped diaminobenzidine (DAB).

To ensure good adhesion, paraffin sections were mounted overnight on the glass slides and incubated at 65°C . Sections in xylene were deparaffinated, then rehydrated in low alcohol levels, and subsequently immersed in 3% H_2O_2 in methanol for 10 minutes to block the endogenous peroxidase activity. This was followed by washing with phosphate buffer saline (PBS).

To reduce non-specific binding, normal serum (10 %) was added for 30 minutes. Then, overnight application of the primary antibodies was followed by washing with

PBS. Sections were coated for 30 minutes with biotinylated secondary anti-mouse antibody and washed in PBS afterward. For 30 minutes, Avidin-biotin reagent was applied then washed with PBS. DAB was mixed for 5 min, as a chromogen and washed with distilled water followed by Mayer's Hematoxylin as a counterstain. Human tonsil (obtained from the pathology department in our institution) served as a positive control according to the Manufacturer Company. Hematoxylin is used as a counterstain (Zhao et al., 2015). The same steps are done to prepare the negative control slides, except that the antibody diluent was incubated instead of the primary antibody. A positive reaction for caspase-3 is demonstrated in the form of brown nuclear staining (Xia and Xue, 2012).

G) Morphometric study:

It was done by using a computer system (image analyzer) available at the morphometric unit in the Histology Department, Faculty of Medicine, Cairo University. Image-Pro Plus program (version 6.0; Media Cybernetics Inc., Bethesda, Maryland, USA). Ten high-power fields (400X) were measured from sections of all the groups and their mean was taken. Statistical analysis was performed using Windows IBM SPSS statistics software (version 20; IBM Corp., Armonk, New York, USA). It determines the following (a- Area percentage of the stained collagen fibers per high power field. b- Area percentage for the distribution of the immune histochemical stains for caspase) (Weibel et al., 2007).

H) Statistical analysis:

The provided data were analyzed by using the SPSS software version 20 (SPSS Inc, Chicago, ILL Company). Continuous

data were analyzed for normality by using the Shapiro-Wilks test, assuming normality at $P > 0.05$. To test the differences between groups, the ANOVA test was used (F test) for normally distributed variables or the Kruskal Wallis test for nonparametric ones. Significant ANOVA or Kruskal was followed by post hoc multiple comparisons using Bonferroni tests to determine the significant pairs. Data were illustrated as bar charts with standard error bars on the excel sheet. $P \leq 0.05$ was considered significant (Souza et al., 2006).

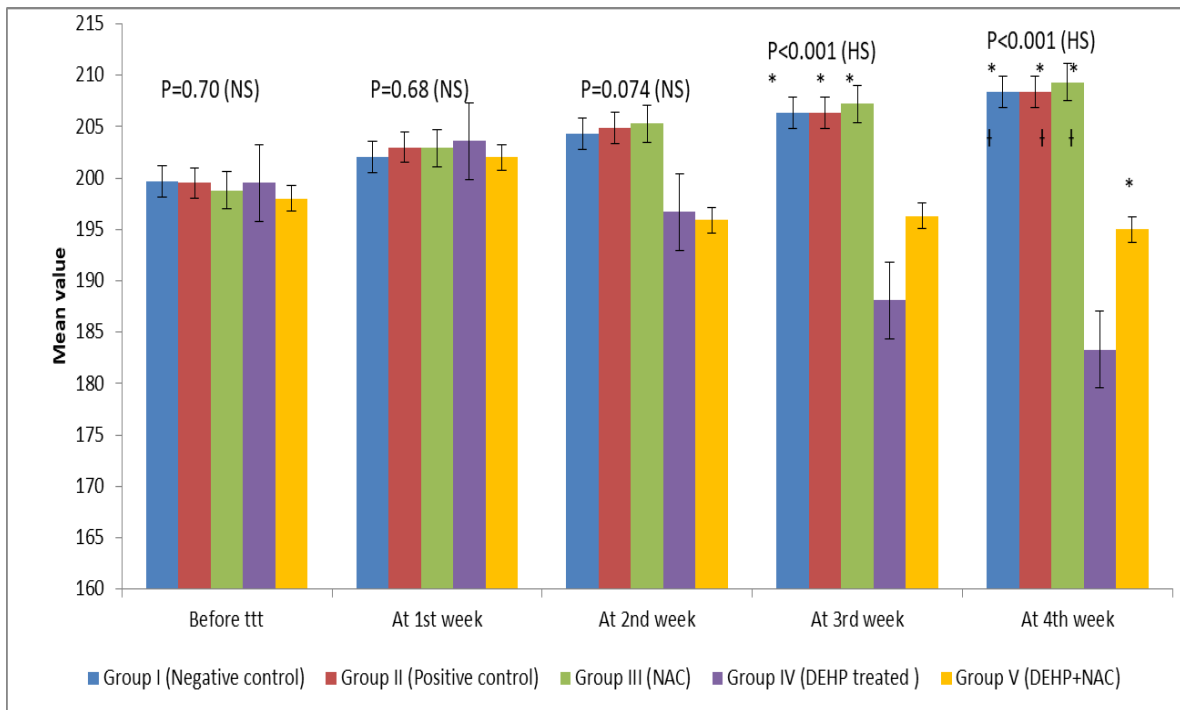
RESULTS

A-Weight of the body and lung organ:

This study revealed a non-significant ($p > 0.05$) difference between all rat groups as regard to their body weight in comparison to the control groups and the NAC-treated group before treatment [df (4, 45), F ratio=0.55] and after the 1st [df (4, 45), F ratio=0.57] and the 2nd weeks of treatment, but a highly significant ($p < 0.001$) decrease in the mean values of the bodyweight of DEHP-treated group was detected after the 3rd and the 4th weeks of treatment and also a highly significant ($p < 0.001$) decrease in the mean values of body weight of DEHP-treated group was detected in comparison to DEHP + NAC treated group after the 4th weeks of treatment. Also, DEHP+ NAC treated group showed a highly significant ($p < 0.001$) decrease in the mean values of the body weight in comparison to the control groups after the 4th week of treatment as illustrated in **fig. 1**.

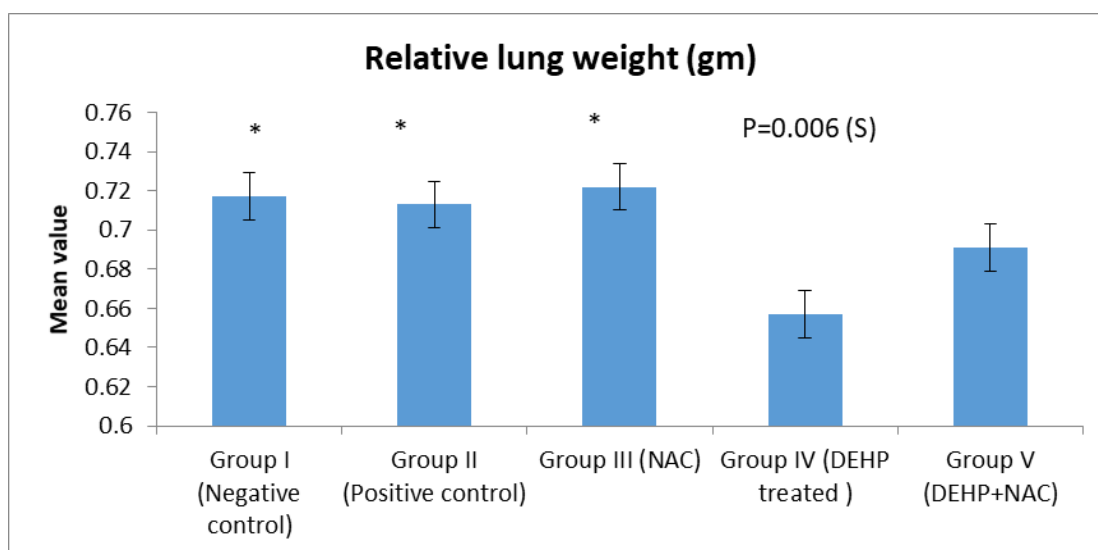
The current work showed a significant ($p < 0.006$) reduction in the mean values of relative lung weights of the DEHP-treated group in comparison to the control groups at the end of the experiment as shown in **fig. 2**.

Fig. (1): The effect of DEHP exposure on the rats' weight as compared to that of the other groups over the study period



*= Significant in comparison with group IV †= Significant in comparison with group V

Fig. (2): Comparison between the mean values of relative lung weights among the rats in the different studied groups.



*=Significant in comparison with group IV

B-Lung biochemical oxidant finding (fig. 3):**Malondialdehyde (MDA) level**

Group (IV) DEHP-treated rats showed a highly significant increase ($P < 0.001$) in the MDA level of lung homogenates as compared to both groups I and II (negative and positive control groups).

In group (V) DEHP + NAC treated rats, there was a highly significant reduction in the elevated level of lipid peroxidation marker (MDA) in the lung as compared to group (IV).

GSH content

The GSH level in the lungs of the rats treated with DEHP showed a highly significant reduction as compared to its level in the rats of the two control groups ($P < 0.001$). Concomitant administration of NAC with DEHP treatment showed a highly significant elevation in the lung GSH level ($P < 0.001$).

CAT activity

The CAT activity in the lung homogenates of DEHP-treated rats was highly significant ($P < 0.001$) lower than that of both control groups.

In the lung homogenates of DEHP + NAC treated rats, highly significant improved CAT activity was detected as compared to the control groups ($P < 0.001$).

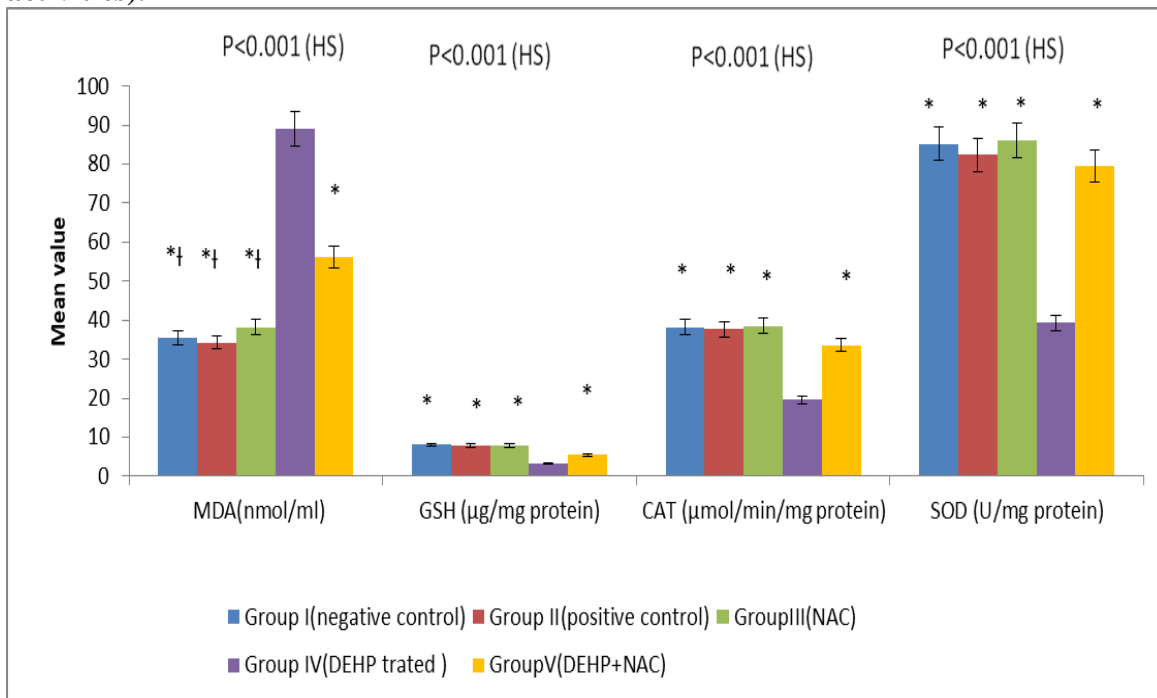
SOD activity

The SOD activity in the lung homogenates of DEHP-treated rats was highly significant ($P < 0.001$) lower than that of both control groups. In the lung homogenates of DEHP + NAC treated group, the SOD activity was highly significant elevated than those of the DEHP-treated group ($P < 0.001$).

C- Western Blot Analysis for the Detection of Caspase-3:

The effect of DEHP administration on the apoptotic marker cleaved caspase-3 is demonstrated as a significant increase of cleaved caspase-3 as compared with control groups ($P < 0.05$). Concomitant administration of NAC with DEHP showed a highly significant reduction in the cleaved caspase -3 level in the rats' lungs ($P < 0.001$) as in **Fig.4**.

Fig. (3): Alteration of the lipid peroxidation markers in the lung tissue of all the studied groups (expressed as MDA level, GSH content, CAT, and SOD activities).



*= Significant in comparison with group IV
 †= Significant in comparison with group V




Fig. (4): A & B: Western blot analysis of cleaved caspase-3 protein and graphic representation of cleaved caspase-3 protein levels in the lung tissues of the control groups as well as DEHP and NAC -treated groups.

D- Histological & Immunohistochemical results:

✚ H&E results

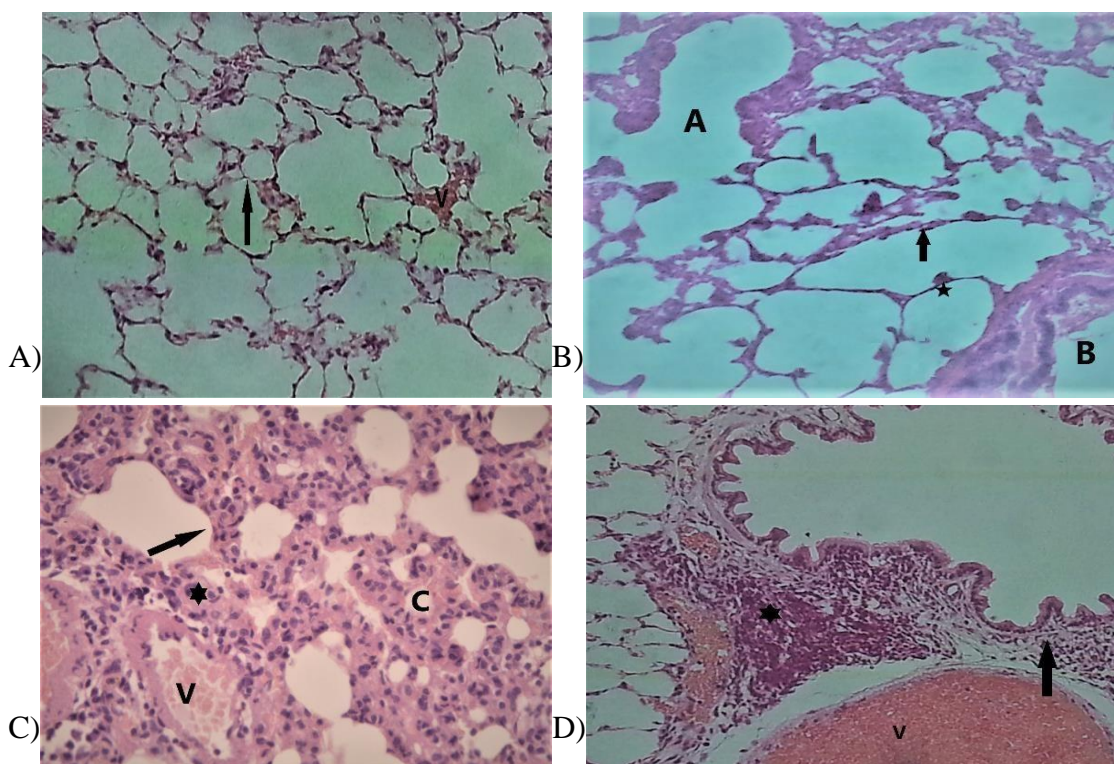
Examination of the lung sections of the control rats' groups showed normal lung structure with bronchioles and blood vessels in between the lung alveoli that have thin inter-alveolar septa (**Fig. 5 A&B**). The lung alveoli of group IV (DEHP- treated group) showed thick inter-alveolar septa with inflammatory cells infiltration and extravasated red blood cells (**Fig. 5 C&D**). Sections of DEHP-treated rats receiving NAC showed thin interalveolar septa with less cellular infiltration and less extravasated RBCs in comparison to DEHP- treated group (**Fig. 5 E&F**).

✚ Sirius red stain results:

Sections of the control groups revealed fine thin collagen fibers in between the

alveoli (**Fig. 6A**). In the DEHP-treated group (group IV), thick bronchioles and thick interalveolar septa with condensed collagen fibers in between them were detected (**Fig. 6 B&C**).

In lung sections of rats treated with DEHP+NAC (group V) apparent decrease in the collagen fibers between the alveoli of bronchioles was detected when compared with group IV (**fig.6 D**).



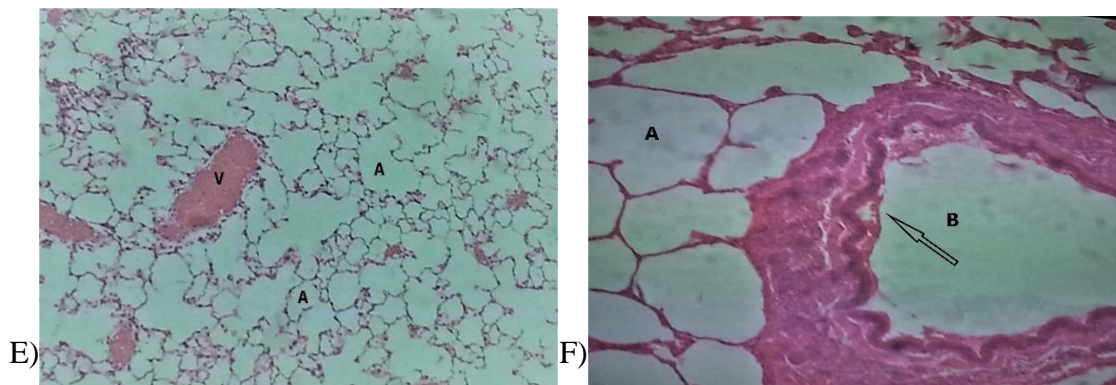


Fig. (5): A) A photomicrograph of a section of a control rat's lung showed many alveoli with thin alveolar walls (arrow). Notice the blood capillary in between alveoli "V". B) A photomicrograph of a section of a control rat's lung showed many alveoli with thin alveolar cells; pneumocyte type I with their flattened nuclei (black arrow) and pneumocytes type II with rounded nuclei (*). Notice the part of a bronchiole "B" and alveolar duct "A". C&D) Photomicrographs of a section of lung treated rats by DEHP (Group IV) showed areas of inflammatory cell infiltration (*), vascular congestion "V", collapsed alveoli "C" and thickened interalveolar septae (arrow), dilated pulmonary blood vessel "V" and inflammatory cells infiltration (*). There is a fragmentation of the surrounding bronchial muscle layer (arrow). E&F) Photomicrographs of a section of lung of treated rats by DEHP+NAC (Group V) showed numerous alveoli "A" with a thin alveolar wall. Notice the part of a bronchiole lined by ciliated columnar epithelium (arrow) and dilated congested blood vessels "V". (A&B and E) H&E, × 200 (C&D and F) H&E, × 400.

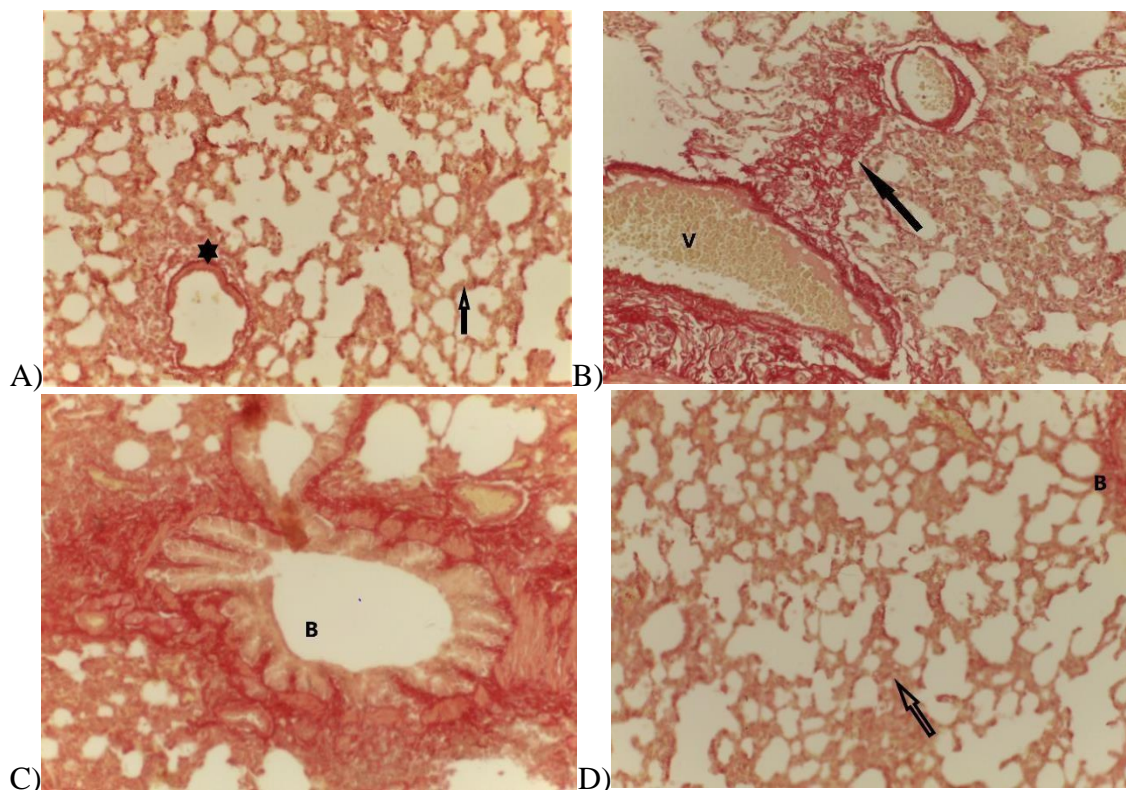


Fig. (6): A) A photomicrograph of a section of a control rat's lung showed alveoli with the presence of a minimal amount of collagen fibers (continuous reddish-brown) in the interalveolar septa (arrow \uparrow) and around bronchiole (*). Sirius red, $\times 400$. B&C) photomicrographs of a section of lung of treated rats by DEHP (Group IV) showed areas of extensive accumulation of collagen fibers around bronchioles "B" within the interalveolar septa (arrow \uparrow). Notice the congested blood vessels "V". Sirius red, (B) $\times 100$ and (C) $\times 400$. D) A photomicrograph of a section of a lung of DEHP+NAC-treated rat (Group V) showed mild to moderate accumulation of collagen fibers around the alveoli (arrow \uparrow), and around the bronchioles "B". Sirius red, $\times 400$

Immunohistochemical results:

Immunostained sections of control groups revealed negative (caspase-3) immunostaining of interalveolar septa (Fig.7A), while, group IV showed strong

positive caspase-3 immunostaining (Fig.7B). Sections of DEHP rats receiving NAC (group V) showed apparently decreased caspase-3 immunostaining (Fig.7 C).

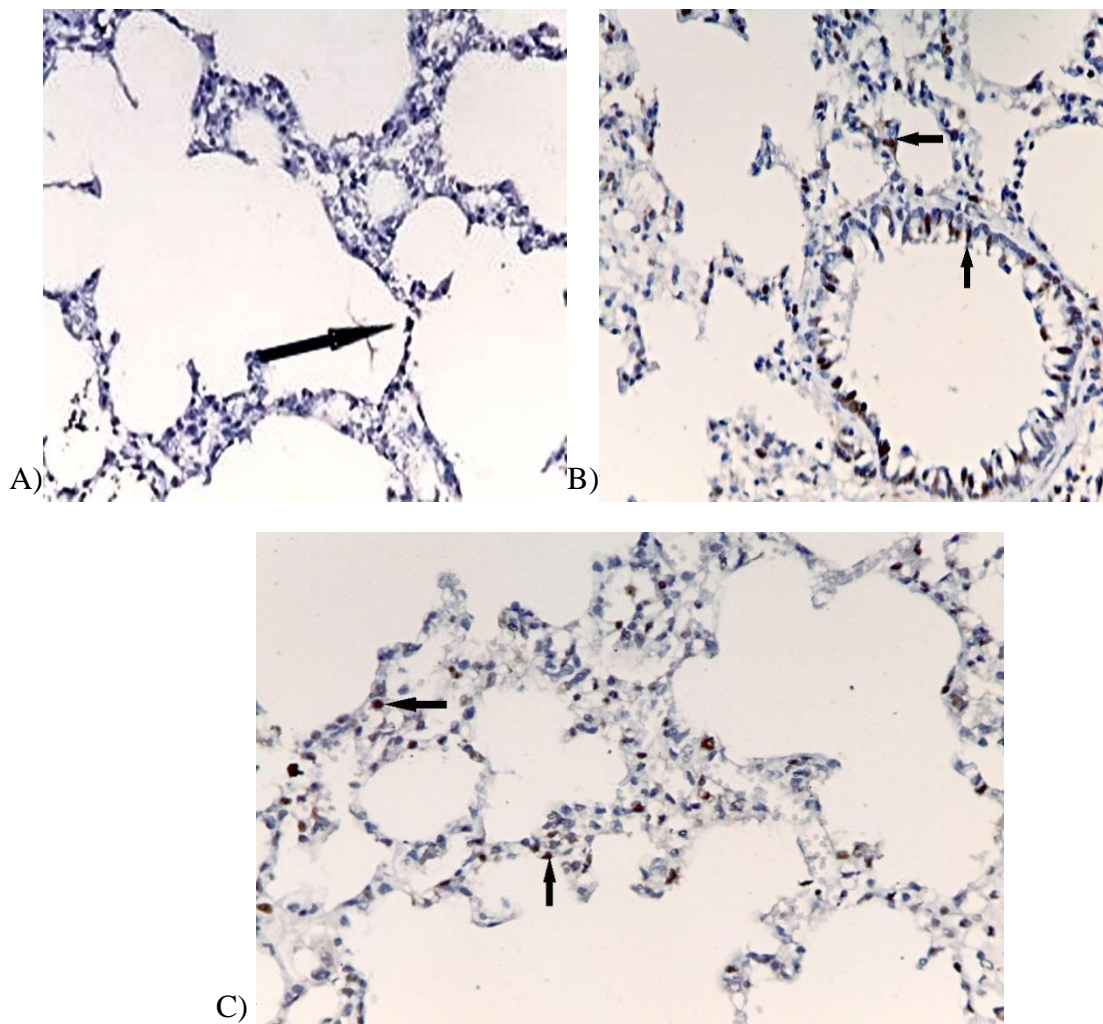


Fig. (7): A) A photomicrograph of a section of a control rat's lung showed few negative caspase-3 immunoreactivities within the nuclei of the alveolar lining cells (arrow \uparrow). B) A photomicrograph of a section of the lung of DEHP -treated rat (Group IV) showed moderate positive caspase -3 immunoreactivity within the nuclei of the alveolar lining cells and the nuclei of the bronchiolar epithelium (arrows \uparrow). C) A Photomicrograph of a section of a lung of DEHP+NAC treated rat (Group V) showed mild positive caspase-3 immunoreactivity within the nuclei of the alveolar lining cells (arrows \uparrow). [Immunostaining for caspase-3 X400].

Morphometric results:

-The alveolar septal wall thickness: (fig. 8)

There was a highly significant increase ($P < 0.001$) in the alveolar septal wall thickness after DEHP administration as compared to control groups. The decrease in the alveolar wall thickness after receiving NAC was highly significant as compared to the DEHP-treated group ($P < 0.001$).

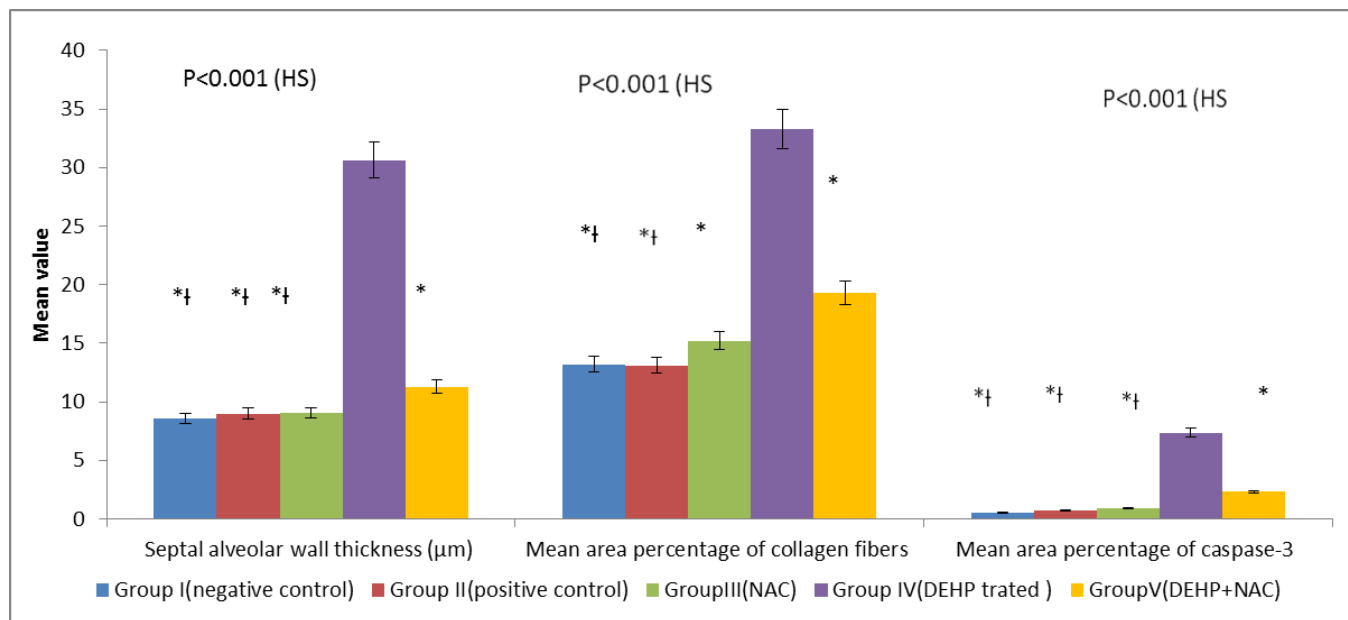
-The collagen fibers (fig .8)

There were highly significant differences in the mean area percentage of collagen

fibers in the DEHP-treated group compared with the control groups ($P < 0.001$) and a highly significant decrease in the mean area percentage of collagen fibers in DEHP+NAC treated group when compared with the DEHP-treated group ($P < 0.001$).

-The caspase-3 (fig .8)

The mean area percentage of caspase-3 positive immune-staining was markedly increased in the DEHP-treated group as compared with the control groups and this increase was highly significant ($P < 0.001$).



*=Significant in comparison with group IV

≡ Significant in comparison with group V

Fig. (8): Morphometric study of septal alveolar wall thickness (µm), the mean area percentage of collagen fibers, and mean area percentage of caspase-3 in different studied groups.

DISCUSSION

DEHP a common type of phthalate plasticizer has become a major environmental toxic hazard to human health (Fakher et al., 2018).

The plasticizer DEHP is commonly used in the production of plastic products due to its fluidity and stability. DEHP is abundant in the environment despite being banned by the European Union and the United States and is considered an emerging pollutant (Gavrilescu et al., 2015; Net et al., 2015).

Most of the researches conducted on DEHP over the past few decades had been investigating its harmful role in reproduction and tumor genesis (Voss et al., 2005). Furthermore, DEHP can cause an inflammatory response in several cell types (Larsen et al., 2007; Nishioka et al., 2012).

The present study revealed that the mean values of the body weight in DEHP treated rats are decreased as compared to the other groups, which were a non-significant reduction after the 1st & 2nd weeks, and it became highly significant after the 3rd & 4th weeks of treatment. Furthermore, it was found that NAC supplementation is partially protective.

A study conducted by Liu et al., 2014 showed that; at the end of the 1st week of DEHP oral exposure at a dose of 1000 or 3000 mg/kg, there was a non-significant difference in the mean body weights of rats but after two and three weeks, the weights of rats treated with DEHP were significantly reduced, and at the end of 4th week the mean body weights of DEHP treated rats were significantly decreased as compared to the control rats.

Another study found that the administration of 1000 mg/kg of DEHP to rats by oral gavage results in a significant decrease in the body weights after 10 days

of DEHP exposure (Erkekoglu et al., 2014).

At the end of the experiment, the relative lung weight is found to be significantly decreased in DEHP –treated group as compared to the control and NAC-treated groups.

This was in concordance with the study of Gray et al. (1977) who found that the absolute weights of most organs in the rats given DEHP were lower than those of the controls. In another study by David et al. (2000) the relative lung weights were found to be significantly higher for the 2500- and 12,500-ppm male rat groups than for the controls.

Bodyweight is an important non-specific indicator that fully reflects substance toxicity and can be used to assess the DEHP effect on rat growth status. DEHP exposure has been recorded to be able to reduce body weight gain by interfering with fat metabolism and synthesis (Itsuki-Yoneda et al., 2007). The present study confirmed that DEHP- treated group showed a highly significant increase in the (MDA) level of the lung homogenates as compared to the control groups but in the (DEHP+NAC) treated group, there was a highly significant reduction in its level. Also, there was a significant decrease in the GSH content, SOD, and CAT in the DEHP - treated group in comparison to that of the other groups.

It is well known that when the amounts of ROS exceed the capacity of endogenous antioxidants, oxidative distress is activated and the cellular antioxidant state is altered. Oxidative stress manifestation includes cell and mitochondrial membrane lipid peroxidation, ATP depletion, protein oxidation, and unfolding, DNA oxidation, and ultimately cell death. The main ROS produced during oxidative stress are superoxide anions (O₂⁻), hydroxyl radicals

(OH %) and hydrogen peroxide (H₂O₂) (Avery, 2011; Sies et al., 2014).

Superoxide dismutase is the antioxidant enzyme of the first line of body defense that can remove free oxygen radicals. MDA is one of the final lipid peroxidation products. MDA is usually referred to as the marker of oxidative stress and antioxidant status (Tsikas, 2017). On the other hand, the enzyme CAT is needed to hydrolyze H₂O₂ into H₂O and O₂, when depletion occurs, tissue change this process to Fenton's response by generating big quantities of (OH %) from H₂O₂ (Sies et al., 2014).

In the current study, DEHP is responsible for the oxidative damage as shown by the high rise in MDA level and the reduction in GSH, CAT, and SOD levels in the lung tissues of the DEHP treated male albino rat group. Whereas, NAC ameliorate the DEHP-induced oxidative damage and apoptosis in a dose-dependent manner. This research revealed that DEHP may result in severe damage to the antioxidant protection system. A possible explanation is that the excess amount of free radicals produced after exposure to DEHP has exceeded the eliminating ability of SOD and CAT enzymes (Gui-sheng, 2014).

The histopathological study of the lung alveoli of DEHP treated group showed thick inter-alveolar septa with cellular infiltration and extravasation of the RBCs while sections of the lungs of DEHP+NAC treated rat group illustrated thin interalveolar septa and decrease in the cellular infiltration and fewer RBCs extravasation in comparison to that of the control groups. By Sirius red stain, the DEHP- treated group showed thick bronchioles and thick inter-alveolar septa. The study also detected condensed collagen fibers in between the alveoli. On the opposite side, the lungs of the DEHP&NAC treated rat group showed apparently

decreased collagen fibers and thickness of the bronchioles, when compared with the lungs of the DEHP, treated group.

Another study reported a marked rise in the density of the inter-alveolar septa with the deposition of collagen and inflammatory cellular infiltration. This was also associated with many collapsed alveoli in the lungs of the DEHP- treated rats after 2 weeks of DEHP administration (Abdel-gawad and Atia, 2013).

Increased epithelial and mesenchymal cell proliferation was also reported in the distal lung parenchyma of the rats treated with DEHP (Rosicarelli and Stefanini, 2009).

DEHP may act through peroxisome proliferator-activated receptors (PPARs) that have been over-expressed in the pneumocytes of type II culture. In type II pneumocytes, overexpression of PPARs gamma induces inflammatory reaction associated with inflammatory cell infiltration, and T-cell suppression in the lung tissue.

DEHP induced release of lysosomal enzymes from the cultured alveolar macrophages is combined with pulmonary vasoconstriction and edema (Ummanni et al., 2010; Abdel-gawad and Atia, 2013).

Apoptosis is a crucial method for eliminating unwanted or defective cells through a cellular disintegration process (Ameisen, 1996). There are few reliable, specific ways to detect apoptosis. However, caspase-3 indicates cell death induction and is considered as the main component in apoptosis. Activation of Caspase-3 often results in a cellular irreversible commitment to apoptosis.

Thus, caspase-3 has been stated as an important marker of apoptosis (Golbs et al., 2007). In this study, the activity of caspase-3 was evaluated to determine the apoptotic

status of the lung cells. It was found that the caspase-3 and the histological damage were much higher in the DEHP-treated group when compared to the other groups.

Based on the results of the present study, NAC protective effects against the oxidative damage of DEHP were observed, both biochemically and histopathologically, in the examined sections of DEHP-induced lung injury.

CONCLUSION

In this study, we can conclude that DEHP toxicity revealed the apoptotic status of the lung cells that was mediated by lipid peroxidation and by the increase in the activity of caspase-3. The utilization of NAC to overcome the lung toxicity provoked by phthalates is recommended for further studies with an elaborative study of their pharmacologic properties and biological effects.

REFERENCES

- Abdel-gawad, S.K. and Atia, T. (2013):** Histological and ultrastructure changes induced by di (2-Ethylhexyl) phthalate (DEHP) in the alveolar tissue of adult albino rats and the possibility of recovery. *J. Cell Sci. Therapy*, 4: 141.
- Ameisen, J.C. (1996):** The origin of programmed cell death. *Sci.*, 272:1278-1279.
- Arikan, D.C.; Bakan, V.; Kurutas, E.B.; Sayar, H. and Coskun, A. (2010):** Protective effect of tadalafil on ischemia/reperfusion injury of rat ovary. *J. Pediatr. Surg.*, 45: 2203-2209.
- Avery, S.V. (2011):** Molecular targets of oxidative stress. *Biochem. J.*, 434:201-210.
- Bancroft, J.D. and Layton, C. (2013):** The hematoxylin and eosin, connective and mesenchymal tissues with their stains. In: Suvarna SK, Layton C, Bancroft JD (eds). *Bancroft's Theory and practice of histological techniques*. (7th edition). Churchill Living stone, Philadelphia; 173-212.
- Beers, M.F. (2008):** *Fishman's Pulmonary Disease and Disorders*. 4th edition. New York: McGraw Hill; 2624-2628.
- Bernard, L.; Décaudin, B.; Lecoœur, M.; Richard, D; Bourdeaux, D; Cueff, R. et al. (2014):** Armed Study Group. Analytical methods for the determination of DEHP plasticizer alternatives present in medical devices: a review. *Talanta*, 129:39-54.
- David, R.M.; Moore, M.R.; Finney, D.C. and Guest, D. (2000):** Chronic toxicity of di (2- Ethylhexyl) phthalate in mice. *Toxicol. Sci.*, 58: 377-385.
- Engel, S.M., and Wolff, M.S. (2013):** Causal inference considerations for endocrine disruptor research in children's health. *Annu. Rev. Public Health*, 34:139-58.
- Eren, I.; Naziroglu, M. and Demirdas, A. (2007):** Protective effects of lamotrigine, aripiprazole, and escitalopram on depression-induced oxidative stress in rat brain. *Neurochem. Research*, 32:1188-95.
- Erkekoglu, P.; Zeybek, N.D.; Giray, B.; Asan, E.; Arnaud, J. and Hincal, F. (2011):** Reproductive toxicity of di (2-Ethylhexyl) phthalate in selenium-supplemented and selenium-

- deficient rats. *Drug Chem. Toxicol.*, 34: 379-389.
- Fakher, H.M.; Ahmed, M. K.; Haggag, O.G.; Madboly, A.G. and Abdrhabu, R.M. (2018):** Subchronic Toxic Effects of Di- Ethylhexyl Phthalate on Ovary and Testis of Adult Albino Rats. *Egypt J. Forensic Sci. Appli*, 18(2): 119-135.
- Gavrilescu, M.; Demnerová, K.; Aamand, J.; Agathos, S. and Fava, F. (2015):** Emerging pollutants in the environment: present and future challenges in biomonitoring, ecological risks, and bioremediation. *N. Biotechnol.*, 32(1): 147-15.
- Golbs, A.; Heck, N. and Luhmann, H.J (2007):** A new technique for real-time analysis of caspase-3 dependent neuronal cell death. *J. Neurosci. Methods*, 161:234-243.
- Gray, T.J.B.; Butterworth, K.B.R.; Gaunt, I.F .; Grasso, G.P. and Gangolli, S.D. (1977):** Short- term toxicity study of di-(2- Ethylhexyl) phthalate in rats. *Food Cosmet. Toxicol.*, 15(5): 389-399.
- Gui-sheng, Z. (2014):** Effect of diethyl phthalate on the biochemical markers of brain, testis, and testicular tissue structure in *Cyprinus carpio* Linnaeus. *J. Environ. Safety*, 5: 075.
- Hoppin, J.A.; Jaramillo, R.; London, S.J.; Bertelsen, R.J.; Salo, P.M.; Sandler, D.P. et al. (2013):** Phthalate exposure and allergy in the U.S. population: results from NHANES 2005–2006. *Environ. Health Perspect.*, 121:1129-1134.
- Itsuki-Yoneda, A.; Kimoto, M.; Tsuji, H.; Hiemori, M. and Yamashita, H. (2007):** Effect of a hypolipidemic drug, di (2-Ethylhexyl) phthalate, on mRNA-expression associated fatty acid and acetate metabolism in rat tissues. *Biosci. Biotechnol. Biochem.*, 71: 414- 420.
- Jaakkola, J.J. and Knight, T.L. (2008):** The role of exposure to phthalates from polyvinyl chloride products in the development of asthma and allergies: a systematic review and meta-analysis. *Environ. Health Perspect.*, 116: 845-853.
- JCIA (Japan Plasticizer Industry Association) (2018):** Statistical database [Internet]. Available from:<http://www.kasozai.gr.jp/data/> (Accessed 25Feb 2019).
- Junaid, M.; Jia, P.P.; Tang, Y.M.; Xiong, W.X.; Huang, H.Y.; Strauss, P.R. et al. (2018):** Mechanistic toxicity of DEHP at environmentally relevant concentrations (ERCs) and ecological risk assessment in the Three Gorges Reservoir Area, China. *Environ. Pollut.*, 242: 1939-1949.
- Koch, R. J.; Barrette, A. M.; Stern, A. D.; Hu, B.; Bouhaddou, M.; Azeloglu, E. U.; et al. (2018):** Validating Antibodies for Quantitative Western Blot Measurements with Microwestern Array. *Sci. rep.*, 8(1): 11329.
- Larsen, S.T.; Hansen, J.S.; Hansen, E.W.; Clausen, P.A. and Nielsen, G.D. (2007):** Airway inflammation and adjuvant

- effect after repeated airborne exposures to di-(2-Ethylhexyl) phthalate and ovalbumin in BALB/cmice. *Toxicol.*, 235:119-129.
- Laskin, J.D.; Black, A.T.; Jan, J.H.; Sinko, P.J.; Heindel, N.D.; Sunil, V.; et al (2010):** Oxidants and antioxidants in sulfur mustard-induced injury. *Ann. N. Y. Acad. Sci.*, 1203: 92-100.
- Liu, T.; Li, N.; Zhu, J.; Yu, G.; Guo, K.; Zhou, L.; Zheng, D.; Qu X.; Huang, J.; Chen, X.; Wang, S. and Ye, L. (2014):** Effects of di-(2-Ethylhexyl) phthalate on the hypothalamus-pituitary-ovarian axis in adult female rats. *Reprod. Toxicol.*, 46: 141-147.
- Maheswari, E.; Saraswathy, G. and Santhranii, T. (2014):** Hepatoprotective and antioxidant activity of N-acetyl cysteine in carbamazepine-administered rats. *Indian J. Pharmacol.*, 46: 211-215.
- Mokhtari, V.; Afsharian, P.; Shahhoseini, M.; Kalantar, S.M. and Moini, A. (2016):** Review on Various Uses of N-Acetyl Cysteine. *Cell J.*, 19 (1):11-17.
- Morton, J. and Snider, T. A. (2017):** Guidelines for collection and processing of lungs from aged mice for histological studies. *Pathobiol. Aging Age Relat. Dis.*, 7(1): 1313676.
- Muczynski, V.; Lecureui, C.; Messiaen, S.; Guerquin, M.J.; N'tumba- Byn, T.; Moison, D. et al. (2012):** Cellular and molecular effect of MEHP involving LXR α in human fetal testis and ovary. *P.L.O.S. ONE*, 7 (10): e48266.
- Nabavi, S.F.; Moghaddam, H.A.; Eslami, S. and Nabavi, S.M. (2012):** Protective effects of curcumin against sodium fluoride-induced toxicity in rat kidneys. *Biol. Trace Elem. Res.*, 145: 369-374.
- Nemmar, A.; Al-Salam, S.; Subramaniyan, D.; Yasin, J.; Yuvaraju, P.; Beegam, S.; et al (2013):** Influence of experimental type 1 diabetes on the pulmonary effects of diesel exhaust particles in mice. *Toxicol. Lett.*, 217:170-176.
- Nemmar, A.; Al-Salam, S.; Yuvaraju, P.; Beegam, S. and Ali, B.H. (2015):** Emodin mitigates diesel exhaust particles-induced increase in airway resistance, inflammation and oxidative stress in mice. *Respir. Physiol. Neurobiol.*, 215, 51-57.
- Net, S.; Delmont, A.; Sempéré, R.; Paluselli, A. and Ouddane, B. (2015):** Reliable quantification of phthalates in environmental matrices (air, water, sludge, sediment, and soil): A review. *Sci. Total Environ.*, 515: 162-180.
- Nishioka, J.; Iwahara, C.; Kawasaki, M.; Yoshizaki, F.; Nakayama, H.; Takamori, K.; et al. (2012):** Di-(2-Ethylhexyl) phthalate induces production of inflammatory molecules in human macrophages. *Inflamm. Res.*, 61: 69-78.
- Rosicarelli, B. and Stefanini, S. (2009):** DEHP effects on histology and cell proliferation in lung of newborn rats. *Histochem. Cell Biol.*, 131(4): 491-500.
- Saha, L.; Kaur, S. and Saha, P.K. (2013):** N-acetyl cysteine in clomiphene citrate resistant polycystic ovary syndrome: A review of reported

- outcomes. *J. Pharma.*, 4(3):187-191.
- Sathyanarayana, S. (2008):** Phthalates and children's health. *Curr. Probl. Pediatr. Adolesc. Health Care*, 38 (2): 34-49.
- Shahin, A.Y.; Hassanin, I.M.; Ismail, A.M.; Kruessel, J.S. and Hirchenhain, J. (2009):** Effect of oral N-acetyl cysteine on recurrent preterm labor following treatment for bacterial vaginosis. *Int. J. Gynaecol. Obstet.*, 104 (1):44-48.
- Sies, C.; Berndt, D.P. and Jones, P. (2017):** Oxidative stress. *Ann. R. Biochem.*, 86: 715-748.
- Souza, J.r.; Soares, B. G., and Pinto, J.C. (2006):** SBS/polyaniline or carbon black system: Finding the optimal process and molding temperature through experimental design. *Macromol. Mater. Engin.*, 291(5): 463-469.
- Takai, R.; Hayashi, S.; Kiyokawa, J.; Iwata, Y.; Matsuo, S.; Suzuki, M.; et al. (2009):** Collaborative work on evaluation of ovarian toxicity. 10) Two- or four-week repeated dose studies and fertility study of di-(2-Ethylhexyl) phthalate (DEHP) in female rats. *J. Toxicol. Sci.*, 34 (1):111-119.
- Ticker, J.A.; Schettler, T.; Guidotti, T.; McCally, M. and Rossi, M. (2001):** Health risks posed by use of di-2- Ethylhexyl phthalate (DEHP) in PVC medical devices: a critical review. *Am. J. Ind. Med.*, 29: 100-111.
- Tsikakos, D. (2017):** Assessment of lipid peroxidation by measuring malondialdehyde (MDA) and relatives in biological samples: Analytical and biological challenges. *Anal. Biochem.*, 524:13-30.
- Ummanni, R.; Lehnigk, U.; Zimmermann, U.; Woenckhaus, C.; Walther, R. and Giebel, J. (2010):** Immunohistochemical expression of caspase-1 and -9, uncleaved caspase-3 and -6, cleaved caspase-3 and -6 as well as Bcl-2 in benign epithelium and cancer of the prostate. *Exper. Ther. Med.*, 1(1):47-52.
- Voss, C.; Zerban, H.; Bannasch, P. and Berger, M.R. (2005):** Lifelong exposure to di-(2-Ethylhexyl) - phthalate induces tumors in liver and testes of Sprague-Dawley rats. *Toxicol.*, 206: 359-371.
- Weibel, E.R.; Hsia, C.C. and Ochs, M. (2007):** How much is there really? Why stereology is essential in lung morphometry. *J.appl. Physiol.*, 102(1): 459-467.
- Xia, L., and Xue, X.Z. (2012):** Immunohistochemical study of NF- κ B p65, c-IAP2, and caspase- 3 expression in cervical cancer. *Oncol. Lett.*, 3(4):839-844.
- Yuan, L.; Li, M.; Meng, F.; Gong, Y.; Qian, Y.; Shi, G.; et al. (2017):** Growth, blood health, antioxidant status, immune response and resistance to *Aeromonas hydrophila* of juvenile yellow catfish exposed to di-2-Ethylhexyl phthalate (DEHP). *Comp. Biochem. Physiol. C. Toxicol. Pharm.*, 202:79-84
- Zhao, H.; Qin, H.Y.; Cao, L.F.; Chen, Y.H.; Tan, Z.X.; Zhang, C.; et al. (2015):** Phenylbutyric acid inhibits epithelial-mesenchymal transition during bleomycin- induced lung fibrosis. *Toxicol. Lett.*, 232: 213-220.

التأثيرات الوقائية لإضافة ان أسيتيل سيستايين ضد الآثار السامة للداي إيثيل هكسيل فتالات على رنتي الفئران البيضاء البالغة (دراسة هستولوجية - مناعية هستوكيميائية)

أمنية أفرج¹، ايمان فاروق²، نشوى حسن أبو رية³، تغريد خربوش⁴، هايدى فخر¹

¹ قسم الطب الشرعى و السموم الاكلينيكية، كلية الطب، جامعة بنها

² قسم الأنسجة و الخلايا، كلية الطب، جامعة بنها

³ قسم الفارماكولوجيا الاكلينيكية، كلية الطب، جامعة بنها

⁴ قسم الميكروبيولوجى، كلية الطب، جامعة بنها

يعتبر الداى إيثيل هكسيل فتالات ملوث بيئي عالمي يتعرض له الإنسان من خلال المصادر البيئية. إن التعرض لهذا الملوث يسبب تأثيرات واضحة على صحة الإنسان سواء كان التعرض له في المجتمع (كإطعام والهواء والماء) أو في المجال الطبي. وقد وجد أن الداى إيثيل هكسيل فتالات له سمية خلوية، و مناعية، و جينية، و تناسلية. لذلك نهدف بهذا العمل لتقييم الآثار السامة المحتملة للداى إيثيل هكسيل فتالات على رنتي الفئران البيضاء البالغة وتقييم الآثار الوقائية المحتملة لداى أسيتيل سيستايين باستخدام وزن الجسم ومعايير وزن الرئة النسبي. تم تقييم سمية الداى إيثيل هكسيل فتالات باستخدام الطرق البيوكيميائية ووالهستوباثولوجية والهستوكيميائية. قُسم خمسين فأر أبيض من الذكور البالغين إلى خمس مجموعات متساوية على النحو التالي: المجموعة الأولى (مجموعة ضابطة سلبية): تم اعطاؤها الوجبة العادية والماء بدون أى علاج لقياس المعايير الأساسية لمدة 4 أسابيع. المجموعة الثانية (مجموعة ضابطة ايجابية): تم اعطاء كل فأر زيت ذرة عن طريق الفم [مل /يومياً] لمدة 4 اسابيع. المجموعة الثالثة (المجموعة المعالجة ب ان أسيتيل سيستايين): أعطيت هذه المجموعة ان أسيتيل سيستايين عن طريق الفم (200 مجم / كجم / يوم). المجموعة الرابعة (المجموعة المعالجة ب الداى إيثيل هكسيل فتالات): تم اعطاء كل فأر الداى إيثيل هكسيل فتالات بعد اذابته بزيت الذرة بالفم 3 جم/ كيلوجرام/ مرة واحدة يومياً لمدة 4 أسابيع. المجموعة الخامسة: (المجموعة المعالجة بكلا من الداى إيثيل هكسيل فتالات و ان أسيتيل سيستايين): تم علاجها ب كلا الدوائين بنفس الجرعات السابقة. كشفت نتائج الدراسة أن ب الداى إيثيل هكسيل فتالات قد زاد بشكل ملحوظ من مستوى بيروكسيد الدهون وقلل بشكل ملحوظ في محتوى الجلوتاثيون و نشاط سوبر أكسيد ديسموتاز و نشاط انزيم الكاتالاز. أظهرت النتائج النسيجية للمجموعة الرابعة ارتشاحاً خلويًا التهابيًا للرنئين، وذمة خلالية، نزيف و سماكة الحاجز السنخي على عكس المجموعة الخامسة، التي أظهرت كذلك انخفاضًا كبيرًا في تراكم ألياف الكولاجين و انتاج انزيم كاسبيز ٣ بالمقارنة مع المجموعة الرابعة. الخلاصة: العلاج ب ان أسيتيل سيستايين يمكن أن يحمي ضد السمية الرئوية التي يسببها ب الداى إيثيل هكسيل فتالات في الفئران عن طريق تقليل الإجهاد التأكسدي، والتهاب، و الموت المبرمج للخلايا