

A Persistent left Superior Vena Cava: Case report

Ayman Elsayed Albadrany

Department of Cardiology, Damietta Cardiac and Gastroenterology Center, Egypt.

*Corresponding author: Ayman Elsayed Elbadrany, Mobile: (+20)1010668806, E-Mail: aymanalbdrany@yahoo.com

ABSTRACT

Background: Persistent left superior vena cava (PLSVC) is rare but important congenital vascular anomaly. It results when the left superior cardinal vein caudal to the innominate vein fails to regress. It is most commonly observed in isolation but can be associated with other cardiovascular abnormalities including atrial septal defect, bicuspid aortic valve, coarctation of aorta, coronary sinus ostial atresia, and cor triatriatum.

Objective: Aim of this case presentation was to describe a rare case of persistent left superior vena cava that is associated with atrial septal defect and partial anomalous pulmonary venous drainage. Also, how to suspect and then confirm the presence of PLSVC by echocardiographic examination, and to know the role of multi-slice CT and cardiac MRI for detection of other cardiac and extra-cardiac anomalies.

Patients and methods: Male patient aged 32 year complaining of shortness of breath for about 1 year, echocardiographic examination revealed dilated coronary sinus and injection of agitated saline indicated the presence of persistent left superior vena cava. PLSVC may be associated with other anomalies so further evaluation by multi-slice CT was done to confirm the diagnosis of PLSVC as well as sinus venosus ASD and partial anomalous pulmonary venous drainage so surgical consultation was done for surgical correction.

Conclusion: Diagnosis of PLSVC is important, as it is often associated with other anomalies as atrial septal defect and partial anomalous pulmonary venous drainage, which lead to pulmonary hypertension and need surgical correction before the occurrence of pulmonary hypertension.

Keywords: PLSVC, CT MRI.

INTRODUCTION

Persistent left superior vena cava (PLSVC) is the most common systemic venous return anomaly, with an estimated prevalence of 0.3-0.5% in the general population, of 4-8% in patients with congenital heart disease ⁽¹⁾, and 0.9% in the fetal population ⁽²⁾. The origin of the PLSVC is not yet completely clear. It is believed to be the result of an intrauterine failure of the development of the left anterior cardinal vein, resulting in the bilateral presence of superior vena cava ⁽³⁾. However, in the last years the prenatal diagnosis of PLSVC has been done based on an abnormal view of three vessels in the upper mediastinum, showing a supernumerary vessel to the left of the pulmonary trunk and arterial duct ⁽⁴⁾.

Although there are many divergences regarding the true prevalence, the PLSVC does not have major clinical impacts, as systemic venous blood continues to return to the right atrium through the coronary sinus, and there is usually a normal right superior vena cava ⁽⁵⁾.

The recognition of PLSVC is of great importance for anatomists, clinicians and surgeons, especially in the implantation of long-term central venous catheter as well as pacemaker insertion. Thus, the present article aimed to report a finding of a persistent left superior vena cava in adult 32 years male who was complaining of shortness of breath for a year before diagnosis ⁽⁶⁾.

Aim of the study: to describe a rare case of PLSVC that was associated with atrial septal defect and partial anomalous pulmonary venous drainage. Also, to

suspect and then confirm the presence of PLSVC by echocardiographic examination, and to know the role of multi-slice CT and cardiac MRI for detection of other cardiac and extra-cardiac anomalies.

CASE PRESENTATION

Male patient aged 32 year, work as a driver with average normal weight and height complaining of shortness of breath for about one year, he asked for medical advice. By clinical examination, normal blood pressure, heart rate, also cardiac and chest examination was unremarkable. Lab investigations were done including CBC, liver functions test, renal functions tests, and thyroid function tests. All lab investigation were normal. ECG showed right bundle branch block pattern. Therefore, echocardiographic examination to assess ventricular function, valves and pulmonary artery pressure was necessary. Echocardiographic data included dilated coronary sinus (Figure 1 and 2) and low probability pulmonary hypertension with TR velocity 2.8 m/sec, and dilated RA, RV.

Causes of dilated coronary sinus includes: LSVC (left superior vena cava), isolated atresia or stenosis of the coronary sinus (CS) partial anomalous hepatic venous connection to CS, partially unroofed CS, anomalous pulmonary venous return to CS, coronary arterio-venous fistula and aneurysm of the CS ^(7,8).

To exclude LSVC, agitated saline was injected through the left arm vein if reached the CS before the right atrium and right ventricle suggest the presence of PLSVC (Figure 3, 4).



This article is an open access article distributed under the terms and conditions of the Creative Commons Attribution (CC BY-SA) license (<http://creativecommons.org/licenses/by/4.0/>)

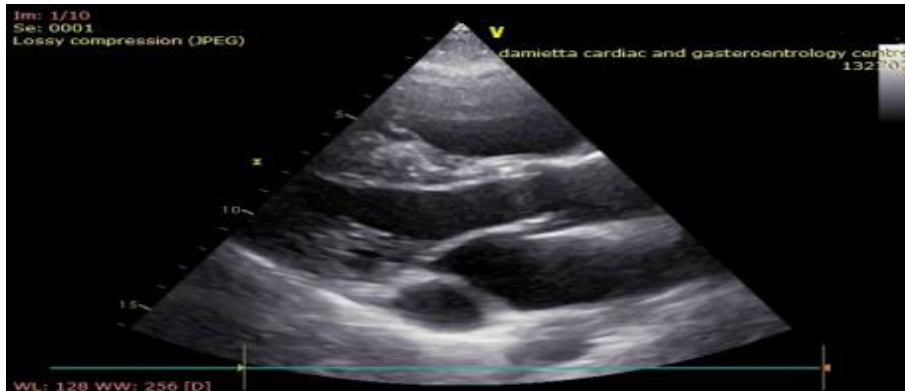

Figure (1): Transthoracic echo, parasternal long axis echocardiographic view showing dilated coronary sinus

The next step was search for the associated cardiac or extra-cardiac anomalies by multi-slice CT or cardiac MRI. Multi-slice CT was done and showed dilated RA, RV, sinus venosus ASD (superior type) measuring 20 mm ×20 mm, dilated coronary sinus, pulmonary trunk measuring 38×30 mm, partial anomalous pulmonary venous drainage (PAPVD) as the right superior pulmonary vein drain into the right lateral aspect of the SVC few mm above its entrance into the RA. The right middle pulmonary vein drain into confluence of SVC into RA by a single veno-atrial connection at the sinus venosus ASD, and persistent left superior vena cava (PLSVC) is receiving the left accessory hemiazygos vein and running along the left cardiac border into the coronary sinus then RA, no bridging veins see figure (5 to 14).

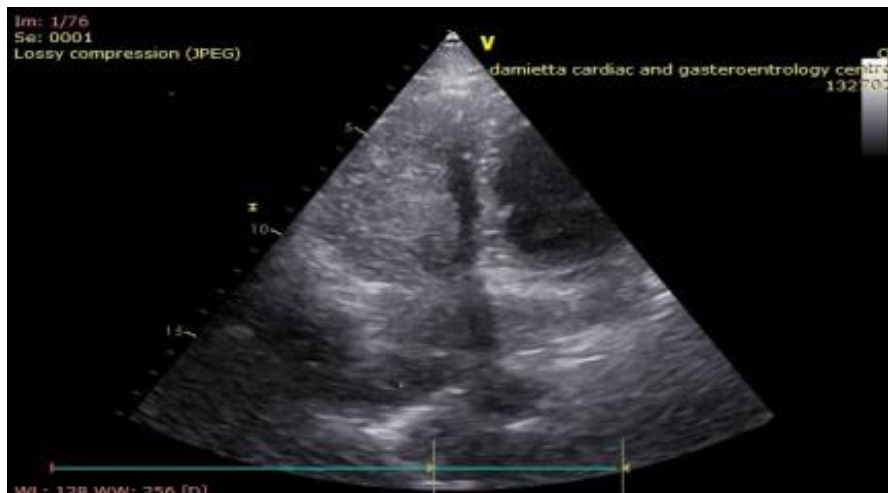

Figure (2): transthoracic echo, apical 4-chamber view with slight tilting of the probe showing dilated coronary sinus.

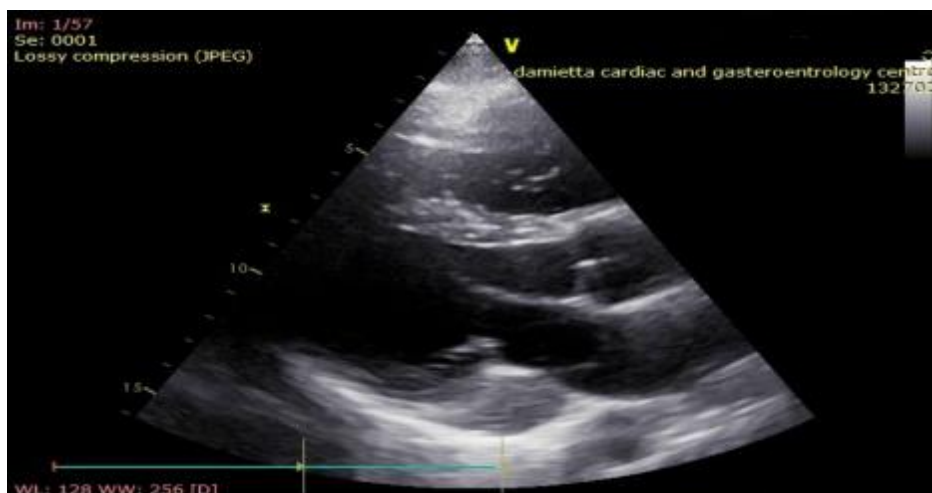


Figure (3): parasternal long axis view after injection of agitated saline reaching the coronary sinus before the right atrium of ventricle

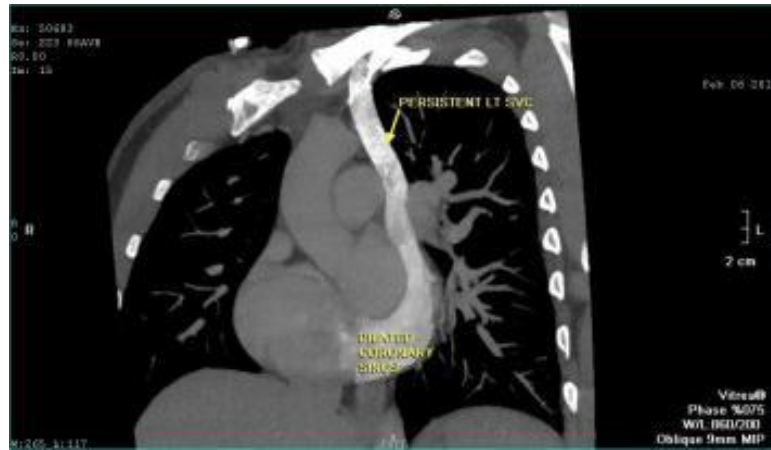


Figure (4): apical 4-chamber view with flow of agitated saline through the coronary sinus to the right atrium then right ventricle

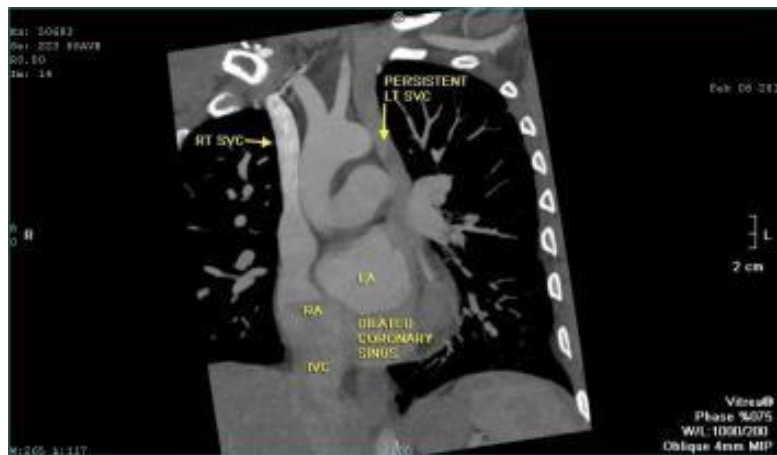

Figure (5): multi-slice CT, showing persistent left superior vena cava running along the left cardiac border of the heart into the dilated CS

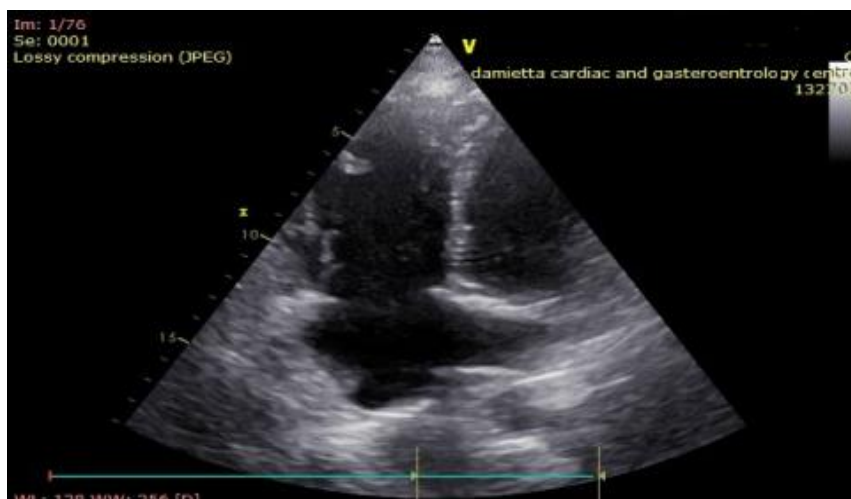


Figure (6): multi slice CT showing the right SVC, and PLSVC which is connected to the dilated CS

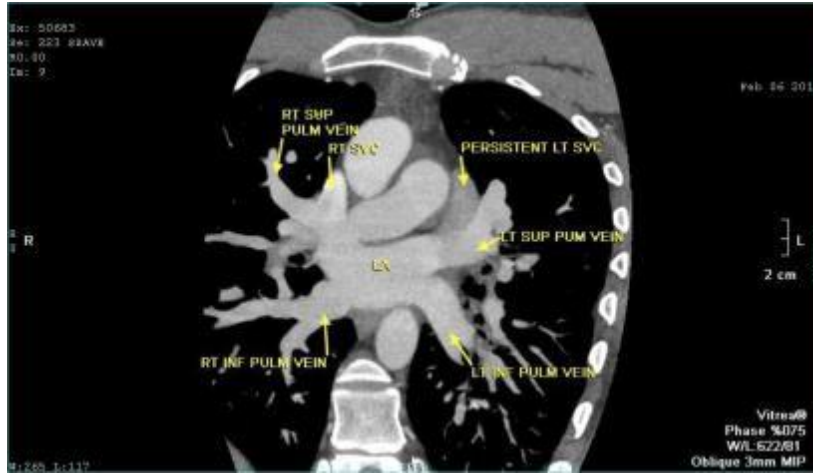


Figure (7): multi slice CT, showing the connection of pulmonary veins to the LA, and the right superior PV to the SVC.

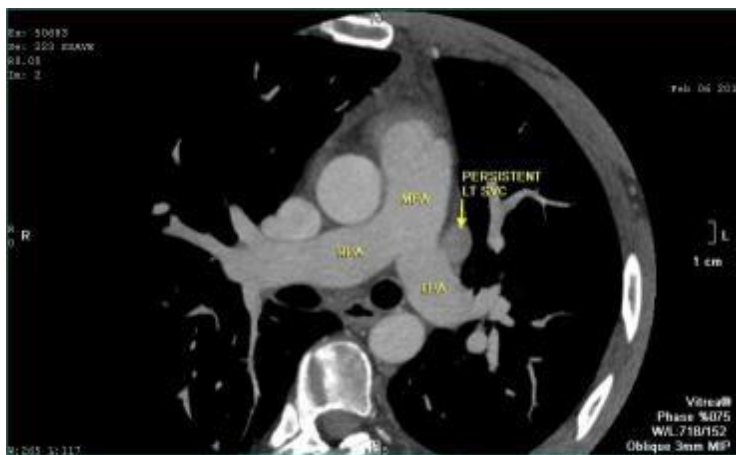

Figure (8): multi slice CT, showing the connection of right middle pulmonary vein to the site of sinus venosus ASD.

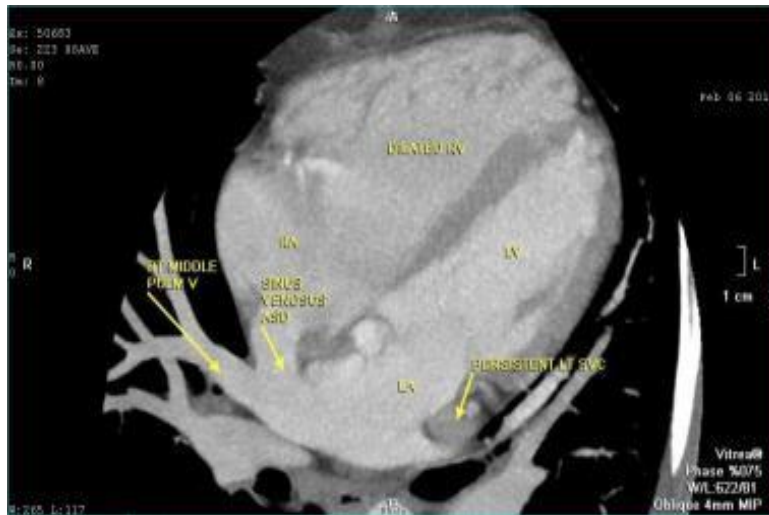

Figure (9): multi slice CT, showing the connection of right superior pulmonary veins to the SVC (PAPVD).

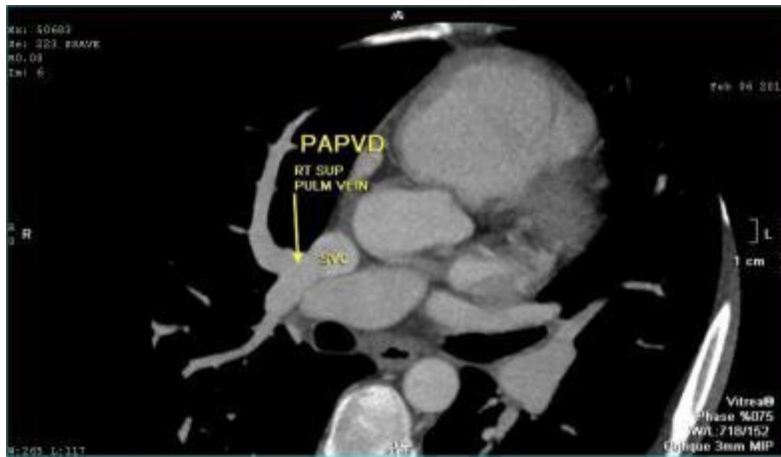


Figure (10): multi slice CT, showing the connection of right superior pulmonary veins and right middle pulmonary vein to RA by a single veno-atrial connection.

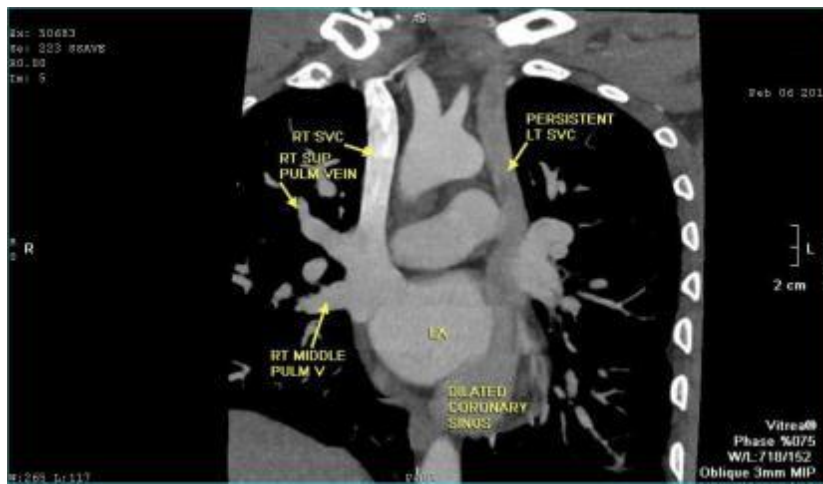


Figure (11): multi-slice CT, showing the site of LSVC in relation to main PA and left PA.

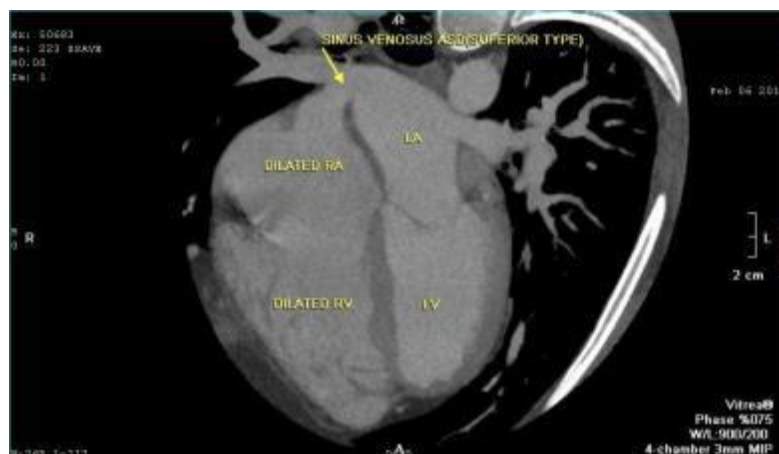

Figure (12): multi-slice CT, sinus venosus ASD, dilated RA, RV.

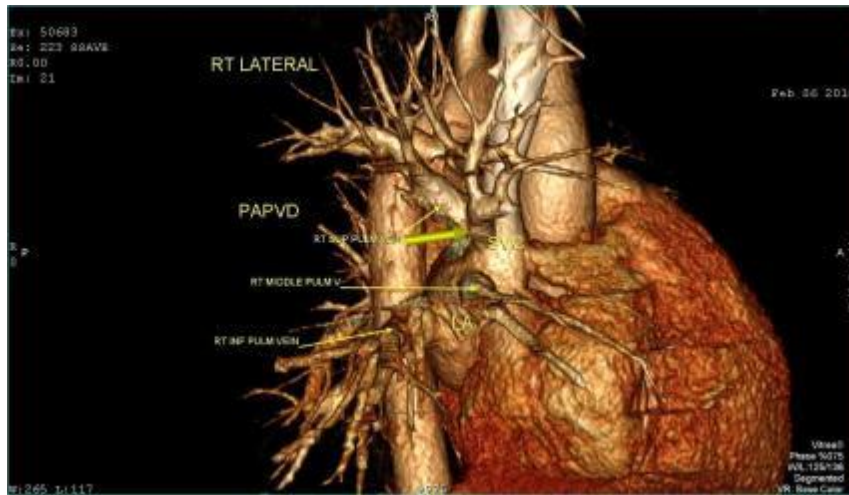


Figure (13): multi-slice CT, PAPVD

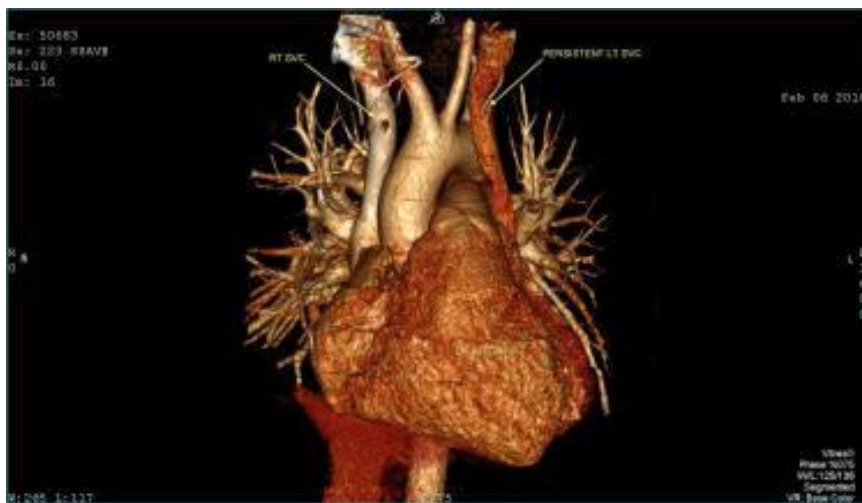


Figure (14): multi-slice CT, showing persistent left superior vena cava running along the left cardiac border of the heart.

DISCUSSION

The most common subtype of PLSVC results in the presence of both left and right SVCs. A bridging innominate vein may or may not be present. **Webb et al.**⁽¹⁰⁾ reported that a PLSVC is associated with absence of the innominate vein in 65% cases. More rarely, the caudal right superior cardinal vein regresses leading to an absent right SVC with PLSVC. In this case, the left SVC returns all the blood from cranial aspect of the body. Variations have also been reported in the insertion of left SVC. In 80–90% of individuals, the persistent LSVC drains into the right atrium via CS and is of no hemodynamic consequence. In the remaining cases, it may drain in left atrium resulting in a right to left sided shunt. Diagnosis of left SVC is usually made as an incidental finding during cardiovascular imaging or surgery. Placement of Swan-Ganz catheter via the left subclavian approach as in this case of PLSVC demonstrates an unusual course of the catheter on chest X-ray.

Transthoracic echocardiography reveals a dilated coronary sinus and diagnosis can be confirmed by use of saline contrast ("bubble study") echocardiography. PLSVC is not the only cause of a dilated coronary sinus,

however, with other etiologies including elevated right atrial pressure (most common), coronary arterio-venous fistula, partial anomalous pulmonary venous return, or an "unroofed" coronary sinus affording shunt flow between the left atrium and coronary sinus⁽¹¹⁾.

The following diagnostic criteria can be used with echocardiography: (1) the presence of a dilated coronary sinus on two-dimensional echocardiography in the absence of evidence of elevated right sided filling pressures; (2) enhancement of the dilated coronary sinus before the right atrium (RA) after contrast material infusion into a left arm vein; (3) normal transit of contrast with RA opacification before the coronary sinus with contrast injected from the right arm. Multislice computed tomography or magnetic resonance venography can also be employed to establish the diagnosis, and is useful to rule out variations in the typical anomalous venous course. Single or multiplane transesophageal echocardiography and radionuclide angiocardiology have also been used to establish diagnosis⁽¹²⁾.

Almost, 40% of patients with PLSVC can have a variety of associated cardiac anomalies, such as atrial septal defect, bicuspid aortic valve, coarctation of aorta,

coronary sinus ostial atresia, and cor triatriatum. The presence of associated anomalies is more common with concomitant absence of right SVC the notation of which warrants appropriate investigation to rule out other anomalies. The PLSVC has been associated with anatomical and architectural abnormalities of the sinus node and conduction tissues ⁽¹³⁾.

Improvements in catheter types and technique over time have permitted the successful placement of right atrial and right ventricular leads for dual-chamber pacing ⁽¹⁴⁾. In addition, cardiac resynchronization therapy for advanced chronic heart failure requires the placement of third pacing lead in left posterolateral vein of the heart. Several operators have successfully placed a cardiac resynchronization system, and therefore a lead via the coronary sinus in individuals with PLSVC with good intermediate term results ⁽¹⁵⁾.

During cardiac surgery, the presence of PLSVC is a relative contraindication to the administration of retrograde cardioplegia. It may be possible to clamp the PLSVC to prevent the cardioplegia solution from perfusing retrograde up the PLSVC and its branches with inadequate myocardial protection ⁽¹⁶⁾. However, there is a possibility that there may be some steal of cardioplegia solution through an accessory vein. During heart transplantation in a patient with PLSVC, the coronary sinus must be dissected carefully to permit re-anastomosis of PLSVC to RA ⁽¹⁷⁾.

CONCLUSION

PLSVC is a rare abnormality of systemic venous return often associated with other congenital cardiac malformations and physicians should be aware of such anomaly and its clinical implications in order to avoid possible complication. Persistent left superior vena cava is suspected in the presence of dilated coronary sinus during echocardiographic examination and can be confirmed by injection of agitated saline through the left arm vein. Diagnosis of PLSVC is important, as it is often associated with other anomalies as atrial septal defect and partial anomalous pulmonary venous drainage, which lead to pulmonary hypertension and need surgical correction before the occurrence of pulmonary hypertension.

LIST OF ABBREVIATION

PLSVC: persistent left superior vena cava

MRI: magnetic resonance imaging

CT: computerized tomography

ASD: atrial septal defect

CS: Coronary sinus

ECG: Electrocardiogram

LSVC: left superior vena cava

RA: right atrium

RV: right ventricle

TR: tricuspid regurge

PAPVD: partial anomalous pulmonary venous drainage

ICD: implantable cardioverter defibrillator

REFERENCES

1. **Parikh S, Prasad K, Iyer R et al. (1996):** Prospective angiographic study of the abnormalities of systemic venous connections in congenital and acquired heart disease. *Cathet Cardiovasc Diagn.*, 38 (4): 379–386.
2. **Galindo A, Gutiérrez-Larraya F, Escribano D et al. (2007):** Clinical significance of persistent left superior vena cava diagnosed in fetal life. *Ultrasound Obstet Gynecol.*, 30 (2): 152–161.
3. **Gustapane S, Leombroni M, Khalil A et al. (2016):** Systematic review and meta-analysis of persistent left superior vena cava on prenatal ultrasound: associated anomalies, diagnostic accuracy and postnatal outcome. *Ultrasound Obstet Gynecol.*, 48 (6): 701–708.
4. **Yoo S, Lee Y, Kim E et al. (1997):** Three- vessel view of the fetal upper mediastinum: an easy means of detecting abnormalities of the ventricular outflow tracts and great arteries during obstetric screening. *Ultrasound Obstet Gynecol.*, 9 (3): 173–182.
5. **Pahwa R, Kumar A (2003):** Persistent left superior vena cava: an intensivist's experience and review of the literature. *South Med J.*, 96 (5): 528–529.
6. **Ricciardi B, Ricciardi C, Lacquaniti A et al. (2017):** Persistent left superior vena cava and partially left inferior vena cava: a case report of a dangerous central venous catheterization. *J Vasc Access.*, 18 (5): 66–69.
7. **Bonnet D (2003):** Anomalies du retour veineux systemique. *Encycl Med Chir (Elsevier, Paris), Radiodiagnostic– Coeur-Poumon*, Pp: 1–4. <https://fr.slideshare.net/immadr/anomalies-du-retour-veineux-systmique-42525433>
8. **Tak T, Crouch E, Drake G (2002):** Persistent left superior vena cava: incidence, significance and clinical correlates. *Int J Cardiol.*, 82: 91–93.
9. **Milner D, Satinder P, Kamel A et al. (2015):** Comprehensive imaging review of the superior vena cava 1. *Radiographics*, 35: 1873-92.
10. **Webb W, Gamsu G, Speckman J et al. (1982):** Computed tomographic demonstration of mediastinal venous anomalies. *AJR Am J Roentgenol.*, 139 (1): 157-161.
11. **Goyal S, Punnam S, Verma G et al. (2008):** Persistent left superior vena cava: a case report and review of literature. *Cardiovasc Ultrasound*, 6: 50-58.
12. **Voci P, Luzi G, Agati L (1955):** Diagnosis of persistent left superior vena cava by multiplane transesophageal echocardiography. *Cardiologia*, 40 (4): 273-275.
13. **Sarodia B, Stoller J (2000):** Persistent left superior vena cava: case report and literature review. *Respir Care*, 45 (4): 411-416.
14. **Roberts D, Bellamy C, Ramsdale D (1992):** Implantation of a dual chamber pacemaker in a patient with persistent left superior vena cava. *Int J Cardiol.*, 36 (2): 242-243.
15. **Meijboom W, Vanderheyden M (2002):** Biventricular pacing and persistent left superior vena cava. Case report and review of the literature. *Acta Cardiol.*, 57 (4): 287-290.
16. **Oosawa M, Sakai A, Abe M et al. (1995):** Repeat open heart surgery in a case associated with persistent left superior vena cava: a method of simple occlusion of L-SVC using an alternative extra-pericardial approach and retrograde cardioplegia. *Kyobu Geka.*, 48 (9): 741-744.
17. **Nsah E, Moore G, Hutchins G et al. (1991):** Pathogenesis of persistent left superior vena cava with a coronary sinus connection. *Pediatr Pathol.*, 11 (2): 261-269.