

Early Results of Surgical Treatment of Intra-Articular Calcaneal Fractures Using T-Shaped Plates

Ahmed Abdulmunem Husayn Layyas*, Mohsen Mohamed Abdo Mar'e'i, Reda Hussien Elkady, Mohamed Abd Elaziz Mohamed Ghieth

Department of Orthopedic, Faculty of Medicine, Zagazig University, Sharkia, Egypt

*Corresponding Author: Ahmed Abdulmunem Husayn Layyas, Mobile: 00218925430873,

E-mail: layas.ahmed87@gmail.com

ABSTRACT

Background: Displaced intra-articular calcaneus fractures are still now a controversial topic among orthopedic surgeons. There is no single treatment option to manage all different fractures. **Objective:** The aim of this study was the assessment and evaluation of providing and maintaining stable fixation by the use of a T-shaped plate for displaced intra-articular calcaneal fractures. **Patients and Methods:** A randomized controlled study was conducted on 18 patients were conducted between the ages of 18 to 50 years in the Orthopedic and Traumatology Department of Zagazig University Hospital from August 2020 to April 2021 including 6 months follow-up periods, all patients with closed D.I.A.C.F with no morbidity. T plates were the method of fixation for all patients.

Results: Mean A.O.F.A.S. hindfoot scale result was 86.61, 88.8% of patients their results were satisfying (excellent and good), and 11.1% of patients their results were unsatisfying (fair). Complications were seen in 27.7% (wound complication, subtalar arthritis, symptomatic hardware, and delayed union).

Conclusion: T-shaped plates can provide stable support and rigid fixation as they maintain proper reduction and alignment to displaced intra-articular calcaneus fractures.

Keywords: Surgical, Calcaneus fracture, T-Shaped Plates.

INTRODUCTION

Calcaneal fractures correspond to 2% of skeletal fractures and about 60% of fractures of the tarsal bones⁽¹⁾.

Calcaneal fractures are divided into two types extra-articular and intra-articular, about 60% to 75% of calcaneal fractures are displaced intra-articular calcaneal fracture (D.I.A.C.F)^(2,3).

The most common cause of injury is axial loading by fall from height leading to calcaneal fractures. Other modes of injury like the brake pedal and high-velocity trauma causing open fractures are also common. Associated fractures like spinal and pelvic fractures must be excluded^(4,5).

The complex anatomy of the hindfoot raises the difficulty of dealing with this calcaneal fracture⁽⁶⁾. The calcaneus bone is irregular in shape with numerous articular facets with very challenging soft-tissue cover, making proper surgical intervention time-sensitive^(7,8).

Despite the great development of orthopedic traumatology in the last century, treatment of these fractures is still controversial and results are often unsatisfactory, due to the complex anatomical shape of the calcaneus, and the fact that it is subjected to constant weight load⁽⁹⁾. Thus, this injury causes major socioeconomic and functional impairment to patients and represents a burden to public and private compensation policies⁽¹⁰⁾.

Tomographic classifications help to assess the severity and prognosis of the injury. Sander's classification is the most commonly used⁽¹¹⁾.

According to the Essex-Lopresti classification, intra-articular fractures can be tongue-type or joint depression types. In most series, joint depression is the

most frequent type of fracture, accounting for 43%–61% of intra-articular fractures^(12,13).

The most suitable treatment for displaced intra-articular calcaneal fractures is still controversial. Since the mid-1990s, open reduction and internal fixation (ORIF) via the extensile lateral approach has been considered the standard treatment for displaced intra-articular fractures of the calcaneus, as it generally restores the subtalar joint anatomically and has good functional outcomes^(14,15). However, there are multiple complications of open surgery including peroneal tendonitis (18%), sural nerve injury (9%), vascularization injury (6-33%), infections (8-18%), and amputation (0-2%)^(16,17).

Attempts to limit these complications many surgical techniques have been developed including: (limited lateral, plantar, combined lateral and medial, u-incision, Kocher, and limited posterior approach). Limited lateral approaches include: (plantar, Ollier, and sinus tarsi). The sinus tarsi approach is using a smaller incision hence limiting soft tissue dissection and provides a good visualization of the articular reduction⁽¹⁸⁻²⁰⁾.

Intra-articular fractures require anatomic reduction and stable fixation to improve the chances of a good outcome⁽²¹⁾. This study was performed to evaluate providing and maintaining stable fixation by



the use of a T-shaped plate for displaced intra-articular calcaneal fractures.

PATIENTS AND METHODS

A randomized controlled study was conducted on 18 patients (12 males (66.6%) and 6 females (33.3%) aged (18-50) years old and the mean age (33) was years and had 19 feet with a displaced intra-articular fracture of the calcaneus. Twelve patients were operated on with O.R.I.F. via the extensile lateral approach while 8 patients (33.3%) were operated on via the sinus tarsi approach.

In this study, 19 feet were operated on (one case was bilateral, 11 left fractures (57.9%), and 8 right fractures (42.1%). Fall from height was the main cause of the injury to 16 patients (88.8%) and road traffic accidents caused the fracture to the remaining 2 patients (11.1%). Calcaneus fracture has been associated with other injuries in a total of 5 patients (27.7%), spine fractures in 3 patients (16.6), pelvic fracture in 1 patient (5.5%), and left talus fracture in the same foot in one patient (5.5%)

Classification of fracture:

The fractures were classified according to both Essex Leprosi classification on plain x-ray and Sanders classification on CT scanning.

According to Essex classification, 12 patients (66.6%) had joint depression type and 6 patients (33.3%) were tongue type fracture. According to Sanders classification, 11 patients (61.1%) were classified as sanders type II and 7 patients (38.8%) were sanders type III.

Approval taking Institutional Review Board (IRB) approval and also informed written consent was taken from patients and/or their caregivers. This Work was performed according to the code of Ethics of the World Medical Association (Declaration of Helsinki) for studies involving humans.

Inclusion criteria: Patients with closed displaced intra-articular fractures of the calcaneus, patients aged from 18 to 50 years old, and patients who had preoperative computed tomography and radiographs of the foot, ankle, and calcaneus.

Exclusion criteria: Fractures treated conservatively due to the patient's reasons or lack of surgical indication, lack of adequate skin condition, edema, and blisters in the lateral aspect of the foot, not resolved by the date of the surgery, and presence of clinical comorbidities such as vascular disorders, heart disease, or decompensated diabetes.

Pre-operative:

All patients in this study undergo proper planning and management before proceeding to the surgery. This management includes; proper clinical assessment by taking full and detailed history with general and local examination, radiological assessment by plain x-ray (axial, lateral, and AP views), and

computed tomography to fully understand the pattern and the nature of the fracture. Routine preoperative laboratory tests were done including; complete blood count, blood typing, renal function, liver function, coagulation profile, blood sugar, and C reactive protein. All patients were complaining of heel pain, swelling, and inability to bear weight, so initial treatment was done with analgesic, elevating the foot, cold compresses, and slab in a neutral position to avoid more swelling and skin blister which will interfere with the ability to perform the surgery, especially with those indicated to surgery by the extensile lateral approach.

Surgical technique:

All patients were operated on spinal anesthesia (15 patients), except in the patients with associated spine injury (3 patients) where general anesthesia was used. A pneumatic thigh tourniquet was used up 300mmHg with pre squeeze to the limb with setting the time of application of the tourniquet. Antibiotic (3rd generation cephalosporin) is given before the application of tourniquet by 30 minutes. Kirschner wires were inserted to hold the skin flap back and perform a non-touch technique, the 3 K wires placed on the fibula, talus, and cuboid bone (Figure 1).

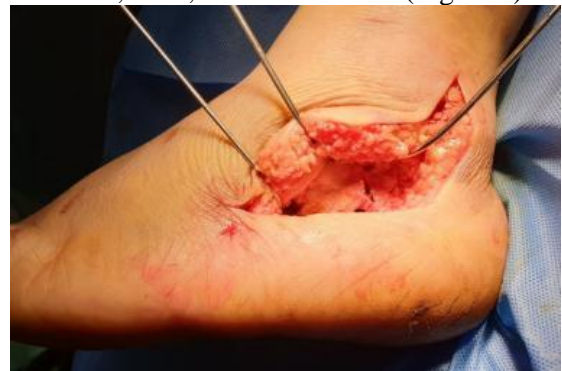

Figure (1): Full-thickness flap non-touch technique.

Steinmann pin was inserted (under fluoroscopy guide) from lateral to medial in the inferior part of the posterior of the calcaneus. Reduction is started from medial to lateral then from posterior to anterior and by the tuberosity fragment, then restoration of calcaneal height and length with valgus and varus alignment is done (figure 2).

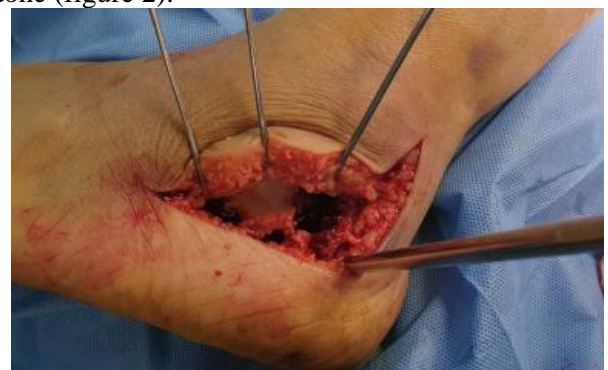

Figure (2): Steinmann pin insertion for traction.

After reduction and restoration of the calcaneus, alignment is done a 2.5 or 3mm k wires were inserted as a temporary fixation (under fluoroscopy guide), these k wires may be removed after the fixation by the T-shaped plate before closure or after 2 to 3 weeks postoperatively if further fixation is required. A lag screw is used in some patients in addition to a T-shaped plate, the screw is inserted anterior and medial with slightly angled inferiorly into the sustentaculum tail across the tuberosity into the good bone of the medial side of the calcaneus.

A small T-shaped plate (3.5 mm) was placed on the lateral wall of the calcaneus to check the proper size and location before fixation, after placement of the plate in the proper position it is fixed with suitable screws (Figure 3).

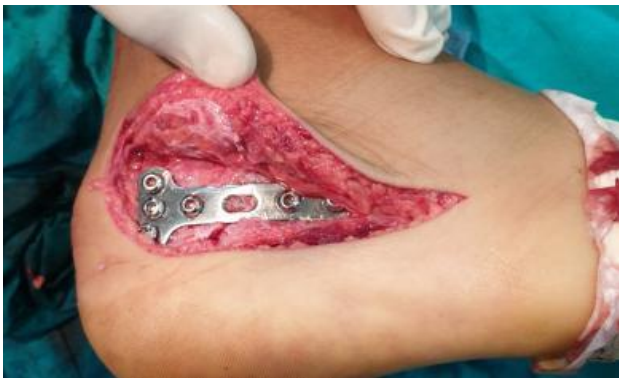

Figure (3): T-shaped plate final fixation.

K wire used for temporary fixation was removed in the operation or 3 weeks postoperatively according to the condition of fracture and amount of fixation required.

There was no need for the use of bone graft in all cases. Irrigation and proper hemostasis were done and closure was done in a layered fashion with absorbable suture vicryl (2-0), and a drainage tube is also used (Figure 4).

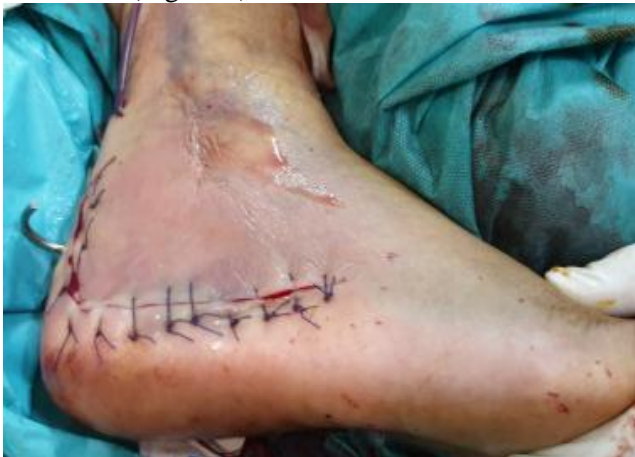

Figure (4): Closure and drainage.

Postoperative care and follow-up:

Antibiotic is given in the first 24 to 48hr. Motion and exercise are avoided until the wound is healed (exercise is induced as soon as the wound is healed and the patient tolerant to avoid the stiffness to the subtalar joint and movements like inversion and eversion are encouraged). Sutures and k.w removed after 2 to 3 weeks. Clinical and radiological evaluations are made in monthly intervals. Partial weight-bearing is encouraged only when signs of the union are confirmed by the x-ray which normally occurred in a period of 8 to 10 weeks (delayed in old, smokers, obese and diabetic patients). Full weight-bearing is encouraged after that according to each patient's tolerance. Functional assessment was done according to A.O.F.A.S (American orthopedic foot and ankle society) on 3rd and 6th months postoperatively.

Ethical Considerations:

Approval of the study was obtained from Zagazig academic and ethical committee. Every patient signed informed written consent for the acceptance of the operation. This work has been carried out following The Code of Ethics of the World Medical Association (Declaration of Helsinki) for studies involving humans.

Statistical analysis

The collected data were coded, processed, and analyzed using the SPSS (Statistical Package for Social Sciences) version 22 for Windows® (IBM SPSS Inc, Chicago, IL, USA). Data were tested for normal distribution using the Shapiro Walk test. Qualitative data were represented as frequencies and relative percentages. Chi-square test (χ^2) to calculate the difference between two or more groups of qualitative variables. Quantitative data were expressed as mean \pm SD (Standard deviation). Independent samples t-test was used to compare between two independent groups of normally distributed variables (parametric data). P-value $<$ 0.05 was considered significant.

RESULTS

Fall from height was the main cause of injury which caused the fracture in 16 patients (88.8%) and RTA caused the fracture in 2 patients (11.1%). There was no significant correlation between M.O.I and A.O.F.A.S. hindfoot scale results as the p-value is greater than the significance level (0.05) (Table 1).

Table (1): Mechanism on injury and A.O.F.A.S. results relationship

M.O.I	Excellent		Good		Fair		Total	Chi-square
	Number	%	Number	%	Number	%		P-value
F.F.H.	3	18.7	11	86.7	2	12.5	16	0.648
RTA	0	0	2	100	0	0	2	
Total	3	16.6	13	72.2	2	11.1	18	

According to the Essex classification of calcaneus fracture, 12 patients (66.6%) in this study were joint depression type while 6 patients (33.3%) were tongue type. There was no significant correlation between Essex classification and A.O.F.A.S. hindfoot scale results as the p-value is greater than the significance level (0.05) (Table 2).

Table (2): Essex classification and A.O.F.A.S. results relationship

Essex	Excellent		Good		Fair		Total	Chi-square
	Number	%	Number	%	Number	%		P-value
J.D	1	8.33	9	75	2	16.6	12	0.594
Tongue	2	33.3	4	66.6	0	0	6	
Total	3	16.6	13	72.2	2	11.1	18	

According to Sander's classification of calcaneus fracture, 11 patients (61.1%) were Sanders type II and 7 patients (38.8%) were Sanders type III. There was a significant correlation between Sanders classification and A.O.F.A.S. hindfoot scale results as the p-value is equal to the significance level (0.05) as showing in (Table 3).

Table (3): Sanders classification and A.O.F.A.S. results relationship.

Sander	Excellent		Good		Fair		Total	Chi-square
	Number	%	Number	%	Number	%		P-value
II	3	27.2	8	72.7	0	0	11	0.05
III	0	0	5	71.4	2	28.5	7	
Total	3	16.6	13	72.2	2	11.1	18	

In this study, there was a highly significant improvement ($p < 0.001$) in Bohler angle between pre, immediate postoperative, and final follow-up measurements. The mean preoperative Bohler angle was 12.6° and immediate postoperative was 28.0° and in final follow up Bohler angle was 27.6° . In this study, there was a highly significant improvement ($p < 0.001$) in Gissane angle between pre, immediate postoperative, and final follow-up measurements. The mean preoperative Gissane angle was 137.9° and immediate postoperative was 122.8° and in final follow-up, Gissane angle was 122.8° (Table 4).

Table (4): Radiological evaluations of calcaneus angles pre, immediate operative, and final follow-up

Angle	Mean±SD Preoperative	Means ±SD Immediate post	Mean ±SD, at Last, Follow up	Paired T.test p-value
Bohler	$12.6^{\circ} \pm 6.29$	$28^{\circ} \pm 7.53$	$27.6^{\circ} \pm 7.93$	0.000312
Gissane	$137.9^{\circ} \pm 9.7$	$122.8^{\circ} \pm 10.12$	$122.8^{\circ} \pm 10.12$	0.000324

In this study, complications occurred in 5 patients (27.7%) (Figure 5) wound infection in two patients (11.1%) 13 to 15 days postoperative, both patients' fractures classified to sanders type III and operated by the extensile lateral approach. One of them was a heavy smoker, both treated with debridement and antibiotic coverage with continuous follow-up and dressing change without the need to remove the hardware and the result to these patients according to A.O.F.A.S. hindfoot scale was 85 (good) and 89 (good). Symptomatic hardware in one patient (5.55%), the patient's fracture classified to Sanders type II and operated by lateral extensile approach, all other causes of heel pain was excluded and the irritable screw was removed after 4 months of the operation and patients complain resolved with A.O.F.A.S. hindfoot scale result was 80 (good).

Subtalar arthritis in one patient (5.55%), the patient's fracture classified to Sanders type III, and operated via extensile approach and scheduled for subtalar arthrodesis and A.O.F.A.S. hindfoot scale result was 73(fair). Delayed union in one patient (5.55%), the patient's fracture classified to Sanders type III and operated via extensile lateral approach, the patient was old and smoker and advised on smock cessation and vitamins and minerals (including calcium and Vit.D) supplements were given with regular follow-up and A.O.F.A.S. hindfoot scale result was 82 (good).

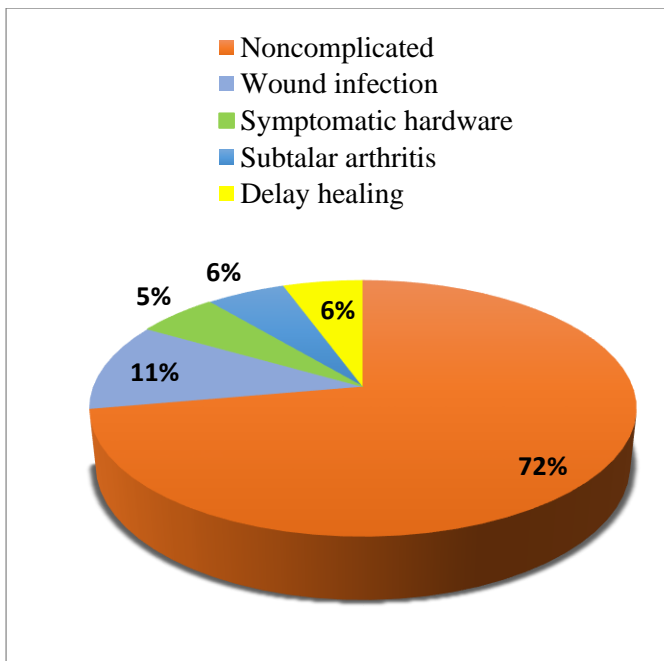


Diagram (5): Complications of surgery.

DISCUSSION

In this study, fall from height was the main cause of the fracture among 16 patients (88.8%), and road traffic accidents were the cause to the remaining 2 patients (11.1%). Santosha *et al.* (22) reported that the most common mode of injury was fall from the height which constituted 21 patients (87.5%) out of 24 patients conducted in their study. Zeman *et al.* (23) in their study said that the most frequent cause of the injury was a fall or jump from the height, which was recorded in 27 patients (93.1%).

In this study, according to Essex classification 12 patients (66.6%) had joint depression type and 6 patients (33.3%) had tongue type fracture which coincided with Santosha *et al.* (23) who reported that 19 (63.3%) of their study patients had joint depression fracture and eleven (36.6%) had tongue type fracture configuration. While Pendse *et al.* (24) found that 21 cases (70%) had joint depression variety and 9 patients (30%) had tongue type fractures.

In this study, the assessment and evaluation of outcome and results are based upon radiological evaluation mainly to Bohler and Gissane angles and calcaneus parameters like length, height, and width together with the clinical evaluation according to the A.O.F.A.S. hindfoot scale which the mean result at the last follow up was 86.61, excellent in (16.6%), good in (72.2%), fair in (11.1%) and no poor results.

The results of this study are considered higher than the ones obtained by Santosha *et al.* (22) who operated on 30 fractures with locked calcaneus plate and the mean A.O.F.A.S. was 79.9 (Range 49-96). Excellent results were achieved in 13 (43.3%) cases, good results in 10 (33.3%), fair results in three (10%) cases, and poor results in four cases (13.3%).

Bohler's angle reduction is associated with a better outcome, which can be obtained by open reduction and rigid fixation with plating. In this study, there was a highly significant improvement ($p < 0.001$) in Bohler angle between preoperative, immediate postoperative, and final follow-up measurements.

The mean preoperative Bohler angle was 12.6° and immediate postoperative was 28° and at final follow up was 27.6° and it was maintained in the normal range (20° to 40°) in all the patients which is a better result than Santosha *et al.* (22) where the angle was restored and maintained only in 25 (83.3%) feet after 24 months of follow-up. Haddad *et al.* (25) noted that restoration of Bohler's angle in 74% of calcaneum, while 86.6% of calcaneal restoration was reported in a study conducted by Jain *et al.* (26) who found that the mean Bohler's angle improved from preoperative 4.15° to immediate postoperative 27.69° which was decreased to 25.47° at final follow-up.

In the present study, complications are seen in 5 patients (27.7%), two patients with wound complications 11% (low incidence due to use of STA in many patients and non-touch technique with ELA) treated with debridement, antibiotics, and dressing change and there was no need for further surgery. One patient had symptomatic hardware 5% where screw extraction was done, and another patient had delay union 5% (old and heavy smoker patient) while one patient 5% had subtalar arthritis scheduled for arthrodesis.

These results are comparable with Santosha *et al.* (22) who reported ankle swelling in 50%, heel pain in 33.3%, subtalar arthritis in 10%, and wound dehiscence in 4%.

CONCLUSION

T-shaped plates can provide stable support and rigid fixation as they maintain proper reduction and alignment to displaced intra articular calcaneus fractures.

With comparable results regarding radiological parameters like Bohler angle, Gissane angle, and calcaneus dimensions like length, height, and width and functional outcome by using A.O.F.A.S. hindfoot scale when compared to different calcaneal plates.

Further studies are recommended with more patients and a longer period of follow-up for a more appropriate assessment of the complications and long-term results.

REFERENCES

1. Griffin D, Parsons N, Shaw E *et al.* (2014): Operative Versus Non-operative Treatment for

- Closed, Displaced, Intra-Articular Fractures of the Calcaneus: Randomised Controlled Trial. *BMJ*, 349:g4483.
- Sanders R (2000):** Current Concepts Review - Displaced Intra-Articular Fractures of the Calcaneus. *The Journal of Bone and Joint Surgery American*, 82(2):225-50.
 - Besch L, Schmidt I, Mueller M et al. (2008):** A Biomechanical Evaluation to Optimize The Configuration of a Hinged External Fixator for the Primary Treatment of Severely Displaced Intraarticular Calcaneus Fractures with Soft Tissue Damage. *The Journal of Foot and Ankle Surgery*, 47(1):26-33.
 - Fitzgibbons T, McMullen S, Mormino M (2001):** Fractures and Dislocations of the Calcaneus1 In: Bucholz RW, editor1 Rockwood and Green's fractures in adults1 5th ed, Philadelphia. Lippincott Williams & Wilkins, pp. 2133-2179. <https://www.worldcat.org/title/rockwood-and-greens-fractures-in-adults/oclc/300348277>
 - Raymakers J, Dekkers G, Brink P (1998):** Results after Operative Treatment of Intra-Articular Calcaneal Fractures with a Minimum Follow-up of 2 Years. *Injury*, 29(8):593-9.
 - Benirschke S, Sangeorzan B (1993):** Extensive Intra-Articular Fractures of the Foot. *Surgical Management of Calcaneal Fractures. Clinical Orthopaedics and Related Research*, 292:128-34.
 - Benirschke S, Kramer P (2004):** Wound Healing Complications in Closed and Open Calcaneal Fractures. *Journal of Orthopaedic Trauma*, 18(1):1-6.
 - Al-Mudhaffar M, Prasad C, Mofidi A (2000):** Wound Complications Following Operative Fixation of Calcaneal Fractures. *Injury*, 31(6):461-4.
 - Zhang T, Su Y, Chen W et al. (2014):** Displaced Intra-Articular Calcaneal Fractures Treated in a Minimally Invasive Fashion: Longitudinal Approach Versus Sinus Tarsi Approach. *The Journal of Bone and Joint Surgery American*, 96(4):302-9.
 - Yu X, Pang Q, Chen L et al. (2014):** Postoperative Complications after Closed Calcaneus Fracture Treated by Open Reduction and Internal Fixation: a Review. *Journal of International Medical Research*, 42(1):17-25.
 - Sanders R (1990):** Radiological Evaluation and CT Classification of Calcaneal Fractures. *Disorders of the Foot and Ankle 3rd ed Philadelphia: WB Saunders*, pp. 2326-2354.
 - Chhabra N, Sherman S, Szatkowski J (2013):** Tongue-type Calcaneus Fractures: a Threat to Skin. *The American Journal of Emergency Medicine*, 31(7):1151-3.
 - De Vroome S, van der Linden F (2014):** Cohort Study on the Percutaneous Treatment of Displaced Intra-Articular Fractures of the Calcaneus. *Foot & Ankle International*, 35(2):156-62.
 - Bing L, Wu G, Yang Y (2016):** Conservative Versus Surgical Treatment for Displaced Fracture of the Medial Process of the Calcaneal Tuberosity. *Journal of Orthopaedic Surgery*, 24(2):163-6.
 - Yao H, Liang T, Xu Y et al. (2017):** Sinus Tarsi Approach Versus Extensile Lateral Approach for Displaced Intra-Articular Calcaneal Fracture: a Meta-analysis of Current Evidence Base. *Journal of Orthopaedic Surgery and Research*, 12(1):1-9.
 - Wakatsuki T, Imade S, Uchio Y (2016):** Avulsion Fracture of the Calcaneal Tuberosity Treated Using a Side-locking Loop Suture (SLLS) Technique Through Bone Tunnels. *Journal of Orthopaedic Science*, 21(5):690-3.
 - Kiewiet N, Sangeorzan B (2017):** Calcaneal Fracture Management: Extensile Lateral Approach Versus Small Incision Technique. *Foot and Ankle Clinics*, 22(1):77-91.
 - Schepers T (2011):** The Sinus Tarsi Approach in Displaced Intra-Articular Calcaneal Fractures: a Systematic Review. *International Orthopaedics*, 35(5):697-703.
 - Meraj A, Zahid M, Ahmad S (2012):** Management of Intra-Articular Calcaneal Fractures by Minimally Invasive Sinus Tarsi Approach Early Results. *Malaysian Orthopaedic Journal*, 6(1):13-19.
 - Mostafa M, El-Adl G, Hassanin E et al. (2010):** Surgical Treatment of Displaced Intra-Articular Calcaneal Fracture Using a Single Small Lateral Approach. *Strategies in Trauma and Limb Reconstruction*, 5(2):87-95.
 - Abdelazeem A, Khedr A, Abousayed M et al. (2014):** Management of Displaced Intra-Articular Calcaneal Fractures Using the Limited Open Sinus Tarsi Approach and Fixation by Screws Only Technique. *International Orthopaedics*, 38(3):601-6.
 - Santosh G, Singh A, Waikhom S et al. (2016):** Open Reduction and Internal Fixation of Displaced Calcaneum, Intra-Articular Fractures by Locking Calcaneal Plate. *Journal of Clinical & Diagnostic Research*, 10(12):18-21.
 - Zeman P, Zeman J, Matejka J et al. (2008):** Long-term Results of Calcaneal Fracture Treatment by Open Reduction and Internal Fixation Using a Calcaneal Locking Compression Plate from an Extended Lateral Approach. *Acta Chirurgiae Orthopaedicae et Traumatologiae Cechoslovaca*, 75(6):457-64.
 - Pendse A, Daveshwar R, Bhatt J (2006):** Outcome after Open Reduction and Internal Fixation of Intra-Articular Fractures of the Calcaneum without the Use of Bone grafts. *Indian Journal of Orthopaedics*, 40(2):111.
 - Haddad M, Horesh Z, Soudry M et al. (2014):** Surgical Treatment of Calcaneal Comminuted Intra-Articular Fractures: Long-Term Follow-Up. *Open Journal of Clinical Diagnostics*, 4(03):117-122.
 - Jain S, Jain A, Kumar I (2013):** Outcome of Open Reduction and Internal Fixation of Intra-Articular Calcaneal Fracture Fixed with Locking Calcaneal Plate. *Chinese Journal of Traumatology*, 16(6):355-60.